



Conversion total hip arthroplasty Functional outcome in Egyptian population

Akram HAMMAD, Ahmed ABDEL-AAL

From Mansoura and Assiut University Hospitals, Egypt

Hemiarthroplasty has been successfully used for treatment of femoral neck fractures in the elderly. With increased demand being placed on the prostheses, some of them failed and had to be converted to total hip replacement. The aim of this study is to evaluate the result of conversion arthroplasty in Egyptian population.

We report 47 patients who had conversion to total hip arthroplasty following failed hemiarthroplasty. There were 32 women and 15 men. The mean age was 64.3 years (range 54 to 83 years); the average follow-up was 44 months (range 24 to 84 months). The main indication for conversion was either acetabular erosion or stem loosening.

Harris hip score improved from a mean of 40.9 points preoperatively to a mean of 86.0 points at the last follow-up. Ninety four percent of the patients had either excellent or good results. Eight patients had nine complications, but there were no instances of instability or loosening. Conversion total hip arthroplasty appears as an excellent management strategy for failed hemiarthroplasty.

Keywords : femoral neck fractures ; hemiarthroplasty ; failure ; THR conversion.

INTRODUCTION

Hemiarthroplasty has been widely used for the treatment of displaced intracapsular fractures of the femoral neck in elderly patients because of the high incidence of non-union and avascular necrosis

following open reduction and internal fixation (ORIF) (24).

Inevitably, some hemiarthroplasties fail and require revision for pain, impaired walking ability, leg length discrepancy or a combination of those. The rate of re-operation varies from 5 to 24% among patients treated by hemiarthroplasty (21).

The treatment of displaced intracapsular fractures in patients who are mobile, socially independent and otherwise fit, is controversial. A prospective randomised comparative study of ORIF, hemiarthroplasty and total hip replacement has shown that patients treated with total hip replacement have better mobility and pain relief after one year and thirteen years (23).

Cossey and Goodwin (4) have shown that conversion to total hip replacement for symptomatic failed hemiarthroplasty gave the patient a pain-free and functionally acceptable life style.

■ Akram Hammad, MD, Assistant Professor in Orthopaedic Surgery.

Orthopaedic Department, Mansoura University Hospital, Egypt.

■ Ahmed Abdel-Aal, MD, Assistant Professor in Orthopaedic Surgery.

Orthopaedic Department, Assiut University Hospital, Egypt.

Correspondence : Dr. Akram Hammad, Orthopaedic Department, Mansoura University Hospital, Mansoura 35516, Egypt.
E-mail: akram_hammad@hotmail.com.

© 2006, Acta Orthopædica Belgica.

The aim of this study was to assess the results of conversion of a failed hemiarthroplasty used to treat femoral neck fracture to a total hip replacement in elderly patients.

PATIENTS AND METHODS

From January 1999 till January 2004, a total of 47 patients had conversion of their failed hemiarthroplasty to a total hip replacement in Assiut and Mansoura university hospitals.

All patients were evaluated clinically and radiologically with review of serial follow-up radiographs if available to identify the possible cause of failure.

Harris hip score (12) was used for functional evaluation in the preoperative, postoperative and follow-up assessment.

Postoperative radiographs were evaluated for component orientation, adequacy of fixation including cement mantle thickness and presence of lucent lines in cemented prostheses. Change in component position or progression of lucent lines were reported in serial follow-up radiographs according to the zones of Gruen *et al* (11) for the femur and De Lee and Charnley (5) for the acetabulum. We used the criteria of Olsson (18) for diagnosis of loosening.

There were 32 women (68%) and 15 men with a mean age of 64.3 years (range 54 to 83 years) at the time of conversion arthroplasty. The mean period of follow-up was 44 months (range 24 to 84 months). Twenty-seven Austin Moore, 18 cemented Thompson and 2 cemented Austin Moore prostheses had been implanted.

Pain with either antalgic gait or leg length discrepancy was the chief presenting complaint. Other presenting complaints are shown in table I.

The main reasons for conversion arthroplasty were acetabular erosion in 18 patients (38.2%) (fig 1), stem loosening in 11 patients (23.4%); there were also 8 patients (17.3%) with an unreduced dislocation – 7 of them were cemented Thompson's –, 4 patients (8.5%) with femoral shaft fracture – all were Thompson's – and two of them showed acetabular erosion as well, three patients (3.66%) with stem fracture (fig 2) and another three patients with deep infection (fig 3).

The mean time from primary operation to appearance of symptoms in this group of patients was 19 months (range 2-96 months), 4 months for dislocated hemiarthroplasty (range 2-9 months, 11 months for femoral loosening (range 5-46 months) and 28 months for acetabular erosion (9-96 months).

Table I. — Patients' Complaints

Complaints	N = 47	%
Pain	13	27.6
Pain+ Antalgic gait	16	34.1
Pain+ LLD	15	31.9
Pain+ antalgic gait+ LLD	3	6.3

LLD = leg length discrepancy

The mean time interval from appearance of symptoms to revision surgery for this group of patients was 33 months; it was 21 months for femoral loosening, 31 months for acetabular erosion and 42 months for femoral shaft fractures.

A standard posterior approach to the hip was used in all patients. Patients revised for infection had a two-stage revision. A transfemoral approach was used in 13 patients: 6 patients with acetabular erosion, 3 with a dislocated cemented prosthesis, 2 with a fractured stem and one with infection. Acetabular grafting with autogenous morsellised ipsilateral iliac bone graft was used for two patients with acetabular erosion with use of cemented cups. Cemented prostheses were used in 34 patients, cementless in 8 patients and hybrid in 5 patients.

RESULTS

Harris hip scores improved in all categories. The overall Harris score improved from a mean of 40.5 preoperatively to a mean of 88.5 at one year follow-up and to 86.0 points at the last follow-up. Pain scores showed marked improvement: at the last follow-up, we had 21 patients with no hip pain and 17 patients with slight pain. Also, at the last follow-up we had 16 patients walking unaided and 17 patients who could walk freely. Range of motion improved significantly and was essentially normal in all but nine patients.

Harris hip scores were affected by the indication for conversion arthroplasty (table II).

At one year follow-up we had 62% excellent results and 32% good results, which changed to 19.1% excellent results, 74.5% good results, 4.3% fair results and 2.1% poor result at the end of follow-up (table III).

The mean leg length discrepancy was 12 mm (range from –25 mm to 20 mm).

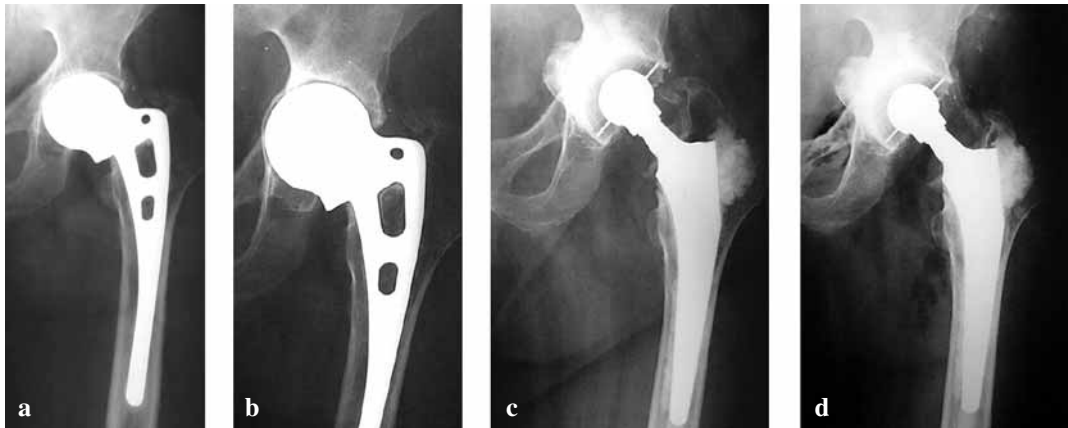


Fig. 1. — (a) Postoperative radiograph with good acetabular floor.
 (b) Pre operative radiograph with acetabular erosion 40 months following initial surgery.
 (c) Post conversion radiograph with use of mesh and autograft.
 (d) 30 months postoperative with Harris hip score of 90 points.

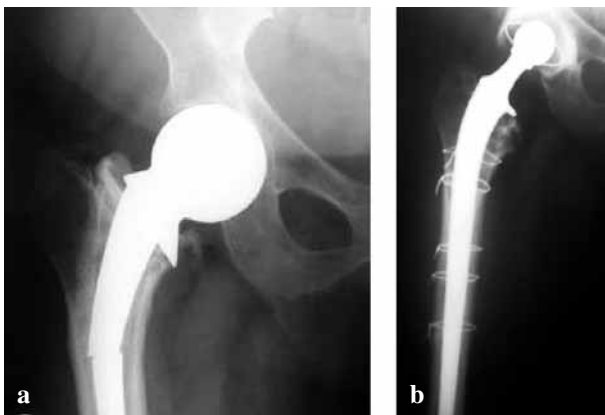


Fig. 2. — (a) 67-year-old female with fractured stem and acetabular erosion ; (b) 32 months following conversion to hybrid arthroplasty through a transfemoral approach.

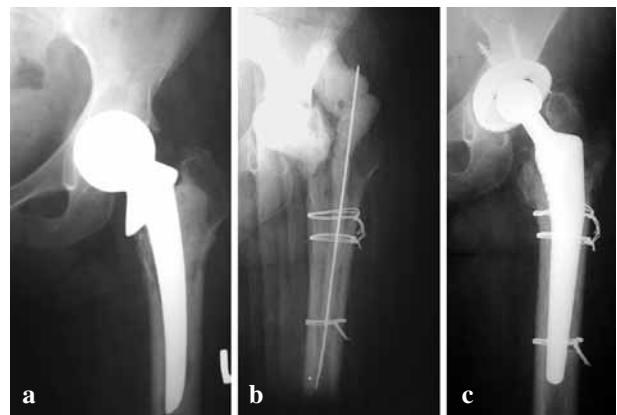


Fig. 3. — (a) 62-year-old female with infected Thompson prosthesis ; (b) 1st stage revision through a transfemoral approach with hand made cement spacer ; (c) 40 months follow-up after a second stage conversion to a cementless total hip arthroplasty with no evidence of infection and Harris hip score of 82 points.

Nine complications occurred in 8 patients (17%). One patient had early wound infection which cured completely after debridement, suction-irrigation and 6 weeks of intravenous antibiotics. Two patients had incomplete sciatic nerve lesion which recovered completely in one patient and improved in the other at one year follow-up. Six patients had persistent groin pain (table IV). We had no loosening at the last follow-up. Also, neither instability nor mortality was reported.

DISCUSSION

The goal of treatment of displaced femoral neck fractures is to return the patients to their pre-injury functional state as rapidly as possible and to minimise the need for further operation (6). Austin Moore and Thompson hemiarthroplasty have fulfilled these criteria for decades (7, 16). With increasing demands being placed on the prosthesis by fitter and more physically demanding patients, a

Table II. — Harris Hip Score in relation to indication

Indications	Preoperative	One-year	Last follow-up
Acetabular erosion (N = 18)	49.6 (± 5.5)	90.9 (± 2.0)	88.1 (± 1.6)
Femoral loosening (N = 11)	41.2 (± 11.8)	90.0 (± 2.8)	86.5 (± 2.2)
Dislocation (N = 8)	26.3 (± 13.4)	87.8 (± 4.6)	86.5 (± 3.2)
Femoral fracture (N = 4)	23.3 (± 13.4)	82.5 (± 3.4)	83.0 (± 2.6)
Infection (N = 3)	44.0 (± 7.5)	76.7 (± 10.3)	72.7 (± 8.3)
Stem fracture (N = 3)	45.6 (± 8.5)	92.0 (± 0.0)	88.0 (± 0.0)

Table III. — Functional results after conversion arthroplasty

Functional result	One year follow-up No (%)	Last follow-up No (%)
Excellent	29 (61.7)	9 (19.1)
Good	15 (31.9)	35 (74.5)
Fair	2 (4.3)	2 (4.3)
Poor	1 (2.1)	1 (2.1)

Table IV. — Complications in relation to the indications for conversion arthroplasty

Indication	Wound infection	Groin pain	Neural deficit	Total
Acetabular Erosion	0	4	0	4
Loosening	0	0	0	0
Dislocation	0	2	1	3
Femoral fracture	0	0	0	0
Infection	1	0	1	2
Stem fracture	0	0	0	0
Total	1	6	2	9

group of these patients would develop early onset groin and thigh pain leading to a marked decrease in their quality of life (23).

When hemiarthroplasty is used in mobile independent patients, it frequently requires conversion to total hip replacement, the result of which is reportedly inferior to a primary procedure. Those whose hemiarthroplasties are not converted often suffer chronic hip pain with reduced mobility (23). Pain following hemiarthroplasty is usually due to one of two pathological processes: articular cartilage degeneration in the acetabulum or loosening of the prosthesis. These pathological processes are

exacerbated by many factors including incongruence between the femoral head and the acetabulum, excessive neck length, impaction at the time of injury, cementation of the prosthesis, physiologically young active patients and shear forces between the prosthesis and the cartilage (2, 7, 14). Cossey and Goodwin (4) concluded that conversion to total hip replacement would give satisfactory results.

The reported intra- and postoperative complications of conversion arthroplasty were high and this reflects the difficulties of this surgery in elderly patients (1, 20, 22). Amstutz and Smith (1) reported results of 41 patients with conversion arthroplasty; they had 5 intraoperative proximal femoral fractures, 2 perforations of the medial cortex with stem protrusion, 2 cases with instability, 2 cases with infection, 3 patients with deep venous thrombosis and 6 patients with progressive loosening. Three patients had required revision by the end of follow-up (mean of 36 months). Llinas *et al* (17) had a larger study with longer follow-up (mean of 87 months) and they had a 6% revision rate which is comparable to the 5% revision rate for primary total hip in a similar period. Cossey and Goodwin (4) reported 46 patients who had conversion arthroplasty; they had no loosening, no dislocation, two patients with superficial infection and three patients were dead at the time of study

We had no loosening in our study and this is different from the 14.6% progressive loosening reported by Amstutz and Smith (1) and this may be due to the cementing technique used and improved stem design. Llinas *et al* (17) concluded that conversion arthroplasty had a higher rate of early loosening of the femoral component than after a primary total hip replacement and this statement was

supported by the results of Amstutz and Smith (1). This failure on the femoral side may be due to extensive resorption of the endosteal bone while the stem of the hemiarthroplasty was loose, or to damage of the endosteal bone during revision (18). Furthermore toggling of the stem may produce a thick fibrous membrane that is adherent and might not be completely removed at revision, with its remnants compromising the subsequent cemented fixation (1). Also, it had been suggested that fragments of such a fibrous membrane are metabolically very active, producing Prostaglandin E₂, collagenase and Interleukin1 β , all of which may contribute to resorption of adjacent bone (8, 9, 10). On the other hand the articulation of the metallic head with the acetabular articular cartilage produces subchondral sclerosis primarily in zone 1 by about one year and this provides better support for a cemented cup than can a virgin acetabulum (17). We may attribute our results to the short period of follow-up and a further evaluation of this group may be needed in the future.

The incidence of instability following conversion arthroplasty varies from 9% as reported by Squires and Bannister (23) to 50% as reported by Champion and McNally (3), whereas Cossey and Goodwin (4) had no instability in their series.

We had no mortality in our study and this is similar to Sipila *et al* (21) who stated that conversion arthroplasty did not appear to increase mortality. However, Palmer *et al* (19) reported 25% mortality at one year compared with 11% mortality in patients who retained their hemiarthroplasty. Even a higher one-year mortality rate after conversion arthroplasty of 36% was also reported by Keating *et al* (15).

We had 93% of our patients with either excellent or good results at the last follow-up (mean 44 months) and this results is far superior to the 70% of Squires and Bannister (23) and this may be attributed to the more sedentary life in Egyptian population compared to a Western population in this age group.

We noticed that the functional results in the majority of patients in the mid-fifties-mid-sixties age group had changed from excellent to good by the end of follow-up. This reduction was mainly in

their score for support, walking distance and limp. Patients older than 70 years keep their results unchanged and this may be also attributed to the level of their physical activities either in their work or social life.

Looking carefully through Harris Hip Scores, conversion arthroplasty seems to be a very effective way to eliminate pain. Also the patients' level of activity and mobility had been improved but not to a large extent, and a similar observation was reported by many authors (15, 19, 21, 23).

We can conclude that conversion arthroplasty is an excellent treatment strategy for symptomatic failed hemiarthroplasty in terms of pain relief and restoration of function and mobility as near as possible to the pre-injury level. Also, hemiarthroplasty should not be used in physically active patients, even in elderly individuals.

REFERENCES

1. **Amstutz R, Smith R.** Total hip replacement following failed femoral hemiarthroplasty. *J Bone Joint Surg* 1979 ; 61-A : 1161-1166.
2. **Andersson G, Müller-Nilsen J.** Results after arthroplasty of the hip with Moore prosthesis. *Acta Orthop Scand* 1972 ; 43 : 39-44.
3. **Champion M, McNeally S.** Dislocation after revision of hemiarthroplasty to total hip replacement. *Injury* 2004 ; 35, 161-164.
4. **Cossey A, Goodwin M.** Failure of Austin Moore hemiarthroplasty : total hip replacement as a treatment strategy. *Injury* 2002 ; 33 : 19-21.
5. **DeLee G, Charnley J.** Radiological demarcation of cemented sockets in total hip replacement. *Clin Orthop* 1976 ; 121 : 20-32.
6. **Dorr L, Glousman R, Hoy A et al.** Treatment of femoral neck fracture with total hip replacement versus cemented and non-cemented hemiarthroplasty. *J Arthroplasty* 1986 ; 1 : 21-28.
7. **Gingras M, Clarke J, Evarts CM.** Prosthesis replacement in femoral neck fracture. *Clin Orthop* 1980 ; 152 : 147-152.
8. **Goldring S, Schiller A, Roelke M et al.** The synovial-like membrane at the bone-cement interface in loose total hip replacement and its proposed role in bone lysis. *J Bone Joint Surg* 1983 ; 65-A : 575-584.
9. **Goodman S, Fornasier V, Kei J.** The effects of bulk versus particulate ultra-high molecular weight polyethylene on bone. *J Arthroplasty* 1988 ; 3 : S 41-46 (suppl).
10. **Gown M, Wood D, Ihrie E, McGuire M et al.** An interleukin 1 like factor stimulates bone resorption in vitro. *Nature* 1983 ; 306 : 378-380.

11. **Gruen T, McNeice G, Amstutz H.** "Modes of failure" of cemented stem-type femoral components : a radiographic analysis of loosening. *Clin Orthop* 1979 ; 141 : 17-27.
12. **Harris W.** Traumatic arthritis of the hip after dislocation and acetabular fracture : treatment by mold arthroplasty. *J Bone Joint Surg* 1969 ; 51-A : 737-755.
13. **Hofmann A, Wyatt R, France E et al.** Endosteal bone loss after total hip arthroplasty. *Clin Orthop* 1989 ; 245 : 138-144.
14. **Kaltsas D, Klugman.** Acetabular erosion : A comparison between the Austin Moore and Monk hard top prosthesis. *Injury* 1986 ; 17 : 230-236.
15. **Keating J, Robinson C, Court Brown C, Mc Queen M, Christy J.** The effect of complications after hip fractures on rehabilitation. *J Bone Joint Surg* 1993 ; 75- B : 976-982.
16. **Kofoed H, Kofoed J.** Moore prosthesis in the treatment of fresh femoral neck fracture. Critical review with special attention to secondary acetabular degeneration. *Injury* 1983 ; 14 : 531-540.
17. **Llinas A, Sarmiento A, Ebramzadeh E, Gogan W, Mc Kellop H.** Total hip replacement after failed hemiarthroplasty or mould arthroplasty. Comparison of results with those of primary replacement. *J Bone Joint Surg* 1991 ; 73-B : 902-907.
18. **Olsson S.** Loosening and femoral neck resorption 5 years after CAD hip replacement. *Acta Orthop Scand* 1987 ; 58 : 491-493.
19. **Palmer S, Parker M, Hollingworth H.** The cost and implications of reoperation after surgery for fractures of the hip. *J Bone Joint Surg* 2000 ; 82-B : 864-866.
20. **Phillips T.** Thompson hemiarthroplasty and acetabular erosion. *J Bone Joint Surg* 1989 ; 71-A : 913-917.
21. **Sipilä J, Hyvönen P, Partanen J, Ristiniemi J, Jalovaara P.** Early revision after hemiarthroplasty and osteosynthesis of cervical hip fracture at the hip. *Acta Orthop Scand* 2004 ; 75 : 402-407.
22. **Soriede O, Lillestol J, Alho A, Hvidsten K.** Acetabular protrusion following endoprosthetic hip surgery : A multi-factorial study. *Acta Orthop Scand* 1980 ; 51 : 943-948.
23. **Squires B, Bannister G.** Displaced intracapsular neck of femur fracture in mobile independent patients : Total hip replacement or hemiarthroplasty. *Injury* 1999 ; 30 : 345-348.
24. **Warwick D, Hubble M, Sarris I, Strange J.** Revision of failed hemiarthroplasty for fractures at the hip *Int Orthop* 1998 ; 22 : 165-168.