

OSSEOUS OVERGROWTH IN CONGENITAL AMPUTATIONS OF THE UPPER LIMB : REPORT OF 3 CASES TREATED WITH AUTOLOGOUS STUMP PLASTY

F. MICHELS, L. DE SMET

Osseous overgrowth is an important problem after traumatic or surgical amputations in children. It is rather exceptional in congenital amputations. We report three cases of congenital amputation of the humerus with osseous overgrowth. They were treated with an autologous stump plasty according to Marquardt's technique.

Keywords : congenital amputation ; stump plasty.

Mots-clés : amputation congénitale ; plastie du moignon.

INTRODUCTION

Osseous overgrowth is a complication seen after surgical or traumatic amputations in children. This phenomenon occurs when in an amputation stump the bone grows faster than the surrounding soft tissues. This growing bone may lead to irritation of the soft tissues, pain, intolerance to the prosthesis and perforation of the soft tissues. Osteitis may even occur. Surgical treatment is recommended. An ordinary transection of the bone stimulates further outgrowth of the bone with recurrence of the problems. Covering the stump after resection of the overgrowth with an iliac bone graft with a growth plate should reduce the risk of recurrence. Osseous overgrowth is rarely seen in congenital amputations (transverse agenesis). We report three cases of transverse agenesis of the humerus with osseous overgrowth. In all cases we resected the overgrowth and covered the stump with an autologous iliac graft.

CASE HISTORIES

Case 1

A 4-year-old girl with congenital agenesis of the upper arm was seen in the outpatient clinic with overgrowth of the humerus and perforation of the soft tissues. Several months before, the arm stump had become tender and distally irritated. On physical examination bone overgrowth with skin perforation was obvious (fig. 1a). There was a small dimple on the posterolateral side. There were no other abnormalities. A Marquardt procedure (4, 6) was performed. A transverse incision was made over the overgrowth, and the surrounding irritated skin was resected. The osseous overgrowth was sharply resected with an oscillating saw. A triangular-shaped iliac graft was harvested including the overlying growth plate. This graft was fixed to the resected humerus with the growth plate oriented distally. It was fixed with one K-wire. The wound was closed over a suction drain. A compressive dressing was applied.

Postoperative follow-up was uneventful. One year later the K-wire was still in place, and there

Department of Orthopedic Surgery, U.Z. Pellenberg ;
Katholic University Leuven, Weligerveld 1, 3212 Lubbeek,
(Pellenberg), Belgium.

Correspondence and reprints : L. De Smet, Department
of Orthopedic Surgery, U.Z. Pellenberg, Weligerveld 1, B-
3212 Lubbeek (Pellenberg), Belgium.

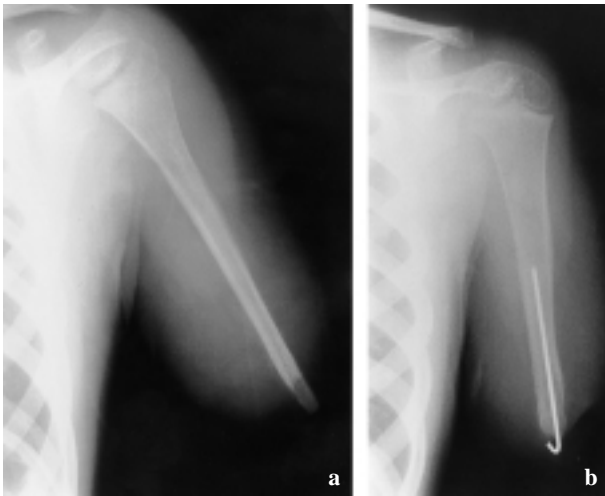


Fig. 1. — Case 1: preoperatively (a) and after one year (b)

were no signs of osseous overgrowth. Rehabilitation with the prostheses continued.

Case 2

A boy of 4 years was seen with transverse agenesis of the left humerus, absence of the distal phalanges of the toes and partial cutaneous syndactyly of the contralateral hand. These deformities probably resulted from very severe malaria of the mother which occurred during the 8th to 11th week of pregnancy.

Physical examination demonstrated a dimple and osseous overgrowth of the humerus stump. The stump was very tender. Radiological examination confirmed the overgrowth (fig. 2a). A Marquardt procedure was performed (fig. 2b). Follow-up at one year demonstrated slight overgrowth but without physical or radiological signs of irritation.

Case 3

This female patient was seen at the age of 4 years. She was born with agenesis of the left upper arm at the middiaphyseal level. There was also asymmetry of the face and a torticollis. She had worn an upper arm prosthesis since the age of three. She was seen with perforation of the skin (fig. 3a). Considering her age the bony overgrowth

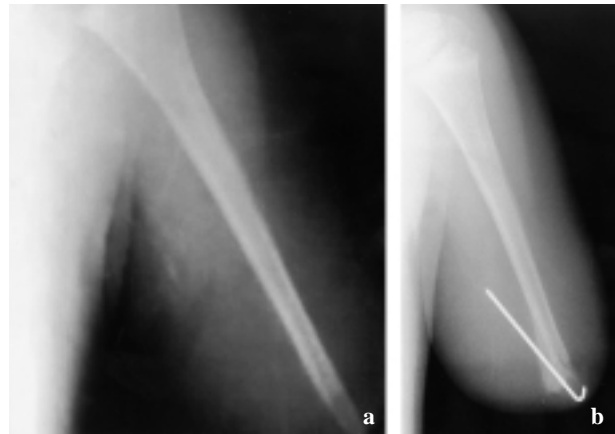


Fig. 2. — Case 2: preoperative (a) and postoperative (b) aspect of the humerus.

was simply resected. She was seen again at the age of seven with local irritation of the distal stump and obvious signs of osseous overgrowth (fig. 3b). We performed a Marquardt procedure (fig. 3c). At follow-up after 4 years she was pain-free and xrays demonstrated slight overgrowth. There were no further problems with the prosthesis. The skin condition was normal.

DISCUSSION

Amputations in children are treated differently than in adults. Skeletal and soft tissues are in a growing phase and have more physiological tolerance (2). Complications are less in children than in adults. Neuromas, scar problems and phantom pain are practically inexistent. The most important complication however is osseous overgrowth. The exact mechanism of osseous overgrowth is still unknown. Aitken (2) demonstrated that distal overgrowth was associated with an osteogenic periosteum. Speer (8) investigated the histological mechanism of osseous overgrowth and concluded that it occurred as a consequence of a local healing mechanism with wound contraction and periosteal and endosteal bone growth. Several factors are important in the occurrence of osseous overgrowth. The age is of major importance: osseous overgrowth is practically not seen in children older than 12 years.

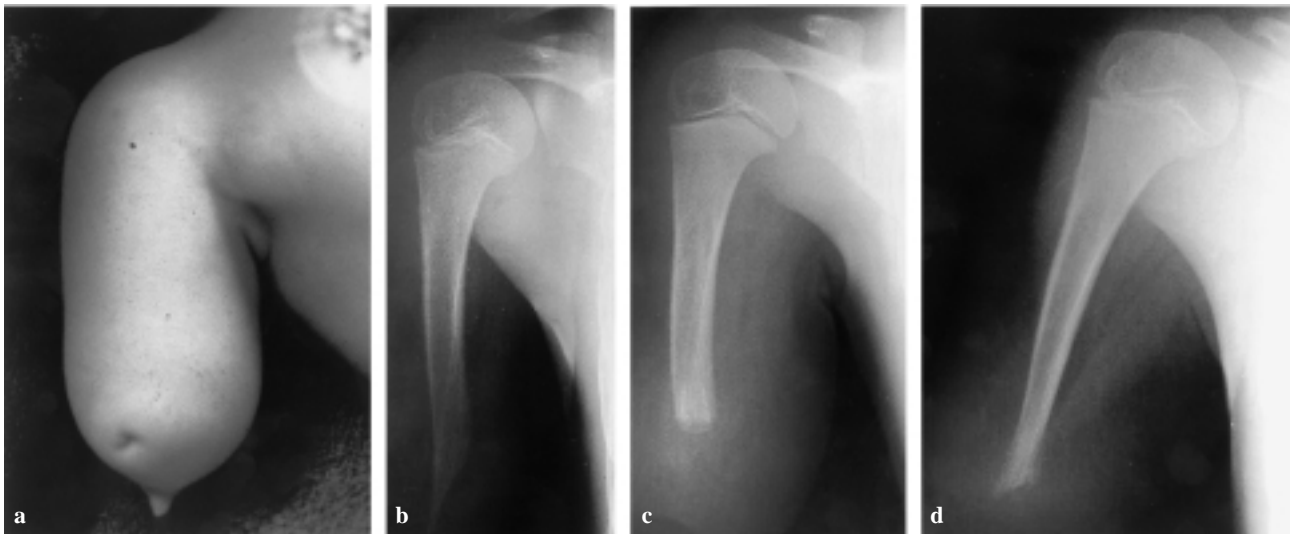


Fig. 3. — Clinical aspect of the overgrowth (a), radiographical aspect preoperatively (b) and postoperatively after 18 months (c) and four years (d).

The most frequent locations are the humerus, the fibula and the tibia (2). Surgical interventions on the amputation stump stimulate osseous overgrowth. In congenital amputations (transverse agenesis) surgical procedures are sometimes necessary to make a prosthesis functioning (1). This was not the case in any of these patients. Traumatic or surgical amputation at the metaphyseal level provokes osseous overgrowth more frequently than amputation at the diaphyseal level. In disarticulations osseous overgrowth does not occur. In congenital agenesis osseous overgrowth is very rare (7). In fact this is not a real amputation but an agenesis, except for congenital constriction bands (amniotic bride syndrome) where we can see a real “amputation” (deleting a previously existing limb). In these congenital band syndromes osseous overgrowth has been seen on a regular basis. In the patients reported here, the absence of other localizations of amniotic brides and the presence of a dimple indicate that it is not an amniotic bride syndrome but a real transverse agenesis. A preliminary report of one patient (case 3) has been published previously (5). Several procedures have been proposed to treat osseous overgrowth : distal resection, proximal epiphysiodesis, coverage of the stump with silicones, metals or polyethylene and skin traction (2). More evidence appeared from using the reversed iliac

bone graft with the physis (autologous stump plasty) technique as described by Marquardt (3, 4, 5, 6). A triangular shaped iliac bone graft with growth

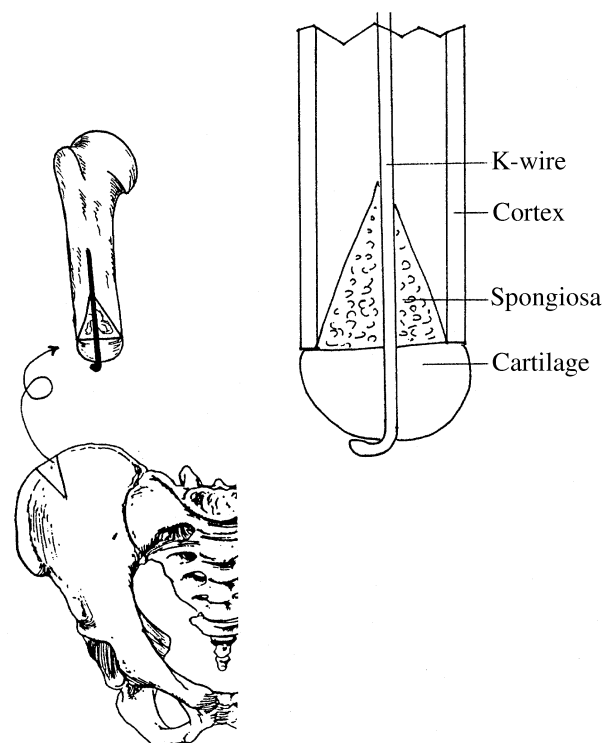


Fig. 4. — Schematic representation of the autologous stump plasty procedure described by Marquardt.

plate is harvested and fixed to the amputation stump. The rationale for the technique was based on the fact that osseous overgrowth does not occur following a disarticulation (fig. 4). Some authors have proposed performing this procedure primarily (3, 4). In traumatic and surgical amputations this is certainly a good option. In congenital amputations one can apply this technique at the time of a procedure to alter the amputation stump in order to fit a prosthesis.

REFERENCES

1. Abraham E., Pellicore R., Hamilton R., Hallman B., Ghosh L. Stump overgrowth in a juvenile amputee. *J. Pediatr. Orthop.*, 1986, 6, 66-71.
2. Aitken G. Surgical amputation in children. *J. Bone Joint Surg.*, 1963, 45-A, 1735-1741.
3. Benevenia J., Makeley J., Leeson M., Benevenia K. Primary epiphyseal transplants and bone overgrowth in childhood amputations. *J. Pediatr. Orthop.*, 1992, 12, 746-750.
4. Bernd L., Bläsius K., Lukoschek M., Lücke R. The autologous stump plasty. *J. Bone Joint Surg.*, 1991, 73-B, 203-206.
5. De Smet L., Fabry G. Amputation stump overgrowth in a congenital above-elbow agenesis. *J. Pediatr. Orthop.*, 1999, 19-B, 54-55.
6. Marquardt E., Corell J. Amputationen. *Z. Orthop. Ihre Grenzgeb.*, 1986, 124, 422-425.
7. O'Neal M., Bahner R., Geney T., Ogden J. Osseous overgrowth after amputation in adolescents and children. *J. Pediatr. Orthop.*, 1996, 16-A, 78-84.
8. Speer D. The pathogenesis of amputation stump overgrowth. *Clin. Orthop.*, 1981, 159, 294-307.

SAMENVATTING

F. MICHELS, L. DE SMET. Osseuse overgroei na congenitale amputaties van het bovenste lidmaat.

Osseuse overgroei is een belangrijk probleem na traumatische of chirurgische amputaties bij kinderen. Osseuse overgroei is zeldzaam na congenitale amputaties. We beschrijven drie gevallen van congenitale amputaties van de humerus met osseuse overgroei. Ze werden behandeld met een autologe stomplastiek volgens Marquardt.

RÉSUMÉ

F. MICHELS, L. DE SMET. Croissance osseuse excessive, sur amputation congénitale du membre supérieur : présentation de trois cas traités par plastie du moignon avec une greffe iliaque autologue.

Après amputation traumatique ou chirurgicale chez l'enfant, les problèmes liés à une croissance osseuse excessive sont classiques. Ils sont plutôt exceptionnels dans les amputations congénitales. Les auteurs présentent trois cas d'amputation congénitale de l'humérus qui ont présenté une croissance osseuse excessive. Ils ont été traités par la technique de Marquardt avec mise en place d'un greffon iliaque inversé, comportant le cartilage de croissance.