

THE BONE BLOCK PROCEDURE IN RECURRENT POSTERIOR SHOULDER INSTABILITY

T. GOSENS¹, F. C. van BIEZEN², J. A. N. VERHAAR²

We analyzed the results of eleven shoulders in ten patients who had a bone block procedure for recurrent posterior shoulder instability after extensive conservative treatment had failed. Five patients had posterior instability with additional laxity in another direction (UPI+), and five patients had unidirectional posterior instability without additional laxity (UPI-). After a median follow-up of 72 (43-102) months there was no recurrent posterior instability in the UPI- group (100% success), but the recurrence rate in the UPI+ group was high (20% success). We concluded from these results that a bone block procedure is not sufficient to treat recurrent posterior shoulder instability in unidirectional posterior instability with additional laxity but it seems to be a good method to treat unidirectional posterior instability without additional laxity.

Keywords : posterior shoulder instability ; bone block.
Mots-clés : instabilité postérieure de l'épaule ; butée osseuse.

INTRODUCTION

Recurrent posterior shoulder instability (RPSI) occurs either spontaneously or after significant trauma and may be combined with anterior and/or inferior laxity (when asymptomatic) or instability (when symptomatic): multidirectional laxity or instability. Several surgical methods have been described, some of them with good results such as glenoid osteotomy (2) or posterior capsular shift (6, 15), others with disappointing results such as reversed Putti-Platt, posterior capsulorrhaphy (7, 10) and glenoid osteotomy (10). Most of the surgical techniques were described in small series because

of the rarity of the problem. The largest published series about the bone block procedure included only five patients (4). We studied the results of the bone block procedure in ten patients.

PATIENTS AND METHODS

Between 1985 and 1995 we operated on 11 patients (12 shoulders) with painful recurrent posterior instability. There were five women and six men, of which one man (one shoulder) was lost to follow-up with a satisfying result after one year of follow-up. One patient had a second bone block after a period of seven years of excellent result. At the time of operation the average age was 25.8 (16 -57) years. Five right and six left shoulders were involved, with the same distribution between the dominant and the nondominant extremity. In two patients there was a traumatic event that preceded the instability ; in all others there was no such event. No patients had epileptic insults and none had Marfan or Ehlers-Danlos disease.

We included five patients with unidirectional instability without additional laxity (UPI-) and three patients with posterior instability combined with inferior laxity (UPI+). Two patients had multidirectional instability (MDI), as their shoulder had been dislocated both posteriorly and anteriorly. In all patients conservative treatment, i.e. strengthening of the posterior shoulder

¹ Department of Orthopaedic Surgery and Traumatology, Atrium Medical Center Heerlen, the Netherlands.

² Department of Orthopaedic Surgery, University Hospital Rotterdam, the Netherlands.

Correspondence and reprints : T. Gosens, Atrium Medical Center Heerlen, PO box 4446, 6401 CX Heerlen, the Netherlands.

muscles, for an average of one year had failed, and three patients (all with UPI+) had been operated before in other hospitals (one patient underwent a reversed Putti-Platt, one patient underwent a reversed Putti-Platt twice and one patient underwent a reversed Putti-Platt followed by a glenoid osteotomy). Patient characteristics are summarized in table I.

After a follow-up of 72 (43 -102) months, 10 patients (11 shoulders) were evaluated for pain, functional (dis)abilities, range of motion and stability of the operated shoulder. At follow-up xrays of the operated shoulder were taken in all patients. We used the Rowe score adjusted for instability to evaluate the success of the operation (16).

Table I. — Summary of patient characteristics

| | A | B | C | D | E | F |
|----|---|----|---|---|-----|---|
| 1 | F | 33 | R | + | 49 | 1 |
| 2 | M | 25 | L | + | 99 | 0 |
| 3 | F | 20 | L | + | 43 | 2 |
| 4 | M | 57 | R | - | 102 | 0 |
| 5 | F | 16 | L | + | 46 | 0 |
| 6 | M | 22 | L | - | 84 | 0 |
| 6a | M | 29 | L | - | 57 | 0 |
| 7 | M | 33 | R | - | 67 | 0 |
| 8 | F | 17 | L | - | 100 | 0 |
| 9 | M | 18 | R | - | 101 | 0 |
| 10 | F | 17 | R | + | 101 | 1 |

A – sex (m or f)

B – age (years)

C – affected side (left or right)

D – unidirectional posterior instability with additional laxity or instability (+) or without (-)

E – follow-up (months)

F – number of previous operations

OPERATIVE TECHNIQUE

After the stability was assessed under general anesthesia, the patient was placed in a prone position with the shoulder in abduction on a supporting device. An incision was made over the spine of the scapula, and the deltoid muscle was detached from it. The interval between the infraspinatus and teres minor muscles was enlarged. The infraspinatus tendon was retracted near the humeral head (not too far medially to preserve the suprascapular nerve).

The joint capsule was opened to inspect the joint cavity. The posterocaudal part of the scapular neck was roughened to create a bed for the bone block. A tricortical bone block, about 3 cm. in length, was harvested from the posterior part of the iliac crest and was fixed with 2 AO-screws at the posterocaudal glenoid rim. We positioned the bone block in such a way that it did not protrude laterally to the posterior labrum (figure 1A and 1B).

The deltoid muscle was reinserted. After operation a Velpau plaster cast was applied for eight weeks. After eight weeks shoulder exercises were started and after six to nine months sports could be resumed.

RESULTS

After a follow-up of 72 (43-102) months 10 patients (11 shoulders) were evaluated for pain, functional (dis)abilities, range of motion and stability of the operated shoulder. Results are summarized in table II.

Pain was decreased in seven patients and increased in two (both UPI+ and one of them a voluntary dislocator) and remained unchanged in one patient.

All patients returned to their work and seven patients could resume their sports at the same level. Two patients (no. 5 and no. 10) were unable to participate in sports, and one patient (no. 4) stopped his sports but not because of his shoulder.

Two patients (no. 5 and no. 10) had an arthrodesis at the time of analysis of the range of motion. Of the remaining eight patients four had symmetric range of motion and four had a deficit in external rotation. Two patients also had a deficit in abduction and elevation and two also had a deficit in internal rotation.

The posterior drawer sign was positive in one patient (no. 2) ; he was satisfied with the result. In three patients (no. 1, no. 2, no. 3) there was a positive sulcus sign on the operated shoulder. Inferior or anterior laxity of the contralateral shoulder was found in five patients (no. 1, no. 2, no. 3, no. 5, no. 10).

One patient (no. 5) had an arthrodesis for recurrent posterior instability. This was also performed

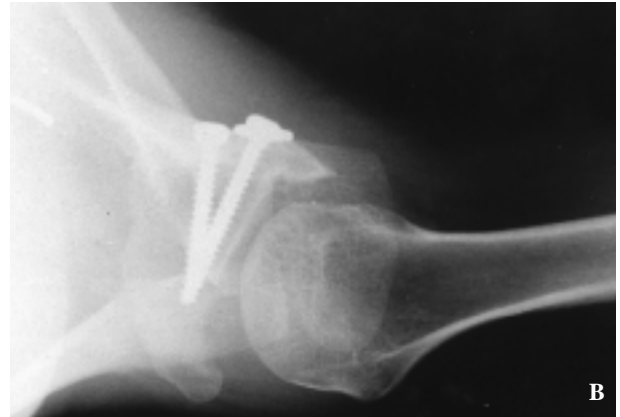
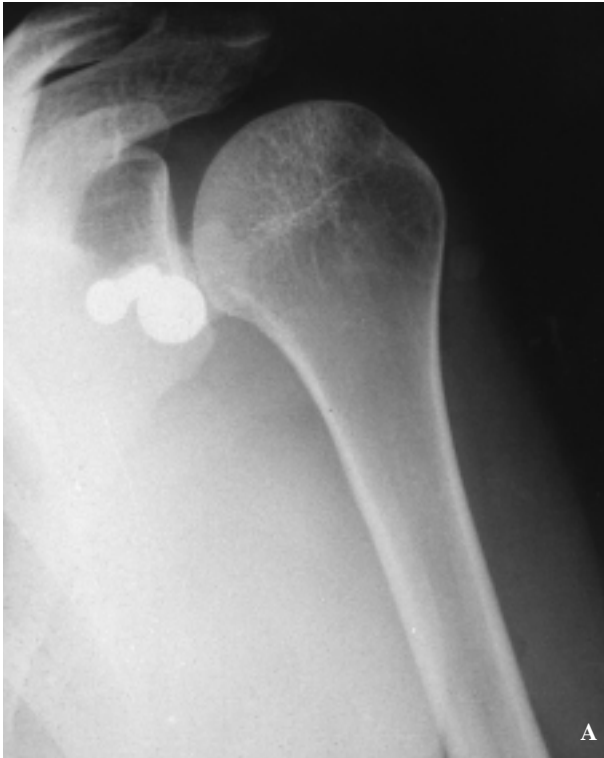

Fig. 1A-1B. — Radiological image of a posterior bone block in a 19-year old female with recurrent posterior shoulder instability (case 8).

Table II. — Results

| | A | B | C | D | E | F | G | H | I | J | K | L |
|----|---|-----|-----|-----|----|----|----|-----|---|---|---|----------------------------|
| 1 | + | 9.5 | 8 | 49 | 50 | 5 | 10 | 65 | F | N | N | |
| 2 | + | 8 | 3 | 99 | 50 | 5 | 30 | 85 | G | N | N | |
| 3 | + | 6 | 8 | 43 | 30 | 15 | 10 | 55 | F | N | N | voluntary dislocator |
| 4 | - | 5 | 1 | 102 | 50 | 5 | 25 | 80 | G | N | N | glenoid luxation fracture |
| 5 | + | 9 | 10 | 46 | N | N | N | N | P | T | Y | arthrodesis |
| 6 | - | 7 | 2 | 84 | 50 | 20 | 25 | 95 | E | P | Y | screw removal |
| 6a | - | 5 | 2 | 57 | 50 | 20 | 25 | 95 | E | N | N | second bone block |
| 7 | - | 7 | 0 | 67 | 50 | 20 | 30 | 100 | E | P | N | |
| 8 | - | 6 | 2 | 100 | 50 | 20 | 30 | 100 | E | N | N | |
| 9 | - | 0 | 0 | 101 | 50 | 20 | 30 | 100 | E | N | Y | screw removal |
| 10 | + | 10 | 5.5 | 101 | N | N | N | N | P | N | Y | screw removal, arthrodesis |

A – unidirectional posterior instability with additional laxity or instability (+) or without (-)

B – VAS for pain before surgery (0-10)

C – VAS for pain at follow-up (0-10)

D – follow-up (months)

E – stability (0-50)

F – range of motion (0-20)

G – function (0-30)

H – total Rowe score (0-100)

I – result (poor, fair, good or excellent)

J – resorption of the bone block (total, partial or none)

K – reoperation (yes or no)

L – remarks

in one patient (no. 10) with recurrent anterior instability with signs of glenohumeral osteoarthritis. After a skiing accident one patient (no. 6) who had had no complaints in the seven years before had a second bone block procedure because of recurrent instability. Removal of a screw was necessary in three patients (no. 6, no. 9, no. 10).

The only complication was in a patient who had a superficial wound infection that was cured by antibiotic therapy, but without the need for a reoperation. No nerve palsies were noted.

On xray nine of the twelve bone blocks were without signs of resorption. One bone block (no. 5) showed total resorption with recurrent posterior instability. One bone block (no. 7) was partially resorbed without recurrent posterior instability and one bone block (no. 6) was partially resorbed with recurrent posterior instability. One patient (no. 10) developed signs of osteoarthritis after 6 years.

The Rowe score classification was for four cases excellent, two were good, two were fair and two were poor. The success rate (defined as a good or excellent Rowe score) was 60% for the whole group of ten patients. The success rate in the UPI+group was 20% (four failures and one good result) and the success rate in the UPI-group was 100% (no failures, four excellent and one good result).

The two-tailed Fisher exact test showed that the difference in success between the two groups (UPI+ and UPI-) is significant ($p = 0.047$).

DISCUSSION

Several surgical methods to treat posterior shoulder instability after failed conservative therapy have been described, some of them with good results such as glenoid osteotomy (2) or posterior capsular shift (15), others with disappointing results such as reversed Putti-Platt, posterior capsulorrhaphy (7, 10) and glenoid osteotomy (7). Most methods of surgical treatment of recurrent posterior shoulder instability have been described only in small series, except capsular shift (3), and because of these limited numbers it is not easy to draw conclusions from these series regarding success or complication rates. The largest published series with a bone

block procedure included only five patients (4). The patients in our series had a bone block procedure (1, 4, 5, 9, 11, 12, 13, 14). This procedure has been recommended when the underlying pathologic lesion was excessive glenoid retroversion or absence of the posterior glenoid rim, but not when capsular redundancy was the cause of the instability (8). We opted for this technique in our patients because in this category of patients the strength of the capsule may be insufficient to perform a proper capsulorrhaphy or capsular shift. In our opinion the tissue is often so thin and lax that in many cases it will stretch after a period of time, which may explain the inferior results of the soft tissue procedures, although very good results have been reported recently by Fuchs *et al.* even in voluntary dislocators (6). The reason for failure of the bone block procedure in patients with UPI+ is in our opinion the residual inferior instability, which is not corrected by a bone block procedure alone.

CONCLUSION

We consider the positioning of a bone block on the posterocaudal glenoid rim a valuable method in recurrent posterior shoulder instability if conservative treatment has failed, if instability and laxity in other directions than posteriorly is absent and if voluntary dislocation is excluded. When there is also inferior instability the patients should have a posteroinferior capsular shift (15), which can be combined with a bone block if the capsule is too thin and lax to give sufficient stability.

REFERENCES

1. Ahlgren S., Hedlund T., Nistor L. Idiopathic posterior instability of the shoulder joint - Results of operation with posterior bone graft. *Acta Orthop. Scand.*, 1978, 49, 600-603.
2. Bessems J. H. J. M., Vegter J. Glenoplasty for recurrent posterior shoulder instability - Good results in 13 cases followed for 1-16 years. *Acta Orthop. Scand.*, 1995, 66, 535-537.
3. Bigliani L. U., Pollock R. G., Mcilveen S. J., Endrizzi D. P., Flatow E. L. Shift of the posterior aspect of the capsule for recurrent posterior glenohumeral instability. *J. Bone Joint Surg.*, 1995, 77-A, 1011-1020.

4. Fried A. Habitual posterior luxation of the shoulder joint – A report on five operated cases. *Acta Orthop. Scand.*, 1949, 18, 329-345.
5. Fronek J., Warren J. F., Bowen M. Posterior subluxation of the glenohumeral joint. *J. Bone Joint Surg.*, 1989, 71-A, 205-216.
6. Fuchs B., Jost B., Gerber C. Postero-inferior capsular shift for the treatment of recurrent, voluntary posterior subluxation of the shoulder. *J. Bone Joint Surg.*, 2000, 82-A, 16-25.
7. Hawkins R. J., Koppert G., Johnston G. Recurrent posterior instability (subluxation) of the shoulder. *J. Bone Joint Surg.*, 1984, 66-A, 169-174.
8. Heller K. D., Forst J., Cohen B., Forst R. Atraumatic recurrent posterior shoulder subluxation : Review of literature and recommendations for treatment. *Acta Orthop. Belg.*, 1995, 61, 263-270.
9. Hindenach J. C. R. Recurrent posterior dislocation of the shoulder. *J. Bone Joint Surg.*, 1947, 29, 582-586.
10. Hurley J. A., Anderson T. E., Dear W., Andrish J. T., Bergfield J. A., Weiker G. G. Posterior shoulder instability – Surgical versus conservative results with evaluation of glenoid version. *Am. J. Sports Med.*, 1992, 20, 396-400.
11. Jager R. Probleme in der operativen Behandlung der hinteren Schultergelenksluxation. *Orthopäde*, 1978, 7, 203-207.
12. Jones J. Recurrent posterior dislocation of the shoulder. *J. Bone Joint Surg.*, 1958, 40-B, 203-207.
13. Lindholm T. S. Recurrent posterior dislocation of the shoulder. *Acta Chir. Scand.*, 1974, 140, 101-106.
14. Mowery C. A., Garfin S. R., Booth R. E., Rothman R. H. Recurrent posterior dislocation of the shoulder joint – Treatment using a bone block. *J. Bone Joint Surg.*, 1985, 67-A, 777-781.
15. Neer C. S., Foster C. R. Inferior capsular shift for involuntary inferior and multidirectional instability of the shoulder. *J. Bone Joint Surg.*, 1980, 62-A, 897-908.
16. Rowe C. R., Patel D., Southmayd W. W. The Bankart procedure : A long-term end result study. *J. Bone Joint Surg.*, 1978, 60-A, 1-16.

SAMENVATTING

T. GOSENS, F. C. van BIEZEN, J. A. N. VERHAAR. De botblok procedure bij recidiverende posterieure schouderinstabiliteit.

Wij analyseerden de resultaten van 11 schouders van 10 patienten die een bot blok procedure ondergingen vanwege recidiverende posterieure schouderinstabiliteit nadat intensieve conservatieve behandeling had gefaald. Vijf patienten hadden posterieure instabiliteit met lax-

iteit in een andere richting (UPI+) en vijf patienten hadden unidirectionele posterieure instabiliteit zonder additionele laxiteit (UPI-). Na een gemiddelde follow up van 72 (43-102) maanden werd geen instabiliteit waargenomen in de UPI-groep (100% succes) maar daarentegen was het recidiefpercentage in de UPI+ groep hoog (20% succes). Wij concluderen uit deze resultaten dat de bot blok procedure niet een goede methode is om unidirectionele posterieure instabiliteit met additionele laxiteit te verhelpen, maar dat deze procedure bij unidirectionele posterieure instabiliteit zonder additionele laxiteit goede resultaten geeft.

RÉSUMÉ

T. GOSENS, F. C. van BIEZEN, J. A. N. VERHAAR. Traitement de l'instabilité postérieure de l'épaule par butée osseuse.

Les auteurs ont étudié les résultats obtenus au niveau de onze épaules chez dix patients qui avaient subi une butée osseuse postérieure en raison d'une instabilité postérieure chronique après échec d'un traitement conservateur intensif. Cinq patients présentaient une instabilité postérieure avec, en outre, une laxité dans une autre direction, tandis que 5 patients présentaient une instabilité postérieure unidirectionnelle, sans autre laxité associée. Avec un suivi moyen de 72 mois (extrêmes : 43 et 102 mois), les patients du premier groupe n'avaient présenté aucune récurrence d'instabilité postérieure (taux de succès : 100%) tandis que le taux de récurrence était élevé dans le groupe des laxités multidirectionnelles (taux de succès : 20%). De leurs observations, les auteurs concluent que la mise en place d'une butée osseuse est insuffisante pour faire disparaître une instabilité postérieure de l'épaule lorsqu'il s'y ajoute une laxité dans une autre direction, mais elle apparaît comme un traitement correct de l'instabilité postérieure unidirectionnelle sans laxité dans une autre direction.