

# THE USE OF A HOOK-PLATE IN THE MANAGEMENT OF ACROMIOCLAVICULAR INJURIES. REPORT OF TEN CASES

A. A. FARAJ, B. KETZER

**A hook-plate is a clavicular small fragment AO plate with a hook engaging below the acromion. It is primarily used to secure the ligament repair in the treatment of displaced acromioclavicular joint dislocations. We have used the hook-plate in conjunction with a Weaver-Dunn procedure to secure the repair in seven patients. In another three we used this plate to reduce and stabilize distal clavicular fractures. Satisfactory results were obtained in all patients ; the deformity disappeared, full pain-free shoulder movement was regained with no motor weakness, with a mean follow-up of 11 months (6-25 months). Our patients returned early to work and sports activities (mean period of three months). The three clavicular fractures healed. One patient developed a superficial wound infection, which responded to antibiotics and wound dressing. None of our patients required removal of the implant. The hook-plate appears to be a useful device for acromioclavicular trauma.**

**Keywords :** hook-plate ; clavicle ; acromioclavicular joint ; fracture.

**Mots-clés :** plaque à crochet ; clavicule ; fracture ; acromio-claviculaire.

---

## INTRODUCTION

Surgical treatment is indicated for fixation of acromioclavicular joint dislocation and distal clavicular fracture when there is significant displacement. Once the coracoclavicular ligament is torn, the reduction of the distal clavicle is difficult to maintain. Many procedures have been described for fixation, which indicates the lack as yet of a proper technique of fixation (2, 3, 4, 5, 6, 7, 8, 9).

We attempted in the current report to assess the value of the hook-plate in the treatment of acromioclavicular injuries. This AO plate is manufactured by Stratec (Switzerland).

## MATERIAL AND METHODS

Between 1997 and 2000, the hook-plate was used in 10 patients (9 male, one female) with a mean age of 34 years (range 32 to 40 years). Seven of these patients had grade three or above acromioclavicular joint dislocation, and they underwent a Weaver-Dunn procedure combined with hook-plate fixation to protect the repair. The right side was affected in all seven patients. The main indications for surgery were disturbance of shoulder function and cosmetic problems.

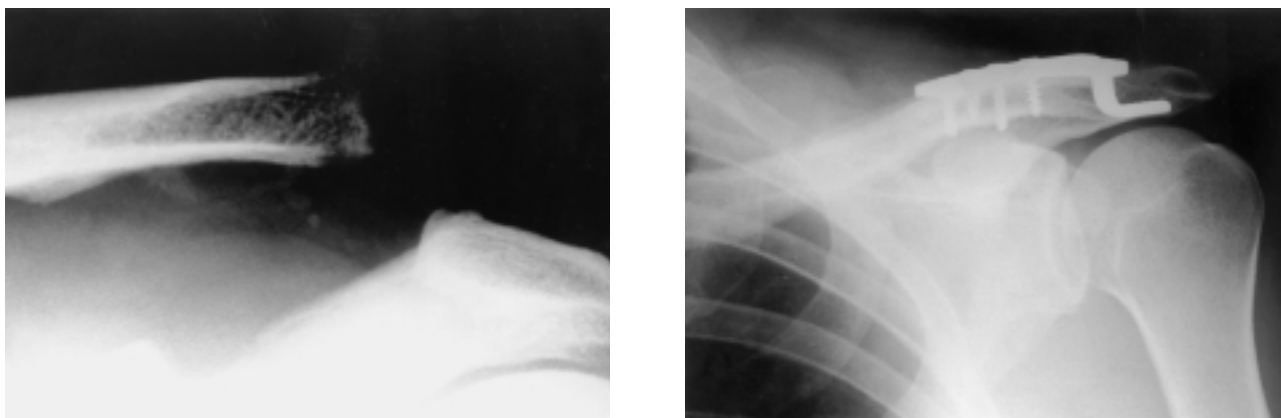
Three patients were operated for lateral clavicular fracture ; the right dominant side was affected in one and the left side in two. Mean age was 37 years (28 to 41 years). The injury followed a fall on the shoulder, and the fracture was displaced but closed.

The operation was carried out through a sabre shoulder incision under general anesthesia. Postoperative active and passive shoulder movement was started as pain allowed ; when at rest, the shoulder was kept in an immobilizer for 4 to 8 weeks after surgery. One patient with a lateral clavicular fracture required an autogenous iliac bone graft.

---

Orthopedic Department, Pinderfields General Hospital, Wakefield, UK.

Correspondence and reprints : A. A. Faraj, 28 Colston Close, Crow Tree Lane, Bradford BD8 0BN, U.K. E-mail : adnanfaraj@hotmail.com.uk.



**Fig. 1.** — Preoperative xray of the left shoulder showing the acromioclavicular joint dislocation and 6 months following a Weaver-Dunn fixation combined with acromioclavicular hook-plate fixation.

## RESULTS

The objective assessment involved the range of shoulder movement and the motor power of the muscles around the shoulder using the following grading system (1) :

- 0 total paralysis
- 1 barely detectable contracture
- 2 not enough power to act against gravity
- 3 strong enough to act against gravity
- 4 still stronger but less than normal
- 5 full power

The subjective assessment included patient's satisfaction, the presence and absence of shoulder pain, and the cosmetic appearance of the shoulder.

A satisfactory result means that the patient is satisfied with the operation, has no shoulder pain and has full range of shoulder movement with grade 5 motor power of the shoulder muscles and has no complications related to surgery.

At a mean follow-up of 11 months (6 to 25 months), all these patients were reporting a satisfactory result. These patients were back to work on average 3 months (2 to 6 months) following surgery. Six months following surgery, all patients resumed sports activities they used to play prior to their injury (football, volleyball).

At a mean follow-up of 3 months (range : 2-4 months) the clavicular fractures were documented to have healed.

## COMPLICATION

One patient developed a superficial wound infection (*E. coli*), which responded to wound debridement and appropriate oral antibiotic administration. We have had no cases of impingement syndrome ; we therefore feel the routine removal of this plate is not necessary.

## DISCUSSION

There are many methods for the fixation of displaced lateral clavicle fractures (Neer type II), and acromioclavicular dislocations ; there are some concerns using any of the implants available.

The concern using Kirschner (K)-wire fixation across the acromioclavicular joint (with or without tension band wiring) is the migration of the wire(s) (5). A Bosworth screw (transclavicular coracoid fixation) may break when the shoulder is mobilized early ; the screw has to be removed.

The hook-plate is a relatively new implant that has been in the market only for few years. The one we used is an AO plate. There is a right-or left-sided plate, the design is such that the plate is put on the superior part of the clavicle and the hook passed below the acromion posterior to the acromioclavicular joint, thus not interfering with the joint. This plate has been used in the management of acromioclavicular joint dislocation and distal clavicle fractures (2-9). As yet there is only

one comparative study comparing the hook plate with the Bosworth screw ; no significant difference was found between the Bosworth screw or the Wolter hook-plate (3). The main concern using the hook-plate is subacromial impingement. Excellent results in patients treated using Wolter hook-plate for acromioclavicular joint dislocation have been reported (4, 6, 7) with no subacromial impingement. Other described complications are widening of the hook hole in the acromion (this occurs because of the large range of movement of the acromioclavicular joint), calcification, ossification of the coracoclavicular ligaments, diastasis of the acromioclavicular joint, and redislocation of the acromioclavicular joint. We have had none of the above-mentioned complications in our series.

In conclusion, the hook-plate is a useful device to treat unstable injuries in the acromioclavicular region. The combination of a Weaver-Dunn procedure with hook-plate fixation has the advantage of protecting the ligament reconstruction without increased risk of subacromial impingement. When used for distal clavicular fracture, the acromioclavicular joint function is not disturbed. Once the fracture has healed, it does not appear to be mandatory to remove the hook-plate.

## REFERENCES

1. Apley A. G., Solomon L. Neuromuscular disorders. In : Apley's system of orthopaedics and fractures. Butterworths London, 6<sup>th</sup> edition, 1987, pp. 114-127.
2. Bircher H. P., Julke M., Thur C. Reconstruction of chronic acromioclavicular joint dislocation (Rockwood III-V) using the modified Weaver-Dunn method. *Swiss Surg.*, 1996, 2,46-50.
3. Broos P., Stoffelen D., Van de Sijpe K., Fourneau I. Surgical management of complete Tossy III acromioclavicular joint dislocation with the Bosworth screw or the Wolter plate. A critical evaluation. [German]. *Unfallchir.*, 1997, 23, 153-159 ; discussion 160.
4. Haberneck K., Schmid L., Walch G. Management of acromioclavicular joint dislocation with the Wolter hook-plate. One year follow-up of 35 cases. *Unfallchir.*, 1993, 19, 33-39.
5. Hackenburch W., Regazzoni P., Schwyzer K. Surgical treatment of lateral clavicular fracture with the clavicular hooked plate. *Z. Unfallchir. Versicherungsmed.*, 1994, 87, 145-152.

6. Henkel T., Oetiker R., Hackenburch W. Treatment of fresh Tossy III acromioclavicular joint dislocation by ligament suture and temporary fixation with the clavicular hooked plate. *Swiss Surg.*, 1997, 3, 160-166.
7. Sim E., Schwarz N., Hocker K., Berzlanovich A. Repair of complete acromioclavicular separations using the acromioclavicular-hook plate. *Clin. Orthop.*, 1995, 314, 134-142.
8. Ring D., Jupiter J. B., Miller M. E., Ada J. R. Fractures of clavicle. In : Browner. B, Jupiter J. B., Levine A. M., Trafton P. G. (eds.). *Skeletal Trauma*, W.B. Saunders, Philadelphia, 1998, pp. 1670-1688.
9. Yamaguchi H., Arakawa H. Kobayashi M. Results of the Bosworth method for unstable fractures of the distal clavicle. *Int. Orthop.*, 1998, 22, 66-68.

## SAMENVATTING

A. A. FARAJ, B. KETZER. *De behandeling van acromioclaviculaire letsels met een haak-plaatje.*

Een haakplaatje is een kleinfragmentenplaatje voorzien van een haak die onder het acromion schuift. Hoofdbedoeling is ondersteuning van het band herstel bij acromiale luxaties met verplaatsing.

Wij gebruikten zevenmaal het haak-plaatje om de reconstructie van een Weaver-Dunn te ondersteunen. Drie maal werd het gebruikt om een distale claviculafractuur te stabilizeren.

In alle gevallen werd een voldoeninggevend resultaat bereikt, met een volledige en pijnvrije schouderbeweeglijkheid zonder motorische verzwakking en dit na een gemiddelde opvolging van 11 maanden (6-25 maanden). Na een gemiddelde onderbreking van 3 maanden hernamen onze patiënten hun werk en sport.

De drie claviculafracturen heelden. Eén oppervlakkige wondinfectie beantwoordde aan wondverzorging en antibiotica. De plaat diende in geen geval te worden verwijderd.

De haak-plaat lijkt een nuttig hulpmiddel bij acromioclaviculaire letsels.

## RÉSUMÉ

A. A. FARAJ, B. KETZER. *Utilisation de la plaque à crochet dans le traitement des lésions traumatiques de l'articulation acromio-claviculaire.*

Les auteurs rapportent leur expérience du traitement des luxations acromio-claviculaires à grand déplacement au moyen d'une plaque à crochet. Il s'agit d'une plaque AO

pour petits fragments, pourvue d'un crochet qui s'engage sous l'acromion. Son indication première est de protéger la réparation ligamentaire après traitement des disjonctions acromio-claviculaires à grand déplacement. Les auteurs ont utilisé cette plaque à crochet en même temps qu'une réparation par la technique de Weaver-Dunn, pour traiter sept cas de luxation ; ils l'ont aussi utilisée dans trois cas pour réduire et stabiliser des fractures distales de la clavicule. Ils ont obtenu des résultats satisfaisants chez tous les patients ; la déformation a disparu, une mobilité complète et indolore de l'épaule a été

recouvrée sans perte de force musculaire, avec un suivi moyen de 11 mois (6 à 25 mois). Les patients ont repris rapidement leur travail et leurs activités sportives (en moyenne à trois mois). Les trois fractures claviculaires ont consolidé. Un patient a présenté une infection superficielle qui a bien répondu aux soins locaux et au traitement par antibiotiques. L'ablation du matériel n'a été nécessaire chez aucun patient. La plaque à crochet apparaît comme un matériel intéressant pour traiter les lésions traumatiques acromio-claviculaires.