



## Clinical results of isolated reconstruction of the medial patellofemoral ligament for recurrent dislocation and subluxation of the patella

Yoshinori MIKASHIMA, Masashi KIMURA, Yasukazu KOBAYASHI, Motoko MIYAWAKI, Taisuke TOMATSU

From Gunma Sports Medicine Research Center, Gunma, and Institute of Rheumatology, Tokyo Women's University, Tokyo, Japan

**Complications and results of medial patellofemoral ligament (MPFL) reconstruction, performed between 2000 and 2003, were studied retrospectively in 24 randomised patients (24 knees). All procedures were performed for recurrent dislocation or subluxation of the patella, using an autogenous semitendinosus tendon. Two different methods of anchoring of the transplant were compared. After a 2-year follow-up, patellar stability was found to be similar, when the transplant was sutured to the fibrous tissue and periosteum overlying the patella or when it was fixed in a bone tunnel through the patella.**

**The majority of the patients who had undergone MPFL reconstruction have returned to their previous level of sports activities. We had two cases of patella fracture and one case of persisting patella apprehension after surgery. Further studies must determine which measures are necessary to prevent these complications.**

**Keywords :** patella ; recurrent dislocation ; subluxation ; medial patellofemoral ligament reconstruction.

### INTRODUCTION

Although more than 100 different surgical techniques for the treatment of patellar instability have been described over the past 100 years, various questions continue to be raised (1, 2, 10, 12).

Based on recent biomechanical studies, the medial patellofemoral ligament (MPFL) is considered as the primary restraint against lateral dislocation among the medial patellar stabilisers (3, 5, 9).

Conlan *et al.* (3) reported that the MPFL provided 53% of the total medial restraining force. Hautamaa *et al* (9) and Desio *et al* (5) respectively reported 55% and 60%.

The MPFL extends from the superior two-thirds of the medial patellar margin to a point distal to the adductor tubercle and proximal to the posterior aspect of the femoral attachment of the medial collateral ligament (MCL). The superficial fibers blend with the posterior capsule of the knee (16).

Several recent studies have documented the value of MPFL reconstruction for recurrent patellar dislocation and subluxation, and have investigated especially the association between clinical symptoms and patellofemoral congruency following different surgical techniques (4, 6- 8, 13, 15, 17, 20, 21).

- 
- Yoshinori Mimashima, MD, Registrar
  - Masashi Kimura, MD, Head of Department
  - Yasukazu Kobayashi, MD, Consultant Orthopaedic Surgeon

■ Motoko Miyawaki, MD, Registrar  
*Department of Orthopaedic Surgery, Gunma Sports Medicine Research Center, Gunma, Japan.*

■ Taisuke Tomatsu, MD, Professor,  
*Department of Orthopaedic Surgery, Institute of Rheumatology, Tokyo Women's Medical University, Kawata chou, Shinjuku, Tokyo, Japan.*

Correspondence : Yoshinori Mikashima, ?198-0021 Takagi Hospital, 5-18-19, Imadera, Oume city, Tokyo, Japan.

E-mail : mikashima@mwb.biglobe.ne.jp

© 2006, Acta Orthopædica Belgica.

---

We compared clinical symptoms, return to sports activities, complications, and results after MPFL reconstruction for recurrent patellar dislocation and subluxation with two different tendon anchorage methods.

## MATERIALS AND METHODS

We retrospectively reviewed 24 randomised patients (24 knees) with recurrent patellar dislocation or subluxation, who had undergone MPFL reconstruction using an autogenous tendon as an isolated procedure between 2000 and 2003. There were 10 males and 14 females. Patients presenting with generalised joint laxity were excluded from this analysis. The mean age at the time of operation was  $21.8 \pm 4.9$  years (range : 13 to 24). The average follow-up was  $41.0 \pm 8.7$  months (range : 28 to 52). All patients were Japanese.

The indication for MPFL reconstruction was made when, after three months of conservative treatment and quadriceps muscle exercises, symptoms such as giving way, painful clicking and instability in activities of daily living or sports activities were not satisfactorily ameliorated.

On a skyline x-ray view, the sulcus angle was  $138^\circ$  to  $162^\circ$  (mean :  $146.2^\circ \pm 4.6^\circ$ ). On computed tomography, the tibial external rotation angle was  $0^\circ$  to  $10^\circ$  (mean :  $6.9^\circ \pm 5.5^\circ$ ).

Patients with recurrent patellar dislocation and subluxation with a tibial external rotation angle of  $8^\circ$  or less

(fig 1), were treated with isolated MPFL reconstruction. When the tibial external rotation angle exceeded  $8^\circ$ , MPFL reconstruction was combined with a distal realignment according to Elmslie-Trillat.

The semitendinosus was used as an autogenous tendon to reconstruct the MPFL. The autogenous tendon was fixed over a button on the femur. On the patella it was either routed through a bone tunnel and then sutured to itself (fig 2 a, b), or directly sutured to the periosteal and fibrous tissue overlying the patella (fig 3). The bone tunnel was drilled through the patella from the proximal half of its medial margin to the center of its anterior surface using a 4.5 mm drill. The autogenous tendon was fixed temporarily using stitches, while the knee was held in  $45^\circ$  flexion and the patella was correctly positioned manually. The anatomical position of the patella was controlled intra-operatively with an axial X-ray view, with the knee in  $45^\circ$  knee flexion. Permanent fixation was done when the joint congruence was satisfactory and MPFL tension remained satisfactory throughout the whole range of knee flexion.

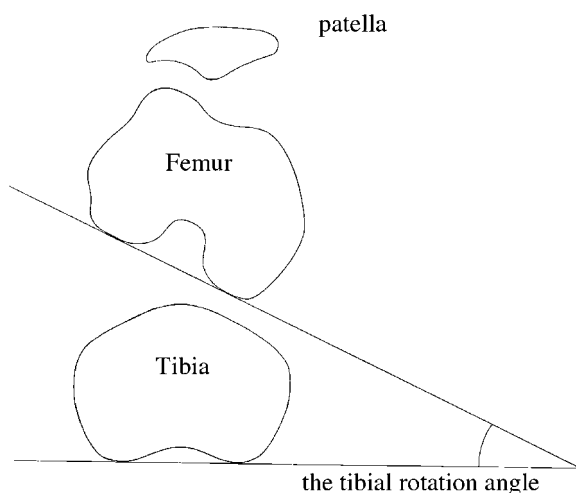
Immediately after surgery, patients were placed in a knee immobiliser. Quadriceps exercises with the knee extended were started as soon as tolerated by the patient. Continuous passive motion began on the second post-operative day. At three weeks post-surgery a patellar brace was applied. Five weeks post-surgery, full weight bearing was allowed. Jogging and mild sports activities were permitted at 4 months and full sports activities at 6 months post-surgery.

The patients were evaluated two years after surgery. Postoperative assessment included postoperative clinical symptoms, return to sports activities, and complications. The results of the two methods of fixation of the reconstructed ligament to the patella were compared.

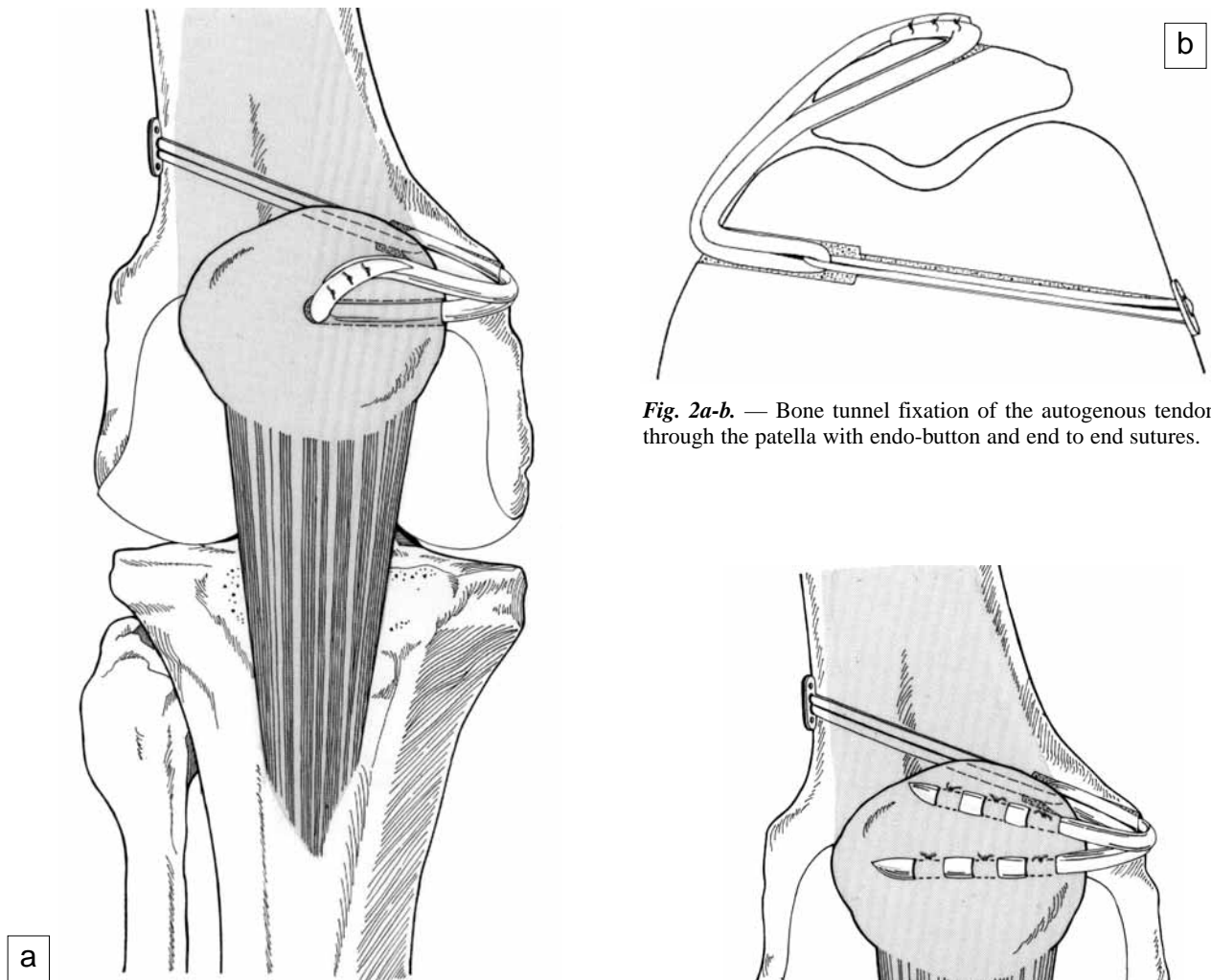
Postoperative clinical symptoms were evaluated comparing the pre- and post-operative Kujala score (11), which includes a variety of symptoms and signs of patellar instability with a maximal score of 100 points.

To evaluate the results, we compared the level of pre-operative and post-operative sports activity (previous level, reduced level, or sports activities abandoned). The delay in sports resumption was noted and the muscular condition was followed. Muscle strength of the flexors and extensors of the knee was measured at 6 months, 12 months, and 24 months after surgery using a Cybex II<sup>®</sup> device, and the unaffected/affected side ratio was calculated.

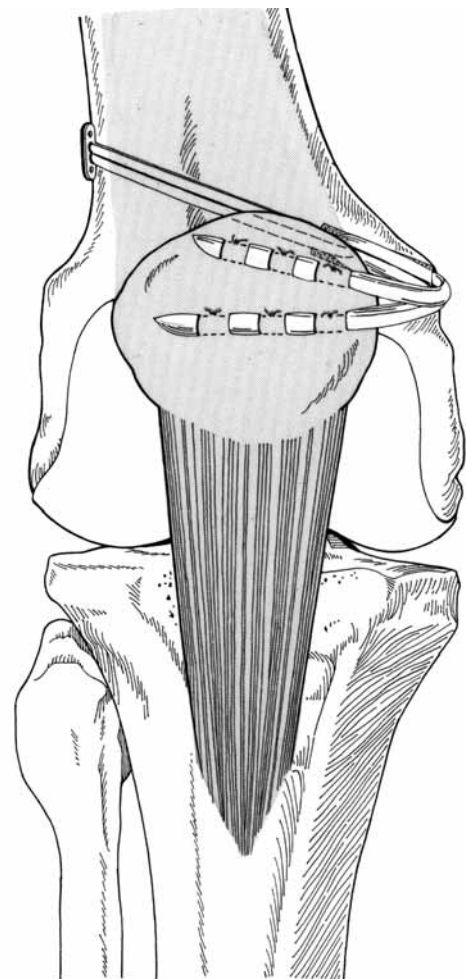
The results were compared between the two methods used to anchor the reconstructed ligament to the patella : the 24 patients were classified into two groups. Group A



**Fig. 1.** — The tibial external rotation angle, i.e. the angle between the posterior femoral condylar line and the posterior tibial condylar line on computed tomography.



**Fig. 2a-b.** — Bone tunnel fixation of the autogenous tendon through the patella with endo-button and end to end sutures.



**Fig. 3.** — Fixation of the autogenous tendon to fibrous tissues and periosteum overlying the patella.

included 12 patients whose reconstructed MPFL was anchored to the surface of the patella ; group B included 12 patients whose reconstructed MPFL was fixed into a patellar bone tunnel.

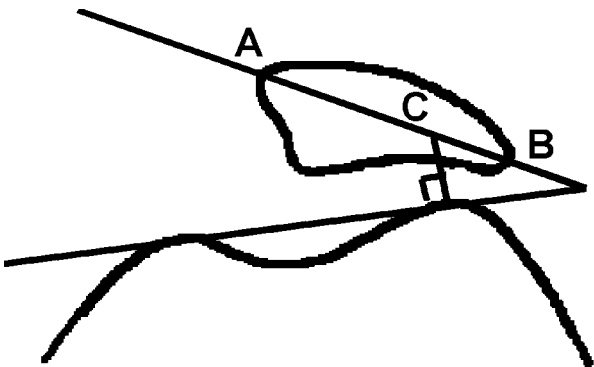
Both groups consisted of 5 males and 7 females. In Group A, ages ranged from 16 to 25 years, with a mean of  $24.0 \pm 6.7$  years. In Group B ages ranged from 13 to 24 years, with a mean of  $22.3 \pm 4.9$  years.

Stress radiographs were obtained. Radiological assessment included the lateral stress shift ratio following Ochi *et al* (18), obtained from a skyline view in  $30^\circ$  flexion with a stress of 2 kg (figs 4, 5). The findings were compared to those made on stress radiographs in 60 normal knees (Group N : 30 normal male knees and 30 normal female knees).

For statistical analysis, Mann-Whitney's test was used, and  $p < 0.05$  was regarded as significant.

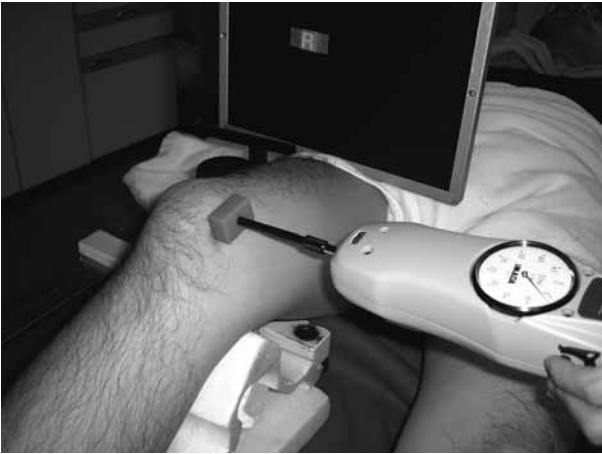

Fig. 4. — Lateral stress shift ratio according to Ochi *et al* (18).



$$\text{lateral shift ratio} = (BC/AB) \times 100$$

Fig. 5. — Skyline view in 30° flexion with 2 kg stress.

We also recorded all postoperative complications in the 24 patients.

## RESULTS

The mean Kujala score was  $95.2 \pm 12.9$  points (range : 82 to 100), compared to  $30.5 \pm 6.7$  points (range : 28 to 38) before surgery. Four knees scored 100 points.

Seventeen (70.8%) of the 24 patients were involved in recreational sports activities prior to injury (the appearance of knee pain). After surgery, 13 of the 17 patients (76.5%) resumed sport activi-

ties at the previous level, and 4 (23.5%) at a reduced level. None complained of patella apprehension or knee joint pain postoperatively.

The mean interval until return to sport activities was  $6.1 \pm 0.85$  months.

The mean values for the ratio of extensor strength of the affected to the unaffected knee at 6 months, 12 months, 24 months after the surgery were  $82.6 \pm 10.6\%$ ,  $90.6 \pm 13.2\%$ , and  $95.8 \pm 19.9\%$ . The mean values for the ratio of the flexor strength of the affected to the unaffected knee at 6 months, 12 months, 24 months after the surgery were  $75.6 \pm 12.4\%$ ,  $79.9 \pm 11.5\%$ , and  $83.9 \pm 12.8\%$ . In those who had returned to previous sports activities, 24 months after surgery, the mean ratio of the extensor strength of the affected to the unaffected knee was  $98.6 \pm 7.6\%$ , and  $78.9 \pm 6.8\%$  in those who had reduced sports levels.

The mean ratio of the flexor strength of the affected to the unaffected knee 24 months after the surgery was  $88.6 \pm 9.2\%$  in those who had returned to the previous sports level, and  $75.9 \pm 7.8\%$  in those who had reduced the sports level.

The mean stress lateral shift ratios was  $15.0 \pm 5.5\%$  (males :  $14.4 \pm 4.5\%$ , females :  $15.7 \pm 6.7\%$ ) in the normal group,  $20.0 \pm 9.4\%$  in Group A, and  $19.2 \pm 6.3\%$  in Group B, against  $32.3 \pm 10.3\%$  in group A and  $35.6 \pm 8.9\%$  in group B before surgery. The postoperative values between Group A and B ( $p = 0.19$ ), and between Group A/B and the normal group ( $p = 0.17$ ) were not significantly different.

Fracture of the patella occurred in two patients, both in Group B. One of them fractured her patella by hyperflexing the knee during a fall in her bathroom 4 weeks post-surgery (fig. 6a,b). She underwent surgery to remove a fragment of the patella and made a satisfactory recovery. In the other patient, a patella fracture was disclosed on a follow-up radiograph 5 weeks post-surgery, without a history of trauma. Rehabilitation was delayed, and the patient made a satisfactory recovery.

Whereas the apprehension test was positive in all the knees pre-operatively, it was found positive at follow-up in only one patient (4.2%) belonging to Group B. The stress lateral shift ratio of this patient was 25.0%, against 35.3% before surgery.

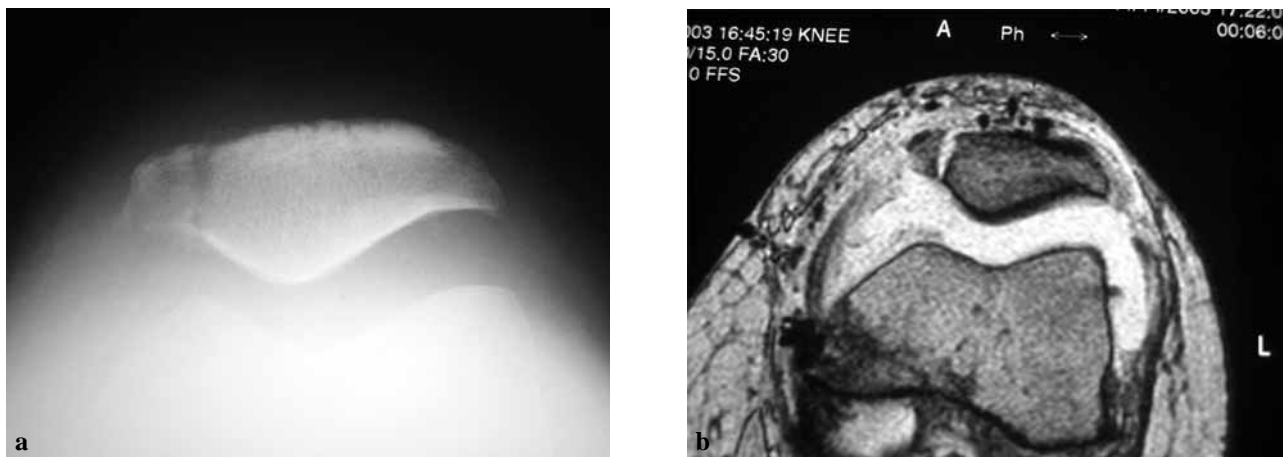


Fig. 6. — Patella fracture after drill hole fixation.

## DISCUSSION

In our institution, the surgical procedure for patellofemoral tracking disorders was selected according to the type of patellofemoral joint incongruence. We use a Tanaka classification based on the sulcus angle and the tibial external rotation angle (fig 7). Type I (recurrent patellar dislocation) includes knees with a large sulcus angle and a large tibial external rotation angle of the tibia. Type II (patellar subluxation) includes knees with a large sulcus angle and a small tibial external rotation angle. Type III (excessive lateral pressure syndrome) includes knees with a small sulcus angle and a large tibial external rotation angle. Type IV (normal) includes knees with a small sulcus angle and a small tibial external rotation angle. We performed distal realignment mainly for type I, proximal realignment mainly for type II (19).

Initially, the Elmslie-Trillat procedure alone was employed for distal realignment. However, many patients showed residual apprehension signs. Therefore, recently, MPFL reconstruction has been performed alone or combined with the Elmslie-Trillat procedure (13).

Nomura *et al* (15) reported that, at an average follow-up of 5.9 years, MPFL reconstruction should be considered a safe and effective procedure, because 26 of 27 MPFL reconstructions using a mesh type artificial ligament were classified as

excellent and good using the Crosby and Insall grading system. Deie *et al* (4) reported that at an average follow-up of 7.4 years, MPFL reconstruction should be considered an effective procedure, as the postoperative average Kujala score in 6 patients with MPFL reconstruction was 96.3 points. In our survey, there was no patient with recurrent dislocation, and good results were obtained with respect to activities of daily living.

Few studies have reported on return to sports activities after MPFL reconstruction. Nomura (15) reported that jogging and mild sports activities

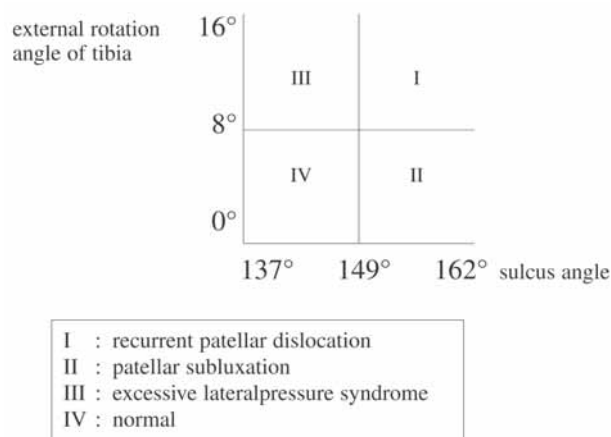


Fig. 7. — The Tanaka classification based on sulcus angle and tibial external rotation angle.

were permitted after 8 weeks and full sport activities 12 weeks post-surgery using an artificial ligament for recurrent patellar dislocation. In our survey, the return to sports activities took longer after surgery, possibly because in our patients the semitendinosus tendon had been sacrificed. However, return to previous sports activities was achieved in many of our patients, possibly because MPFL reconstruction improved lateral patellar instability and eliminated anxiety to participate in sport activities. The reason why some patients returned to sports activities at a reduced level was thought to be muscular weakness around the knee, rather than persistence of patella apprehension or knee joint pain.

As postoperative complications of MPFL reconstruction, Nomura (15) reported local pain about the femoral staples used for fixation of the artificial ligament, Yamada (21) reported restriction of flexion, and Watanabe (20) persisting patellar apprehension. We had two patella fractures in our 24 patients. Both of the patients with patella fracture were in Group B (patients whose reconstructed MPFL was fixed into a bone tunnel in the patella). We also had one patient complaining of persisting patellar apprehension postoperatively.

Because in this study no significant difference after a 2-year follow-up was observed in the quality of fixation between suturing to the periosteum and the fibrous tissue overlying the patella and fixation in a bone tunnel, we recommend suturing to fibrous tissue and the patellar periosteum as the first choice, especially in patients with a small patella or open physes. The reconstructed ligament should be sutured as close as possible to the lateral retinaculum to ensure firm fixation. Fixation in a bone tunnel is recommended in patients with a thin fibrous and periosteal covering of the patella.

Gomes *et al* (7) warned against damaging the cartilage surface of the patella by creating a bone tunnel. Utmost caution not to damage the cartilage surface or to cause fracture is necessary in creating a bone tunnel. The direction of the bone tunnel varied from parallel (Yamada *et al.* (21)) to oblique, as in our technique (fig 1 b) in relation to the patellar surface, needs further evaluation.

In our survey, one knee was judged to have mild hypermobility.

The influence of the knee angle during final fixation and the tension of fixation of the reconstructed ligament, on the persistence of patellar apprehension need further consideration. Gomes *et al* (7) fixed at 90° flexion, Nomura *et al* (15, 17) at 60°, Yamada *et al* (21) at 45°, Deie *et al* (4) at 30°. Nomura *et al* (15, 17) placed a temporary 6-mm high tension spacer with traction at 0.5 kg while the artificial ligament was temporarily fixed, and fixed permanently after confirming the tension of the ligament to be adequate in the entire range of motion. Yamada *et al* (21) manually pushed the patella to the lateral side, while the transplant tension was adjusted so that the patella could not be dislocated. Since the tension of fixation is considered to change when autogenous tendons are used, such as a semitendinous tendon and a gracilis tendon, a quantitative measurement as with the artificial ligament of Nomura *et al* (15, 17) is less reliable. Further evaluation is necessary to find the limb position and tension of fixation appropriate for the prevention of slackness.

Opinions also differ concerning the material to be used for ligament reconstruction. Nomura *et al* (15, 17) used an artificial ligament, and Deie *et al* (4) Yamada *et al* (21), Drez *et al* (6), and Watanabe *et al* (20) used autogenous tendons such as a semitendinosus or a gracilis tendon for the reconstruction. Gomes *et al* (7, 8) performed reconstruction initially using artificial ligaments (polyester, 8 mm wide) but have recently used a semitendinosus tendon. In summary, autogenous tendons are used in a majority of reports at present. We think that autogenous tendons are best, because we have achieved good results using autogenous tendons and there is nothing that surpasses an autologous histocompatibility. Further evaluation is also necessary concerning the reconstruction material.

## CONCLUSION

1. In this study, we investigated clinical symptoms, return to sports activities, complications, and outcome with two different methods of anchoring the reconstructed MPFL to the patella for recurrent patellar dislocation and subluxation.

2. The majority of patients have returned to sports activities after MPFL reconstruction surgery.
3. The two methods used to anchor the reconstructed MPFL to the patella resulted in a similar post-operative outcome.

### REFERENCES

1. **Aichroth PM, Al-Duri Z.** Dislocation and subluxation of the patella : an overview. In : Aichroth PM, Al-Duri Z, eds. *Knee Surgery*. Martin Dunitz, London. 1992 ; pp 354-379.
2. **Barney L, Freeman III.** Recurrent dislocation. In : *Campbell's Operative Orthopaedics*. Seventh edition, Mosby, Philadelphia 1987 ; 52 : pp 2173-2184.
3. **Conlan T, Gaeth WPJr, Lemons JE.** Evaluation of the medial soft-tissue restraints of the extensor mechanism of the knee. *J Bone Joint Surg* 1993 ; 75-A : 682-693.
4. **Deie M, Ochi M, Yasumoto M et al.** Reconstruction of the medial patellofemoral ligament for the treatment of habitual or recurrent dislocation of the patella in children. *J Bone Joint Surg* 2003 ; 85-B : 887- 890.
5. **Desio DS, Burk RT, Bachus KN.** Soft tissue restraint to lateral patellar translation in human knee. *Am J Sports Med* 1998 ; 26 : 59- 65.
6. **Drez D, Edwards TB, Williams CS.** Results of medial patellofemoral ligament reconstruction in the treatment of patellar dislocation. *Arthroscopy* 2001 ; 17 : 298-306.
7. **Gomes JLE.** Medial patellofemoral ligament reconstruction for recurrent dislocation of the patella ; a preliminary report. *Arthroscopy* 1992 ; 8 : 335-349.
8. **Gomes JLE, Marczyk LRS, Cesar PC et al.** Medial patellofemoral ligament reconstruction with semitendinosus autograft for chronic patellar instability : a follow up study. *Arthroscopy* 2004 ; 20 : 147-151.
9. **Hautamaa PV, Fithian DC, Kaufmann KR et al.** Medial soft tissue restraints in lateral patellar instability and repair. *Clin Orthop* 1998 ; 349 : 174- 182.
10. **Hughston JC, Deese M.** Medial subluxation of the patella as a complication of lateral retinacular release. *Am J Sports Med* 1998 ; 16 : 383-388.
11. **Kujala UM, Jaakkola LH, Koshinen SK et al.** Scoring of patellofemoral disorders. : *Arthroscopy* 1993 ; 9 : 159-163.
12. **Madigan R, Wissinger HA., Donaldson WF.** Preliminary experience with a method of quadricepsplasty in recurrent subluxation of the patella. *J Bone Joint Surg* 1975 ; 57-A : 600-607.
13. **Mikashima Y, Kimura M, Kobayashi Y et al.** Medial patellofemoral ligament reconstruction for recurrent patellar instability. *Acta Orthop Belg* 2004 ; 70 : 545-550.
14. **Morikawa T, Moriya H, Katsuro T et al.** The study of operative treatment for recurrent patellar dislocation and subluxation. *Rinshou Suports Igaku* 1985 ; 2 : 405-411.
15. **Nomura E, Horiuchi Y, Kihara M.** A mid-term follow-up of medial patellofemoral ligament reconstruction using an artificial ligament for recurrent patellar dislocation. *Knee* 2000 ; 7 : 213-216.
16. **Nomura E, Donald CF, Elizabeth EA.** The significance of the medial patellofemoral ligament in patellar dislocation. *Seikeigeka* 2002 ; 53 : 1 : 1-7.
17. **Nomura E, Inoue M.** Surgical Technique and rationale for medial patellofemoral ligament reconstruction for recurrent patellar dislocation. *Arthroscopy* 2003 ; 19 : 1- 9.
18. **Ochi M, Murakami Y, Deie M et al.** Roentgenographic examination of subluxation and instability of the patella. *J Joint Surg* 1996 ; 15 : 53- 61.
19. **Tanaka K, Kimura M, Hasegawa J.** Study for patellofemoral malalignment. *Tokyo hiza kansetugakkai kaishi* 1990 ; 11 : 44-51.
20. **Watanabe S, Omori G, Sofue T et al.** Short term result of medial patellofemoral ligament reconstruction for recurrent dislocation of patella. *J Japan Knee Society* 2004 ; 29 : 167-170.
21. **Yamada Y, Toritsuka Y, Shino K et al.** The bi-socket medial patellofemoral ligament reconstruction for recurrent dislocation of the patella. *J Japan Knee society* 2004 ; 28 : 120-124.
22. **Yoshimatsu T, Saito A, Fukushima K et al.** Clinical follow-up study of the recurrent patella dislocation and patella subluxation syndrome ; relation between muscle recovery and sports activity. *Seikeisaigaigeka* (in Japanese) 2001 ; 44 : 769-774.