



## Osteochondral fractures in the knee treated with butyl-2-cyanoacrylate glue A case report

Rehan GUL, Fahim KHAN, Yusuf MAHER, Dermot O'FARRELL

*From Mid Western Regional Hospital, Limerick, Ireland*

**We report a new method of fixation of osteochondral fractures using tissue adhesive butyl-2-cyanoacrylate. A traumatic osteochondral fracture of the patella and the medial femoral condyle in a 29-year-old male was fixed with butyl-2-cyanoacrylate tissue adhesive. At 6 month follow-up the fractures showed complete healing, the postoperative knee score was 84 and the functional knee score 90 (Knee Society Clinical Rating System).**

**Keywords :** butyl-2-cyanoacrylate ; osteochondral fracture.

### INTRODUCTION

Butyl-2-cyanoacrylate has been used as tissue adhesive since the 1960's. Its applications include skin closure and attaching cartilage in facial reconstructive surgery and rhinoplasty. It has been used to embolise blood vessels in cases of tumours and haemorrhage. It has been extensively used in maxillofacial surgery and its safety and effectiveness have been widely tested. Cyanoacrylates can be synthesised by reacting formaldehyde with alkyl cyanoacetate to obtain a prepolymer that, by heating, is depolymerised into a liquid monomer. The monomer can then be modified by altering the alkoxy carbonyl (-COOR) group of the molecule to obtain compounds of different chain lengths. Butyl-2-cyanoacrylate is the only commercially available cyanoacrylate tissue adhesive. It is

approved by the Food and Drug Administration authority as tissue adhesive.

### CASE HISTORY

A 29-year-old gentleman fell from a height of six feet and landed on his left knee. He was referred to the outpatient clinic two days after the injury and was diagnosed with osteochondral fractures of the medial femoral condyle and the patella. He had no previous complaints about the knee and had no ligamentous instability on examination. He underwent a knee arthroscopy, confirming a full thickness osteochondral fracture of the medial femoral condyle and patella (fig 1). Subsequently arthrotomy was performed using a medial parapatellar approach with a view to fix the osteochondral fragments. We found the osteochondral fragments very thin to be secured with anchors or Herbert screws ;

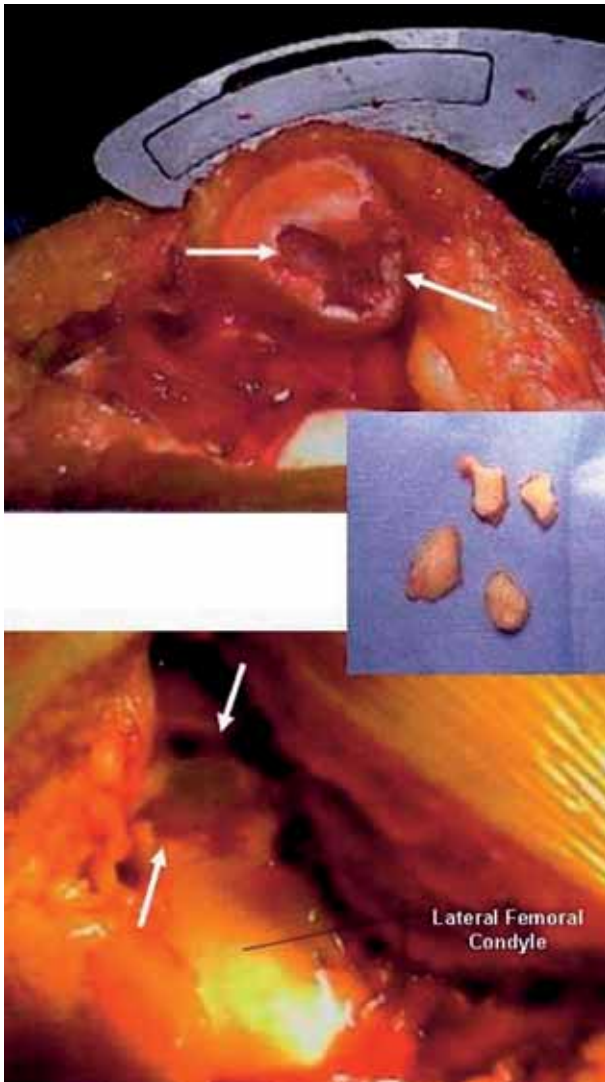
- 
- Rehan Gul, FRCS (Tr & Orth), MD, Specialist Registrar.
  - Fahim Khan, FRCSI, MD, Specialist Registrar.
  - Yusuf Maher, FRCSI, MD, Registrar.
  - Dermot O'Farrell, FRCS (Tr & Orth), MD, Consultant Orthopaedic Surgeon.

*Department of Orthopaedic and Trauma Surgery, Mid Western Regional Hospital, Limerick, Ireland.*

Correspondence : Mr. Rehan Gul, AFRCSI, FRCSI, SPR, Orthopaedic Surgery, Cappagh National Orthopaedic Hospital, Cappagh, Dublin, Ireland. E-mail : rehangul@hotmail.com.

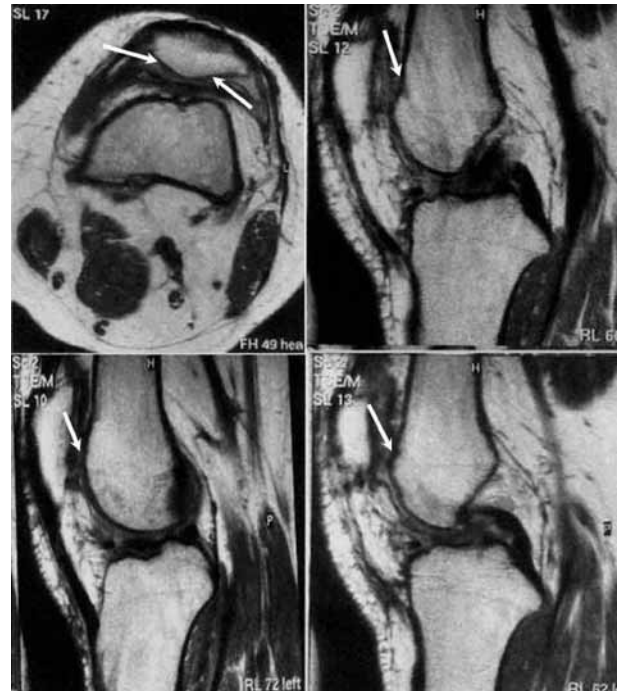
© 2006, Acta Orthopædica Belgica.

---



**Fig. 1.** — Intra-operative view of osteochondral fracture in patella and medial femoral condyle.

therefore a decision was taken to reattach the fragments using butyl-2-cyanoacrylate tissue glue. Postoperatively the knee was immobilised in a cylinder cast for six weeks. The patient was informed about the use of butyl-2-cyanoacrylate tissue glue postoperatively. Range of movement (ROM), quadriceps strengthening and closed chain exercises were started at six weeks. The patient regained full ROM after six weeks and was mobilising without any support. An MRI Scan of the knee was performed at 6 month follow-up and



**Fig. 2.** — MRI Scan of left knee at 6 months showing complete healing of osteochondral fractures.

confirmed complete healing of the fracture fragments (fig 2). The patient was asymptomatic at this stage and scored 84 points on the post operative knee score and 90 points on the functional knee score of the Knee Society Clinical Rating System.

## DISCUSSION

Osteochondral fractures of the knee are common and frequently missed injuries. If left untreated the defects may lead to symptomatic arthritis of the knee (2). There is no satisfactory method of fixing these fractures. Various methods have been reported including sutures, screw fixation, multiple smooth pins (Smillie pins) and darts. The success of these different techniques depends on fracture fragment thickness, time duration, location of fracture and operator experience. Yilmaz and Kuyurtar (7) reported successful fixation of a talar osteochondral fracture with cyanoacrylate glue.

Cyanoacrylates were first synthesised in 1949 by Airdis (1). Their adhesive properties and their

possible use in surgery were described by Coover *et al* in 1959 (3). Upon application to living tissues, the monomer undergoes an exothermic reaction that results in polymerisation of the adhesive. Several studies have shown wound breakdown strength in wounds repaired with butyl-2-cyanoacrylate to be equal to that in wound repaired with sutures at 5-7 days. After polymerisation, the adhesive becomes brittle and is subject to fracturing: i.e. the parent compound degrades by an aqueous process into by-products: cyanoacetate and formaldehyde. It has been shown to cause inflammation, tissue necrosis and granulation formation when implanted subcutaneously, possibly due to the by-products of degradation and depending on the rate of degradation of the parent compound (4, 5). Butyl-2-cyanoacrylate has been widely used in maxillofacial and plastic surgery (upper lid blepharoplasty, facial skin closure, and scalp wound closure) as tissue adhesive. It has been used by radiologists and gastroenterologists as embolising agent. Its use in fixation of bone fragments is still under investigation (6).

We successfully used butyl-2-cyanoacrylate to reattach osteochondral fractures in the knee and follow-up showed successful healing of the frac-

tures with no complications and excellent clinical outcome. In conclusion, butyl-2-cyanoacrylate has shown to be an effective means for fixation of acute osteochondral fractures but it requires a further investigation to establish the efficacy of this form of treatment.

## REFERENCES

1. **Ardis AE.** US Patents No. 2467926 and 2467927, 1949.
2. **Birk GT, DeLee JC.** Osteochondral injuries. Clinical findings. *Clin Sports Med* 2001 ; 20 : 279-286.
3. **Coover HN, Joyner FB, Sheerer NH.** Chemistry and performance of cyanoacrylate adhesive. *J Soc Plast Surg Engl* 1959 ; 15 : 5-6.
4. **Galil KA, Schofield ID, Wright GZ.** Effects of n-butyl-2-cyanoacrylate (histoacryl blue) on healing of the skin wounds. *J Can Dent Assoc* 1984 ; 50 : 565-569.
5. **Quinn J, Wells G, Sutcliffe T.** Tissue adhesive versus suture wound repair at 1 year: randomized clinical trial correlating early, 3 month and 1 year cosmetic outcome. *Ann Emerg Med* 1998 ; 32 : 645-649.
6. **Shermak MA, Wong L, Inoue N et al.** Fixation of craniofacial skeleton with butyl-cyanoacrylate and its effects on histotoxicity and healing. *Plast Reconstr Surg* 1998 ; 102 : 309-318.
7. **Yilmaz C, Kuyurtar F.** Fixation of talar osteochondral fracture with cyanoacrylate glue. *Arthroscopy* 2005 ; 21 : 1009.