

# DISTRACTION OSTEOTOMY FOR MALUNION OF THE DISTAL END OF THE RADIUS WITH RADIAL SHORTENING

H. ARSLAN, M. SUBASI, C. KESEMENLI, A. KAPUKAYA, S. NECMIOGLU

**The treatment and outcomes of distraction osteotomy in 9 patients with malunion of the distal radius with radial shortening are presented.**

**The patients had an average age of 32 years (range : 14 to 36 years) and comprised 7 males and 2 females. Ulnar inclination was below normal in all patients, volar inclination was below normal in 8 patients, and the average radial length discrepancy was 7.6 mm (range : 4 to 16 mm). Angulations in the distal radius were corrected by manipulation after osteotomy, and shortening by callus distraction.**

**In order to achieve normal radial length, distraction was performed for an average of 10.2 days (range : 7 to 19 days), and union occurred in an average of 10.7 weeks (range : 9 to 13 weeks). During the waiting period between distraction and consolidation, impairment of ulnar and volar inclination recurred in 3 patients, and translation of the distal fragment necessitating correction occurred in 3 patients. No cases of nonunion or malunion were observed. In all patients, there was a decrease in cosmetic and pain-related complaints, and improvement in wrist movements.**

**Distraction osteotomy is a simple and effective treatment for malunion of the distal radius with concurrent radial shortening. However, the position of the distal fragment should be followed up until consolidation.**

carpal impingement (9, 11). Furthermore, it may decrease inclination in the ulnar plane, grasping strength, and extension and ulnar deviation in the wrist and hand, as well as bringing about cosmetic complaints (7, 10, 11).

Bowers' hemiresection interposition arthroplasty, Darrach's procedure, the Sauvé-Kapandji procedure and other corrective surgical methods have been described in the literature (2, 3, 7, 8). Indications for Darrach's procedure have been narrowed in recent years due to its complications (3, 7). Corrective surgery and combined procedures in the distal radius are frequently reported to lead to residual problems in the distal radioulnar joint (3, 5, 10, 11). Achieving an anatomical relationship between the sigmoid notch and the ulnar head is a requisite for success. However, during corrective osteotomies, correction of length discrepancy with a suitable graft and maintenance of the correction are technically difficult, particularly in cases with marked discrepancy and in long-standing deformities (1, 11, 12). Few cases have been reported in which malunion of the distal radius was treated by callus distraction, and there is insufficient data concerning its effectiveness (7).

In the present study, we present the treatment and outcomes of callus distraction in patients with

## INTRODUCTION

Shortening of the radius following fracture of its distal end leads to incongruence and instability in the distal radioulnar joint. This deformity adversely affects forearm rotation and causes distal ulno-

---

Department of Orthopaedic and Trauma Surgery, University of Dicle, School of Medicine, Diyarbakır, Turkey

Correspondence and reprints : Hüseyin Arslan, Dicle Üniversitesi. Tıp Fakültesi, Ortopedi ve Travmatoloji Kliniği, Diyarbakır, Türkiye. E-mail : diclehuseyin@hotmail.com.

severe shortening of the radius following fracture of its distal end.

## MATERIALS AND METHODS

We treated 9 patients who presented with malunion following distal radial fracture, who were treated by callus distraction. Their average age was 32 years (range : 14 to 36 years) ; there were 7 males and 2 females.

Malunion was secondary to intraarticular fracture of the distal radius in five patients, Colles fracture in two patients, Smith's fracture in one patient, and segmental fracture of the radius in one patient. The last patient had nonunion of the radial diaphysis in addition to malunion of the distal radius (fig 1a, b, c).

Standard anteroposterior and lateral radiographs were taken preoperatively, and measurements were carried out with Castaing's modification of the method devised by Gartland and Werley (in 3). Ulnar inclination was measured as the angle between a line drawn parallel to the distal articular surface of the radius and a line drawn perpendicular to the radial shaft. Volar inclination was measured as the angle between a line drawn tangential to the distal radial articular surface in the sagittal plane and a line drawn parallel to the shaft of the radius. The radio-ulnar index was measured by determining the distance between a line drawn perpendicular to the long axis of the radius and tangential to the lunate facet of the radial articular surface and the distal end of the ulnar head.

Post-traumatic osteoarthritic changes were graded according to the criteria of Knirk and Jupiter (6). Mild changes represented slight narrowing of the joint space ; moderate changes, marked narrowing, and the presence of marginal osteophytes ; and severe changes indicated complete loss of the joint space and the presence of marginal osteophytes and subchondral bone cysts.

Pain was assessed as mild, moderate, or severe. Mild pain meant that there was pain in extreme wrist movements that did not create physical or psychological problems ; moderate pain meant that pain occurred during hard work and that it created physical and/or psychological problems ; and severe pain meant that pain occurred during daily activities, and even at rest (3).

## SURGICAL TECHNIQUE

A dorsal approach was performed under general anesthesia using a pneumatic tourniquet. The distal radial metaphysis and Lister' tubercle were exposed. Two K-wires were positioned parallel to

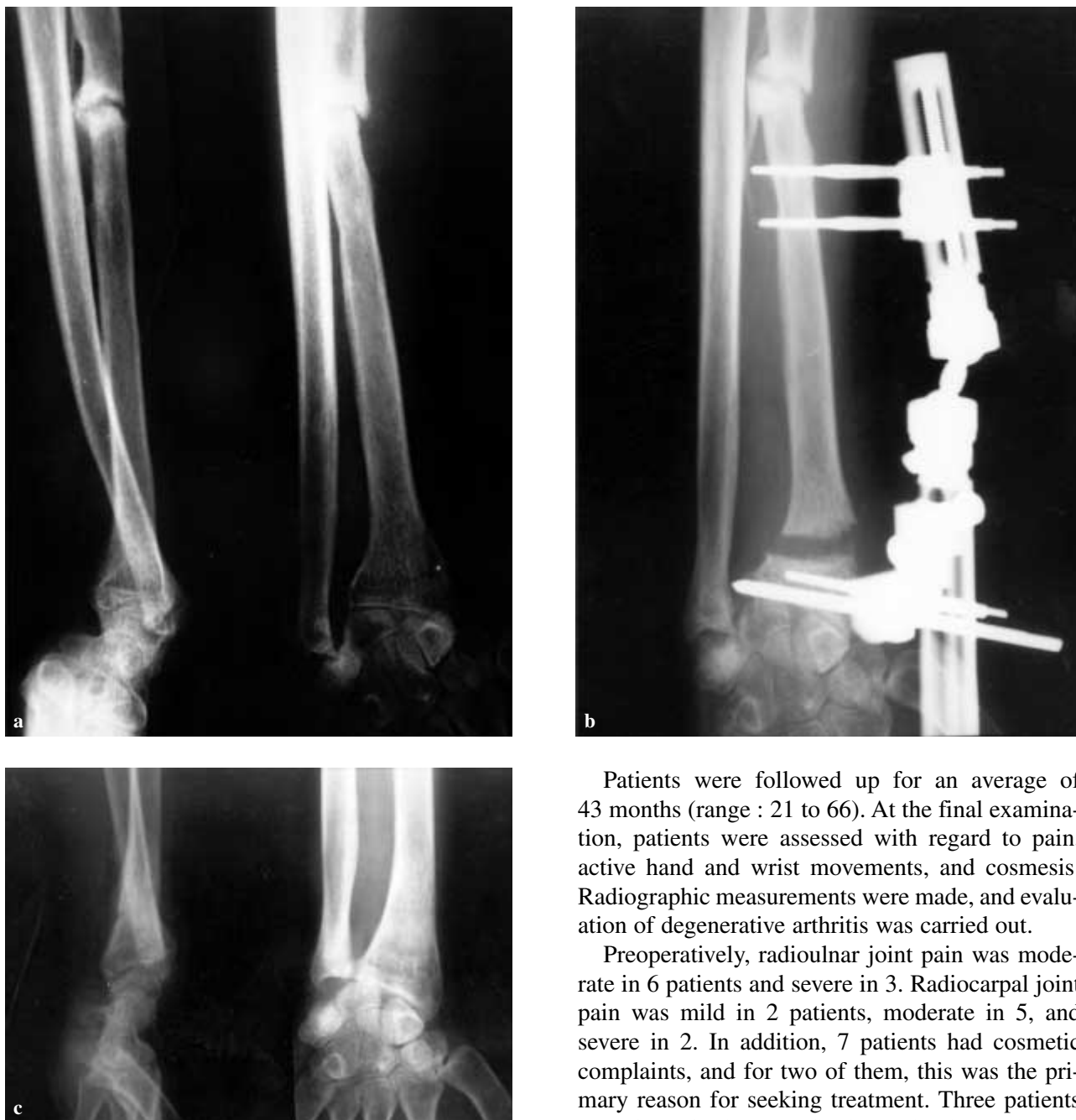the joint, one on Lister' tubercle and the other on the ulnar side of this pin, at a 45° angle in the frontal plane, and their position was checked by fluoroscopy. Two fixator pins were then placed in suitable positions. The radius was then exposed proximally over 10 to 14 cm and 2 pins were inserted in the radial diaphysis. Complete osteotomy of the radius was performed 10 mm proximal to the distal pins, and the external fixator was adapted. By manipulation of the fragments, radial inclination and volar inclination were corrected under fluoroscopic control, and the fixator connector was tightened. Intraoperatively, correction of radial shortening and bone grafting were not performed.

On postoperative day 7, after the waiting period, daily distraction of  $2 \times 0.5$  mm was begun, and the extent of distraction was followed up radiographically. After a sufficient radioulnar index was obtained, distraction was terminated and the fixator was left in place until consolidation. Postoperatively, active and passive hand and wrist exercises were initiated, and continued after removal of the fixator.

## RESULTS

In order to achieve normal radial length, it was necessary to perform distraction for an average of 10.2 days (range : 7 to 19 days), and union was achieved in an average of 10.7 weeks (range : 9 to 13 weeks). No nonunion or delayed union were observed. Nonunion in the radial diaphysis of patient 4 healed spontaneously, presumable because distraction in the distal metaphysis exerted compression on the nonunion (fig 1b, c).

During the distraction period and the waiting period for consolidation, ulnar and volar inclination was impaired in 3 patients, and ulnar and volar translation occurred in the distal fragment in two patients (fig 1b), and volar translation occurred in the distal fragment in one patient. In these patients, the external fixator module was loosened and the fragments were corrected by manipulation. Volar translation persisted in two patients, and volar translation and impaired volar inclination persisted in two patients (fig 1c).

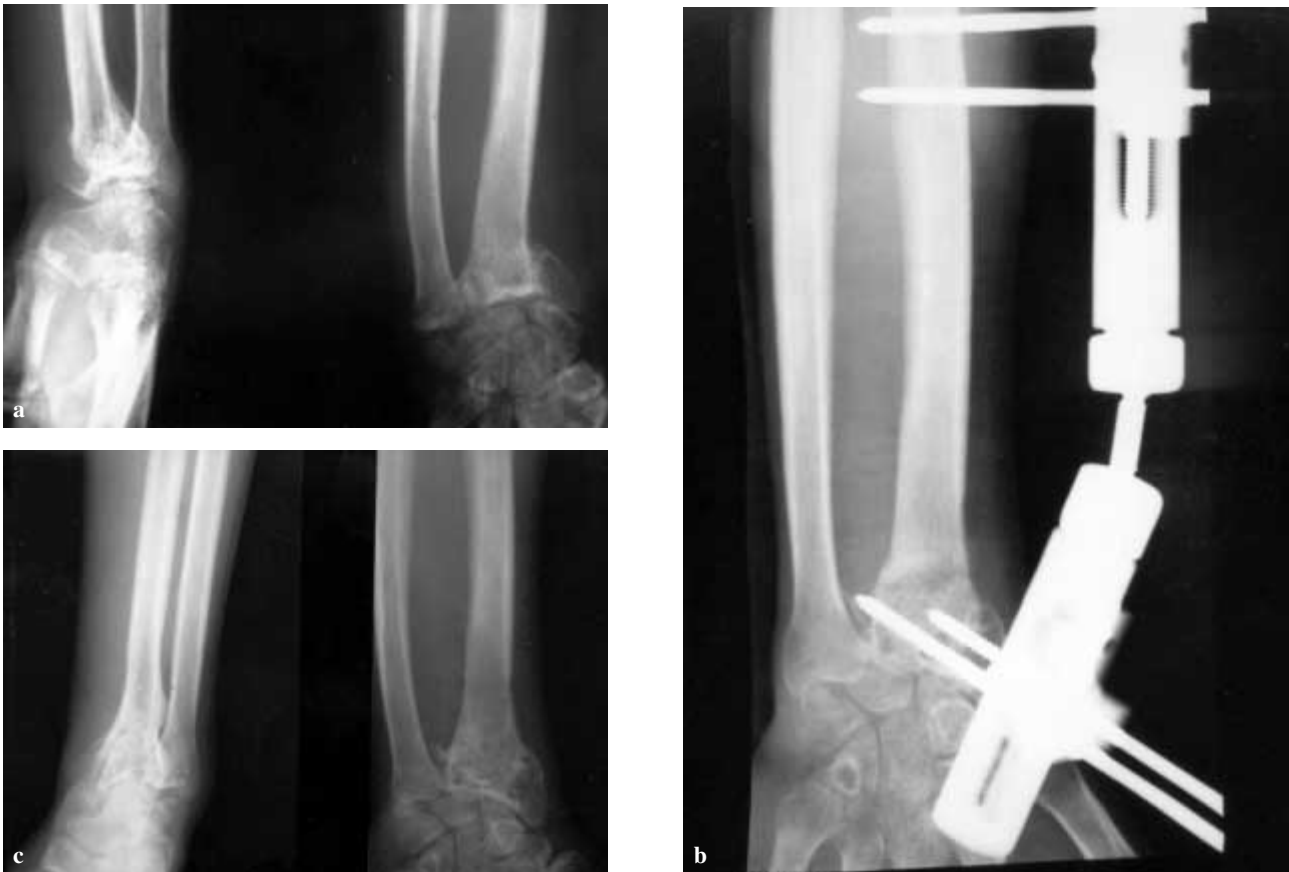


**Fig. 1a.** — Preoperative anteroposterior and lateral X-ray of a patient with malunion in the distal radius and nonunion in the diaphysis associated with a segmental fracture in the radius (case 4). **b** : Ulnar translation of the distal fragment occurred during distraction. **c** : Anteroposterior and lateral X-ray 6 months postoperatively. Radio-ulnar index : 0 mm. Volar inclination : 8°. Ulnar inclination : 19°. Diaphyseal nonunion healed.

Patients were followed up for an average of 43 months (range : 21 to 66). At the final examination, patients were assessed with regard to pain, active hand and wrist movements, and cosmesis. Radiographic measurements were made, and evaluation of degenerative arthritis was carried out.

Preoperatively, radioulnar joint pain was moderate in 6 patients and severe in 3. Radiocarpal joint pain was mild in 2 patients, moderate in 5, and severe in 2. In addition, 7 patients had cosmetic complaints, and for two of them, this was the primary reason for seeking treatment. Three patients were free of pain at the final examination. Pain persisted, albeit decreased, in all but one of the remaining six ; radiocarpal joint pain was mild in four and moderate in one, and radioulnar joint pain was mild in two and moderate in four. All patients had cosmetic improvement, and were pleased with their cosmetic outcomes (fig 2a, b, c).

The average preoperative hand-wrist range of motion determined by standard goniometry was as



**Fig. 2a.** — Preoperative anteroposterior and lateral X-ray of a patient with malunion in the lower end of the radius following Colles fracture (case 9). **b** : Anteroposterior X-ray 2 months postoperatively. **c** : X-ray 24 months postoperatively. Radioulnar index : 0 mm. Volar inclination : 11°. Ulnar inclination : 22°.

follows : dorsiflexion, 48° (normal side 78°), palmar flexion 25° (normal side 74°), pronation 25° (normal side 75°), and supination 17° (normal side 87°). At final examination, the average angles were respectively, 55°, 38°, 46°, and 59°.

Preoperatively, ulnar inclination was below normal in all patients, volar inclination was below normal in 8 patients (table I), and the average length discrepancy was 7.6 mm (range : 4 to 16 mm). Radiographically, the average volar inclination was 1.6° (range : -11 to 6°) preoperatively, and 7.2° (range : 3 to 11°) postoperatively. The average ulnar inclination increased from 5.7° preoperatively (range : -5 to 13°) to 17.5° postoperatively (range : 12 to 22°). The average radioulnar index was -7.6 mm (range : -4 to -16 mm) preoperatively and 0.2mm (range : -2 to 2 mm) postoperatively.

In the radiocarpal joint, two patients had mild and one had moderate osteoarthritis (fig 2c) ; in the radioulnar joint, two patients had mild, three patients had moderate, and one patient had severe osteoarthritis. In addition, chondropathy in the ulnar head was noted on X-rays in one patient .

## DISCUSSION

Surgical indications in malunion of the distal radius include severe pain or functional impairment rather than anatomical irregularities (2, 3, 4, 5, 7). In cases involving only osteopenia, osteoarthritic changes, and in patients with systemic problems, surgery is contraindicated. To date, a number of surgical procedures have been implemented, each having its own area of application, advantages, and

Table I. - Data of the patients before surgery and at latest follow-up

Case	Age, Sex	Radiographic measurements (before surgery)			Time		Radiographic measurements (latest follow-up)			Pain (before surgery)		Pain (latest follow-up)	
		VI	UI	RUI	Distrac. (days)	Union (weeks)	VI	UI	RUI	RCJ	RUJ	RCJ	RUJ
1	28, M	6	-2	-6	9	11	9	16	2	++	++	-	-
2	14, M	10	4	-12	15	9	10	17	0	+	+++	+	++
3	36, M	-11	0	-7	8	12	3	21	-1	++	++	+	+
4	18, M	8	13	-16	19	13	8	19	0	++	+++	-	++
5	24, M	0	-5	-7	10	12	5	12	1	+++	++	+	+
6	27, M	2	8	-6	8	11	7	16	1	++	++	-	-
7	32, M	-3	7	-5	8	10	5	20	-2	++	++	++	-
8	30, FM	1	0	-6	8	9	7	15	1	+++	+++	+	++
9	23, M	2	12	-4	7	10	11	22	0	+	++	-	-

VI ; Volar Inclination (degrees), UI ; Ulnar Inclination (degrees), RUI ; Radioulnar Index (mm) (Negative value = radius shorter than ulna), RCJ : Radiocarpal Joint, RUJ ; Radioulnar joint.

- ; no pain at all, + ; mild pain, ++ ; moderate pain, +++ ; severe pain.

disadvantages. Darrach's procedure is one of the oldest, but it has significant complications such as carpal instability, decreased grasping strength, and painful instability of the distal ulnar stump. It is currently recommended only in cases where treatment by other methods is not possible (4, 6, 7, 9, 11, 12). In selected cases of painful instability of the distal radioulnar joint, the Sauvé-Kapandji procedure can be preferred. However, this technique is a salvage procedure, and we think that the Sauvé-Kapandji procedure, as well as the Darrach procedure, should not be considered as first choice.

Radial shortening is the most frequent cause of residual radioulnar joint problems after treatment for wrist deformity. The reason is usually insufficient radial distraction. The maximum lengthening that can be obtained in distal radius osteotomies is 6-7 mm (3). When greater lengthening is required, radius osteotomy alone is inadequate. In such cases, it must be combined with ulnar leveling ; however, this combined procedure is known to expose to a number of complications, including ulnar nonunion, radial nonunion, incomplete correction, pin tract infection and hardware failure, soft tissue problems and tendonitis, reflex sympathetic dystrophy, carpal tunnel syndrome, and residual problems in the distal radioulnar joint (2, 4,

5, 8). Furthermore, these procedures present technical difficulties. The osteotomy and callus distraction we performed allow the necessary length to be achieved with limited surgery, and are technically simple .

Classical osteotomies of the distal end of the radius require the planning and execution of 3-dimensional bone graft models (1, 11, 12). However, the exact calculation of the dimensions of the bone graft, the achievement of the appropriate dimensions, and proper execution are not always easy. Since we did not use bone grafts, there was no need for such complex planning. Moreover, no difficulties with union were observed in any of the patients.

In the literature, there are few cases in which malunion of the distal end of the radius was treated by osteotomy and callus distraction ; it has been reported that there is insufficient control of the distal fragment in this procedure (7). Displacement of the distal fragment occurred in six of our nine patients. This was completely corrected in two patients, but in the remaining four, the anatomic defects were not completely corrected even after a second manipulation. No detailed information is available on the reason for translation. However, loosening is a general problem with fixators which

have moving ball connectors. We think that the reason for translation of the distal fragment may be loosening in the external fixator module caused by the muscle pull during longitudinal traction. Although patients may have good clinical outcomes with osteotomy and callus distraction, it should be kept in mind that there may be problems in maintaining the distal fragment position throughout the distraction period.

### CONCLUSION

In the treatment of malunited fractures of the distal end of the radius with shortening of the radius, distraction osteotomy is a simple and effective method that does not require extensive dissection. However, during distraction and the waiting period, the position of the distal fragment should be well monitored until consolidation is achieved.

### REFERENCES

1. **Bilic R, Zdravkovic V, Baljevic Z.** Osteotomy for deformity of the radius. *J Bone Joint Surg* 1994 ; 76-B : 150-154
2. **Brown JN, Bell MJ.** Distal radial osteotomy for malunion of wrist fractures in young patients. *J Hand Surg* 1994 ; 19-B : 589-593
3. **Fernandez DL.** Radial osteotomy and Bowers arthroplasty for malunion of the distal end of the radius. *J Bone Joint Surg* 1988 ; 70-A : 1538-1551
4. **Flinkkila T, Raatikainen T, Kaarela O.** Corrective osteotomy for malunion of the distal radius. *Arch Orthop Trauma Surg* 2000 ; 120 : 123-126
5. **Hove LM, Engesaeter LB.** Corrective osteotomies after injuries of the distal radial physis in children. *J Hand Surg* 1997 ; 22-B : 699-704
6. **Kirk JL, Jupiter JB.** Intraarticular fractures of the distal end of the radius in young adults. *J Bone Joint Surg* 1986 ; 68-A : 647-659
7. **Ladd AL, Huene DS.** Reconstructive osteotomy for malunion of the distal radius. *Clin Orthop* 1996 ; 327 : 158-171
8. **Linder L, Stattin J.** Malunited fractures of the distal radius with volar angulation. *Acta Orthop Scand* 1996 ; 67 : 179-181
9. **Jupiter JB, Ring D.** A comparison of early and late reconstruction of malunited fractures of the distal end of the radius. *J Bone Joint Surg* 1996 ; 78-A : 739-748
10. **McQueen M, Caspers J.** Colles fracture : Does the anatomical result affect the final function ? *J Bone Joint Surg* 1988 ; 70-B : 694-651
11. **Oskam J, Bongers AJ, Karthaus AJM, Frima AJ, Klasen HJ.** Corrective osteotomy for malunion of the distal radius. *Arch Orthop Trauma Surg* 1996 ; 115 : 219-222
12. **Shea K, Fernandez DL, Jupiter JB, Martin C.** Corrective osteotomy for malunited, volarly displaced fractures of the distal end of the radius. *J Bone Joint Surg* 1997 ; 79-A : 1816-1826