



Primary hyperparathyroidism and pathological fractures : A review

Loek VERLAAN, Bart VAN DER WAL, Geert-Jan DE MAAT, Geert WALenkAMP, Lizette NOLLEN-LOPEZ, André VAN OOIJ

From the University Hospital Maastricht, Maastricht, The Netherlands

Primary hyperparathyroidism is due most often to a parathyroid adenoma secreting parathyroid hormone. Elevated PTH levels cause bone resorption, the formation of polyostotic lesions and a reduction in bone mineral density, predisposing to pathological fractures. The final stage of this disease is osteitis fibrosa cystica. The authors review the literature about osteitis fibrosa cystica and the treatment options when a pathologic fracture occurs.

Keywords : primary hyperparathyroidism ; pathological fractures.

INTRODUCTION

The incidence of untreated hyperparathyroidism has dramatically decreased (4). Primary hyperparathyroidism often was not diagnosed until patients developed symptoms and signs of advanced disease. Nowadays primary hyperparathyroidism is diagnosed in an early phase because of the routine use of multi-channel chemical blood screening. Primary hyperparathyroidism most often is due to a parathyroid adenoma that secretes parathyroid hormone (PTH). The severity of hypercalcemia is correlated with the size and weight of the responsible parathyroid adenoma (20). Due to elevated PTH levels bone resorption increases which causes polyostotic lesions of the bone and a reduction in bone mineral density (20). Osteitis fibrosa cystica eventually develops in patients with advanced stages of the disease (8, 12,

15, 16). Low density of bone and impaired bone quality predispose to a pathologic fracture. Patients often require parathyroidectomy as a definitive treatment (14, 25). The aim of this article is to review the literature about osteitis fibrosa cystica and the treatment options in case of a pathologic fracture.

ILLUSTRATIVE CASE

A 40-year-old Turkish male was admitted to the emergency department with acute pain in his left upper leg. The pain developed after rising from a chair. Radiographs of the pelvis (fig 2), right and left femur showed severe osteoporosis with multiple osteolytic bone lesions and an undisplaced pathological fracture through a markedly destructive cystic lesion of the distal femur (fig 1). For a year this patient had been suffering of fatigue and

-
- Loek Verlaan, MD, Intern in Orthopaedic Surgery.
 - Bart van der Wal, MD, Resident in Orthopaedic Surgery.
 - Geert-Jan de Maat, MD, Resident in Orthopaedic Surgery.
 - Geert Walenkamp, MD, PhD, Orthopaedic Surgeon.
 - André van Ooij, MD, PhD, Orthopaedic Surgeon.
 - Lizette Nollen-Lopez, MD, PhD, Resident in Pathology.
- University Hospital Maastricht, Maastricht, The Netherlands.*

Correspondence : Bart C.H. van der Wal, Department of Orthopaedic Surgery, University Hospital Maastricht, P.O. Box 5800, 6202 AZ Maastricht, The Netherlands.

E-mail : bchvanderwal@yahoo.com.

© 2007, Acta Orthopædica Belgica.

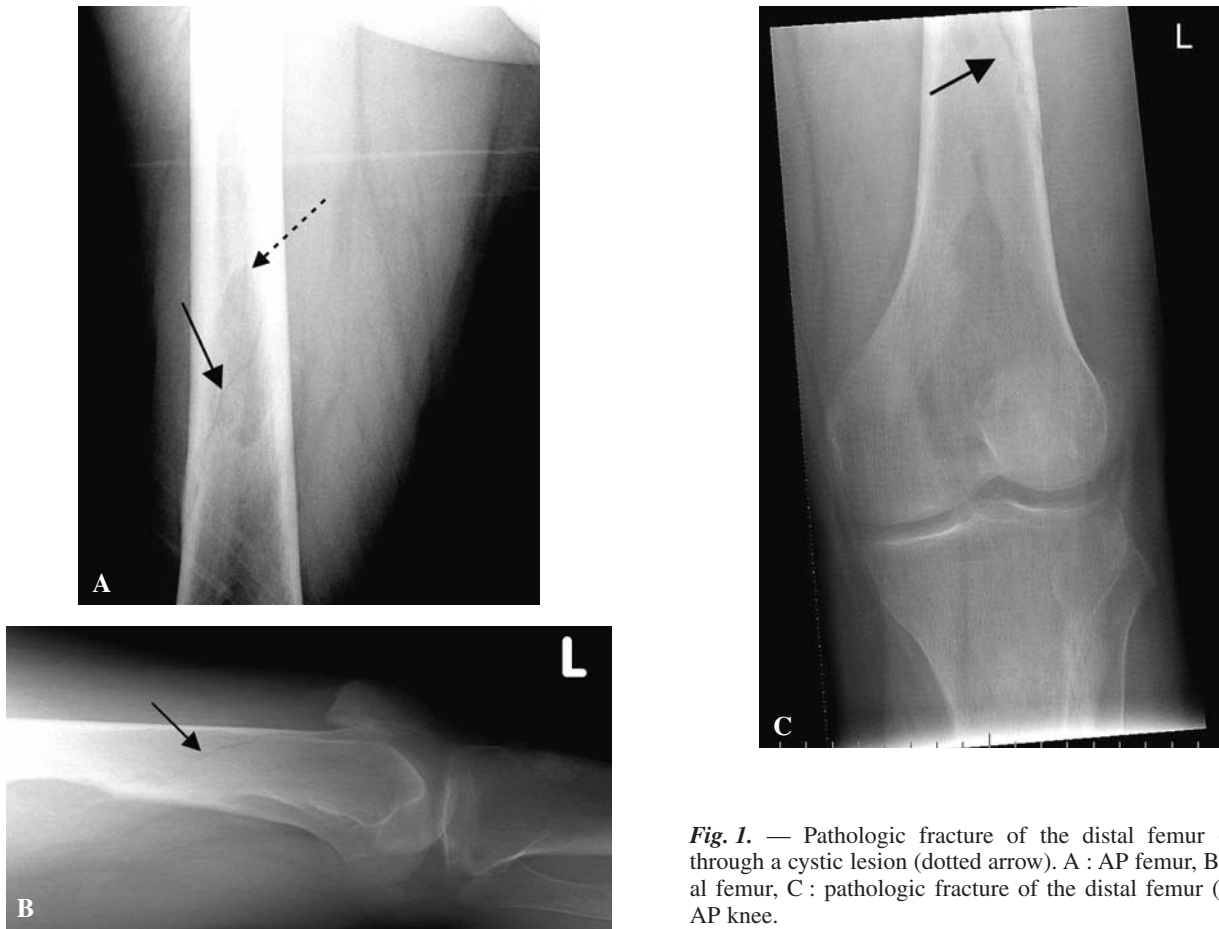


Fig. 1. — Pathologic fracture of the distal femur (arrow) through a cystic lesion (dotted arrow). A : AP femur, B : lateral femur, C : pathologic fracture of the distal femur (arrow), AP knee.

muscle pain in his thighs, increased snoring, sweating, thirst and polyuria.

Physical examination also revealed a painful tumour in the right mandible (fig 3) and a tumour in the right proximal tibia (fig 4).

The serum level of calcium was elevated (3.09 mmol/l : normal range 2.10-2.55 mmol/l), as well as the values for alkaline phosphatase (569 U/l : normal range < 125 U/l) and intact-PTH (62 pmol/l : normal range 2-7 pmol/l), whereas the level of 25 (OH) vitamin D was decreased (14 nmol/l : normal range 20-100 nmol/l), indicative for hyperparathyroidism.

Technetium bone scanning demonstrated increased uptake in multiple areas of the skeleton interpreted as a result of a metabolic disease. The initial differential diagnosis included hyperparathyroidism with brown tumours, fibrous dysplasia, as well as metastases of unknown origin.

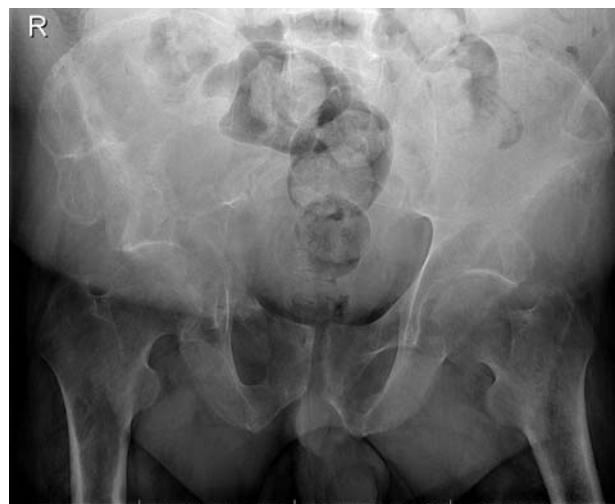

Fig. 2. — Osteopenia of the pelvis especially of the right acetabulum.

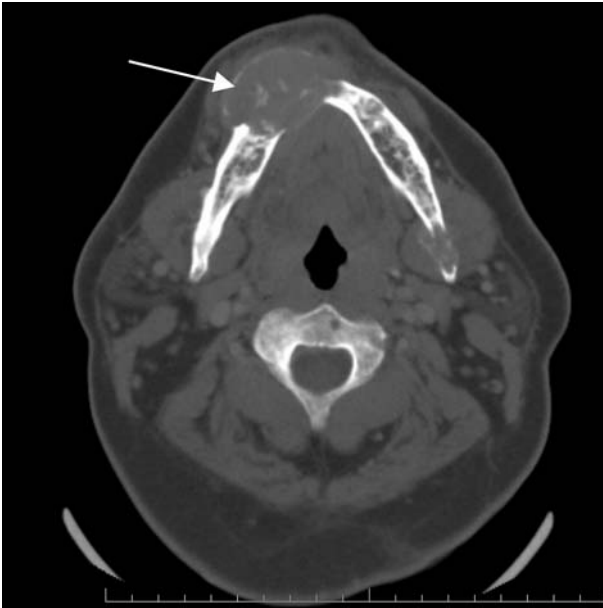


Fig. 3. — CT scan of the jaw shows multiple tumours with a remarkably large tumour in the right mandible.

Because the fracture of the distal femur was not displaced, treatment was conservative and his leg was immobilised in a long leg cast. Weight bearing was not allowed for 6 weeks and bed rest was prescribed. A biopsy of the right proximal tibia was performed (fig 5). Histopathological findings were typical for brown tumour.

Ultrasound of the neck and a sestamibi scan confirmed the diagnosis of an adenoma of the left inferior lobe of the parathyroid gland. After a left parathyroidectomy hypercalcaemia persisted and at a second operation two other adenomas on the right hand side were removed. Histopathology confirmed the diagnosis of adenomas of the parathyroid glands.

After the last operation the patient developed hypocalcaemia, in association with a so called hungry bone syndrome. Calcium- and $1,25(\text{OH})_2$ vitamin D was supplemented intravenously. Three months after admittance the patient is still on medication and will probably have to be supplemented life long with Calcium and Vitamin D.

The distal femoral fracture united in 3 months (fig 6) and full weight bearing was allowed. The

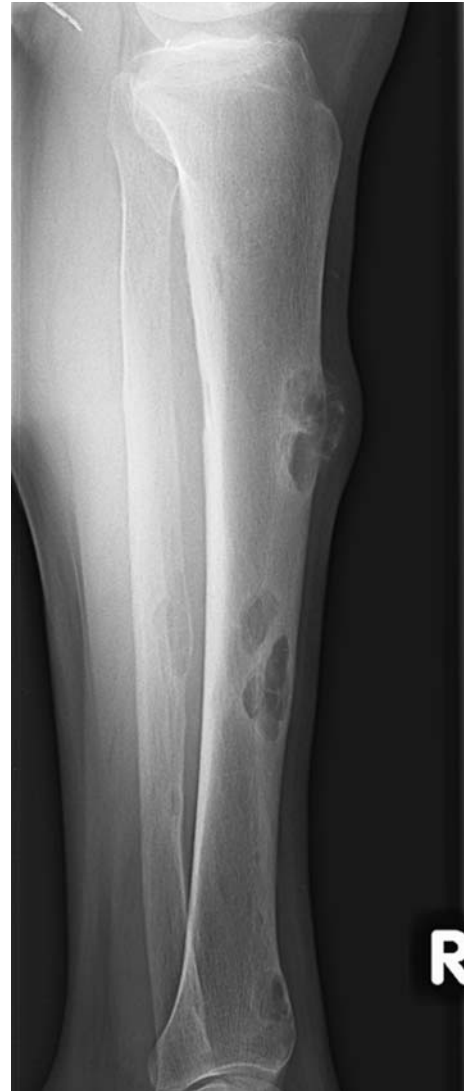

Fig. 4. — Osteolytic lesions of the right tibia.

pain in his right mandible had resolved and his teeth remained well fixed.

A DEXA scan (L2-L4 lumbar spine and right femur) was performed to obtain a baseline value of the bone density for future follow-up. The DEXA scan showed osteoporosis according to the WHO guidelines (26).

DISCUSSION

Primary hyperparathyroidism is rare. The prevalence rate varies from 1‰ to 4‰, with a

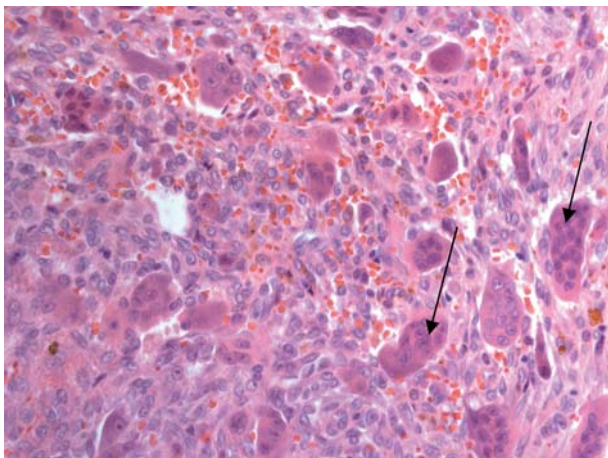


Fig. 5. — Brown tumour (haematoxylin and eosin $\times 40$). Biopsy of the lesion revealed clusters of multinucleated osteoclast-like giant cells, within proliferating fibroblasts (see arrows). Interstitial haemorrhages marked by haemosiderin deposition were present within the fibrous tissue. Extreme osteoclastic resorption and some bone production were observed near the borders of the conglomerates. Mitotic activity was rare. There was no evidence for malignancy. These histopathological findings were typical for brown tumour.

female:male ratio of 3:1 (7). In 80% of cases the cause is a solitary adenoma and in 20% a glandular hyperplasia (28). Serum calcium, ionised calcium and PTH levels should be obtained to diagnose hyperparathyroidism.

Singhal *et al* (23) reported that 5-15% of patients with primary hyperparathyroidism have associated bony abnormalities. Radiological examination reveals osteopenia of the entire skeleton and multiple localised lytic lesions with a benign aspect. Hyperparathyroidism affects mainly cortical bone, and not cancellous bone (19).

The incidence of brown tumours in patients with primary hyperparathyroidism is 1.5% to 1.7% (28). Nowadays hyperparathyroidism is usually treated before such lesions develop; therefore they have become extremely rare. Clinically, brown tumours most often manifest as slowly growing, painful masses. These tumours can behave aggressively and become destructive, as a consequence of high osteoclastic activity (7, 16). Histologically, brown tumours are characterised by numerous giant cells, diffuse or arranged in clusters. Brown tumours

may be indistinguishable from giant cell tumours of bone, and correlation with clinical and radiographical data is essential in making the correct diagnosis (28).

Brown tumours represent foci of haemorrhage within an enlarged fibrotic marrow space. Organisation of these lesions results in the release of haemosiderin and the accumulation of macrophages, fibroblasts and giant cells. Osteitis fibrosa cystica may be mistaken for neoplastic metastatic disease (2, 10, 12, 15, 21, 24). Patients who do develop symptoms of primary hyperparathyroidism should undergo surgical treatment (25).

The fracture in our case of a 40-year-old man was treated conservatively because there was no displacement of the fracture. Curettage, bone grafting and prophylactic stabilisation may be required, in case of persistent symptomatic bone lesions or pathological fractures in patients with primary hyperparathyroidism (9, 23). However, the literature does not provide guidelines to know which patients suffering from osteitis fibrosa cystica cases need prophylactic stabilisation. To control hyperparathyroidism with the presence of brown tumours, parathyroidectomy is the treatment of choice. Normalisation of parathyroid function should lead to a reduction in size or disappearance of the tumour (27). Destructive skeletal lesions, as in our case, heal within 6 months after the excision of a parathyroid adenoma (1, 6, 12). Brown tumours occasionally affect the jaws. Four weeks after parathyroidectomy our patient noted that the tumour in his right mandible had decreased in size and his teeth were well fixed. For a year this patient was not allowed to eat solid food because of the large cyst, which can easily fracture the jaw.

Several reports advocate resection of any remaining brown tumours after the hyper-parathyroid function has resolved (3, 5, 11, 13, 17). Spontaneous tumour involution of the jaw lesion made additional surgery unnecessary.

In about half of the cases primary hyperparathyroidism with multiple parathyroid adenomas is part of a familial syndrome (1). The family history for hyperparathyroidism was negative in our patient. After successful parathyroidectomy for primary hyperparathyroidism bone mass density (BMD)

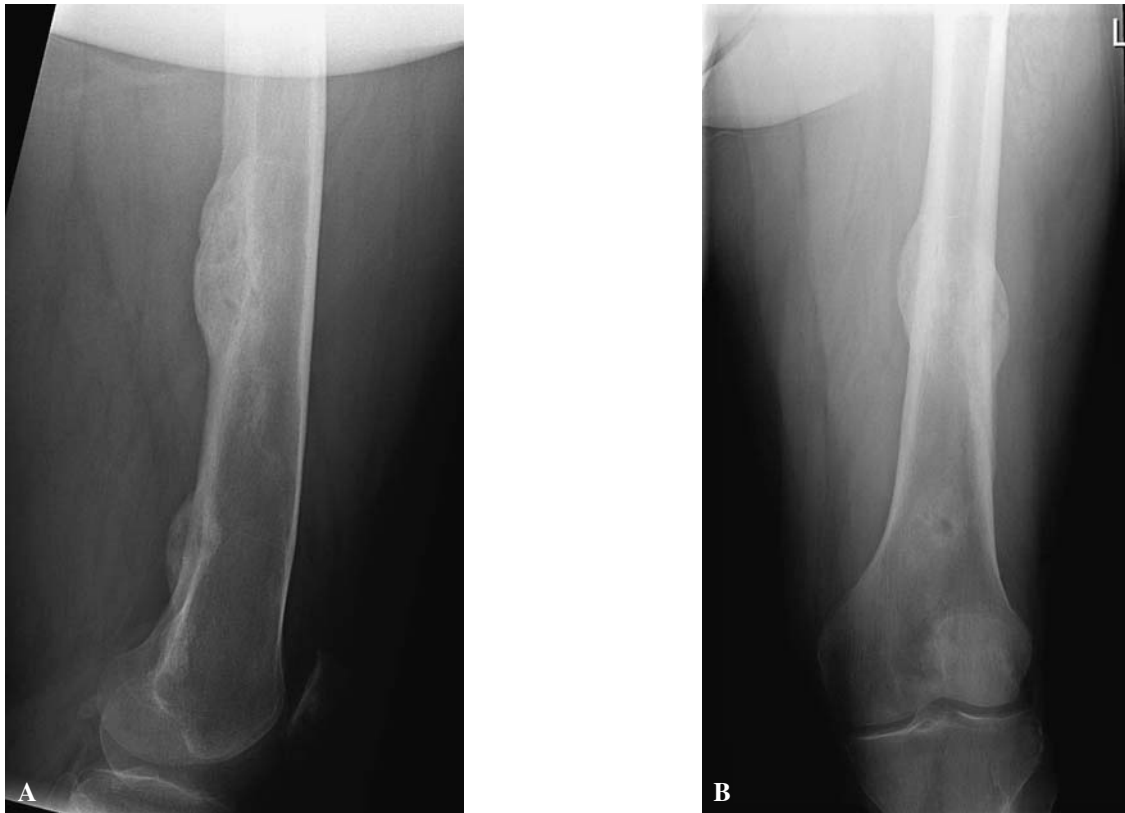

Fig. 6. — Healing of the distal fracture of the left femur (lateral and AP)

might increase by as much as 10% one year after surgery (18). The DEXA scan in our patient showed osteoporosis and long term follow-up may be necessary to adequately monitor this patient, because it is well-known that increase in BMD might go on for up to 4 years (8, 22). After parathyroidectomy the serum level of PTH falls dramatically as the unaffected glands have been suppressed by hypercalcaemia. Consequently, the PTH-induced osteoclastic bone resorption stops, whilst the osteoblastic activity continues resulting in a marked increase in bone uptake of calcium and phosphate (the so called hungry bone syndrome) demanding for Calcium en Vitamin D.

In conclusion, in a patient presenting with a pathologic fracture, routine serum calcium should be obtained. In case of symptomatic primary hyperparathyroidism and a pathological fracture, patients require parathyroidectomy, while fracture

treatment can be conservative if undisplaced and uncomplicated.

REFERENCES

1. al Zahrani A, Levine MA. Primary hyperparathyroidism. *Lancet* 1997 ; 349 : 1233-1238.
2. Bassler T, Wong ET, Brynes RK. Osteitis fibrosa cystica simulating metastatic tumor. An almost-forgotten relationship. *Am J Clin Pathol* 1993 ; 100 : 697-700.
3. Bedard CH, Nichols RD. Osteitis fibrosa (brown tumor) of the maxilla. *Laryngoscope* 1974 ; 84 : 2093-2100.
4. Chen H, Parkerson S, Udelsman R. Parathyroidectomy in the elderly : do the benefits outweigh the risks? *World J Surg* 1998 ; 22 : 531-535, discussion 535-536.
5. Dusunsel R, Guney E, de Gunduz Z *et al.* Maxillary brown tumor caused by secondary hyperparathyroidism in a boy. *Pediatr Nephrol* 2000 ; 14 : 529-530.
6. Grey AB. The skeletal effects of primary hyperparathyroidism. *Baillieres Clin Endocrinol Metab* 1997 ; 11 : 101-116.

7. **Heath DA.** Primary hyperparathyroidism. Clinical presentation and factors influencing clinical management. *Endocrinol Metab Clin North Am* 1989 ; 18 : 631-646.
8. **Heath H.** Primary hyperparathyroidism, hyperparathyroid bone disease, and osteoporosis. In : Marcus R, Feldman D, Kelsey J (eds), *Osteoporosis*. Academic Press, San Diego, 1995 : pp 885-897.
9. **Hsieh MC, Ko JY, Eng HL.** Pathologic fracture of the distal femur in osteitis fibrosa cystica simulating metastatic disease. *Arch Orthop Trauma Surg* 2004 ; 124 : 498-501.
10. **Joyce JM, Idea RJ, Grossman SJ et al.** Multiple brown tumors in unsuspected primary hyperparathyroidism mimicking metastatic disease on radiograph and bone scan. *Clin Nucl Med* 1994 ; 19 : 630-635.
11. **Keyser JS, Postma GN.** Brown tumor of the mandible. *Am J Otolaryngol* 1996 ; 17 : 407-410.
12. **Kocher MS, Gebhardt MC, Jaramillo D, Perez-Atayde AR.** Multiple lytic skeletal lesions and hypercalcemia in a 13-year-old girl. *Clin Orthop* 2000 ; 374 : 298-302, 317-319.
13. **Krause I, Eisenstein B, Davidovits M et al.** Maxillo-mandibular brown tumor : a rare complication of chronic renal failure. *Pediatr Nephrol* 2000 ; 14 : 499-501.
14. **Lenchik L, Sartoris DJ.** Orthopedic aspects of metabolic bone disease. *Orthop Clin North Am* 1998 ; 29 : 103-134.
15. **Lewis MM, O'Connell JX.** Case records of the Massachusetts General Hospital. Weekly clinicopathological exercises. Case 14-1993. A 74-year-old woman with hyperparathyroidism and an osteolytic lesion in the humerus. *N Engl J Med* 1993 ; 328 : 1031-1035.
16. **Mankin HJ.** Metabolic bone disease. *Instr Course Lect* 1995 ; 44 : 3-29.
17. **Martinez-Gavidia EM, Bagan JV, Milian-Masanet MA et al.** Highly aggressive brown tumour of the maxilla as first manifestation of primary hyperparathyroidism. *Int J Oral Maxillofac Surg* 2000 ; 29 : 447-449.
18. **Nakaoka D, Sugimoto T, Kobayashi T et al.** Prediction of bone mass change after parathyroidectomy in patients with primary hyperparathyroidism. *J Clin Endocrinol Metab* 2000 ; 85 : 1901-1907.
19. **Parisien M, Mellish RW, Silverberg SJ et al.** Maintenance of cancellous bone connectivity in primary hyperparathyroidism : trabecular strut analysis. *J Bone Miner Res* 1992 ; 7 : 913-919.
20. **Rubin E, Farber J.** *Pathology*, 3rd ed, Lippincott Williams & Wilkins, 1999.
21. **Rubin MR, Livolsi VA, Bandeira F et al.** Tc99m-sestamibi uptake in osteitis fibrosa cystica simulating metastatic bone disease. *J Clin Endocrinol Metab* 2001 ; 86 : 5138-5141.
22. **Silverberg SJ, Gartenberg F, Jacobs TP et al.** Increased bone mineral density after parathyroidectomy in primary hyperparathyroidism. *J Clin Endocrinol Metab* 1995 ; 80 : 729-734.
23. **Singhal S, Johnson CA, Udelsman R.** Primary hyperparathyroidism : what every orthopedic surgeon should know. *Orthopedics* 2001 ; 24 : 1003-1009, quiz 1010-1011.
24. **Teng CT, Nathan MH.** Primary hyperparathyroidism. *Am J Roentgenol Radium Ther Nucl Med* 1960 ; 83 : 716-731.
25. **Utiger RD.** Treatment of primary hyperparathyroidism. *N Engl J Med* 1999 ; 341 : 1301-1302.
26. WHO Study Group, G., (1994).
27. **Yamazaki H, Ota Y, Aoki T, Karakida K.** Brown tumor of the maxilla and mandible : progressive mandibular brown tumor after removal of parathyroid adenoma. *J Oral Maxillofac Surg* 2003 ; 61 : 719-722.
28. **Yilmazlar S, Arslan E, Aksoy K, Tolunay S.** Sellar-parasellar brown tumor : case report and review of literature. *Skull Base* 2004 ; 14 : 163-168.