



Solitary eosinophilic granuloma of the radius An unusual differential diagnosis

Manish CHADHA, Anil AGARWAL, Nidhi AGARWAL, Manoj Kumar SINGH

From the University College of Medical Sciences and Guru Teg Bahadur Hospital, Delhi, India

A case of an 11-year-old patient with a lesion in the proximal metaphyseo-diaphyseal region of the right radius is presented. The clinico-radiological suspicion was either infection or tumour of the proximal radius. Subsequently, a biopsy proved the lesion to be an eosinophilic granuloma of bone. Following curettage and after a follow-up of two years, there was complete resolution of the lesion with restitution of the cortex.

Keywords : eosinophilic granuloma ; radius ; tumour ; osteomyelitis.

INTRODUCTION

Eosinophilic granuloma (EG) of bone is the most common skeletal manifestation of a spectrum of diseases broadly known as histiocytosis X. The term histiocytosis X incorporates the multiple organ involvement in disseminated Hand Schuller Christian disease and the acute and the fulminant form, Letterer-Siwe disease. Neither the clinical nor the radiographic presentation of EG is specific, and the diagnosis poses a dilemma to the orthopaedic surgeon (1, 2).

The commonest differential diagnosis made in an adolescent patient with a relatively short history of severe bone pain and bony tenderness in the metaphyseo-diaphyseal region of a long bone is either infection or tumour. Newer investigation modalities like computed tomography (CT) and magnetic resonance imaging (MRI) help in evalu-

ating the extent of the lesion but the diagnosis can only be confirmed by histopathology.

CASE REPORT

An 11-year-old patient presented to the outpatient department with a history of pain over the right forearm for the past 6 weeks. There was no history of trauma or any associated constitutional symptoms. The child had not taken any treatment except occasional analgesics.

On examination, he was afebrile, with marked local tenderness over the proximal third of the radius. There was no enlargement of regional lymph nodes. The local temperature was not raised and there was no significant local swelling.

■ Manish Chadha, MS (Ortho.), Reader.

Department of Orthopaedics, University College of Medical Sciences and Guru Teg Bahadur Hospital, Shahdara, Delhi, India.

■ Anil Agarwal, MS (Ortho.), Specialist.

Department of Orthopaedics, Chacha Nehru Bal Chikitsalaya, Geeta Colony, Delhi, India.

■ Nidhi Aggarwal, MD (Patho.) Senior Resident.

■ Manoj Kumar Singh, MD (Patho.) Professor.

Department of Pathology, All India Institute of Medical Sciences, Ansari Nagar, Delhi, India.

Correspondence : Manish Chadha, C-A/16, Tagore Garden, New Delhi-110027, India. E-mail : mchadha@hotmail.com.

© 2007, Acta Orthopædica Belgica.

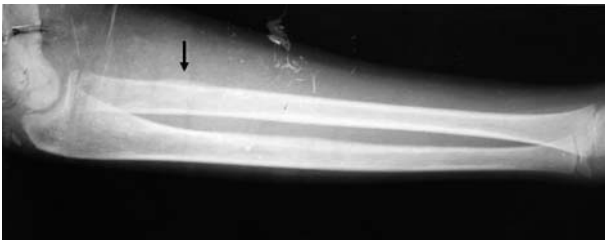


Fig. 1. — Plain radiograph of the right proximal forearm revealing a minimal periosteal reaction (black arrow) in the radius.

Plain radiographs of the right proximal forearm revealed a minimal periosteal reaction in the radius with no lesion in the bone (fig 1). Subsequently a CT-scan performed to delineate the lesion further showed destruction of the cortex of the proximal metaphyseal-diaphyseal region of the right radius with an associated periosteal reaction (fig 2).

A provisional diagnosis of a subacute osteomyelitis or a Ewing's sarcoma was made. A contrast MRI done for evaluation of soft tissue involvement only showed some soft tissue oedema (fig 3).

The patient was taken up for an open biopsy using Thompson's approach. Intraoperatively there was no pus. There was cortical thickening in the region of the radial tuberosity, corresponding to the area of bony destruction on CT. A window was made in the region and a grayish tissue resembling granulation tissue was curetted from the lesion and sent for Gram staining, culture, polymerase chain reaction (PCR) test for *Mycobacterium Tuberculosis* and histopathology. Gram staining, bacterial culture and PCR were found to be negative.

Histologically, a low-power view showed numerous eosinophils, lymphocytes and Langerhans cell histiocytes. A high-power microphotograph (fig 4) showed Langerhans cells with grooved nuclei, mixed with eosinophils, suggestive of eosinophilic granuloma (EG). There were no signs of infection or granulomas. Immunohistochemical stains S100 (fig 5) were performed, confirming the diagnosis.

To look for other lesions, a skeletal survey, an ultrasonography of the abdomen and a bone scan were performed. These investigations did not reveal any other focus of disease and the diagnosis

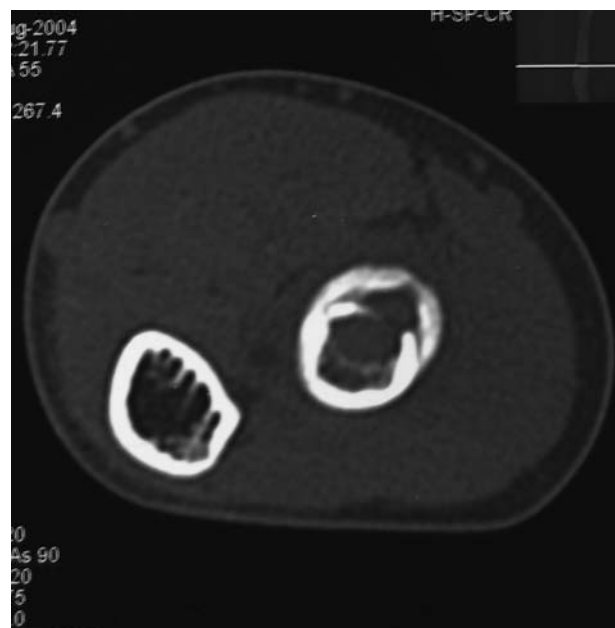
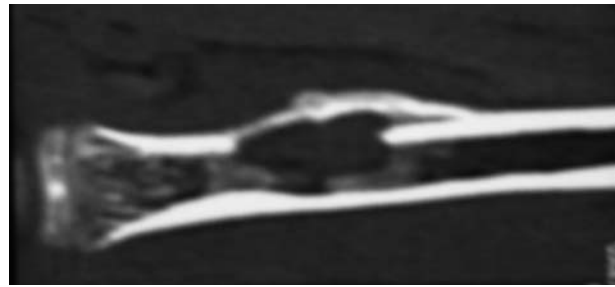


Fig. 2. — CT scan of the forearm revealed destruction of the cortex of the proximal metaphyseal-diaphyseal region of the radius with an associated periosteal reaction.

of an isolated EG of the radius was made and the patient was kept under observation. An above-elbow plaster of Paris cast was maintained for a period of 8 weeks to prevent a pathological fracture. Thereafter active mobilisation of the elbow was initiated.

The child's symptoms gradually improved and subsequent radiographic films showed progressive healing of the lesion. The child was clinically asymptomatic with no local pain or tenderness and had resumed all activities when followed at two years. Plain radiographs and CT scans obtained at this time showed complete resolution of the lesion with reconstitution of the cortex (fig 6, 7).

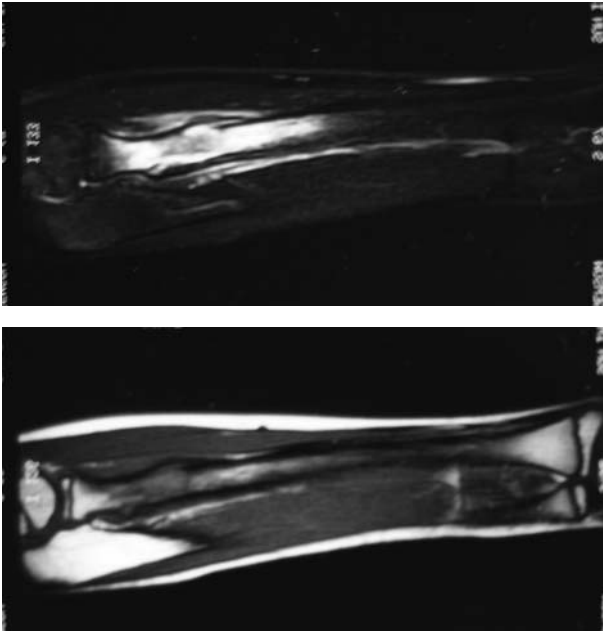


Fig. 3. — A contrast MRI showed normal soft tissues with oedema.

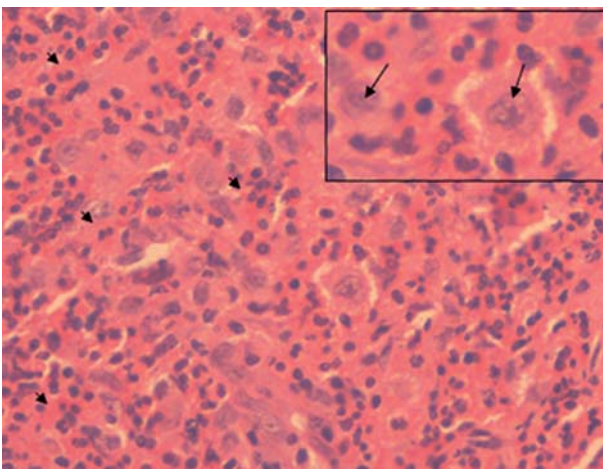


Fig. 4. — Photomicrograph (haematoxylin and eosin ; magnification, $\times 20$).

DISCUSSION

Solitary EG of bone is the commonest manifestation of histiocytosis (60 to 80% cases) (1). The hallmark of histiocytosis X is the Langerhans cell, a histiocyte with characteristic racquet shaped Birbeck granules visible on electron microscopy.

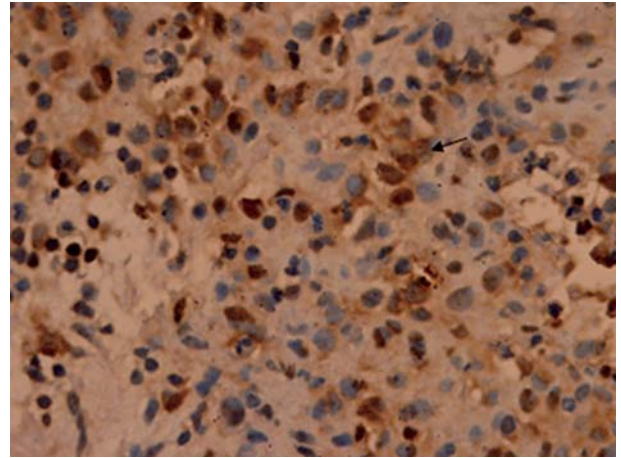


Fig. 5. — Nuclear positivity of S100 protein in Langerhans' cells (arrow) (immunostaining, LSAB technique, $40\times$).

The pathogenesis of EG is not completely understood. Infections, immune and neoplastic causes have been postulated (1). Up to 80% of histiocytosis X lesions in children are of solitary EG type and up to 90% occur in children (1).

The usual sites of bony involvement include the skull (34%), spine (15%), ribs (7%) and long bones (15%), although almost any bone may be affected (2). In the long bones, the diaphysis is most commonly affected (58%), followed by the metaphysis (2). The presenting symptoms of the disease are variable and non-specific. The patient may complain of pain, localized swelling depending upon the region involved and sometimes a pathological fracture. At other times, EG is discovered incidentally while screening for other medical problems (ultrasonography of the abdomen) or in traumatic conditions (e.g. head injury) (9).

The physical examination of the child may be essentially normal. Laboratory findings are usually non-specific except for a moderate and inconsistent rise in erythrocyte sedimentation rate.

The characteristic radiographic finding described for EG involvement of long bones is a lytic medullary based lesion (7). In the acute phase, lesions appear rapidly, perhaps in a few weeks, and are aggressive looking with poorly defined margins (1). The radiological diagnosis is difficult to differentiate from infection or Ewing's sarcoma at

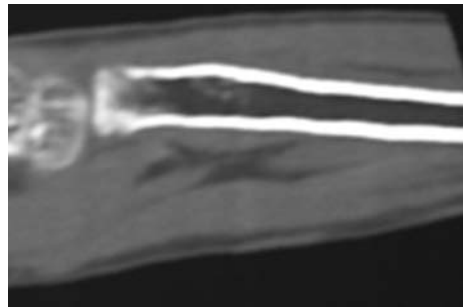
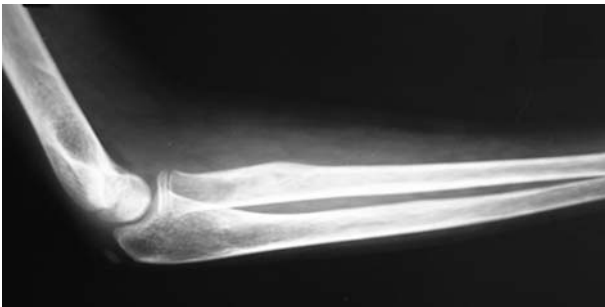

Fig. 6 & 7. — Follow-up 2 years after curettage and biopsy : Plain radiographs and CT scans show complete resolution of the lesion with reconstitution of the cortex.

this time (5). This may either regress to a well-defined lesion with sclerotic scalloping, cortical erosion, periosteal reaction (single or laminated ‘onion peel’ appearance) and soft tissue involvement (5). If a pathological fracture occurs, the radiographic findings become even more confusing.

A child suspected of having EG should be carefully investigated for the presence of other stigmata of histiocytosis. Most investigators recognize the poor reliability of bone scintigraphy (7, 9). Parker *et al* reported that only 35% of lesions are visible on a bone scan (7). CT or MRI is useful in evaluating soft tissue involvement which is normally moderate or absent in EG (2). MRI is very well suited for demonstrating bone marrow involvement and accompanying soft tissue mass or inflammation in EG of bone. Although MRI is very sensitive, the findings remain non-specific (1). Biopsy remains the key to diagnosis in EG. Further confirmation is possible using immunohistochemical staining such as S100, cluster of differentiation 1 (CD-1), or monoclonal antibody OKT6 and electron microscopy (9).

The treatment of EG is equally controversial with different therapeutic approaches claiming effectiveness. Solitary EG of bone has been shown to undergo spontaneous remission (6). Symptomatic surgically accessible solitary EG are managed by biopsy, curettage and bone grafting if needed (9). A single curettage usually results in healing (9). Local injection of corticosteroids was described by Scaglietti *et al*, with immediate pain relief and healing response within 2 months after injection (8). Irradiation is rarely used because of reports of late latent neoplasms (4). The use of chemothera-

py and oral corticosteroids alone or combined is indicated in systemic disease but rarely in a solitary lesion due to unpredictable results obtained and the toxic and oncogenic risk (3).

It has been stated that patients with unifocal EG, who subsequently develop additional lesions, usually do so within 6 months after appearance of the initial lesion (2). Other favourable prognostic factors are age greater than 2 years, absence of pulmonary, hepatic, haemopoietic lesions or multiple bony involvement (2).

Histiocytosis X with its confusing nomenclature, unknown aetiology, non-specific clinical and imaging findings with diagnosis possible only on histopathological examination, will always pose a diagnostic challenge to the orthopaedic surgeon. We conclude with a single message. Suspect it, lest you will miss it.

REFERENCES

1. Azouz EM, Saigal G, Rodriguez MM, Podda A. Langerhans' cell histiocytosis : pathology, imaging and treatment of skeletal involvement. *Pediatr Radiol* 2005 ; 35 : 103-115.
2. Bollini G, Joure JL, Gentet JC, Jacquemier M *et al*. Bone lesions in histiocytosis X. *J Pediatr Orthop* 1991 ; 11 : 469-477.
3. De Camargo OP, De Oliveira NR, Andrade JS *et al*. Eosinophilic granuloma of the ischium : Long-term evaluation of a patient treated with steroids. *J Bone Joint Surg* 1992 ; 74-A : 445-447.
4. Egeler RM, Neglia JP, Puccetti DM, Brennan CA *et al*. Association of Langerhans cell histiocytosis with malignant neoplasm. *Cancer* 1993 ; 71 : 865-873.

5. **McCullough CJ.** Eosinophilic granuloma of bone. *Acta Orthop Scand* 1980 ; 51 : 389-398.
6. **Muscolo DL, Scullitel G, Ranalletta M et al.** Spontaneous remission of massive solitary eosinophilic granuloma of the femur. *J Pediatr Orthop* 2003 ; 23 : 763-765.
7. **Parker BR, Pinckney L, Etcubanas E.** Relative efficacy of radiographic and radionuclide bone surveys in the detection of skeletal lesions of histiocytosis X. *Radiology* 1980 ; 134 : 377-380.
8. **Scaglietti O, Marchetti PG, Bartolozzi P.** Final results obtained in the treatment of bone cysts with methylprednisolone acetate (Depo-Medrol) and a discussion of results achieved in other bone lesions. *Clin Orthop* 1982 ; 165 : 33-42.
9. **Sessa S, Sommelet D, Lascombes P et al.** Treatment of Langerhans – cell histiocytosis in children. *J Bone Joint Surg* 1994 ; 76-A : 1513-1525.