



Paradoxical fat embolism after uncemented total hip arthroplasty : A case report

Emmanuel THIENPONT, Samir KADDAR, Stuart MORRISON

From the Hôpital Français – Université Libre de Bruxelles, Brussels, Belgium

The authors report a paradoxical presentation of fat embolism after uncemented total hip arthroplasty. The patient presented vertigo and diplopia after surgery. Cerebral fat embolism was diagnosed by MRI.

A patent foramen ovale was responsible for the venous to arterial circulation shunt. Treatment was conservative. Spontaneous and complete recovery occurred.

Keywords : cerebral fat embolism ; patent foramen ovale ; uncemented hip arthroplasty.

INTRODUCTION

Perioperative fat embolisation occurs frequently in arthroplasty and intramedullary nailing (1-6). Opening the medullary canal in total knee and hip arthroplasty is already sufficient to observe intravasation of fat and marrow elements (2, 4). In total hip arthroplasty other technical aspects contribute to fat embolisation (2, 4). The more important factors are reaming of the proximal femur and acetabulum, impaction of press fit components or cementation under pressure (2-4). Fat emboli are usually absorbed by the filter of the lungs, which may result in hypotension, hypoxaemia, Acute Respiratory Distress syndrome, confusion, coma, cardiac arrest and even death (1, 2, 4). Paradoxical embolisation occurs when emboli pass from the right to the left side of the heart either through a patent foramen ovale or the pulmonary capillaries (1, 3, 5, 6).

The authors report a case of cerebral fat embolism through a patent foramen ovale causing postoperative diplopia and vertigo after uncemented total hip arthroplasty.

CASE REPORT

A 76-year-old male patient presented with clinically and radiographically end-stage osteoarthritis of the right hip. He had a history of bladder cancer with a curative resection and Bricker reconstruction. He received a cemented total hip arthroplasty on the left side six years previously. Because of untractable pain, surgery on the right hip was now scheduled.

Under spinal anaesthesia and endocarditis prophylaxis, total hip arthroplasty was performed in the left lateral decubitus position. An anterolateral approach was used. After adequate reaming of the acetabulum, an uncemented press fit cup with a

-
- Emmanuel Thienpont, MD, Orthopedic Surgeon.
 - Samir Kaddar, MD, Anaesthesiologist.
 - Stuart Morrison, MD, Anaesthesiologist.

Departments of Orthopaedic Surgery and Anaesthesiology, Hôpital Français – ULB, Brussels, Belgium.

Correspondence : Emmanuel Thienpont, Hôpital Français – ULB Hospital, Av. Josse Goffin 180, 1082 Brussels, Belgium.
E-mail : ethienpont@yahoo.com.

© 2007, Acta Orthopædica Belgica.

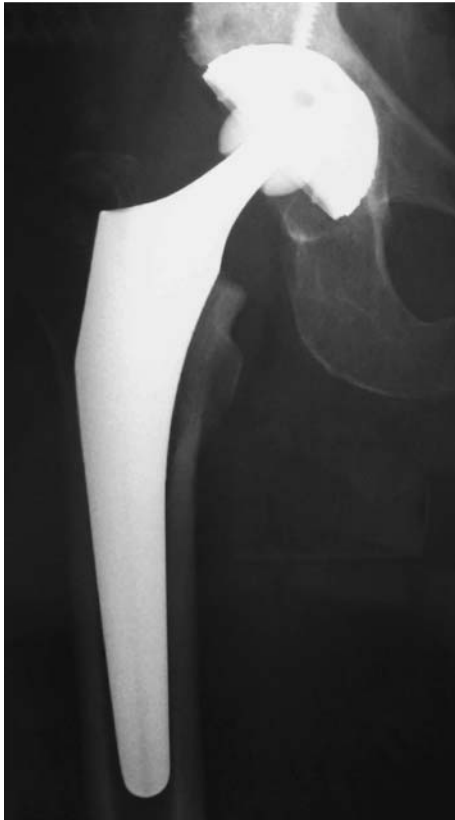

Fig. 1. — Uncemented total hip arthroplasty

compression screw was implanted. A hydroxyapatite coated femoral stem was introduced with correct anteversion. A ceramic 28 mm head with neutral neck length was used. Excellent range of motion and stability was obtained.

When the patient started weight bearing two days after surgery, he noted vertigo but especially diplopia. Initially, this was attributed to possible anaemia or an effect of the anaesthetic drugs. The postoperative haemoglobin level was 11.3 g/dl without transfusion and a web search of possible side effects of all the drugs used excluded both these causes.

As the symptoms persisted, a neurology consultation was organised and an MRI of the brain scheduled. The MRI clearly showed fat emboli (fig 3).

It was then noted that the preoperative cardiology report indeed mentioned a patent foramen ovale, which was the reason for the endocarditis prophylaxis.

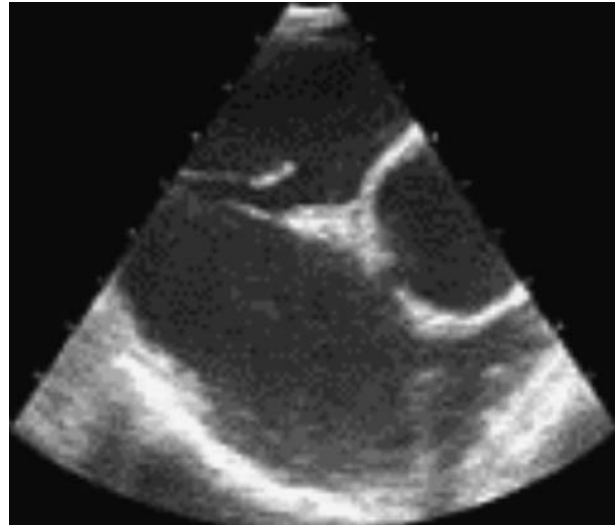


Fig. 2. — Patent Foramen Ovale

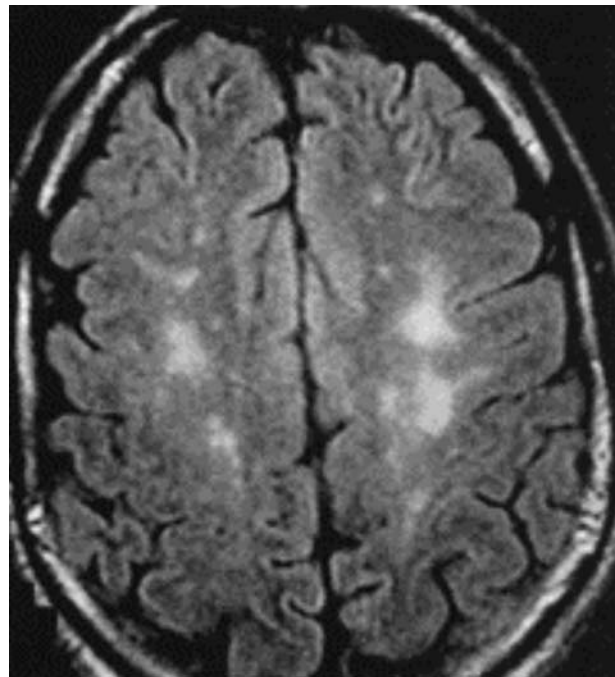


Fig. 3. — MRI of the brain showing fat emboli

Conservative treatment with aspirin was prescribed. A clinical evaluation showed diplopia and vertigo still present, but less prominent at the three months follow-up. Spontaneous and complete recovery was observed after 6 months.

DISCUSSION

Bone marrow and fat embolisation is very frequent during knee and hip arthroplasty (1-4, 6). It is considered to be more frequent after cemented hip arthroplasty (2-4). Preparation of the bone at the acetabulum and femur releases marrow elements into the venous circulation; at the femur, this occurs at the linea aspera or the distal metaphyseal area (2, 4). Usually these fat emboli are absorbed in the right heart and the pulmonary circulation (2-4). The worst case scenario would be to induce an Acute Respiratory Distress Syndrome (ARDS) or sudden death (2-4). An embolism occurring on the arterial side of the circulation is called a paradoxical embolisation (2, 3). This bypass of the lungs may cause cerebral emboli resulting in neurological symptoms, coma or end with fatal results (1-3, 6). A venous to arterial bypass of the circulation is possible when a patent foramen ovale is present (5). This condition is not very rare (5). Twenty-seven percent of the general population reportedly presents this pathology at autopsy, and fifteen percent when examined with contrast transthoracic echocardiography (5).

A patent foramen ovale has no clinical symptoms or abnormalities during auscultation (5). Transoesophageal contrast echocardiography is the recommended examination (5, 9). A bolus of agitated saline is injected in a vein and microbubbles will appear in the right atrium. If within three cardiac cycles the microbubbles appear in the left atrium the test is positive (5, 9). Diagnosis of cerebral embolism is based on clinical neurological examination and MRI (7, 8). CT scan is usually negative (7, 8, 10). If cerebral embolism is suspected early on, transcranial Doppler can even be performed during surgery (6, 9).

Takahashi *et al* (10) characterised the lesions on MRI after cerebral fat embolism as high-intensity signals in the deep white matter on T2-weighted images and graded them into four categories according to the severity of the brain lesions. These authors also showed that resolution of the high-intensity MRI lesions paralleled neurologic recovery (10).

Spinal anaesthesia could increase the risk of right to left shunting by altering the circulatory volumes and the arterial and venous pressures secondary to vasoplegia. In contrast to general anaesthesia, it also makes coughing or sneezing of the patient possible during surgery, which can increase local pressures (5). An additional risk factor in this case, could have been the left lateral decubitus promoting the passage of fat emboli through the patent foramen ovale to the left heart.

Treatment consists of observation and prevention of secondary thrombotic events (1, 3, 4, 7). Surgical treatment or closure by catheterisation of a patent foramen ovale should not be considered preoperatively to arthroplasty because of the rare presentation of cerebral embolism (5).

REFERENCES

1. **Dive AM, Dubois PE, Ide C *et al***. Paradoxical cerebral fat embolism : an unusual cause of persistent unconsciousness after orthopedic surgery. *Anesthesiology* 2002 ; 96 : 1029-1031.
2. **Ereth MH, Weber JG, Abel MD *et al***. Cemented versus noncemented total hip arthroplasty : embolism-hemodynamics, and intrapulmonary shunting. *Mayo Clin Proc* 1992 ; 67 : 1066-1074.
3. **Gelinas JJ, Cherry R, MacDonald SJ**. Fat embolism syndrome after cementless total hip arthroplasty. *J Arthroplasty* 2000 ; 15 : 809-813.
4. **Koessler MJ, Pitto RP**. Fat and bone marrow embolism in total hip arthroplasty. *Acta Orthop Belg* 2001 ; 67 : 97-109.
5. **Meier B, Lock JE**. Contemporary management of patent foramen ovale. *Circulation* 2003 ; 107 : 5-9.
6. **Riding G, Daly K, Hutchinson S *et al***. Paradoxical cerebral embolisation. An explanation for fat embolism syndrome. *J Bone Joint Surg* 2004 ; 86-B : 95-98.
7. **Sasano N, Ishida S, Tetsu S *et al***. Cerebral fat embolism diagnosed by magnetic resonance imaging at one, eight, and 50 days after hip arthroplasty : a case report. *Can J Anesth* 2004 ; 51 : 875-879.
8. **Stoeger A, Daniaux M, Felber S *et al***. MRI findings in cerebral fat embolism. *Eur Radiol* 1998 ; 8 : 1590-1593.
9. **Sulek CA, Davies LK, Enneking FK *et al***. Cerebral microembolism diagnosed by transcranial Doppler during total knee arthroplasty : correlation with transesophageal echocardiography. *Anesthesiology* 1999 ; 91 : 672-676.
10. **Takahashi M, Suzuki R, Osakabe Y *et al***. Magnetic resonance imaging findings in cerebral fat embolism : correlation with clinical manifestations. *J Trauma* 1999 ; 46 : 324-327.