



The clinical significance of lumbosacral transitional anomalies

Johannes L. BRON, Barend J. VAN ROYEN, Paul I. J. M. WUISMAN

From VU University Medical Center, Amsterdam, The Netherlands

Lumbosacral transitional vertebrae (LSTV) are common congenital anomalies of the human spine. In LSTV, either the fifth lumbar vertebra may show assimilation to the sacrum (sacralisation), or the first sacral vertebra may show transition to a lumbar configuration (lumbarisation). Although the condition has an incidence of over 12% in the general population, knowledge about the exact clinical implications is still lacking. The association between LSTV and low back pain has been debated since it was first described by Bertolotti almost a century ago. Furthermore, several conflicting studies have been published regarding the association of LSTV with other spinal pathology. There seems to be a relation with early disc degeneration above the LSTV in young patients. However, these differences fade with age as they are masked by other degenerative changes of the spine. From a practical view-point, failure to recognise and to number LSTV during spinal surgery may have serious consequences.

Keywords : lumbosacral spine ; transitional anomalies.

Complete transition results in numerical abnormalities of the lumbar and sacral segments (30) : the lumbosacral junction is renamed according to the transition type, resulting in L4-S1 (sacralisation) and L6-S1 (lumbarisation) (see infra : “numbering of lumbosacral transitional vertebrae”). In most cases, however, transition is incomplete or unilateral (fig 1) (37). In 1984, Castelli *et al* (9) proposed a classification (table I) for the degree of transition based on form and orientation of the transverse processes : they show varying degrees of articulation up to complete fusion to the sacral ala (fig 2).

In 1917, Bertolotti (4) was the first to describe an association between LSTV and low back pain (LBP). However, this has remained a matter of debate in the literature for almost a century now (3,9,15,16,20,21,23,28,37,39,51,52,56,59-61,63). In addition, patients with LSTV are reported to have increased risk for advanced disc degeneration or disc herniation (fig 3a and b) above the LSTV (2,28,

INTRODUCTION

Lumbosacral transitional vertebrae (LSTV) are common congenital anomalies of the lumbosacral spine (64). Most frequently, the fifth lumbar vertebra shows signs of assimilation to the sacrum, a condition often referred to as sacralisation. In case of lumbarisation, the first sacral vertebra shows signs of transition to a lumbar configuration (30).

-
- Johannes L. Bron, MD, Orthopaedic Resident.
 - Barend J. van Royen, MD, PhD, Orthopaedic Surgeon.
 - Paul I. J. M. Wuisman, MD, PhD, Orthopaedic Surgeon.

Department of Orthopaedic Surgery, VU University Medical Center, Amsterdam, The Netherlands.

Correspondence : B. J. van Royen, VU University Medical Center, Department of Orthopaedic Surgery, P.O. Box 7057, 1007 MB Amsterdam, The Netherlands.

E-mail : bj.vanroyen@vumc.nl

© 2007, Acta Orthopædica Belgica.

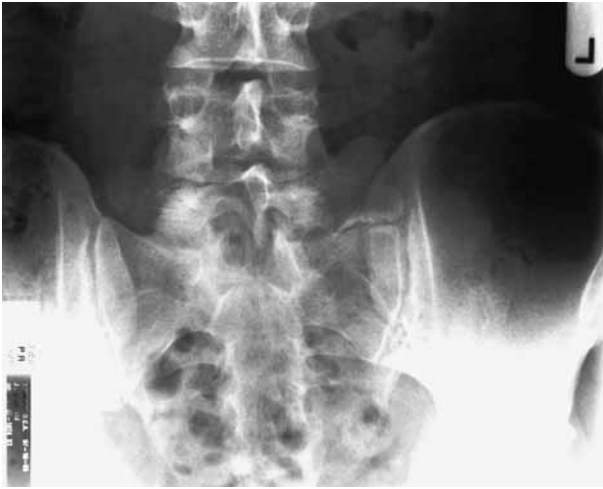

Fig. 1. — Plain A-P radiograph of a patient without low back pain and with a unilateral (left-sided) LSTV, type IIa according to Castellvi.

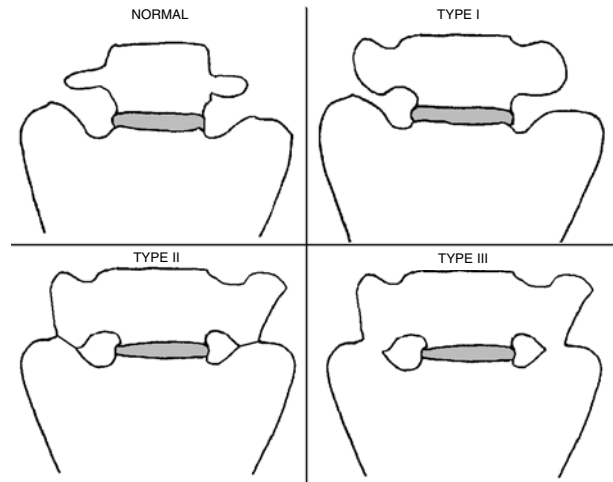


Fig. 2. — Schematic presentation of the classification of LSTV according to Castellvi. Type IV is not reproduced : it is a mixture of type II and III.

Table I. — Classification of LSTV according to Castellvi *et al* (9)

Type I	Dysplastic transverse process	Unilateral (a) or bilateral (b) large triangular transverse process, at least 19 mm wide
Type II	Incomplete lumbarisation / sacralisation	Enlarged transverse process with unilateral (a) or bilateral (b) pseudarthrosis with the adjacent sacral ala
Type III	Complete lumbarisation / sacralisation	Enlarged transverse process, with unilateral (a) or bilateral (b) complete fusion with the adjacent sacral ala
Type IV	Mixed	Type IIa on one side and type IIIa on the other

36,43,46,47,61,64). Other studies have reported association with cervical ribs, altered nerve root functioning and facet joint arthrosis (10,22,67). From a practical view-point, failure to recognise LSTV on imaging studies during the planning of spinal procedures may result in wrong level surgery (38). In the current study, a review of the literature is presented and clinical relevance of LSTV is discussed.

NUMBERING OF LUMBOSACRAL TRANSITIONAL VERTEBRAE

The most accurate method of determining the lumbosacral transition is using AP and lateral lumbosacral radiographs combined with a 30° angled cranially directed AP plain radiograph (12,19,30,62) :

the lumbar levels can now easily be defined on the radiograph by counting down from the T12 vertebra, defined as the vertebra from which the lowest rib originates. However, when MRI scanning is performed in absence of plain radiographs, particular attention for the existence of LSTV is necessary, and additional knowledge and techniques are required (30). Many techniques have been suggested to define the lumbar vertebral levels on MRI images, including counting down from C2 or up from S5, and the relation to anatomical landmarks like the aortic bifurcation, the right renal artery and the iliolumbar ligament. A consensus, however, is still lacking (11,18,25,29,30,44,48,53). O'Driscoll *et al* (44) correlated a classification of sacral disc morphology on MRI with the classification of LSTV

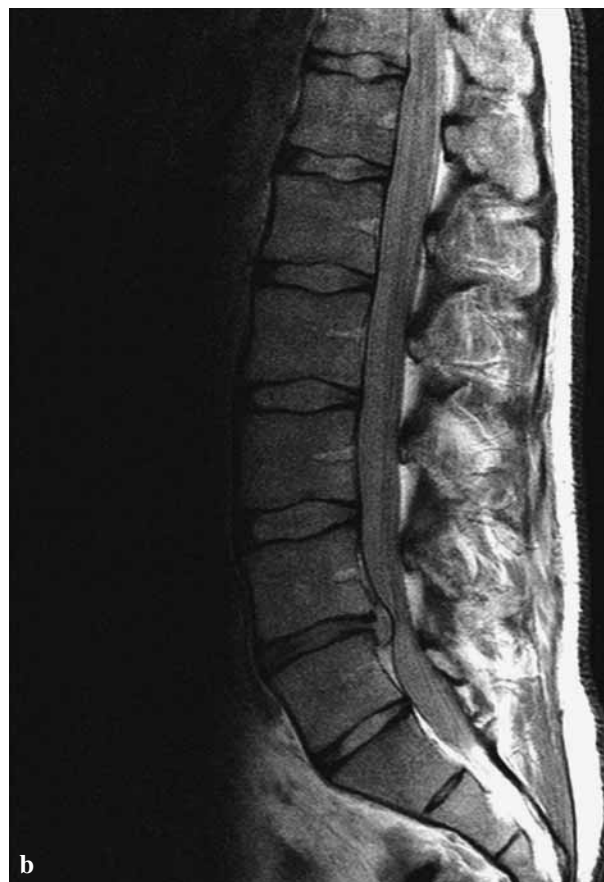
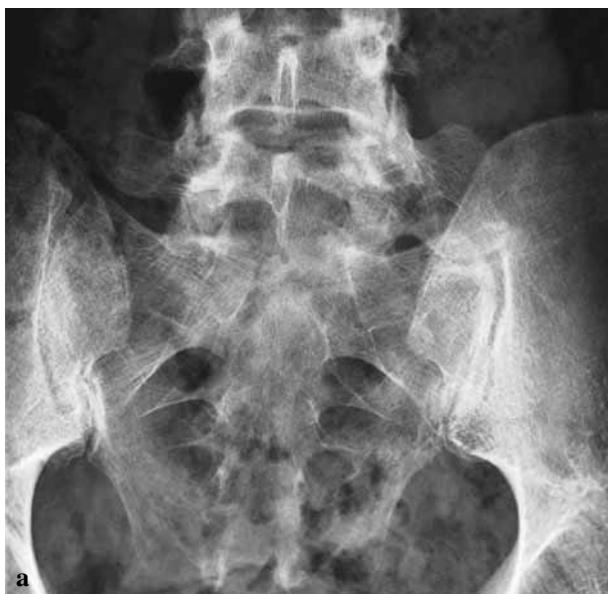
Fig. 3. — (a) Plain A-P radiograph of a patient with low back pain without radiculopathy and a unilateral (left-sided) LSTV, type IIa according to Castellvi ; (b) T1-weighted sagittal MRI scan of the same patient, showing a disc herniation, typically above the LSTV.

according to Castellvi. The sagittal scans of the sacrum were separated into four types (1-4) according to the appearance of the disc between the uppermost sacral segment and the remainder of the sacrum. This demonstrated a good correlation between the presence of a fused LSTV (Castellvi type III or IV) and a type 4. However, patients with Castellvi types Ia or IIb LSTV were not identified with this method (30,44). Another MRI method for defining the lumbar levels is using C2 as a landmark, which is based on the assumption that there are always 7 cervical and 12 thoracic vertebrae (12,25,44,48). Hahn *et al* (25) made a cervicothoracic scout MRI in every patient and counted caudally from C2. They identified 24 cases of LSTV in 200 patients (12%). Moreover, they stated that consistently accurate verification of the actual level of disc disease outweighs the additional time and efforts that are required. Peh *et al* (48) found an 11.6% interobserver discordance in assessment of

L5 when only using a lumbosacral scout MRI, while the lumbar segments could be identified consistently when using an additional cervicothoracic scout, so that one could count down from C2. Chithriki *et al* (11) investigated the relationship of the aortic bifurcation with the lumbar spine. In the normal spine, the aorta bifurcated at the L4 level in 67% of the cases. In case of sacralisation the bifurcation was found at the level of L3 in 59%. In lumbarisation, the bifurcation was found at the level of L4 in 40% and at the level of the L4/L5 disc space in 33%. Therefore, the localisation of the aortic bifurcation as a landmark cannot be used in patients with LSTV to accurately determine the lumbar vertebral levels. Recently, Hughes *et al* (29) showed that the iliolumbar ligament could be used as a landmark on T1-weighted MRI scans. In the absence of LSTV, the ligament exclusively arises from the transverse process of L5. In their study, they showed that when the ligament arose at the

vertebra above a LSTV, the S1 segment was transitional (lumbarisation). In case of L5 transition (sacralisation), the ligament was absent or smaller and of course no ligament was seen at the level above. They advised the use of the iliolumbar ligament as an accurate method to assign lumbar levels in case of LSTV (29). Milicic *et al* (42) obtained sagittal MR images of the sacrum and coccygeal bone in addition to sagittal MRI scans of the lumbosacral spine to define the lumbosacral transition in children. According to the authors, the sacrum can be clearly distinguished from the coccygeal bone on the T2-weighted sequence. By counting upward from S5, the S1 vertebra could be accurately identified.

Incorrect numbering during the planning of spinal surgery may have serious consequences. Malanga and Cook (38) reported wrong level emergency decompression, in a patient with a cauda equina syndrome, due to neglecting complete lumbarisation of S1. Incorrect numbering can theoretically lead to problems with the administration of epidural or intradural anaesthetics in patients with LSTV. Kim *et al* (34) showed that an LSTV does affect the position of the intercrestal line (the line connecting the highest points of the iliac crests, also called 'Tuffier's line'), and on the location of the conus medullaris. The intercrestal line normally corresponds with the level L4/L5 and is therefore used as a landmark for needle insertion (34). Theoretically, variations in the exact level of the intercrestal line in patients with LSTV might have serious consequences. However, the margin of safety between the intercrestal line and the conus medullaris still allows the use of this line as an anatomical landmark for the administration of spinal anaesthetics in patients with LSTV (34).

AETIOLOGY

Genetic factors are being held responsible for the segmental development of the lumbosacral spine (62). During embryogenesis, the axial skeleton is derived from the paraxial mesenchyma that surrounds the neural tube. The mesenchyma undergoes craniocaudal segmentation, resulting in clusters of cells, the so-called somites (22). The somites

are segmentally organised in pairs on both sides of the neural tube and are specific for the axial level at which they are positioned (8). This segmental identity of the somites is determined by different Hox-genes in the presomitic mesoderm (8,66). The specific combination of Hox-genes that is expressed at a particular level seems to determine the axial identity of the resulting structures. To support this hypothesis, Carapuco *et al* (8) showed that vertebral sacralisation can be induced in transgenic mice by Hox11 expression. Wellik *et al* (66) showed that in the absence of Hox11 function, sacral vertebrae are not formed and instead these vertebrae assume a lumbar identity. In addition, they showed that in the absence of Hox10 function, no lumbar vertebrae are formed. Thus, these studies show that the normal patterning of lumbar and sacral vertebrae as well as the changes in the axial pattern, such as LSTV, result from mutations in the Hox-10 and Hox-11 paralogous genes (8,66). In addition, Erken *et al* (22) found a significant association between sacralisation and cervical rib. The mechanisms responsible for the development of the lumbosacral spine may therefore influence the development of the cervical spine and vice versa.

PREVALENCE

The prevalence of LSTV reported in the literature ranges from 4 to over 35% (table II). This wide range may be explained by differences in diagnostic criteria, imaging techniques, and confounding factors between the investigated population samples. Hsieh *et al* (28) found a prevalence of 4% in a population mainly consisting of Chinese patients by using anteroposterior (AP) plain radiographs for diagnosis. However, they excluded Castellvi type I, because this lesion would lack effects on spinal biomechanics. Erken *et al* (22) also used AP plain radiographs for diagnosis, but did not exclude subtypes of LSTV. They found a prevalence of 35.9% in a predominantly Turkish population sample. No further studies have been published regarding racial differences. In a systematic review of comparable observational studies from 1986 to date we found a mean prevalence of 12.3% (table II). About 50% of these studies further divided LSTV in

Table II. — Survey of prevalence of LSTV in the observational studies published since 1986

First author	Year	Number patients	Transitional vertebrae	Lumbarisation	Sacralisation	LBP	DD
Quinlan (52)	2006	769	35 (4.6%)			+	
Hughes (29)	2006	500	67 (13.4%)	21 (4.2%)	46 (9.2%)		
Delpont (17)	2006	300	90 (30.0%)				
Peterson (51)	2005	353	43 (12.2%)			-	
Taskaynatan (60)	2005	881	41 (4.7%)			+	
Luoma (37)	2004	163	49 (30%)			-	-
Steinberg (59)	2003	464	85 (18.3%)	20 (4.3%)	65 (14.0%)	+	
Kim (35)	2003	690	41 (5.9%)	29 (4.2%)	12 (1.7%)		
Chithriki (11)	2002	441	37 (8.4%)	15 (3.4%)	22 (5.0%)		
Otani (46)	2002	1009	119 (11.8%)			-	+
Erken (22)	2002	729	262 (35.9%)				
Santiago (56)	2001	138	26 (18.4%)	10 (7.2%)	16 (11.6%)		
Hsieh (28)	2000	1668	67 (4.0%)				+
Dai (16)	1999	460	126 (27.4%)			+	
Peh (48)	1999	129	17 (13.2%)	9 (7.0%)	8 (6.2%)		
Cadeddu (7)	1997	299	16 (5.4%)				
Vergauwen (64)	1997	350	53 (15.0%)			-	+
O'driscoll (44)	1996	100	15 (15.0%)				
Hald (26)	1995	5781	792 (13.7%)	341 (5.9%)	451 (7.8%)		
Hahn (25)	1992	200	24 (12%)	9 (4.5%)	15 (7.5%)		
Elster (20)	1989	2000	140 (7%)			-	
Leboeuf (36)	1989	530	61 (11.5)	32 (6.0%)	29 (5.5%)		+
TOTAL		17954	2206 (12.3%)	486 (5.5%)	664 (7.5%)		

LBP+ or DD+ means that there was a positive correlation with Low Back Pain or Disc Degeneration ; LBP- or DD- refers to the opposite.

lumbarisation and sacralisation with a mean prevalence of 5.5% and 7.5%, respectively (table II).

ASSOCIATED SPINAL PATHOLOGY

Patients with LSTV are often suggested to be prone to various secondary pathologic spinal conditions including intervertebral disc herniation and/or degeneration, facet joint arthrosis and spinal canal or foraminal stenosis. For most conditions, however, convincing evidence is lacking in the scientific literature. Elster (20) found no difference in the overall incidence of structural pathology of the spine (eg, spinal stenosis and disc protrusion) in patients with LSTV after studying 2,000 adult patients. However, they noticed a significant difference in the distribution of these spinal lesions : bulging disc or disc herniation, as it occurred in

patients with LSTV, was nine times more common at the level immediately above the transitional vertebra compared to patients without LSTV. The increased risk for disc herniation or degeneration at the disc level above the LSTV was confirmed by other studies (28,36,46,47). Luoma *et al* (37) showed that disc degeneration above the LSTV was more frequent in young patients ; but during aging these degenerative disc changes became less obvious and were masked by regular degenerative changes. Reversely with Elster (20), Otani *et al* (46) found a significantly higher incidence of LSTV in patients that were treated for disc herniation when compared to an asymptomatic control group. In addition, they showed that the mean age was significantly lower in patients with disc herniation and LSTV, compared to patients with disc herniation without signs of LSTV.

Increased disc degeneration of the disc above a LSTV is attributed to its relative hypermobility (24,64). This may be analogous to the advanced degeneration adjacent to a block vertebra or an interbody fusion mass (37,64). Taskaynatan *et al* (60) suggested an inability to disperse load equally and an increase in local stresses to result in lumbar instability. Conversely, LSTV is reported to prevent the development of degenerative disc disease of the disc below the LSTV (37,64). The articulation or fusion between the transverse process of the LSTV and the sacrum has been assumed to restrict rotational and bending movements and thereby protect the disc below (2,37,60,64).

Other spinal disorders secondary to LSTV have only been studied scarcely. Vergauwen *et al* (64), in a prospective study of patients with LBP and sciatica, found facet joint arthrosis and foraminal stenosis to occur significantly more often in patients with LSTV. However, for the occurrence of spinal canal stenosis in patients with LSTV, no statistically significant differences were found compared to patients without LSTV. This observation was confirmed by Oguz *et al* (45), and, in addition, they found no relation between the spinal canal diameter at adjacent levels and LSTV.

The relation between LSTV and degenerative spondylolisthesis has been studied by Cinotti *et al* (13). In this study, no difference in prevalence of LSTV was found in 27 patients with degenerative spondylolisthesis compared to 27 healthy control patients.

LOW BACK PAIN AND RADICULOPATHY

The association between low back pain (LBP) and LSTV has been disputed since it was first described by Bertolotti in 1917 (4). Of the 22 reviewed observational studies (table II), 4 studies found a positive and 5 studies a negative correlation between LBP and LSTV. Therefore the clinical challenge in patients with LSTV presenting with LBP is to determine whether an anatomical substrate related to LSTV is the underlying cause of the pain. Hypertrophic transverse processes (Castellvi type I) are generally considered to have no clinical significance and do not need further

attention in clinical practice (9,28,61). In patients with more severe types of LSTV, however, certain structures should receive particular attention during clinical assessment. Firstly, the pain may have a discogenic origin, generated in the disc above the transitional vertebra (Castellvi types II, III, IV) (52). In addition, the bulging or herniated disc may cause nerve root compression resulting in LBP and sciatica (46). However, nerve roots may also be compressed between the transverse segment of the LSTV and the sacral ala (Castellvi type II) (27). Secondly, the pain may be generated in the articulation between the enlarged transverse process and the sacral ala or ilium (Castellvi type II) (32). Thirdly, contralateral LBP in patients with unilateral LSTV (Castellvi type IIa) may reflect facetogenic pain (5).

In patients with radiculopathy, the altered function of lumbar nerve roots accompanying LSTV should be taken into account during clinical investigation (10,58). Chang *et al* (10) revealed altered distribution of muscle weakness after compression of the S1 nerve root by herniated discs in patients with a lumbarised S1 compared to normal subjects. The S1 nerve root performed the function of the L5 nerve root. These findings are in line with earlier findings of McCulloch *et al* (41) who showed the L5 nerve always to originate in the 'last mobile' level of the lumbosacral segment.

Magnetic resonance imaging (MRI) is indicated in cases with LBP and radiculopathy (27,44,61). Single Photon Emission Computed Tomography (SPECT) is helpful in differentiating a painful articulation between the enlarged transverse process and the sacral ala or ilium (Castellvi type II) from symptomatic degenerative changes in the lumbar spine and pelvis (14,15,49,50). Indeed, focal, markedly increased uptake at the lumbosacral articulation has been shown to correspond well with the location of the pain (14,15,50). In patients with unilateral LSTV (Castellvi type IIa) and contralateral LBP, SPECT has proved to be less useful to evaluate contralateral facetogenic pain (50), while Computed Tomography (CT) seems to be most sensitive. Local anaesthetic infiltration of the anomalous articulation or facet joint can be used as a diagnostic tool in patients with (unilateral) LSTV.

However, this should be reserved for patients who are planned for resection or fusion therapy, to define the painful origin in LSTV (5,40,50).

TREATMENT

While there is little consensus on the clinical significance of LSTV, even less is known about useful treatment strategies. Unfortunately, only scarce reports with small case series are available in the literature, describing specific treatment options in symptomatic LSTV (1,5,6,31,33,40,54,65). Marks and Thulborn (40) reported about 10 patients with LBP, treated with injection of a local anaesthetic and hydrocortisone in the articulation between the LSTV and the sacrum. Eight of these patients experienced acute relief of symptoms after the injection, but the pain relapsed in 5 of them within 12 weeks. Only one patient remained free of pain for a period of two years. Nevertheless, the authors concluded that in selected cases local infiltration can be therapeutic, but that it offers greater opportunities when used as a diagnostic tool. Santavirta *et al* (55) surgically treated 16 patients with chronic persistent LBP and radiographically diagnosed LSTV either by posterolateral fusion (8 patients) or resection of the transitional articulation (8 patients); the results were similar, but the groups were rather small. Brault *et al* (5) reported the case of a 17-year-old patient with unilateral LSTV and contralateral facetogenic pain. The diagnosis was preoperatively confirmed by fluoroscopic guided injection into the facet joint. As treatment, resection of the right transverse process was performed. At 1-year follow-up the patient was free of pain. Senegas (57), finally, described encouraging results in the treatment of disc herniation at the level above LSTV using a dynamic stabilising interspinous implant.

CONCLUSION

LSTV is a benign anatomical variation of the lumbosacral spine that is very often encountered by the spinal surgeon. However, the clinical significance of the condition is still unknown and its relation with low back pain is controversial. In patients who present with LBP and a LSTV revealed by

plain radiographs, the physician should be aware of secondary spinal disorders like disc degeneration and disc herniation above the LSTV, and/or facet joint arthrosis. In selected cases therefore, additional imaging methods like CT, MRI and SPECT may be considered. Furthermore, caution in numbering of lumbosacral vertebrae in symptomatic LSTV is of utmost importance in spinal surgery, especially if surgery is performed in the absence of regular plain radiographs. There is no evidence that specific surgery is indicated in patients with symptomatic LSTV.

REFERENCES

1. Abe E, Sato K, Shimada Y, Okada K, Yan K, Mizutani Y. Anterior decompression of foraminal stenosis below a lumbosacral transitional vertebra. A case report. *Spine* 1997 ; 22 : 823-826.
2. Aihara T, Takahashi K, Ogasawara A, Itadera E, Ono Y, Moriya H. Intervertebral disc degeneration associated with lumbosacral transitional vertebrae : a clinical and anatomical study. *J Bone Joint Surg* 2005 ; 87-B : 687-691.
3. Batt ME, Skattum N, Chong BK, Tanji JL. Posterior element pain in a adolescent schoolgirl. *Br J Sports Med* 1996 ; 30 : 356-358.
4. Bertolotti M. Contributo alla conoscenza dei vizi di differenziazione regionale del rachide con speciale riguardo all' assimilazione sacrale della v. lombare. *Radiol Med* 1917 ; 4 : 113-144.
5. Brault JS, Smith J, Currier BL. Partial lumbosacral transitional vertebra resection for contralateral facetogenic pain. *Spine* 2001 ; 26 : 226-229.
6. Brenner AK. Use of lumbosacral region manipulation and therapeutic exercises for a patient with a lumbosacral transitional vertebra and low back pain. *J Orthop Sports Phys Ther* 2005 ; 35 : 368-376.
7. Cadeddu JA, Benson JE, Silver RI, Lakshmanan Y, Jeffs RD, Gearhart JP. Spinal abnormalities in classic bladder exstrophy. *Br J Urol* 1997 ; 79 : 975-978.
8. Carapuco M, Novoa A, Bobola N, Mallo M. Hox genes specify vertebral types in the presomitic mesoderm. *Genes Dev* 2005 ; 19 : 2116-2121.
9. Castellvi AE, Goldstein LA, Chan DPK. Lumbosacral transitional vertebrae and their relationship with lumbar extradural defects. *Spine* 1984 ; 9 : 493-495.
10. Chang HS, Nakagawa H. Altered function of lumbar nerve roots in patients with transitional lumbosacral vertebrae. *Spine* 2004 ; 29 : 1632-1635.
11. Chithriki M, Jaibaji M, Steele RD. The anatomical relationship of the aortic bifurcation to the lumbar vertebrae : a MRI study. *Surg Radiol Anat* 2002 ; 24 : 308-312.

12. **Cimen M, Elden H.** Numerical variations in human vertebral column : a case report. *Okajimas Folia Anat Jpn* 1999 ; 75 : 297-303.
13. **Cinotti G, Postacchini F, Fassari F, Urso S.** Predisposing factors in degenerative spondylolisthesis. A radiographic and CT study. *Int Orthop* 1997 ; 21 : 337-342.
14. **Connolly LP, d'Hemecourt PA, Connolly SA, Drubach LA, Micheli LJ, Treves ST.** Skeletal scintigraphy of young patients with low-back pain and a lumbosacral transitional vertebra. *J Nucl Med* 2003 ; 44 : 909-914.
15. **Connolly LP, Drubach LA, Connolly SA, Treves ST.** Young athletes with low back pain : skeletal scintigraphy of conditions other than pars interarticularis stress. *Clin Nucl Med* 2004 ; 29 : 689-693.
16. **Dai L.** Lumbosacral transitional vertebrae and low back pain. *Bull Hosp Jt Dis* 1999 ; 58 : 191-193.
17. **Delpont EG, Cucuzzella TR, Kim N, Marley J, Pruitt C, Delpont AG.** Lumbosacral transitional vertebrae : incidence in a consecutive patient series. *Pain Physician* 2006 ; 9 : 53-56.
18. **Desmond PM, Buirski G.** Magnetic resonance appearances of developmental disc anomalies in the lumbar spine. *Australas Radiol* 1993 ; 37 : 26-29.
19. **Ebraheim NA, Xu R.** Assessment of lumbosacral fusion mass by angled radiography. Technical notes. *Spine* 1998 ; 23 : 842-843.
20. **Elster AD.** Bertolotti's syndrome revisited. Transitional vertebrae of the lumbar spine. *Spine* 1989 ; 14 : 1373-1377.
21. **Endo K, Ito K, Ichimaru K, Komagata M, Imakiire A.** A case of severe low back pain associated with Richard disease (lumbosacral transitional vertebra). *Minim Invasive Neurosurg* 2004 ; 47 : 253-255.
22. **Erken E, Ozer HT, Gulek B, Durgun B.** The association between cervical rib and sacralization. *Spine* 2002 ; 27 : 1659-1664.
23. **Frymoyer JW, Newberg A, Pope MH, Wilder DG, Clements J, MacPherson B.** Spine radiographs in patients with low-back pain. An epidemiological study in men. *J Bone Joint Surg* 1984 ; 66-A : 1048-1055.
24. **Gay RE, Ilharreborde B, Zhao K, Zhao C, An KN.** Sagittal plane motion in the human lumbar spine : Comparison of the in vitro quasistatic neutral zone and dynamic motion parameters. *Clin Biomech (Bristol, Avon)* 2006 ; 21 : 914-919.
25. **Hahn PY, Strobel JJ, Hahn FJ.** Verification of lumbosacral segments on MR images : identification of transitional vertebrae. *Radiology* 1992 ; 182 : 580-581.
26. **Hald HJ, Danz B, Schwab R, Burmeister K, Bähren W.** Radiographically demonstrable spinal changes in asymptomatic young men. *Rofo* 1995 ; 163 : 4-8.
27. **Hashimoto M, Watanabe O, Hirano H.** Extraforaminal stenosis in the lumbosacral spine. Efficacy of MR imaging in the coronal plane. *Acta Radiol* 1996 ; 37 : 610-613.
28. **Hsieh CY, Vanderford JD, Moreau SR, Prong T.** Lumbosacral transitional segments : classification, prevalence, and effect on disk height. *J Manipulative Physiol Ther* 2000 ; 23 : 483-489.
29. **Hughes RJ, Saifuddin A.** Numbering of lumbosacral transitional vertebrae on MRI : role of the iliolumbar ligaments. *Am J Roentgenol* 2006 ; 187 : W59-W65.
30. **Hughes RJ, Saifuddin A.** Imaging of lumbosacral transitional vertebrae. *Clin Radiol* 2004 ; 59 : 984-991.
31. **Ichihara K, Taguchi T, Hashida T, Ochi Y, Murakami T, Kawai S.** The treatment of far-out foraminal stenosis below a lumbosacral transitional vertebra : a report of two cases. *J Spinal Disord Tech* 2004 ; 17 : 154-157.
32. **Jonsson B, Stromqvist B, Egund N.** Anomalous lumbosacral articulations and low-back pain. Evaluation and treatment. *Spine* 1989 ; 14 : 831-834.
33. **Junge RE, Muhlbauer M, Haines V, West G.** Clinical challenge. Transitional vertebra at the lumbosacral junction. *J Zoo Wildl Med* 2002 ; 33 : 87-88.
34. **Kim JT, Bahk JH, Sung J.** Influence of age and sex on the position of the conus medullaris and Tuffier's line in adults. *Anesthesiology* 2003 ; 99 : 1359-1363.
35. **Kim NH, Suk KS.** The role of transitional vertebrae in spondylolysis and spondylolytic spondylolisthesis. *Bull Hosp Jt Dis* 1997 ; 56 : 161-166.
36. **Leboeuf C, Kimber D, White K.** Prevalence of spondylolisthesis, transitional anomalies and low intercrestal line in a chiropractic patient population. *J Manipulative Physiol Ther* 1989 ; 12 : 200-204.
37. **Luoma K, Vehmas T, Raininko R, Luukkonen R, Riihimäki H.** Lumbosacral transitional vertebra : relation to disc degeneration and low back pain. *Spine* 2004 ; 29 : 200-205.
38. **Malanga GA, Cooke PM.** Segmental anomaly leading to wrong level disc surgery in cauda equina syndrome. *Pain Physician* 2004 ; 7 : 107-110.
39. **Mann DC, Keene JS, Drummond DS.** Unusual causes of back pain in athletes. *J Spinal Disord* 1991 ; 4 : 337-343.
40. **Marks RC, Thulbourne T.** Infiltration of anomalous lumbosacral articulations. Steroid and anesthetic injections in 10 back-pain patients. *Acta Orthop Scand* 1991 ; 62 : 139-141.
41. **McCulloch JA, Waddell G.** Variation of the lumbosacral myotomes with bony segmental anomalies. *J Bone Joint Surg* 1980 ; 62-B : 475-480.
42. **Milicic G, Krolo I, Vrdoljak J, Marotti M, Roić G, Hat J.** Using magnetic resonance imaging to identify the lumbosacral segment in children. *Coll Antropol* 2006 ; 30 : 55-58.
43. **Nicholson AA, Roberts GM, Williams LA.** The measured height of the lumbosacral disc in patients with and without transitional vertebrae. *Br J Radiol* 1988 ; 61 : 454-455.
44. **O'Driscoll CM, Irwin A, Saifuddin A.** Variations in morphology of the lumbosacral junction on sagittal MRI :

- correlation with plain radiography. *Skeletal Radiol* 1996 ; 25 : 225-230.
45. **Oguz H, Akkus S, Tarhan S, Açıkgözoğlu S, Kerman M.** Measurement of spinal canal diameters in young subjects with lumbosacral transitional vertebra. *Eur Spine J* 2002 ; 11 : 115-118.
 46. **Otani K, Konno S, Kikuchi S.** Lumbosacral transitional vertebrae and nerve-root symptoms. *J Bone Joint Surg* 2001 ; 83-B : 1137-1140.
 47. **Paajanen H, Erkindalo M, Kuusela T, Dahlstrom S, Kormano M.** Magnetic resonance study of disc degeneration in young low-back pain patients. *Spine* 1989 ; 14 : 982-985.
 48. **Peh WC, Siu TH, Chan JH.** Determining the lumbar vertebral segments on magnetic resonance imaging. *Spine* 1999 ; 24 : 1852-1855.
 49. **Pekindil G, Pekindil Y, Sarikaya A.** Degenerative lumbosacral transitional articulation : atypical increased sacral uptake on planar bone scintigraphy. *Clin Nucl Med* 2002 ; 27 : 840-841.
 50. **Pekindil G, Sarikaya A, Pekindil Y, Gültekin A, Kokino S.** Lumbosacral transitional vertebral articulation : evaluation by planar and SPECT bone scintigraphy. *Nucl Med Commun* 2004 ; 25 : 29-37.
 51. **Peterson CK, Bolton J, Hsu W, Wood A.** A cross-sectional study comparing pain and disability levels in patients with low back pain with and without transitional lumbosacral vertebrae. *J Manipulative Physiol Ther* 2005 ; 28 : 570-574.
 52. **Quinlan JF, Duke D, Eustace S.** Bertolotti's syndrome. A cause of back pain in young people. *J Bone Joint Surg* 2006 ; 88-B : 1183-1186.
 53. **Ralston MD, Dykes TA, Applebaum BI.** Verification of lumbar vertebral bodies. *Radiology* 1992 ; 185 : 615-616.
 54. **Reitsma AM, Schuler TC, Hasz MW, Poelstra KA.** Surgical treatment of symptomatic Bertolotti's syndrome in post-fusion patients. *Orthopedics* 2002 ; 25 : 340-342.
 55. **Santavirta S, Tallroth K, Ylinen P, Suoranta H.** Surgical treatment of Bertolotti's syndrome. Follow-up of 16 patients. *Arch Orthop Trauma Surg* 1993 ; 112 : 82-87.
 56. **Santiago FR, Milena GL, Herrera RO, Romero PA, Plazas PG.** Morphometry of the lower lumbar vertebrae in patients with and without low back pain. *Eur Spine J* 2001 ; 10 : 228-233.
 57. **Senegas J.** Mechanical supplementation by non-rigid fixation in degenerative intervertebral lumbar segments : the Wallis system. *Eur Spine J* 2002 ; 11 Suppl 2 : S164-S169.
 58. **Seyfert S.** Dermatome variations in patients with transitional vertebrae. *J Neurol Neurosurg Psychiatry* 1997 ; 63 : 801-803.
 59. **Steinberg EL, Luger E, Arbel R, Menachem A, Dekel S.** A comparative roentgenographic analysis of the lumbar spine in male army recruits with and without lower back pain. *Clin Radiol* 2003 ; 58 : 985-989.
 60. **Taskaynatan MA, Izci Y, Ozgul A, Hazneci B, Dursun H, Kalyon TA.** A Clinical significance of congenital lumbosacral malformations in young male population with prolonged low back pain. *Spine* 2005 ; 30 : E210-E213.
 61. **Tertti MO, Salminen JJ, Paajanen HE, Terho PH, Kormano MJ.** Low-back pain and disk degeneration in children : a case-control MR imaging study. *Radiology* 1991 ; 180 : 503-507.
 62. **Tini PG, Wieser C, Zinn WM.** The transitional vertebra of the lumbosacral spine : its radiological classification, incidence, prevalence, and clinical significance. *Rheumatol Rehabil* 1977 ; 16 : 180-185.
 63. **van Tulder MW, Assendelft WJ, Koes BW, Bouter LM.** Spinal radiographic findings and nonspecific low back pain. A systematic review of observational studies. *Spine* 1997 ; 22 : 427-434.
 64. **Vergauwen S, Parizel PM, van Breusegem L et al.** Distribution and incidence of degenerative spine changes in patients with a lumbo-sacral transitional vertebra. *Eur Spine J* 1997 ; 6 : 168-172.
 65. **Weiner BK, Walker M, Fraser RD.** Vascular anatomy anterior to lumbosacral transitional vertebrae and implications for anterior lumbar interbody fusion. *Spine J* 2001 ; 1 : 442-444.
 66. **Wellik DM, Capecchi MR.** Hox10 and Hox11 genes are required to globally pattern the mammalian skeleton. *Science* 2003 ; 301 : 363-367.
 67. **Yuksel M, Karabiber H, Yuksel KZ, Parmaksiz G.** Diagnostic importance of 3D CT images in Klippel-Feil Syndrome with multiple skeletal anomalies : a case report. *Korean J Radiol* 2005 ; 6 : 278-281.