



Arthroscopic ankle debridement : 5-year survival analysis

Hazem HASSOUNA, Skand KUMAR, Stephen BENDALL

From the Brighton and Sussex University Hospitals, East Sussex, United Kingdom

Little information exists regarding the long term prognosis following ankle arthroscopy, particularly in avoiding further major surgery. The purpose of this study is to evaluate the prognosis of arthroscopic ankle treatment. We also investigated the relationship between the arthroscopic treatment and time for a further major ankle surgery.

In this consecutive case series study using a prospectively collected database, 80 consecutive patients (80 ankles) having ankle arthroscopy with the finding of osteoarthritis or impingement were identified and their outcome at five years was ascertained. Fifty five (69%) patients had soft tissue impingement, and 25 (31%) patients had osteoarthritic degenerative changes. Seven (9%) patients had further major surgery and 6 (8%) had repeat arthroscopy. The surgery was required for 7 arthritic ankles among which, however, survival analysis showed no significant difference between those under 50 and those over 50 years. Twenty-eight percent of osteoarthritic patients progressed to major ankle surgery, within 5 years of arthroscopic treatment. None of the patients with impingement symptoms required further major surgery.

In conclusion, arthroscopically treated impingement ankles were found to have an excellent prognosis, while osteoarthritic ankles had a less favoured prognosis, with a high proportion requiring further major surgery. Age did not appear to affect the prognosis in the osteoarthritic group.

Keywords : ankle arthroscopy ; osteoarthritis ; impingement ; adults ; arthrodesis.

INTRODUCTION

Arthroscopy has been used widely in the last twenty years for the treatment of pathologies of the ankle. It shortens the duration of diagnosis, decreases morbidity and enables a rapid rehabilitation permitting a faster return to work, social and sportive activities (10). Currently, indications for operative arthroscopy include chondral talar dome fractures, acute articular fractures with haemarthrosis, posttraumatic synovitis, loose bodies, inflammatory synovitis, degenerative joint disease, and soft tissue impingement (2). Several reports assessed the effectiveness of arthroscopy in terms of patient satisfaction (5,9,14,23). In this study we evaluated the prognosis of patients with osteoarthritis or impingement symptoms after arthroscopic ankle treatment.

-
- Hazem Hassouna, AFRCSEd, Orthopaedic Registrar.
 - Skand Kumar, MRCS, Orthopaedic Registrar.
 - Stephen Bendall FRCS (Orth), Consultant Orthopaedic Surgeon.

Trauma and Orthopaedics Department, Brighton and Sussex University Hospitals, East Sussex, United Kingdom.

Correspondence : Hazem Hassouna, Department of Orthopaedics, Princess Royal Hospital, Haywards Heath, RH16 4EX, United Kingdom. E-mail : hhassouna@gmail.com.

© 2007, Acta Orthopædica Belgica.

PATIENTS AND METHODS

From January 1997 to December 2000, information was prospectively collected, using the Manchester Database, on 80 consecutive patients that underwent ankle arthroscopic debridement and irrigation. Demographic data including patients age and gender was collected. The indication for the surgical intervention was pain, which was not controlled by non operative measures, e.g. 3 months physiotherapy and/or intrarticular injection of local anaesthetics and steroid, in association with radiographic evidence of moderate osteoarthritic (OA) degenerative changes. All patients had plain ankle radiographs. MR scans were not routinely requested. All patients had ankle arthroscopy performed under the care of one surgeon, with ankle distraction applied (6). Standard anteromedial and anterolateral portals were used. Standard instruments were used. Treatment consisted of debridement of osteochondral lesions, removal of loose bodies, curettage, drilling, synovectomy, and abrasion of the subchondral bone. All ankle joints had wash out. They were called to follow-up at 6 weeks post operative and subsequently at 6 to 12 months' intervals. Mean follow-up period was 48 months (range : 18 to 65).

Results were examined using Kaplan Meier survival analysis. Statistical analysis of the results was done using Chi squared test.

RESULTS

The 80 ankle arthroscopies were performed on 80 patients, of whom 51 were male and 29 female. The mean age of all patients was 40.9 years (range : 38 to 71).

Fifty five patients (69%) had synovitis (27 patients) or soft tissue impingement (24 patients), or osteochondral lesions (4 patients) on arthroscopic examination, while 25 patients (31%) had moderate to severe osteoarthritic degenerative changes.

Overall 14 (28%) patients subsequently required an ankle arthrodesis and 6 (24%) patients had a repeat ankle arthroscopy at 5 year follow-up. Those who had further major surgery, i.e. joint arthrodesis were on average 11 years older.

Survival analysis of arthroscoped joints revealed an early failure phase pattern. There is rapid failure

Ankle Arthroscopy: Survival proportions

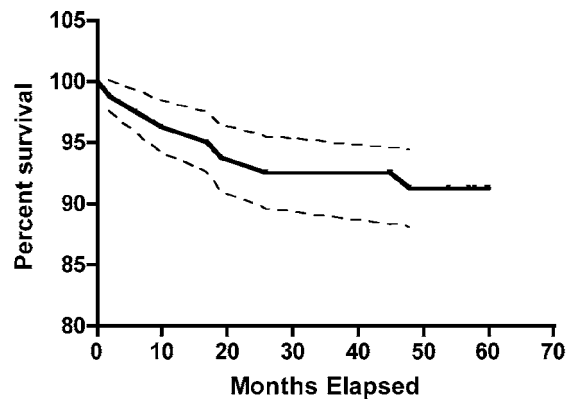


Fig. 1. — Survivorship curve of ankles following arthroscopic treatment.

rate within first 24 months, followed by a plateau failure pattern (fig 1).

There were 53 patients over the age of 50 and 27 patients under 50.

When comparing the survival analysis of patients aged 50 and over and those under 50, no significant difference was found using the Chi square test (p value = 0.159) (fig 2).

DISCUSSION

Arthroscopy enables accurate diagnoses with the advantage of direct vision in patients with persistent ankle problems. It can also be used to treat the diagnosed pathology at the same session. Many procedures that were done by open methods can be done arthroscopically today. Osteochondral lesions (3,12,13,19), post-traumatic talar cysts (20), anterior and posterior impingement syndromes (7, 15,16,25,27), ligament injuries (17), osteoid osteomas of the talus (26) and synovitis can be diagnosed and treated with this method. Arthroscopy can be used both for diagnostic and therapeutic purposes in acute ankle fractures (11), and subtalar joint pathologies (13).

The role of arthroscopy in the management of patients with an osteoarthritic ankle has been debated. This study revealed that one hundred percent of ankles with impingement survived any further surgical intervention, but over 50% of those

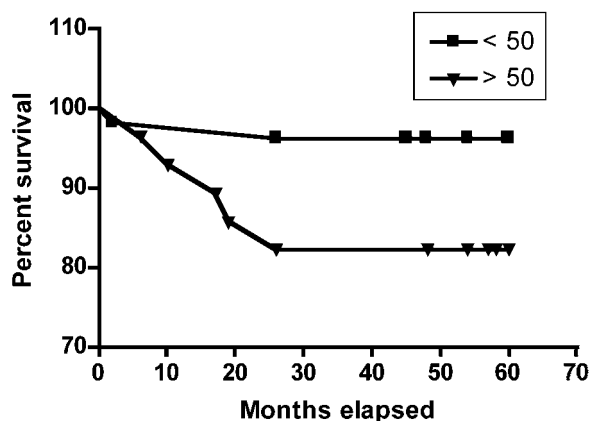


Fig. 2. — Percent survival of ankle joints in patients > 50 and patients < 50 years old.

with osteoarthritic changes had a major surgery, i.e. arthrodesis, or repeat arthroscopy at 5-year follow-up. Therefore, the risk for major ankle surgery is higher in osteoarthritis. This risk appears to be independent of patient's age, as depicted in figure 2. Ninety four percent of patients less than 50 years of age survived without further surgery at 26 months compared with 85% of patients over 50. This is probably because most patients in the younger age group have impingement syndromes. Arthroscopy is clearly beneficial particularly for the younger age group with impingement signs.

There has not been any study demonstrating the survival analysis of ankles which underwent arthroscopy for impingement or OA. One series (8) indicated that ankle arthroscopy achieved good to excellent results in 73% of subjects at 2 years follow-up. However, the follow-up period is rather short, so the long term results have not been documented.

Aroen and Granlund (1) have reported that ankle arthroscopy is useful in alleviating symptoms of impingement, but has no value in treating osteoarthritis. However the current study indicates that there is a role for arthroscopy in the management of osteoarthritic ankles, at least as a temporising measure. Our results showed that 28% of osteoarthritic ankles required further major surgery. This finding supports a report by Cheng and Ferkel (4) in which operative arthroscopy for ankle

arthritis has not met with great success ; however, recent studies have shown that it can provide an interim alternative to arthrodesis in early arthritis with preserved range of motion.

Parisien and Vangsnes (21) reported 85% satisfaction rate in arthroscopically treated ankles at 3 year follow-up. However, his study group was relatively small and included a young age group.

A recent study by Strecker *et al* (24), evaluating arthroscopy for ankle osteoarthritis, showed 57% excellent to good results, 43% fair to poor results, based on patient satisfaction.

Ogilvie-Harris *et al* (18) reported results of ankle arthroscopy on 27 osteoarthritic ankles. Seventeen patients showed improvement, but only 2 returned to normal function.

None of these authors report further major surgery as the primary measure of outcome and analysis was made of the temporal failure pattern.

It is not surprising to find no statistical significance in the survival rate between the two age groups of the OA patients, as ankle arthrodesis remains the gold standard for the operative treatment of advanced ankle arthritis (22).

Selection for major surgery is always a balance against severity of symptoms and the patient's ability to perform his normal life activities without undue pain. The presence of OA increases the incidence of major surgery regardless of age. However, none of the patients suffering from impingement symptoms have required further major surgery.

The failure pattern of arthroscopically treated ankles with OA indicates an initial failure in the first two years, then the failure rate slows down considerably. It is likely that this rate reflects the disease progression particularly in the osteoarthritic group. The early failure rate in osteoarthritic ankles indicates that arthroscopy is an unsuitable treatment for some ankles.

The outcome endpoint of this study – further major surgery – was chosen over further surgery e.g. ankle arthroscopy for two reasons. Many patients would go for a repeat arthroscopy. Major surgery is a hard end point that patients want to avoid. However, it is inevitably influenced in its timing by subjective judgement by both surgeon and patient.

In conclusion, this paper addresses the prognosis, and not the effectiveness of arthroscopy in the treatment of ankle disorders, namely impingement and arthritis. Arthroscopically treated impingement ankles were found to have an excellent prognosis, while osteoarthritic ankles had a less favoured prognosis. From a practical point of view, these patients can be confidently discharged from clinic if failure did not occur in 24 months.

REFERENCES

1. **Aroen A, Granlund OG.** [Ankle arthroscopy—indications, findings and results.] (Norwegian). *Tidsskr Nor Laegeforen* 1999 ; 119 : 658-560.
2. **Baker CL, Graham JM, Jr.** Current concepts in ankle arthroscopy. *Orthopedics* 1993 ; 16 : 1027-1035.
3. **Baker CL Jr, Morales RW.** Arthroscopic treatment of transchondral talar dome fractures : a long-term follow-up study. *Arthroscopy* 1999 ; 15 : 197-202.
4. **Cheng JC, Ferkel RD.** The role of arthroscopy in ankle and subtalar degenerative joint disease. *Clin Orthop* 1998 ; 349 : 65-72.
5. **Demaziere A, Ogilvie-Harris DJ.** [Operative arthroscopy of the ankle. 107 cases.] (French). *Rev Rhum Mal Ostéoartic* 1991 ; 58 : 93-97.
6. **Econopouly DS, Perlman MD, Notari MA, Boiardo RA.** The use of an ankle joint distractor in ankle arthroscopy. *J Foot Surg* 1992 ; 31 : 96-99.
7. **Egol KA, Parisien JS.** Impingement syndrome of the ankle caused by a medial meniscoid lesion. *Arthroscopy* 1997 ; 13 : 522-525.
8. **Feder KS, Schonholtz GJ.** Ankle arthroscopy : review and long-term results. *Foot Ankle* 1992 ; 17 : 382-385.
9. **Ferkel RD, Karzel RP, Del Pizzo W, Friedman MJ, Fischer SP.** Arthroscopic treatment of anterolateral impingement of the ankle. *Am J Sports Med* 1991 ; 19 : 440-446.
10. **Ferkel RD, Small HN, Gittins JE.** Complications in foot and ankle arthroscopy. *Clin Orthop* 2001-391 : 89-104.
11. **Hintermann B, Regazzoni P, Lampert C, Stutz G, Gachter A.** Arthroscopic findings in acute fractures of the ankle. *J Bone Joint Surg* 2000 ; 82-B : 345-351.
12. **Kumai T, Takakura Y, Higashiyama I, Tamai S.** Arthroscopic drilling for the treatment of osteochondral lesions of the talus. *J Bone Joint Surg* 1999 ; 81-A : 1229-1235.
13. **Lahm A, Erggelet C, Steinwachs M, Reichelt A.** Arthroscopic management of osteochondral lesions of the talus : results of drilling and usefulness of magnetic resonance imaging before and after treatment. *Arthroscopy* 2000 ; 16 : 299-304.
14. **Lee JW, Suh JS, Huh YM, Moon ES, Kim SJ.** Soft tissue impingement syndrome of the ankle : diagnostic efficacy of MRI and clinical results after arthroscopic treatment. *Foot Ankle Int* 2004 ; 25 : 896-902.
15. **Liu SH, Nuccion SL, Finerman G.** Diagnosis of anterolateral ankle impingement. Comparison between magnetic resonance imaging and clinical examination. *Am J Sports Med* 1997 ; 25 : 389-393.
16. **Lombardi CM, Silhanek AD, Connolly FG.** Modified arthroscopic excision of the symptomatic os trigonum and release of the flexor hallucis longus tendon : operative technique and case study. *J Foot Ankle Surg* 1999 ; 38 : 347-351.
17. **Ogilvie-Harris DJ, Gilbert MK, Chorney K.** Chronic pain following ankle sprains in athletes : the role of arthroscopic surgery. *Arthroscopy* 1997 ; 13 : 564-574.
18. **Ogilvie-Harris DJ, Mahomed N, Demaziere A.** Anterior impingement of the ankle treated by arthroscopic removal of bony spurs. *J Bone Joint Surg* 1993 ; 75-B : 437-40.
19. **Ogilvie-Harris DJ, Sarrosa EA.** Arthroscopic treatment after previous failed open surgery for osteochondritis dissecans of the talus. *Arthroscopy* 1999 ; 15 : 809-812.
20. **Ogilvie-Harris DJ, Sarrosa EA.** Arthroscopic treatment of post-traumatic cysts of the talus. *Arthroscopy* 2000 ; 16 : 197-201.
21. **Parisien JS, Vangsness T.** Operative arthroscopy of the ankle. Three years' experience. *Clin Orthop* 1985-199 : 46-53.
22. **Raikin SM.** Arthrodesis of the ankle : arthroscopic, mini-open, and open techniques. *Foot Ankle Clin* 2003 ; 8-2 : 347-359.
23. **Rasmussen S, Hjorth Jensen C.** Arthroscopic treatment of impingement of the ankle reduces pain and enhances function. *Scand J Med Sci Sports* 2002 ; 12 : 69-72.
24. **Strecker W, Eisele R, Fritz M, Kinzl L, Hehl G.** [Value of arthroscopy in the treatment of upper ankle arthritis.] (German). *Unfallchirurg* 2005 ; 108-6 : 461-469.
25. **Tol JL, Verheyen CP, van Dijk CN.** Arthroscopic treatment of anterior impingement in the ankle. *J Bone Joint Surg* 2001 ; 83-B : 9-13.
26. **Tuzuner S, Aydin AT.** Arthroscopic removal of an osteoid osteoma at the talar neck. *Arthroscopy* 1998 ; 14 : 405-409.
27. **van Dijk CN, Scholten PE, Krips R.** A 2-portal endoscopic approach for diagnosis and treatment of posterior ankle pathology. *Arthroscopy* 2000 ; 16 : 871-876.