



Spontaneous kyphotic collapse followed by autostabilisation secondary to cervical osteomyelitis in an intravenous drug abuser

Ranganathan ARUN, Anand Vijay KASBEKAR, S. M. Hossein MEHDIAN

From the Center for Spinal Studies and Surgery, Nottingham University Hospital, Nottingham, United Kingdom

There is a high risk of cervical osteomyelitis in intravenous drug abusers due to the use of jugular veins for administration of drugs. Here described is a case of rapid vertebral body destruction at two levels leading to a progressive kyphotic deformity followed by autofusion, secondary to cervical osteomyelitis. The case report goes on to hypothesise about the unique manner of progression of untreated cervical osteomyelitis with a rapid onset of kyphotic deformity and associated severe bone destruction in an intravenous drug abuser. Due to the high incidence of osteomyelitis in intravenous drug abusers, there should be a low threshold to investigate for this condition and early magnetic resonance imaging is vital. It alerts the treating spine surgeon to the fact that early immobilisation is crucial in these cases to prevent a severe impending deformity that can be surgically challenging.

Keywords : cervical spine ; osteomyelitis ; kyphotic collapse.

acute severe cervical kyphosis and rapid vertebral body destruction followed by auto-stabilisation at two levels, secondary to pyogenic osteomyelitis in an intravenous drug abuser.

CASE REPORT

A 33-year-old female intravenous drug (heroin) abuser presented with a 6 week history of neck pain associated with right sided brachialgia. She did not give any history of trauma or constitutional ailments to suggest infection. She had no other medical problems except for ongoing treatment of four months duration for Candida endophthalmitis with oral Fluconazole 200 milligrams (mgs) once daily, oral Prednisolone 60 mgs once daily, Dexamethasone and Atropine eye drops. She was being treated with intra vitreal instillations of Amphotericin B, Amikacin and Vancomycin. On examination of

INTRODUCTION

Osteomyelitis of the spine is rare and represents 1% of all bone infections. Of these, 3-10% occur in the cervical spine (6). Literature about osteomyelitis of the cervical spine is therefore scarce. Despite advances in imaging, the diagnosis is often delayed and the varied patterns of progression of this condition continue to be a challenge to the treating spine surgeon. This is the first report of

■ Ranganathan Arun, MRCS (Ed), Spinal Research Fellow.
■ Anand Vijay Kasbekar, BMBS, B med Sci (Hons), Pre-registration house officer.

■ S. M. Hossein Mehdian, MS (Orth), MD, FRCS (Ed), Consultant Spine Surgeon.

Queen's Medical Centre, Nottingham, United Kingdom.

Correspondence : Ranganathan Arun, 45 St Cuthbert Avenue, Marton in Cleveland, Middlesbrough – TS7 8RG, UK.
E-mail : arearoon@yahoo.com

© 2007, Acta Orthopædica Belgica.

the neck, the patient had severe tenderness around the C-2/3 spinous processes. She also had pain on extension and lateral rotation. There was no neurological deficit in both upper and lower limbs. Plain radiographs of the cervical spine (fig 1a) showed a reduced disc space at the C-3/4 level and Grade I spondylolisthesis at C-2/3 and C-4/5. Laboratory investigations revealed a normal total white cell count (TWCC) - $4.7 \times 10^9/L$, erythrocyte sedimentation rate (ESR) - 17 mm/hr and C-reactive protein (CRP) - 7 mg/l. A diagnosis of degenerative cervical disc disease was considered and it was decided to perform magnetic resonance imaging (MRI) of the cervical spine. However, the patient self-discharged against medical advice and refused any further investigations.

A month later, the patient presented again to the Accident and Emergency department with complaints of severe neck pain. She was afebrile and had no neurological deficit. Plain radiographs were not performed at this stage and the patient declined admission. However, she agreed to have an MRI scan of the cervical spine as an outpatient the following week but again failed to keep this appointment. Three weeks later, she presented complaining of severe neck pain, dysphagia and constitutional symptoms. She was pyrexial ($39.2^\circ C$) and also complained of chills and rigors. On examination, she had severe tenderness over the spinous processes of C-2 to C-6. There was a palpable gap between the C-3/4 spinous processes with a gibbus. She had no neurological deficit but her forward vision was impaired and her neck, completely rigid with gross restriction of movements. Plain radiographs (fig 1b) of the neck showed a kyphotic deformity at C-2/3 with collapse of the C-3 vertebral body and C3/4 interbody fusion. Laboratory investigations revealed a total white cell count (TWCC) of $18.3 \times 10^9/L$, erythrocyte sedimentation rate (ESR) of 72 mm/hr and C-reactive protein (CRP) of 110 mg/l.

MRI of the cervical spine (fig 3a) showed a huge prevertebral abscess communicating with the anterior aspect of the C3 vertebral body. Marrow oedema was also noted in the lateral masses and vertebral bodies suggesting vertebral osteomyelitis. Under local anaesthetic and computed tomography

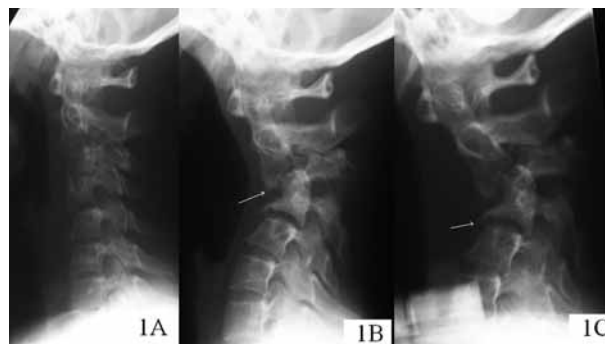


Fig. 1. — Plain lateral radiographs of the cervical spine showing sequential progression of the kyphotic deformity ; a) plain lateral radiograph at initial presentation, note obliteration of the cervical lordosis with Grade I spondylolisthesis at C2/3 and C4/5. Also, note the reduced C3/4 disc space. b) plain lateral radiographs of the cervical spine, 7 weeks later, showing a kyphotic deformity at C2/3 and fusion of C3/4 vertebral bodies. White arrowhead indicates the phenomenon of anterior point loading of C2 and preferential destruction of the anterior cortex of C3/4. c) radiographs at the end of 10 weeks with gross destruction of C3/4 bodies and toppling of C2 on the rounded superior endplate of C3. The arrowhead indicates fluffy new bone formation.

(CT) guidance 30 millilitres of pus was aspirated using a 14-gauge needle. The culture from the aspirate grew *Staphylococcus aureus* sensitive to Fusidic acid, Flucloxacillin and Rifampicin. Blood cultures and tests for tuberculosis were negative. The patient was found to be Hepatitis C positive (Reverse Transcriptase Polymerase Chain Reaction) and negative for Human Immunodeficiency virus. She was treated with Fusidic acid 30 mgs/kg body weight/day in divided doses IV 8 hourly and oral Rifampicin 300 mgs 8 hourly. Halo traction was started with 2 pounds (lbs) and gradually increased by 1 lb every 24 hours. The patient's neck complaints subsequently resolved and her constitutional symptoms improved. With each increment in weight, repeat radiographs of the cervical spine were taken and serial neurological assessments were performed. She remained stable throughout. Once 8 lbs of traction had been achieved, a halo vest was applied in this position. Laboratory investigations at the end of one week showed a decreased level of inflammatory markers - ESR 39 mm/hr, CRP- 65 mg/l and TWCC - $9.3 \times 10^9/L$.

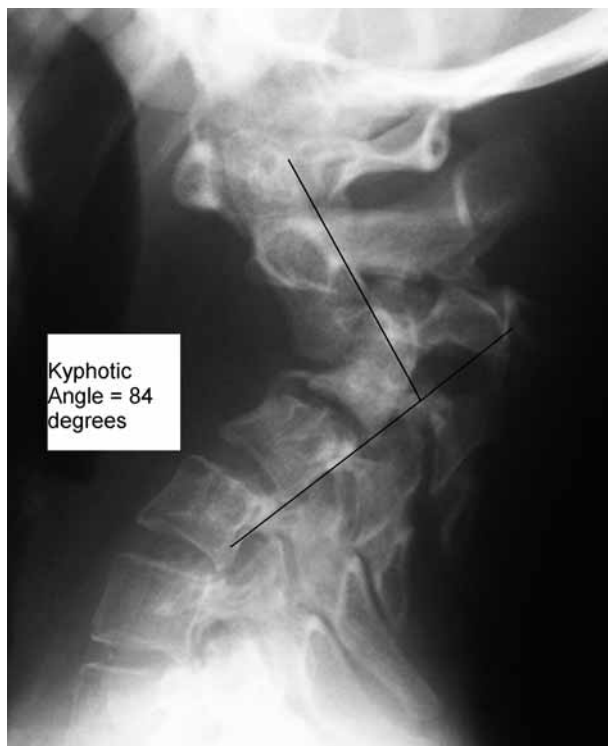

Fig. 2. — Plain lateral radiographs at the end of 3 months of halo vest immobilisation and antibiotic treatment showing an 84° kyphotic deformity and ossific bridge formation between C3/4.

A repeat MRI scan (fig 3) showed resolution of the abscess and decrease of marrow oedema by the end of three weeks and a spinal realignment procedure to correct the kyphotic deformity was planned. However, the patient refused surgery and hence was discharged with a halo vest and oral Flucloxacillin 1 g daily and Rifampicin 300 mg 8 hourly for a total period of three months. At three months follow-up, laboratory investigations showed normalisation of the inflammatory markers ; ESR 12 mm/hr, CRP 5 mg/L, TWCC $5.2 \times 10^9/L$. Plain radiographs (fig 2) showed a kyphotic deformity measuring 84° at C2/3 and fusion between C3/4 and C5 by a bony bridge. Antibiotics and the halo vest were removed and the patient was advised to wear a Philadelphia collar for a further period of three months.

At 1-year follow-up, no further progression of neck deformity was noted and the patient had complete resolution of symptoms. CT scan (fig 4)

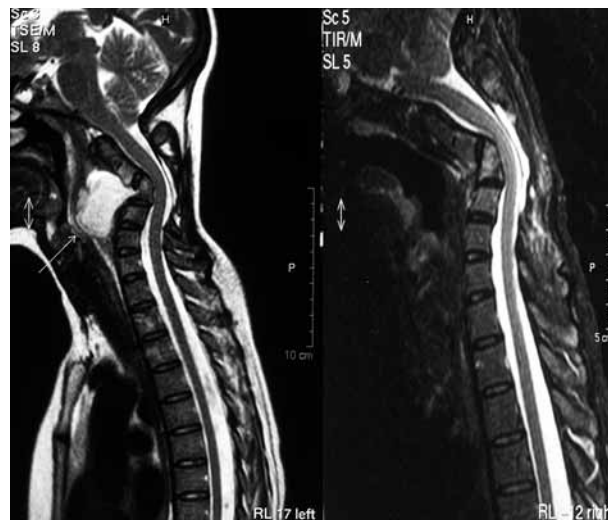


Fig. 3. — T2 weighted sagittal MRI scan of the neck (left) 7 weeks after initial presentation, showing a huge anterior prevertebral abscess compressing on the oesophagus, causing dysphagia. Also, note the communication with the C3 vertebral body indicating the anterior cortex of the bone was breached, leading to discharge of the purulent material into the prevertebral space. The MRI scan (right) after CT guided aspiration and 3 months of treatment with halo vest immobilisation and antibiotic treatment showing complete resolution of the abscess.

showed autostabilisation of the anteroinferior tip of C2 with the superior end plate of C5. Sections through the facet joints (fig 4b) showed facet fusion at C2/3, which was responsible for preventing facet subluxation and neurological deficit. She has declined to undergo any surgical procedures to correct her kyphotic deformity.

DISCUSSION

In IV drug users, the rate of cervical lesions has been reported to be as high as 27% (8). Due to this high incidence, IV drug abusers have to be investigated appropriately at an early stage. The frequent use of the jugular veins to administer drugs probably contributes to the high incidence of cervical osteomyelitis in these cases (3). Periostitis and osteomyelitis can occur in drug abusers not only by haematogenous dissemination of the infecting organisms, but also as a result of introduction of

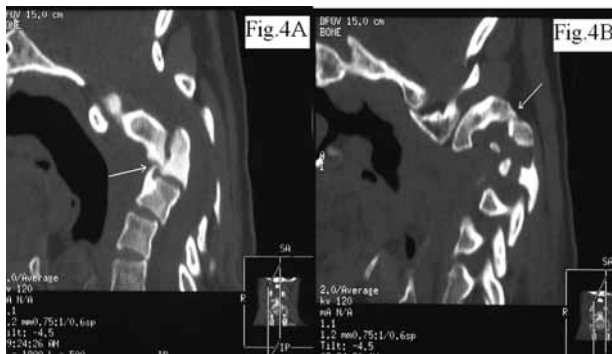


Fig. 4. — CT scans of the neck, sagittal sections in different planes at the end of 1 year. Section (a) shows an ossified bridge of bone between the anteroinferior tip of C2 and superior endplate of C5 (white arrow). b) is a slice through the facet joints showing fusion between the C2 and C3 facet joint. This fusion prevented C2/3 subluxation despite the gross rotation of the C2 vertebral body and hence the canal dimensions were maintained.

bacteria into the bone by injecting through infected skin and subcutaneous tissues directly into the periosteum.

The large diameter of the cervical spinal cord relative to the spinal canal and the significant range of motion of the cervical spine make cervical osteomyelitis a unique entity. Even small epidural infections can cause a neurological deficit. Bone destruction and ligamentous laxity can thus manifest as severe instability, deformity, or a neurological deficit.

The most common screening investigation for cervical disorders remains a plain radiograph. However, plain radiographs lag behind clinical presentation in cervical osteomyelitis. The usual delay in diagnosis has been reported to be two to four months despite the use of imaging techniques, thereby leading to a late diagnosis and hence complications (4). As was the situation in our case, plain radiographs in early stages of cervical osteomyelitis closely mimic degenerative changes thereby leading to an incorrect diagnosis. In addition, widening of the perivertebral soft tissue on lateral radiographs of the cervical spine is difficult to detect. CT scans also lag by showing osteolytic lesions only after several weeks of infection but have an advantage of being able to detect an early epidural or perivertebral abscess. Radioisotope

scanning is useful in diagnosis and follow-up allowing secondary sites of involvement to be seen. Palestro and Kim (7) used increased or decreased activity as criteria for infection and stated that for diagnosing vertebral osteomyelitis the accuracy of leukocyte imaging (indium 111) and technetium 99 bone imaging was similar, 66% and 63% respectively.

MRI is the best form of imaging for a suspected spondylodiscitis (5). It is more sensitive and accurate than plain films and radioisotope scanning especially in the early stages of the condition. This aids prompt diagnosis before the onset of neurological symptoms allowing conservative treatment. MRI in the follow-up period is also possible despite a halo vest for stabilisation. Non-compliance of the patient led to a delay in diagnosis in this case and was unavoidable. This has however, given us an opportunity to visualise the natural course of the disease in IV drug abusers and realise its destructive potential.

Blood investigations can be important adjuncts in screening for cervical osteomyelitis and can help differentiate between degenerative changes and infection. They are also useful in monitoring response to therapy. It should be noted that existing literature states that leukocyte count is typically not elevated in spinal infections (2, 6). Instead levels of ESR are more commonly elevated ranging from 73% to 100% of cases (2). Studies also show that leukocyte count and ESR are consistently elevated when spinal infections are associated with a prevertebral or epidural abscess. This pattern was seen in our case report when inflammatory markers were fairly low during the early presentations of the disease and underwent a sudden elevation at the third time of presentation when there was an associated prevertebral abscess.

Staphylococcus aureus is the predominant organism responsible for 80% of spinal infections (6). However Sapico *et al* (9) showed that in intravenous drug abusers Gram-negative aerobic bacilli accounted for 82% of infections, and *Pseudomonas* species comprised 66% of the total. Ninety-two percent of these patients responded to parenteral antibiotic therapy administered for four weeks or longer. The study noted the good

prognosis for intravenous drug abusers with vertebral osteomyelitis following appropriate therapy, without any deaths or permanent neurologic sequelae experienced.

Vertebral osteomyelitis can be managed in most cases non-operatively, using intravenous antibiotics and external immobilisation (1). Surgery is indicated when uncontrolled infection, abscess formation, neurological deficit or intractable pain caused by instability and kyphosis are encountered (1). Our patient did not have neurological compromise even though the progression of deformity was rapid, as the cross-section of the spinal canal was maintained.

We hypothesise that the purulent material from the C3 vertebral body burst out of the anterior cortex leading to the formation of the prevertebral abscess. This caused weakening of the C3 vertebral body. The muscle spasm obliterated the normal cervical lordosis and this was worsened by the subsidence of the C3 vertebral body. The moment arm substantially increased as the kyphosis worsened leading to destructive forces on the vertebral body thereby leading to preferential destruction of the anterior cortex of the C3/4 vertebral bodies. Early fusion of facet joints in the upper cervical spine is known to occur following septic arthritis (10). We noticed in our case that early fusion of the C2/3 facet had occurred and that this was instrumental in preventing subluxation of the C2/3 facet despite the severe kyphotic deformity (fig 4b). The fused facet acted as a hinge for point loading of C2 onto the anterior cortex of C3 and C4 vertebral bodies leading to their collapse. The net effect was a vertically orientated C2/3 intervertebral disc. Surprisingly, even this extreme degree of rotation did not cause a facet subluxation and hence, the absence of a neurological deficit in our case. Contact of the antero-inferior tip of C2 with the C5 vertebral body and formation of an ossific bridge (fig 4a) ultimately retarded the kyphotic progression.

CONCLUSIONS

The objective of this case report is to illustrate a unique manner of progression of cervical

osteomyelitis with spontaneous vertebral body destruction leading to a severe kyphotic deformity. In IV drug abusers, there should be a low threshold to investigate for osteomyelitis and an MRI scan is the investigation of choice. Cervical spinal osteomyelitis if untreated is prone to an extreme degree of deformity due to the small size of the cervical vertebral bodies and a high degree of ligamentous laxity permitting an excessive range of motion. This case also alerts the treating spine surgeon to the fact that early immobilisation (internal or external) is necessary in these cases to prevent a severe impending deformity, which can be surgically challenging.

REFERENCES

1. **Abramovitz JN, Batson RA, Yablon JS.** Vertebral osteomyelitis : The surgical management of neurologic complications. *Spine* 1986 ; 11 : 418-420.
2. **Digby JM, Kersley JB.** Pyogenic nontuberculous spinal infection. *J Bone Joint Surg* 1979 ; 61-B : 47-55.
3. **Endress C, Guyot DR, Fata J, Saliccioli G.** Cervical osteomyelitis due to i.v. heroin use : radiologic findings in 14 patients. *Am J Roentgenol* 1990 ; 155 : 333-335.
4. **Gasbarrini AL, Bertoldi E, Mazzetti M et al.** Clinical features, diagnostic and therapeutic approaches to haematogenous vertebral osteomyelitis. *Eur Rev Med Pharmacol Sci* 2005 ; 9 : 53-66.
5. **Gundry CR, Fritts HM.** Magnetic resonance imaging of the musculoskeletal system : the spine. *Clin Orthop* 1998 ; 346 : 262-278.
6. **Hadjipavlou AG, Mader JT, Necessary JT, Muffoletto AJ.** Hematogenous pyogenic spinal infections and their surgical management. *Spine* 2000 ; 25 : 1668-1679.
7. **Palestro CJ, Kim CK.** Radionuclide diagnosis of vertebral osteomyelitis : Indium-111-leukocyte and technetium-99-methylene diphosphonate bone scintigraphy. *J Nucl Med* 1991 ; 32 : 1861-1865.
8. **Sapico FL, Montgomerie JZ.** Vertebral osteomyelitis. *Infect Dis Clin North Am* 1990 ; 4 : 539-550.
9. **Sapico FL, Montgomerie JZ.** Vertebral osteomyelitis in intravenous drug abusers : report of three cases and review of the literature. *Rev Infect Dis* 1980 ; 2 : 196-206.
10. **Spies EH, Stücker R, Reichelt A.** Conservative management of pyogenic osteomyelitis of the occipitocervical junction. *Spine* 1999 ; 24 : 818-822.