



A simple external fixator for complex finger fractures

Roshin K. THOMAS, Rajinder S. GAHEER, Rupert D. FERDINAND

From Dumfries and Galloway Royal Infirmary, Dumfries, United Kingdom

Complex fractures of phalangeal bones in the hand are difficult to treat. External fixation is an effective method of treatment particularly when internal fixation is not possible due to comminution and associated soft tissue injury.

A variety of commercial fixators are available for the treatment of hand fractures. However, these fixators are costly and need a sufficient degree of expertise and familiarity for their use.

We describe a very simple fixator which is stable, lightweight and can be easily constructed with materials readily available in most trauma theatres.

Keywords : hand ; phalanges ; metacarpals ; fractures ; external fixator.

INTRODUCTION

Complex fractures of the phalanges involve highly comminuted fractures with significant intra-articular extension (fig 1). These may present as open fractures with associated neurovascular damage, tendon injury and sometimes with a fracture dislocation of the adjacent joint. The management of intra-articular fractures involving the interphalangeal and metacarpophalangeal joints of the hand remains controversial (6) and difficult (5). The principles of management (10) involve restoration of articular congruity and fixation of the fracture with an internal or external fixation device. Early mobilisation of the affected joint improves functional outcome and this can be best achieved by either internal fixation or a dynamic external fixator.

Open reduction and internal fixation may not be suitable in comminuted fractures due to the small size of fracture fragments (5) and it is also not ideal when there is risk of infection due to open wounds and when further soft tissue damage is to be avoided. External fixation offers an effective treatment option in the management of these difficult fractures and a variety of external fixators are available for this purpose.

Commercial external fixators although versatile, need expertise in their application (1). They are often costly (9) and are not readily available in many trauma theatres. Due to these drawbacks, various innovative, improvised external fixators have been described for hand fractures. However, these fixators do not provide the required stability and have their own shortcomings.

We describe a stable, 'easy to construct' external fixator which can be used for a variety of hand fractures, particularly in an emergency setting, and possibly as a definitive fixation device.

■ Roshin K. Thomas, Clinical Fellow, Trauma and Orthopaedics.

■ Rajinder S. Gaheer, Clinical Fellow, Trauma and Orthopaedics.

■ Rupert D. Ferdinand, Consultant Orthopaedic Surgeon.
Dumfries and Galloway Royal Infirmary, Dumfries, United Kingdom.

Correspondence : Roshin K. Thomas, 64 Hatters Court, Stockport, United Kingdom, SK1 3EB.

E-mail : thomas_rkt@yahoo.com

© 2008, Acta Orthopædica Belgica.

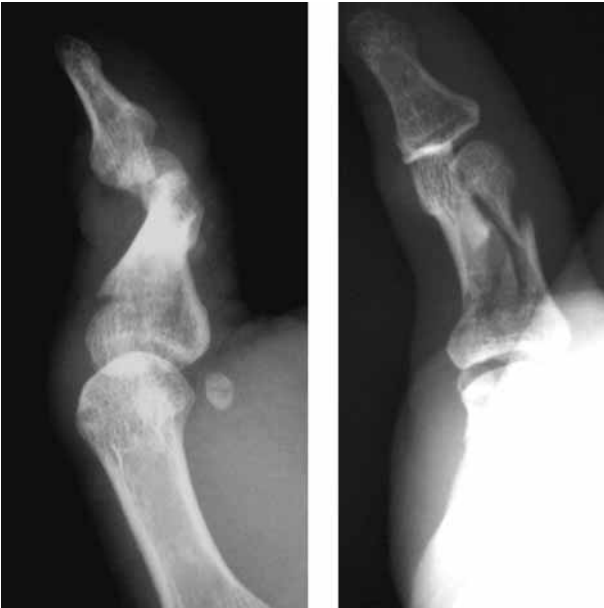

Fig. 1. — Radiographs showing a comminuted fracture of the proximal phalanx of the thumb with an associated fracture dislocation of the interphalangeal joint.

Procedure

This fixator construct requires four 1.6 mm Kirschner wires (K-wires), a plastic K-wire storage tube (fig 2), and 10 ml of low viscosity bone cement. Although we used smooth K-wires, threaded K-wires can also be used to improve bone purchase. After initial debridement of any open wounds, the fractured phalanx is reduced with traction and manipulation and checked with the image intensifier. Once acceptable reduction has been achieved, two parallel bicortical 1.6 mm K-wires are introduced into the proximal fragment of the fractured bone (phalanx or metacarpal). The fracture is then pulled out to length and rotational deformity corrected. Two bicortical K-wires are then inserted into the distal fragment. The wires are passed with care at the 10 O'clock position as described by Drenth *et al* to avoid the neurovascular bundle and image guidance helps achieve a good position within the bone. Ideally it is best to place all the K-wires in the same sagittal plane after correcting finger rotation. When the K-wires are used to fix a single fractured bone (phalanx or




Fig. 2. — A plastic K-wire storage tube with a K-wire in situ. One end of the tube has a cap and the other end is sealed.

metacarpal), it allows for early mobilisation of adjacent joints.

The construct may be used to span adjacent joints when the fracture pattern necessitates (fig 3). A plastic K-wire storage tube of one of the K-wires that have been used is then chosen. The sealed end of the tube is simply cut away with a scissor after measuring the required length. This end can be sealed, after cementing, with the cap of one of the other K-wire tubes. A tube open at both ends helps the flow of viscous cement and prevents air pockets in the cement mantle. The plastic tube is then placed beside the finger after correcting the length and rotation of the fractured phalanx or metacarpal. The locations corresponding to the K-wires are marked on the tube. These points on the plastic tube are then predrilled (a K-wire can be used for this purpose). These openings can be widened easily to accommodate the minor variations in angles at which the four K-wires lie in the sagittal plane. The K-wires are passed through these holes in the tube and the tube is lowered giving adequate clearance from the skin. As an alternative method, the K-wire storage tube can be kept parallel to the

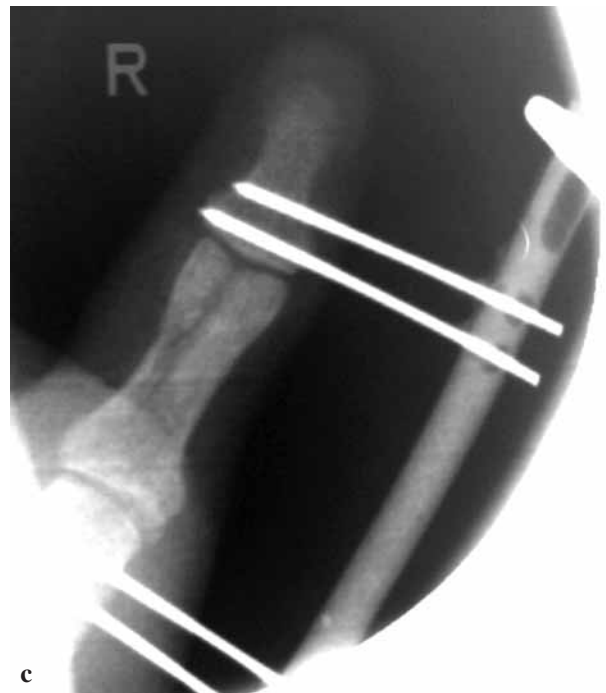
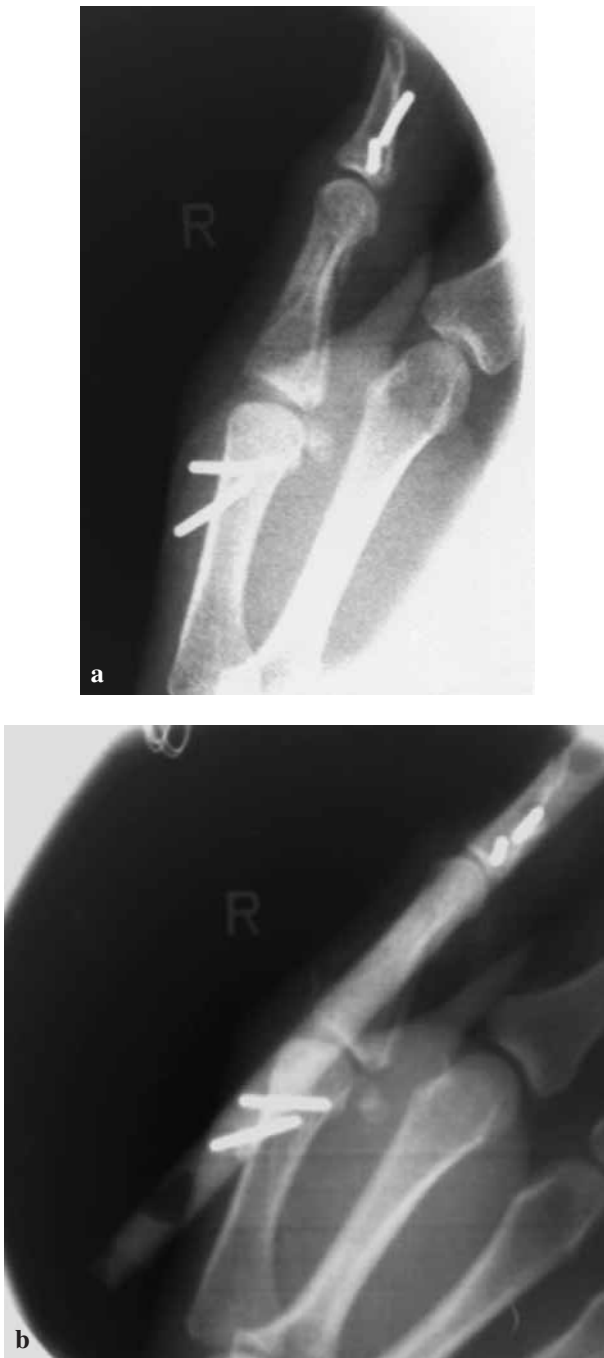
Fig. 3. — Intraoperative images. This construct was used to span two joints as the fracture line extended into the metacarpophalangeal and interphalangeal joints of the thumb. The two lateral view images are 1) without fixator 2) with radiolucent fixator *in situ*.

and around the pin sites to contain any extruding cement. Elevation of the finger helps by gravity assisted filling of the tube. Once the entire tube fills with cement, caps are applied at both ends and the cement allowed to harden. The protruding end of the K-wires can be cut flush with the tube or left 1 cm proud and covered with bone cement before it hardens. This prevents damage from sharp points on the fixator construct. Excess cement extruding from the tube at K-wire sites is cleared while still soft. Once the cement hardens this fixator provides stable fixation of the fractured digit (fig 4).

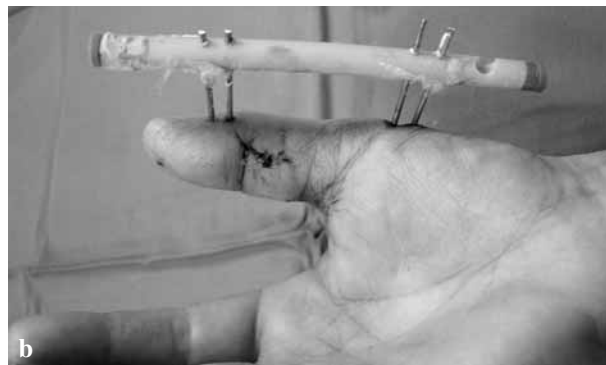
DISCUSSION

Commercial external fixators for hand fracture management have the best results when used at specialised hand units with sufficient expertise in their application. Unlike commercial external fixators, improvised fixators are simple to use even

finger along the intended plane of insertion of K-wires. The K-wires can then be drilled directly through the tube into the underlying bone. Low viscosity bone cement is then loaded in a 10 ml syringe and injected from the distal end of the plastic tube. Gauze dressings are placed over the finger

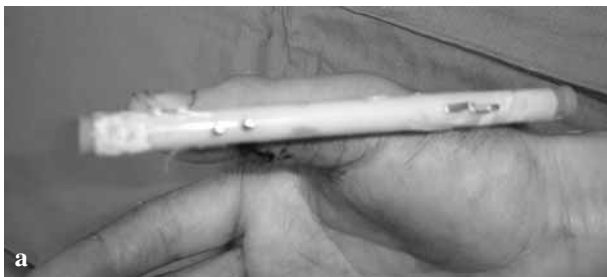

Fig. 4. — Clinical photographs with the fixator *in situ* showing a healing wound on the radial aspect of the thumb.



by general orthopaedic units dealing with hand fractures. The technique of external fixation using K-wires bonded with methylmethacrylate resin was first described by Crockett (3) in 1974. These early fixators lost popularity as they were cumbersome and not ideal for hand fracture treatment. McCulley and Hasting (7) described the use of the plastic sheath of an intravenous cannula as a crossbar to hold K-wires in place. However, the length of the sheath was inadequate and often the sheath slipped over the smooth K-wires to abut the skin, often losing fracture reduction. Furthermore, introducing parallel K-wires through the hard plastic sheath of narrow width was not an easy task. The fixator that we have described overcomes these shortcomings. The K-wire storage tube has sufficient length to act as a cross bar for several K-wires and can cover the entire length of the hand if required. It is made of soft plastic and therefore can be easily perforated at designated points to accommodate the K-wires. After the cement inside the tube hardens, it becomes a rigid construct but remains lightweight.

It is simple to construct even with basic orthopaedic experience and all the materials required for this fixator are readily available in most theatres. Unlike many commercial external fixators, this construct enables good lateral view images as the cement mantle is radiolucent. This fixator can be easily removed in the clinic, often without the need for a digital block anaesthesia. Although this fixator can be used in various fractures, its application should be based on the accepted principles in the management of hand fractures.

The fixator functions primarily due to its ability to achieve and maintain fracture reduction by capsuloligamentotaxis (11). This may not be sufficient to reduce centrally impacted articular fragments which would require open reduction (2) or early mobilisation of the distracted joint (dynamic traction) to benefit from articular remodelling (8).

Even in these situations, the fixator we have described is an ideal temporary device that prevents soft tissue contracture while allowing for the wounds to heal and planning for definitive fixation. This may mean referral to a specialised hand surgery unit as dynamic traction devices are technically demanding to construct. However, in many situations, this improvised fixator can be used in the definitive management of fractures if satisfactory fracture reduction can be achieved and maintained by ligamentotaxis. We recommend this effective, 'easy to use' fixator in the management of fractures involving the small bones of the fingers where complex fixators are not available or the expertise at using them is lacking.

REFERENCES

1. Aro HT, Hein TJ, Chao EY. Mechanical characteristics of an upper-extremity external fixator. *Clin Orthop* 1990 ; 253 : 240-250.
2. Bilos ZJ, Vender MI, Bonavolonta M, Knutson K. Fracture subluxation of proximal interphalangeal joint treated by palmar plate advancement. *J Hand Surg* 1994 ; 19-A : 189-195.
3. Crockett DJ. Rigid fixation of bones of the hand using K wires bonded with acrylic resin. *Hand* 1974 ; 6 : 106-107.

4. **Drenth DJ, Klasen HJ.** External fixation for phalangeal and metacarpal fractures. *J Bone Joint Surg* 1998 ; 80-B : 227-230.
5. **Keramidas EG, Miller G.** The Suzuki frame for complex intraarticular fractures of the thumb. *Plastic Reconstr Surg* 2005 ; 116 : 1326-1331.
6. **Khan W, Fahmy N.** The S-Quattro in the management of acute intraarticular phalangeal fractures of the hand. *J Hand Surg* 2006 ; 31-B : 79-92.
7. **McCulley SJ, Hasting C.** External fixator for the hand : a quick, cheap and effective method. *J Royal Coll Surgeons Edinb* 1999 ; 44 : 99-102.
8. **Schenck RR.** The dynamic traction method. Combining movement and traction for intra-articular fractures of the phalanges. *Hand Clinics* 1994 ; 10 : 187-198.
9. **Schuind F, Cooney WP 3rd, Burny F, An KN.** Small external fixation devices for the hand and wrist. *Clin Orthop* 1993 ; 293 : 77-82.
10. **Ugwonali OF, Jupiter JB.** Mini external fixation in the hand. *Techniques in Hand Upper Extr Surg* 2006 ; 10 : 187-196.
11. **Vidal J, Buscayret C, Connes H.** Treatment of articular fractures by ligamentotaxis with external fixation. In : A. F. Brooker Jr., C. C. Edwards (eds). *External Fixation. The Current State of Art.* Williams and Wilkins, Baltimore, 1979, pp 75-81.