



Free vascularised corticoperiosteal bone flaps in the treatment of non-union of long bones An ignored opportunity ?

Andrzej KAMINSKI, Heinz BÜRGER, Ernst Josef MÜLLER

From the Landeskrankenhaus Klagenfurt, Austria

Five patients with atrophic or septic non-union of long bones were treated with free vascularised corticoperiosteal bone flaps. The patients had undergone an average of nine prior operations (range, 2-29). The treatment was combined with repeat internal fixation in four patients. Treatment took place an average of 25.5 months (range 5-83 months) after the initial injury. The thin corticoperiosteal grafts were harvested from the supracondylar region of the femur. One patient died from unrelated causes 2.5 months postoperatively. In the other four patients, bone healing was documented after an average of 7.7 months (range 6-11 months). No further operations were necessary during the follow-up period of 13.7 months on average (range 10-17 months). There were no complications associated with the procedure. The treatment presented here is complex but was successful in this small population. The procedure has the potential to become established as a treatment option for problematic bone defects.

Keywords : fracture ; non-union ; treatment ; corticoperiosteal bone flaps.

defects. Ultimately, this method can be used only in well-vascularised and non-infected defects (7). Poorly vascularised, long and/or infected defects have low chances of healing. Use of vascularised bone grafts is then a possible method of treatment. Handling these grafts is difficult as they are rigid and not malleable. They are not suitable for short defects less than 6 cm in length (3). Graft necrosis and infection are the complications associated with the procedure. The osteogenic potential of thin and malleable periosteal grafts has been investigated in defects of long bones in an animal model (4,11,12, 13). However, they are used very rarely in clinical traumatology (3,5).

This article reports the results of treatment of chronic bone defects in long bones with free vascularised corticoperiosteal bone flaps.

INTRODUCTION

Bone grafting with non-vascularised cancellous bone graft is by far the most widely used operative method in the treatment of bone defects (6). However, the availability of autologous tissue is limited and is usually sufficient only for short

■ Andrzej Kaminski, MD, Fellow.
■ Heinz Bürger, MD, Attending Orthopaedic Surgeon.
■ Ernst Josef Müller, MD, PhD, Head of Department.
Department of Traumatology, Landeskrankenhaus Klagenfurt, Austria.

Correspondence : Mr A. Kaminski, Landeskrankenhaus Klagenfurt, Unfallchirurgische Abteilung, St. Veiter Strasse 47, 9020 Klagenfurt, Austria. E-mail : kaminski@t-online.de
© 2008, Acta Orthopædica Belgica.

Table I. — General information about the treated patients

Patient	Age	Primary injury	Primary treatment	Non-union
DW	85	closed distal extra-articular humerus fracture	elsewhere : closed reduction and K-wire internal fixation	atrophic
LF	60	open proximal extra-articular forearm fracture	ORIF (plate)	septic ; fistula present (MSSA found)
PH	74	closed proximal extra-articular humerus fracture	elsewhere : ORIF (plate)	atrophic
OV	78	closed distal extra-articular humerus fracture	elsewhere : closed reduction and K-wire internal fixation	septic ; fistula present (MSSA found)
JA	41	open extra-articular lower leg fracture	external fixator (AO)	septic ; fistula present (MRSA found)

PATIENTS AND METHODS

Patient population

Five patients with non-union in the extra-articular part of long bones were treated with free vascularised corticoperiosteal bone flaps (FCPF) between 2004 and 2006. There were two women and three men with an average age of 67.6 years (range 41-85 years) (table I). Three patients were referred to us from other hospitals. Three patients had septic non-union and two patients had aseptic atrophic nonunion following fracture. All the septic non-unions were associated with fistulas and positive bacteriology (*Staphylococcus aureus*). All fractures were treated surgically initially. Prior to treatment with FCPF the patients had undergone an average of nine operations (range 2-29). At least one change of implant (range 1-6) had been performed in four of the five patients prior to FCPF. In the three septic patients, an average of eight procedures to remove the infection was performed prior to FCPF (range 3-17). These include debriding revisions and fasciocutaneous or myocutaneous flaps. The resulting non-unions were painful in all patients.

In four patients, treatment with FCPF was combined with repeat internal fixation. In one patient, FCPF was performed on its own. Treatment with FCPF took place an average of 25.5 months (range 5-83 months) after the initial injury. The patients had regular clinical and radiographic follow-up at our institution. Radiographs in two planes were taken to assess bony consolidation. Computed tomography was performed in case of doubt.

Operative technique

The operation began with excision of the non-union. This was followed by reduction and internal fixation of the affected bone. The vessels for the graft were exposed. We performed preoperative angiography in only one case of non-union in the lower limb. The FCPF was then harvested from the medial femur. Dissection was begun using a tourniquet with a medial incision along the posterior border of the vastus medialis. After longitudinal incision of the fascia, the muscle was mobilised and retracted anteriorly. The descending genicular vessels were then exposed on the periosteum of the femur (fig 1). The artery and accompanying veins were followed proximally as far as the femoral vessels. The vascular pedicle was not divided yet. An attached corticoperiosteal flap about 7-8 cm long and 4-6 cm wide was elevated with a curved osteotome (fig 1). The cortical part must remain as thin as possible (approximately 1.0 mm) in order to maintain flap malleability and thick enough not to damage the periosteal cambium layer. After releasing the tourniquet, flap perfusion was then examined. The vascular pedicle was then dissected far proximally close to the femoral artery. The flap was then wrapped around the non-union and joined to local vessels by microvascular anastomoses (fig 2). Two veins can be anastomosed for better venous outflow. We did not perform postoperative monitoring of flap circulation. Functional treatment began in all patients on the second postoperative day at the latest.

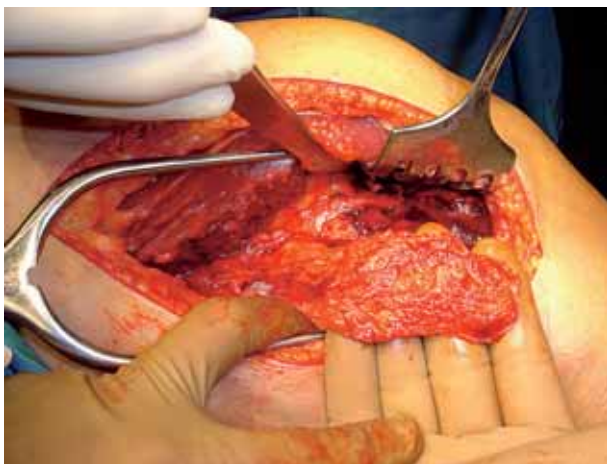


Fig. 1. — The flap is elevated, still attached to its vascular pedicle. The muscles are retracted anteriorly.

RESULTS

One 85-year old patient with atrophic non-union of the distal humerus died from unrelated causes 2.5 months postoperatively. Up to that time, no bony consolidation had been observed in this patient. There were no other postoperative complications. In the other four patients, bony consolidation of the non-union was documented after an average of 7.7 months (range 6-11 months). The four patients reported a reduction in pain compared to their preoperative condition. In two of three patients with a draining septic non-union, the fistulae healed. Antibiotic therapy according to antibiogram was continued for three to four weeks postoperatively in the infected cases. Exacerbations of osteomyelitis were not observed in these patients over an average follow-up period of 13.7 months (range 10-17 months). No further operations were performed in this follow-up period. One patient had a persistent localised fistula in the distal lower leg. This patient had had osteomyelitis of the tibia in childhood and had undergone repeated surgery because of this. At the age of 41 years, he sustained a grade II compound lower leg fracture. The initial treatment consisted of an Ilizarov fixator. He subsequently developed septic non-union with evidence of methicillin-resistant *Staphylococcus aureus*. Prior to FCPF the

patient had been operated a total of 29 times within 25 months (six times for exchange of implant). Bony healing was achieved 11 months after FCPF without revision.

Healing at the donor site was uneventful in all patients. None of the patients complained of pain at the donor site following healing.

DISCUSSION

The patients described here had chronic non-union. Further conventional treatment with non-vascularised bone grafts appeared to have a poor prognosis. There was either local infection or an atrophic, a-reactive non-union. Treatment with FCPF was preferred to other forms of vascularised bone graft as this procedure involves a thin and malleable graft. This means that the graft can be better fitted to the local soft tissues and a space-limiting periosteal tube can be formed. According to Stock *et al* (9), creation of a closed periosteal space is an important criterion for osteogenesis. Close contact can also be achieved between the graft and bone, which increases the osteogenic potential (2). The choice of periosteal donor site also appears to play a part in the amount of osteogenesis. Periosteum from the limbs appears to have more osteogenic potential than that from the skull or ribs (11,10). Harvesting from the medial femur takes this into account, makes it possible to obtain sufficiently large grafts and is associated with low morbidity. The descending genicular vessels are constantly present and are of sufficient size for reliable microsurgical anastomosis (5). The osteogenesis model assumes that groups of active osteoblasts initially produce small islands of bone matrix, which later become confluent to form an ever larger mass (1). However, stable internal fixation is an important requirement for successful FCPF. The osteogenic effect of FCPF does not compensate for insufficient fixation. Doi and Sakai (3) used vascularised periosteal bone grafts in non-union of an upper extremity without massive bone defects and attributed failure of therapy in two of eleven cases to unstable internal fixation. In our patients, stable internal fixation was an essential component of the treatment regime.

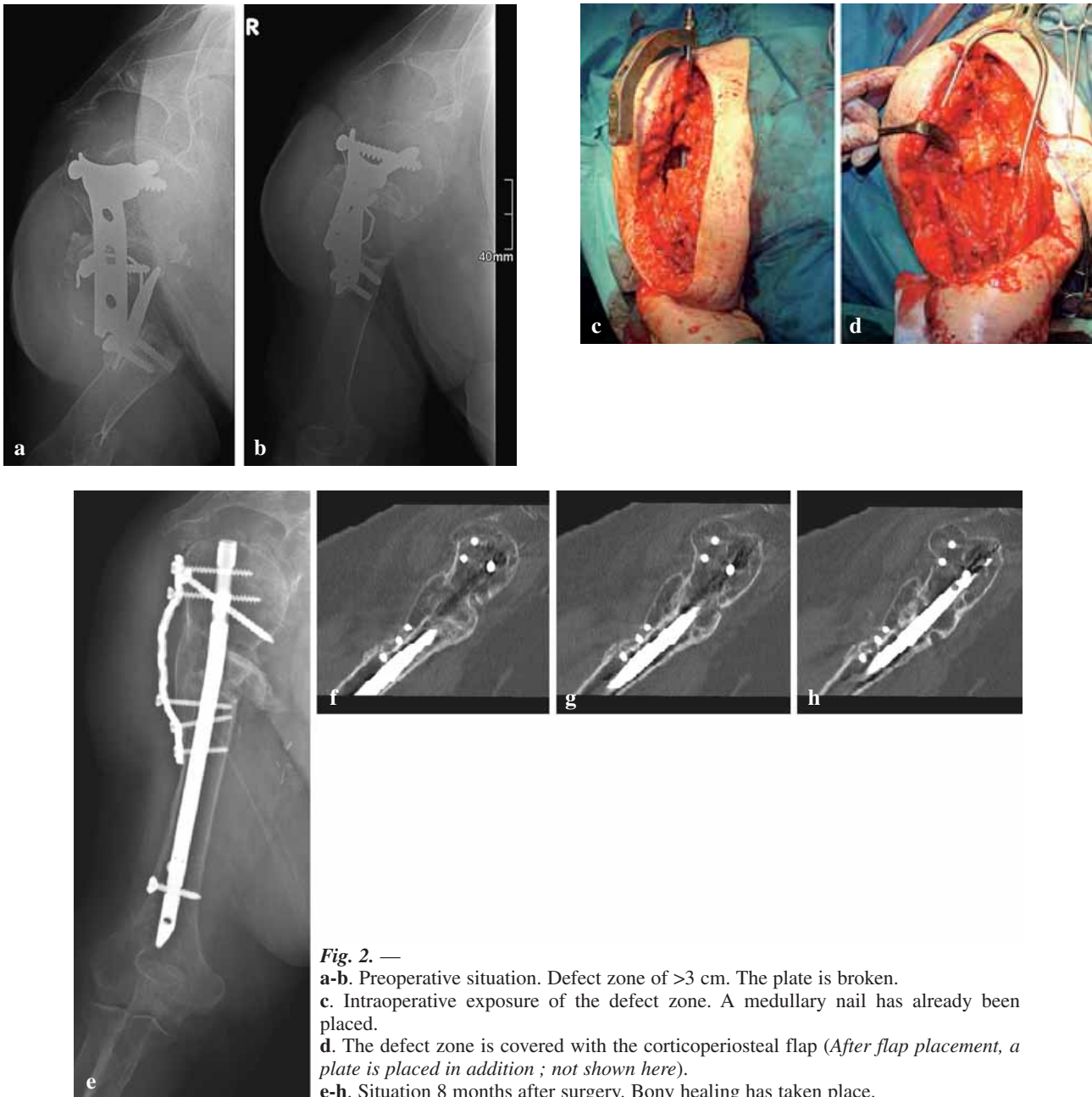


Fig. 2. —

a-b. Preoperative situation. Defect zone of >3 cm. The plate is broken.

c. Intraoperative exposure of the defect zone. A medullary nail has already been placed.

d. The defect zone is covered with the corticoperiosteal flap (After flap placement, a plate is placed in addition ; not shown here).

e-h. Situation 8 months after surgery. Bony healing has taken place.

We did not observe any postoperative complications associated with the treatment in our study. However, the patient population is small, so no general conclusions can be drawn about the paucity of complications. Particularly when used in the lower extremities, preoperative angiography appears imperative. Postoperative circulation monitoring is partially possible as the descending

genicular vessels have a saphenous branch, which allows harvesting of a skin flap. A technical alternative for monitoring is to use a Cook-Swartz venous Doppler system (8). This is an implantable, removable, 20 MHz ultrasonic probe around the venous pedicle and a battery operated portable monitor (8). We have had no experience of this up to now.

Treatment with free vascularised corticoperiosteal bone flaps as presented here is complex but the results are acceptable. The relatively advanced age of the patients and presence of chronic infection do not appear to be contraindications to the procedure. However, studies on larger patient populations are necessary if the method is to become established.

REFERENCES

1. **Burstein FD, Canalis RF.** Studies on the osteogenic potential of vascularized periosteum: behaviour of periosteal flaps transferred onto soft tissues. *Otolaryngology* 1985 ; 93 : 731-735.
2. **Canalis RF, Burstein FD.** Osteogenesis in vascularized periosteum. Interactions with underlying bone. *Arch Otolaryngol* 1985 ; 111 : 511-516.
3. **Doi K, Sakai K.** Vascularized periosteal bone graft from the supracondylar region of the femur. *Microsurgery* 1994 ; 15 : 305-315.
4. **Finley JM, Acland RD, Wood MB.** Revascularised periosteal grafts. A new method to produce functional new bone without bone grafting. *Plast Reconstr Surg* 1978 ; 61 : 1-6.
5. **Fuchs B, Steinmann SP, Bishop AT.** Free vascularized corticoperiosteal bone graft for the treatment of persistent non-union of the clavicle. *J Shoulder Elbow Surg* 2005 ; 14 : 264-268.
6. **Gazdag AR, Lane JM, Glaser D, Forster RA.** Alternatives to autogenous bone graft : efficacy and indications. *J Am Acad Orthop Surg* 1995 ; 3 : 1-8.
7. **Nicoll EA.** The treatment of gaps in long bones by cancellous insert grafts. *J Bone Joint Surg* 1956 ; 38-B : 70-82.
8. **Oliver DW, Whitaker IS, Giele H et al.** The Cook-Swartz venous Doppler probe for the post-operative monitoring of free tissue transfers in the United Kingdom : a preliminary report. *Br J Plast Surg* 2005 ; 58 : 366-370.
9. **Stock W, Hierner R, Dielert E et al.** The iliac crest region : donor site for vascularized bone periosteal and soft tissue flaps. *Ann Plast Surg* 1991 ; 26 : 105-109.
10. **Takato T, Harii K, Nakatsuka T.** Osteogenic capacity of vascularized periosteum : experimental study using rib periosteum in rabbits. *Br J Plast Surg* 1988 ; 41 : 528-532.
11. **Uddströmer L, Ritsila V.** Osteogenic capacities of periosteal grafts. *Scand J Plast Reconstr Surg* 1978 ; 12 : 207-214.
12. **Vögelin E, Jones NF, Huang JI et al.** Healing of a critical-sized defect in the rat femur with use of a vascularized periosteal flap, a biodegradable matrix, and bone morphogenetic protein. *J Bone Joint Surg* 2005 ; 67-A : 1323-1331.
13. **Wildenberg FAJM, Goris RJA, Tutein BJE.** Free revascularised periosteum transplantation : an experimental study. *Br J Plast Surg* 1984 ; 37 : 226-235.