



## Medium-term results of patellofemoral joint arthroplasty

Riazuddin MOHAMMED, Tushar JIMULIA, Kaustubh DURVE, Manish BANSAL, Marcus GREEN, Duncan LEARMONTH

*From the Royal Orthopaedic Hospital, Birmingham, United Kingdom*

The results of a multi-surgeon, multi-implant series of patellofemoral joint arthroplasties performed over a ten year period are presented. All patellofemoral joint arthroplasties performed from 1997 to 2006 were retrospectively reviewed using case notes, radiographs and clinic appointments until their latest follow-up period.

One hundred and one arthroplasties in 91 patients were followed up for an average period of 48 months (range 6-96 months). The average age was 57 years with female patients thrice as common as male patients. There were 5 (5%) complications with 1 deep infection and 4 stiff knees. Thirty five subsequent procedures were performed in 28 patients including arthroscopic debridement in 18, arthroscopic lateral retinacular release in 8, tibial tuberosity transfer in 3, manipulation for stiffness in 2, and revision to total knee arthroplasty in 4 patients (3 for progression of tibiofemoral osteoarthritis and 1 for infection).

The necessity of further surgeries in one third of the study group suggests that close follow-up of these patients is needed to address any concerns that can be easily resolved.

**Keywords :** knee ; patellofemoral arthroplasty.

### INTRODUCTION

Isolated patellofemoral osteoarthritis has long been a common observation as an important source of knee pain. McAlindon *et al* (9) reported isolated symptomatic patellofemoral arthritis in 8% of women and 2% of men over the age of 55 years. In a recent radiographic study, Davies *et al* (3) noted

that the prevalence of isolated patellofemoral arthritis was 9.2% of 206 knees in patients older than forty years.

Various treatment options have been advocated over the years with varying results. Most cases of patellofemoral arthritis can be initially treated with non operative management. This includes activity modification, medications, weight control and physical therapy. For non responsive cases, the surgical options available are transposition/elevation of the tibial tubercle, drilling, realignment procedures, patellectomy, patellar resurfacing, patellofemoral arthroplasty and total knee arthroplasty.

---

■ Riazuddin Mohammed, MS (Orth), MRCS, Junior Orthopaedic Surgeon.

■ Tushar Jimulia, MS (Orth), FRCS (Orth), Locum Orthopaedic Consultant.

■ Kaustubh Durve, MS (Orth), MRCS, Junior Orthopaedic Surgeon.

■ Manish Bansal, MS (Orth), MRCS, Junior Orthopaedic Surgeon.

■ Marcus Green, FRCS (Orth), Consultant Orthopaedic Surgeon.

■ Duncan Learmonth, FRCS (Orth), Consultant Orthopaedic Surgeon.

*Arthroplasty and Reconstruction Unit (Knee and Shoulder), Royal Orthopaedic Hospital, Birmingham, United Kingdom.*

Correspondence: Riazuddin Mohammed, 16 Bayliss Close, Birmingham, B31 2XP, United Kingdom.

E-mail: riaz22@hotmail.co.uk

© 2008, Acta Orthopædica Belgica.

---

Our study aims to analyze the results of patellofemoral joint arthroplasty performed at a single centre over a ten year period and their follow-up for a medium term period. The outcome measure used is based on the necessity for further surgery in the medium term and the incidence of revision to total knee replacement.

### MATERIALS AND METHODS

This study was a retrospective review of all patellofemoral joint arthroplasties performed in the Knee & Shoulder Unit at our hospital over a ten year period from 1997 to 2006. The unit comprises seven specialist surgeons, each with considerable experience in knee arthroplasty and numerous trainee surgeons. One hundred and one patellofemoral joint arthroplasties performed in 91 patients were identified from the theatre records. Three different implant models were used : the Lubinus implant (Waldemar Link, Germany), the FPV system (Wright Medical, UK) and the Avon system (Stryker UK). All these implants were simultaneously used as per the surgeon's choice. All our initial arthroplasties were using the Lubinus implants. However we have abandoned this and have been using the other two implants for the past eight years.

In all cases, the case notes were reviewed and all data collected as per a standard proforma. Preoperative and postoperative weight bearing radiographs were reviewed for signs of loosening, mechanical failure of the implants and progression of tibiofemoral arthritis. All the bilateral arthroplasties were staged procedures, with the interval period ranging from 2-35 months.

### RESULTS

One hundred and one patellofemoral arthroplasties were performed in 91 patients in our centre. The average age was 57 years with female patients thrice as common as male patients. Clinical and radiological evidence of isolated patellofemoral joint arthritis were the indication in all patients. Up to 86% of patients had symptoms and signs of pain specific to the patellofemoral joint. These include anterior knee pain, difficulty in maneuvering stairs, and difficulty in getting up from a seated position, positive patellar crepitus, positive patellar grind test and positive Zohlen's sign. Seven patients also had

symptoms and signs of patellar subluxations and maltracking.

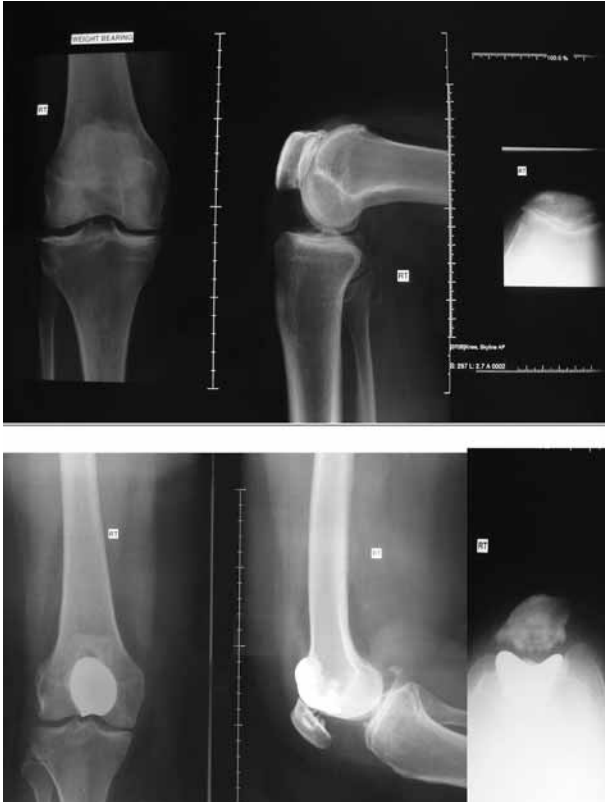Standard weight bearing radiographs were taken in antero-posterior, lateral and skyline views in all cases. These showed evidence of severe (grade 3-4) patellofemoral joint arthritis in 66% patients. Radiographs of 40 patients also showed grade 1-2 tibiofemoral arthritis. These were evidenced by mild narrowing of the joint space, some squaring of the femoral condyles or marginal osteophytes. However none of these patients had any significant tibiofemoral pain.

Previous surgeries were performed in all but 19 knees. The majority of them (58 knees) had arthroscopic assessment and debridement, including chondroplasty in 15 knees. Patellar realignment procedures in the form of 23 lateral retinacular release and 3 tibial tuberosity transfers were performed. Eighteen of the knees had intra-articular steroid injections for pain relief in the past.

A standard medial parapatellar approach was adopted in all cases. The intra-articular joint condition of both tibiofemoral and patellofemoral joints was assessed. Ligament stability and patellar tracking were also looked for. Intraoperative findings confirmed grade 1-2 patellar osteoarthritis in 18% and grade 3-4 in 82% of the knees. Grade 1-2 osteoarthritic changes in the trochlea in 36%, grade 3-4 in 58% and normal looking trochlea in 6% knees were also noted. In the tibiofemoral joint, 70% were normal looking joint surfaces, 25% had mild changes of osteoarthritis and 5% had moderate osteoarthritis.

Three different implant models were used. A total of 46 knees had the Lubinus implant (Waldemar Link, Germany), 30 knees had the FPV system (Wright Medical, UK) and 25 knees had the Avon system (Stryker UK), based solely on surgeon's preference. The average tourniquet time was 67 minutes (fig 1).

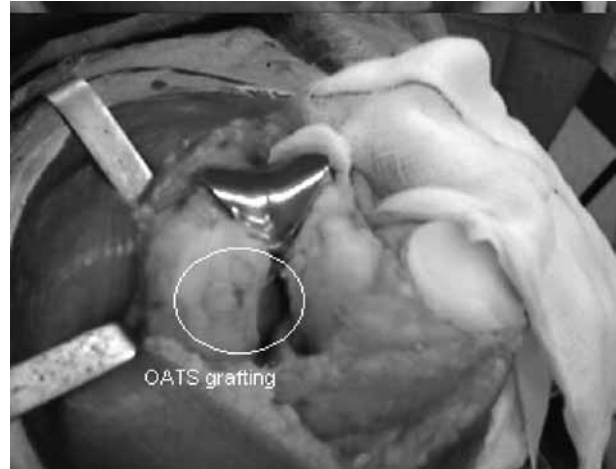Seventy three percent of the knees did not warrant any additional procedure. However concomitant lateral retinacular release was necessary in 23 knees to aid better patellofemoral tracking. In 6 knees isolated well defined full thickness cartilage defects were noted on the weight bearing surfaces of the femoral condyles. These knees had a



**Fig. 1.** — Pre-operative and four year post-operative radiographs for an isolated symptomatic patellofemoral arthritic joint.

simultaneous osteochondral autograft transfer system (OATS) procedure along with the patellofemoral joint replacement (fig 2).

Postoperative inpatient stay was 7 days on an average. However with the introduction of our community based nursing scheme since the last few years, the current average inpatient stay is only 3 days postoperatively. Patients were seen at 6 weeks, 6 months, one year postoperatively in the outpatient department and then annually. The average duration of follow-up in our series was 48 months (range 6-96 months). No patients had been lost to follow-up. During these visits, further symptoms were elicited and a clinico-radiological assessment was carefully performed. There was no mechanical failure or loosening of any of the implants radiologically.



**Fig. 2.** — Patellofemoral replacement with concomitant OATS grafting.

Most patients regained a very good range of knee movements following the arthroplasty. Twenty five percent of patients lost the last ten degrees of flexion of the knee and 5% of patients lost five degrees of terminal extension. Four stiff knees were among the complications noted. Of these 2 underwent manipulation under anaesthesia. 2 patients did not agree to undergo the same and chose to accept their knee stiffness.

In total, 26 knees underwent arthroscopic assessment for ongoing pain or instability following the patellofemoral joint replacement and 8 of these required a lateral retinacular release. Three of these patients had recurrent patellofemoral maltracking problems and needed a tibial tuberosity transfer. Three patients had pain from progression of tibiofemoral arthritis and this was severe enough to need one stage revision arthroplasty to a total knee replacement. The average time between the primary and this revision was 39 months. There was one staphylococcal infection of the prosthetic knee two years after the procedure. This patient underwent a two staged revision arthroplasty to a total knee replacement, and is satisfied with the outcome.

Based on the subsequent procedures that were felt necessary for symptomatic patients with patellofemoral arthroplasty, 73 patients (72%) did very well, not needing any further intervention.

This does not include the two patients with stiff knees who have accepted the minor disability. Twenty eight patients needed 35 operative interventions in all, which included arthroscopic debridement (18), arthroscopic lateral retinacular release (8), tibial tuberosity transfer (3), manipulation for stiffness (2) and revision to total knee arthroplasty (4).

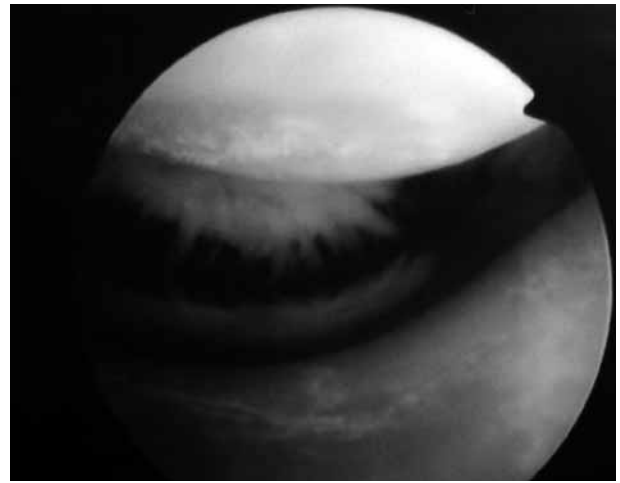
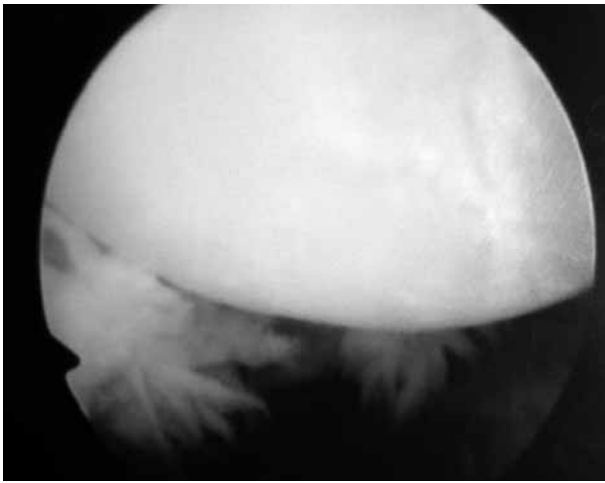
## DISCUSSION

Isolated symptomatic patellofemoral arthritis needs to be clinically and radiologically identified accurately. The management plan would differ if there is any element of symptomatic tibiofemoral arthritis involved. Eighty six percent of our patients in the study had symptoms specific to the patellofemoral joint and none had any tibiofemoral symptoms or signs. Lonner has suggested that radiological evidence of mild tibiofemoral arthritis can be accepted provided no tibiofemoral pain exists on functional activities or physical examination, and the chondral degeneration observed at previous arthroscopy or at the time of arthrotomy is minimal (6).

In six knees, tibiofemoral osteoarthritis was noted to be of moderate to severe grade and it was debatable whether to proceed with a total knee replacement. Since the lesions were all well demarcated and on the weight bearing femoral condyles, a combination of the arthroplasty with an osteochondral autograft transfer system (OATS) was performed. The average age of the patients in this group was 48 years (36 to 59 years) at the time of the procedure. This combination offers an alternative to more invasive options such as total knee replacement in younger patients in whom it is preferable to delay such a major surgery. A recent study by Lonner *et al* (8) have shown good results from this combination procedure.

Eighty percent of our patients had undergone some previous procedures. Of these, 32% of them had realignment procedures for maltracking of the patella. It is our belief that excessive patellar maltracking and large Q-angle need to be corrected to avoid poor results. Eight patients had subsequently a maltracking patella and underwent arthroscopic

lateral release. Three of them did not improve and for them a tibial tuberosity transfer was performed. All these 8 patients had the Lubinus implant. There is evidence in literature to show that some trochlear designs such as the Lubinus implant have a particularly high incidence of pain, snapping and instability (11,12) compared to other implant models such as the Avon implant (1). Our experience has evolved over the years in the choice of these implants. All our initial arthroplasties were done using the Lubinus implant, an unconstrained anatomical implant with a short and narrow trochlear component. The patellar button articulates with the anterior femoral surface in full extension before it engages in the trochlear component. The sagittal radius of curvature of the trochlear prosthesis is obtuse. Implanting the prosthesis either flush with the femoral trochlea or in slight flexion would result in offsetting the distal or the proximal end of the trochlear component (6). All these factors could explain the high risk of impingement or patellar clunking and maltracking associated with the Lubinus implant. The Avon implant has a broad symmetrical trochlear flange, which allows relatively unconstrained movement of the patella in extension (1). The trochlear groove narrows around the arc of flexion so that the patella engages in the groove and becomes more stable as the knee flexes. The patellar component has a medially offset dome of 3 mm to facilitate better tracking. The FPV implant has similar features to the Avon prosthesis in terms of a broad flange trochlear component with a proportionate proximal extension and side determined components. However the trochlear component sulcus angle is approximately 140 degrees compared to 125 degrees for the Avon prosthesis and 110 degrees for the Lubinus implant. This closely approximates the average radiographic sulcus angle of 138 degrees (standard deviation 6 degrees). This improves the patellar tracking and minimizes patellar instability. Of the three implants, we found the FPV implant instrumentation to be the most operator friendly and the least prone to errors in implant alignment. We have been using the FPV implant and the Avon implant for patellofemoral arthroplasties more often in the past few years and have abandoned the Lubinus implant.



**Fig. 3.** — Arthroscopic image showing scar tissue at the superior aspect of the patellar button. This patient had pain and ‘clicking’ sensation in the knee following patellofemoral replacement. The fibrous scar tissue was successfully debrided arthroscopically.

Based on subsequent surgical procedures for symptomatic patellofemoral arthroplasties, the FPV prosthesis has shown the best outcome in our series. Out of the 30 FPV knees, only two (6%) needed arthroscopic debridement in the short follow-up period. Of the 25 knees with the Avon prosthesis, six subsequent procedures were necessary in six (24%) knees. These include arthroscopic debridement in four, arthroscopic lateral retinacular release in one and manipulation under anaesthesia for one stiff knee. Twenty (43%) of the 46 Lubinus knees required subsequent procedures like arthroscopic debridement (12), arthroscopic lateral retinacular release (7), tibial tuberosity transfer (3), manipulation for stiffness (1) and revision to total knee arthroplasty (4).

In our series, 28 patients underwent subsequent procedures, including two manipulations for stiff knees. In a study involving 85 patients, Blazina *et al* (2) have shown that 35% of their patients underwent at least one subsequent procedure at a mean follow-up of 21 months. Kooijman *et al* (4) have reported that 25% of their patients required secondary surgery for progressive tibiofemoral arthritis at a mean of 15.6 years. In our study 26 knees underwent arthroscopic assessment for their symptomatic patellofemoral replacements (fig 3). In 23 patients (88%), arthroscopy was a useful diagnostic tool and

in 14 patients (54%), arthroscopy proved to be successful therapeutically. This suggests that though patellofemoral replacements give rise to problems subsequently, these can be easily addressed. We therefore, believe that arthroscopy has a role as the first line of management for symptomatic patellofemoral arthroplasty.

Four patellofemoral replacements were revised to total knee replacements. Three patients developed symptomatic tibiofemoral disease that failed to improve from simpler measures like arthroscopic debridement. Of these, one knee had a simultaneous OATS graft performed for full thickness wear on the medial femoral condyle. Subsequently the patient underwent arthroscopic washout and a partial medial meniscectomy which did not relieve her symptoms and at four years following the primary replacement, a total knee replacement was performed. The other two knees did not have any symptoms or signs of tibio-femoral arthritis at presentation and these articular surfaces were found to be normal looking at the time of the arthroplasty. The mean duration between the two procedures was 39 months and the mean age was 63 years. All the knees had a Lubinus patellofemoral prosthesis. This shows the importance of patient assessment and ideal patient selection when patellofemoral replacement is considered.



The major failure mechanism reported from patellofemoral arthroplasty is progression of tibiofemoral arthritis. Kooijman *et al* (4) have reported 86% good or excellent results at mean follow-up of 17 years. A significant issue was progression of the disease, necessitating conversion to a total knee arthroplasty. They conclude that a patellofemoral joint arthroplasty should be compared with operations such as high tibial osteotomy, in which a successful outcome at ten years is considered a good result. Because of long term failure from progression of tibiofemoral arthritis, patellofemoral arthroplasty may be considered an intermediate procedure for selected patients with patellofemoral arthritis (5). The results of revision to total knee replacement reported in the literature are good. Lonner *et al* (7) and Sisto *et al* (10) have shown that the functional outcome from a revision of a failed patellofemoral replacement to a total knee replacement is not compromised.

Our study has a drawback in terms of lack of an objective outcome score, and it is a retrospective study. However this study is one of the largest series of patellofemoral replacements reported, and all were performed at one centre by multiple surgeons using different implants. With the necessity of further surgery as the outcome measure, 72% of our patients are doing well, having not needed any form of further intervention.

*Acknowledgements*

The authors wish to thank Messers T. Ashraf, K. Baloch, G. Chana, S. Massoud, and J. Plewes for kindly agreeing to let us include their patients in the study.

**CONCLUSION**

The necessity of further surgeries in 28% of the study group suggests that problems following patellofemoral arthroplasty are quite common. Close follow-up of these patients is needed to address any concerns that arise. Arthroscopy can be

a useful tool in both the diagnosis and management of symptomatic patellofemoral joint arthroplasty. Our study reiterates the importance of regular follow-up of these patients in obtaining satisfactory medium term results from patellofemoral joint arthroplasty.

**REFERENCES**

1. Ackroyd CE, Newman JH, Evans R, Eldridge JD, Joslin CC. The Avon patellofemoral arthroplasty : five-year survivorship and functional results. *J Bone Joint Surg* 2007 ; 89-B : 310-315.
2. Blazina ME, Fox JM, Del Pizzo W, Broukhim B, Ivey FM. Patellofemoral replacement. 1979. *Clin Orthop* 2005 ; 436 : 3-6.
3. Davies AP, Vince AS, Shepstone L, Donell ST, Glasgow MM. The radiologic prevalence of patellofemoral osteoarthritis. *Clin Orthop* 2002 ; 402 : 206-212.
4. Kooijman HJ, Driessen APPM, van Horn JR. Long-term results of patellofemoral arthroplasty – A report of 56 arthroplasties with 17 years of follow-up. *J Bone Joint Surg* 2003 ; 85-B : 836-840.
5. Lonner JH. Patellofemoral arthroplasty. *J Am Acad Orthop Surg* 2007 ; 15 : 495-506.
6. Lonner JH. Patellofemoral arthroplasty : pros, cons, and design considerations. *Clin Orthop* 2004 ; 428 : 158-165.
7. Lonner JH, Jasko JG, Booth RE Jr. Revision of a failed patellofemoral arthroplasty to a total knee arthroplasty. *J Bone Joint Surg* 2006 ; 88-A : 2337-2242.
8. Lonner JH, Mehta S, Booth RE Jr. Ipsilateral patellofemoral arthroplasty and autogenous osteochondral femoral condylar transplantation. *J Arthroplasty* 2007 ; 22 : 1130-1136.
9. McAlindon TE, Snow S, Cooper C, Dieppe PA. Radiographic pattern of osteoarthritis of the knee joint in the community- The importance of the patellofemoral joint. *Ann Rheum Dis* 1992 ; 51 : 844-849.
10. Sisto DJ, Cook DL. Total knee replacement in patients with a failed patellofemoral replacement. *Orthop Trans* 1997 ; 21 : 115.
11. Smith AM, Peckett WR, Butler-Manuel PA, Venu KM, d'Arcy JC. Treatment of patello-femoral arthritis using the Lubinus patello-femoral arthroplasty : a retrospective review. *Knee* 2002 ; 9 : 27-30.
12. Tauro B, Ackroyd CE, Newman JH, Shah NA. The Lubinus patellofemoral arthroplasty. A five- to ten-year prospective study. *J Bone Joint Surg* 2001 ; 83-B : 696-701.