



## Discharging pin sites following K-wire fixation of distal radial fractures : A case for pin removal ?

Aravind DESAI, Asterios DRAMIS, Neville THOMPSON, Tim BOARD, Awani CHOUDHARY

*From Bassetlaw District General Hospital, Worksop, United Kingdom*

The aim of this study was to find out whether discharging pin sites following Kirschner-wire fixation of distal radial fractures warrant early wire removal. In a prospective study of 50 patients with a closed distal radial fracture treated by manipulation and either percutaneous or mini-incision Kirschner-wiring, we identified 14 patients (28%) with discharging pin sites. All of the cases were observed within the first two weeks following surgery. Of the 14 cases, only 2 patients had a positive swab culture and were treated with systemic antibiotics. In all cases the Kirschner wires were left *in situ* until serial radiographs demonstrated satisfactory union. Three patients (8.6%) in the percutaneous group had superficial radial nerve irritation, which settled following wire removal. Deep soft tissue infection, pyoarthrosis, osteomyelitis, and extensor tendon rupture were not encountered. We conclude that pin site discharge, whether sterile or infected, is in general not an indication for early wire removal.

**Key words :** Kirschner wire ; distal radial fracture ; pin tract ; infection.

### INTRODUCTION

Fractures of the distal radius are common (23) and contribute to a substantial proportion of the workload in orthopaedic trauma practice (1). Furthermore, the authors of a prospective, multicenter epidemiological study in the United Kingdom estimated the incidence of distal radial fractures to

be 36.8/10,000 person-years in women and 9.0/10,000 person years in men over the age of thirty-five (19).

There appears to be a bimodal distribution of distal radial fractures consisting of a younger group who sustains relatively high-energy trauma to the upper extremity such as traffic accident and an elderly group, especially females, who sustains both high-energy injuries and insufficiency fractures. This reflects the greater fragility of the bone, resulting from disuse or postmenopausal osteoporosis. It has been estimated that, at 50 years of age, a white woman in the USA or Northern Europe has a 15%

---

■ Aravind Desai, MBBS, MS, M.R.C.S. MSc, Clinical Research Fellow in Trauma & Orthopaedics.

■ Asterios Dramis, BM, MSc, MRCS, Clinical Research Fellow in Trauma & Orthopaedics.

■ Neville Thompson, MB, MPhil, FRCS (Tr&Orth), Upper Limb Fellow.

■ Tim Board, MSc, FRCS (Tr&Orth), Consultant Orthopaedic surgeon.

*Department of Trauma and Orthopaedics, Wrightington Hospital, Hall Lane Appley Bridge, Wigan, United Kingdom.*

■ Awani Choudhary, FRCS, Associate Specialist in Orthopaedics.

*Department of Trauma and Orthopaedics, Bassetlaw District General Hospital, Worksop, United Kingdom.*

Correspondence : Mr Aravind Desai, Wrightington Hospital, Hall Lane Appley Bridge, Wigan WN6 9EP, United Kingdom.

E-mail : [desaiaravind@yahoo.co.uk](mailto:desaiaravind@yahoo.co.uk)

© 2009, Acta Orthopædica Belgica.

lifetime risk of a distal radius fracture whereas a man has a lifetime risk of just over two per cent (6). More recent estimates of the lifetime risks of radius or ulna fracture at 50 years of age are similar : 16.6% for women versus 2.9% for men (26).

Treatment options include cast immobilisation, manipulation plus Kirschner-wire fixation, open reduction and internal fixation or external fixation either alone or in combination.

The use of Kirschner-wire fixation to stabilise fracture reduction is a frequently used technique (17). This is less invasive and, usually, technically simpler than open surgery, where the fractured bone is exposed to direct view. For percutaneous pinning, the reduction of the fracture is closed (9), although pins – such as Kirschner wires – may be used to manipulate the fracture fragments. At the end of the procedure the wires may be cut and buried beneath the soft tissues or left protruding through the skin to facilitate removal in the outpatient department. Complications related to Kirschner-wire fixation are however well documented. These include pin tract infection, osteomyelitis, nerve injury, pin migration and tendon rupture (4,11,25).

Pin tract infection is a common complication and usually manifests clinically as pin site discharge, tenderness and localised erythema (5,12,25). The incidence of infection increases with the length of time for which the Kirschner wire is *in situ* (4). Treatment often involves systemic antibiotic therapy and removal of the pin (11), which at an early stage in fracture healing may result in a loss of fracture reduction.

The aims of this prospective study were to determine the rate of pin tract infection and whether the presence of pin site discharge is an indication for early wire removal in patients undergoing Kirschner-wire fixation for a fracture of the distal radius.

## PATIENTS AND METHODS

We prospectively followed fifty closed distal radial fractures (48 patients) treated by manipulation and either percutaneous (35 fractures) or mini-incision Kirschner-wire fixation (15 cases) under fluoroscopy control during

a period from January to July 2005. The decision to perform either percutaneous wiring or a mini-incision technique was determined by the surgeon's preference. The wires were left protruding in both the techniques. The mean age was 44 years (range : 10 to 86 years). The male : female ratio was 1.2:1. Of the 50 distal radial fractures, 43 (86%) were extra-articular and 7 (14%) intra-articular. All cases were treated within 72 hours of injury with 30 (60%) patients having surgery on the day of injury. None of the patients received intraoperative prophylactic antibiotics and all procedures were performed in a laminar flow operating theatre. Patients with concomitant diseases like diabetes mellitus, immunosuppressive conditions and on oral corticosteroids for any illness were not included in the study.

Following satisfactory fracture reduction, a minimum of two Kirschner-wires (diameter : 1.6 mm) were inserted (45 cases, two wires ; 5 cases, three wires) under fluoroscopy control. The wires were then bent, cut and left protruding from the skin. Percutaneous wiring was done in 12 cases and a mini-incision technique was used in the other two cases. For those patients where the wires were inserted using a percutaneous technique, care was taken to ensure that there was no tension of the surrounding skin by performing a simple release. In the group treated using the mini-open technique, the skin was loosely closed around the wire using interrupted 4.0 ethilon sutures. A simple non-adherent dressing was placed around the base of the pin site and a below – elbow back slab applied with the wrist in a neutral position. All of the patients were discharged within 24 hours of surgery with a planned review at one week for pin site inspection and plain radiographs.

At review, any discharging pin sites were swabbed and the specimens sent for microbial culture. None of the cases were commenced on antibiotic therapy unless a positive swab culture was obtained with evidence of significant bacterial growth. Systemic antibiotics were commenced based on the organism cultured and the antibiotic sensitivities. Antibiotic therapy was continued until the infection settled clinically and a negative swab culture obtained. Patients were subsequently reviewed at 2, 4 and 6 weeks. The decision to remove the Kirschner-wires and the total period of immobilisation was based on the appearance of serial post-operative radiographs. In this study, the K-wires were removed in the outpatient clinic usually between 4-6 weeks.

## RESULTS

Serous discharge and localised erythema around one or all of the pin sites, was observed in 14 cases

(28%). All were observed within the first two-week period. Of these 14 cases, 8 patients were between 70-86 years of age, 4 were between 40-50 years of age and one each in age groups between 20 to 30 and 30 to 40 years of age. Twelve cases had a negative swab and therefore did not receive any antibiotic therapy. In all these cases, 2 Kirschner wires were used. Further management consisted of regular pin site dressings every 2 weeks, and in all of these patients the discharge settled without any additional intervention. None of the patients had early Kirschner-wire removal.

In 2 cases (4%) a significant growth of *Staphylococcus Aureus* was noted. Both the patients were between 30-40 years of age and had undergone percutaneous pinning; 3 Kirschner wires had been used in one of them. One of the patients had associated cellulitis and was admitted for intravenous antibiotic therapy. The other patient was treated with oral antibiotics. Treatment was continued until a negative swab culture was obtained. In both patients the Kirschner-wires were left *in situ* until the end of the fourth week. At six-month review, neither patient had clinical or radiological evidence of deep sepsis. All of the fractures proceeded to satisfactory union.

Three patients (9%) in the percutaneous group developed paraesthesia in the distribution of the superficial radial nerve, which settled following wire removal. This complication was not observed in the mini-incision group. Deep soft tissue infection, pyoarthrosis, osteomyelitis, and extensor tendon rupture were not encountered.

## DISCUSSION

Manipulation and Kirschner-wire fixation is one of the most commonly used methods for treating displaced, unstable fractures of the distal radius. Percutaneous pinning has been recommended as a simple way of providing additional stability to immobilisation in a cast in unstable extra-articular fractures of the distal radius in which anatomical reduction is obtainable (5,14,15,21,22,24). Complications are usually minor and, to some extent, avoidable (10). A variety of different pinning techniques or methods have been described in the litera-

ture (7,21). The advantages of percutaneous pinning are as follows: K-wires are readily available in most hospitals of the world, it is a low cost technique, it augments the stability of the reduction (or at least it should) and it allows, when used as joystick, exact reconstruction of the joint surface and metaphyseal area. The disadvantages are as follows: the need for an additional immobilisation (plaster of Paris or external fixation), the risk of injuring neurovascular structures or tendons, the risk of hardware migration, the risk of secondary displacement in osteoporotic elderly patients and after pin removal, and the risk of pin-tract infection (18).

However, despite meticulous aseptic technique the risk of pin tract infection cannot be completely eliminated and remains a common complication following this method of fixation. Several authors have shown that burying the wire deep to the skin at the end of the procedure significantly reduces the infection rate (11,20) but necessitates readmission for wire removal with considerable economic implications.

Pin tract infection is usually treated by systemic antibiotic therapy and removal of the wire. Early wire removal may however result in a loss of fracture reduction increasing the risk of malunion and functional impairment (16).

In our series we did not use any prophylactic antibiotics. There is no study till date available in the literature showing that perioperative antibiotics reduce the risk of postoperative pin track infection in the percutaneous fixation of distal radius fractures. In a prospective trial, 50 patients with an unstable distal radius fracture were randomised for treatment with closed reduction followed by either a standard small 4-pin fixator of the Association for the Study of Internal Fixation (25 patients) or a 5-pin external fixator (25 patients). In this trial, 6 of the 50 patients had drainage from the proximal sites during treatment. No intraoperative intravenous antibiotics were used. Cultures were positive for only one patient. This patient, who had a *Staphylococcus aureus* infection, was treated with oral antibiotics and the fixator was removed at nine weeks as per trial protocol. In the five remaining patients the drainage ceased following secondary tensioning of the fixator frame (27).

In another prospective study, 25 patients with fractures of the distal radius were treated with non-bridging external fixation for six weeks. None of the patients received prophylactic antibiotics. There were two major pin tract infections with loosening which eventually required removal five weeks after surgery with no adverse effect on fracture healing. One further superficial pin tract infection healed within one week by local pin care without administration of antibiotics (8).

There is no published data available which documents the proportion of patients with percutaneous Kirschner wires who develop serous discharge and localised erythema around the pin sites. All available studies simply quantify the number of pin tract infections. In another prospective randomised study of 60 patients (average age 55 years) treated by closed reduction and trans-styloid Kirschner wire fixation which compared two groups of 1-week and 6-week post operative immobilisation, pin tract infection occurred in only one patient (1.6%). The pin tract infection subsided after the planned removal of the wires with local treatment and no antibiotic therapy (2).

Finally, in another randomised controlled trial of 179 patients (mean age 40 years) comparing indirect percutaneous reduction and external fixation with open reduction and internal fixation, there were 5 (6%) superficial pin tract infection cases in the indirect reduction group. Two of these patients developed pin tract infections which were deep enough to require operative intervention and debridement (13).

None of these studies documented administration of any prophylactic antibiotics or adherence to any protocol of pin site management. Our pin tract infection rate is similar to that reported in the literature. As there is no data available in the medical literature about pin tract discharge rate, it is difficult to compare our results. In our study, 14 cases (28%) displayed features suggestive of pin tract infection i.e. serous discharge and localised erythema, however only two cases (4%) had a positive swab culture (*S. Aureus*) requiring systemic antibiotics. This could be well explained by the fact that most likely the discharge is a liquefying haematoma that is

draining rather than infection *per se*. A positive swab culture is not always diagnostic of infection especially in the absence of other clinical signs. In all 14 cases, the Kirschner-wires remained *in situ* and were removed only when union was deemed satisfactory from serial radiographs. To date, we have not experienced any cases of deep sepsis resulting from leaving the wires *in situ* although we acknowledge the relatively short duration of follow-up.

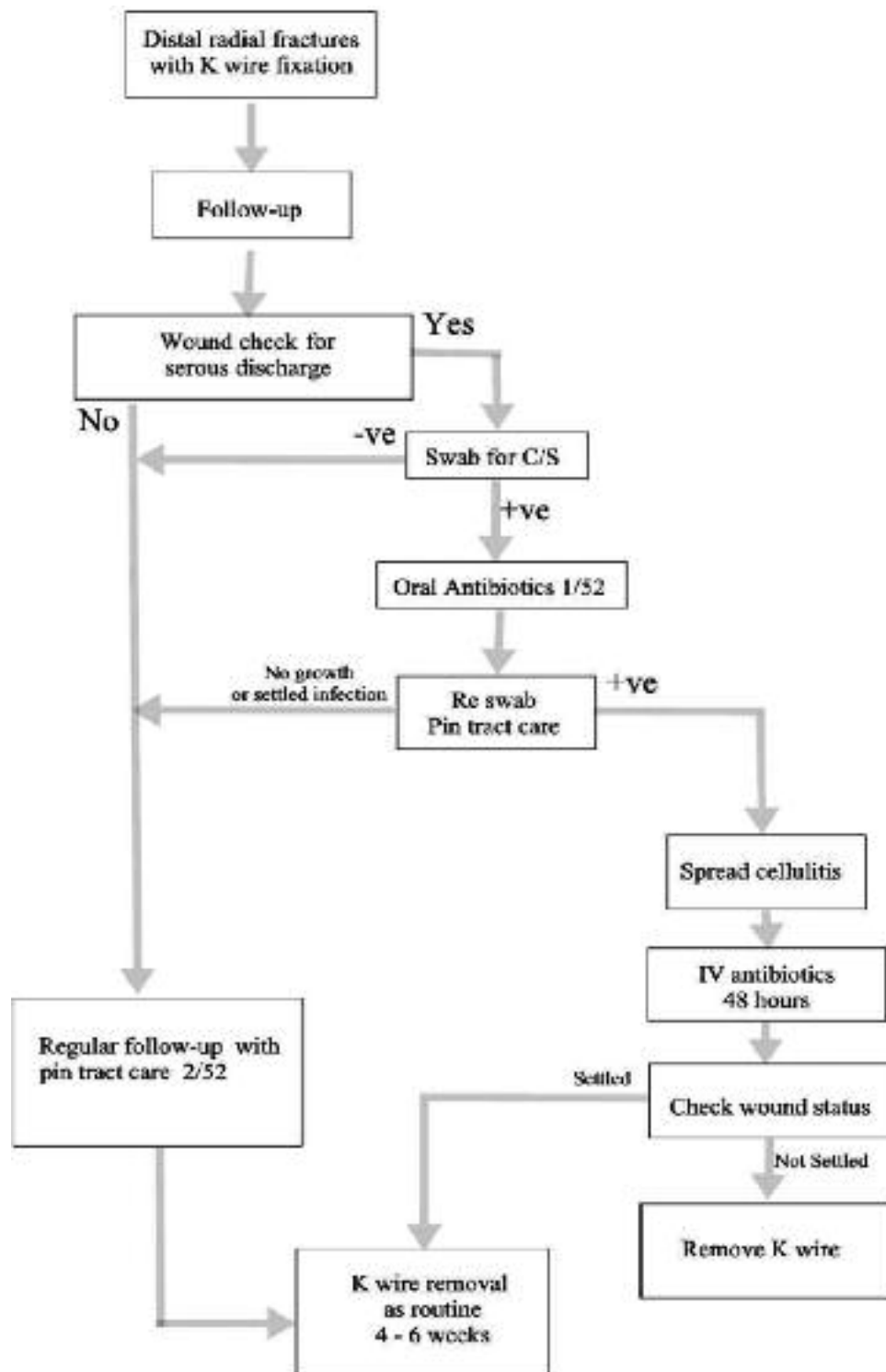
Hence we believe and emphasise that patients should be considered for K-wire removal when clinical signs of infection are present such as spreading cellulitis or signs of deep infection not settling after 48 hours of intravenous antibiotics, rather than based purely on microbiological evidence of infection.

We also recommend the pin tract care following K-wire fixation for distal radial fractures as shown in our flow chart (fig 1).

The limitations of our study were that the sample size might have influenced our results and a larger study group would have given more definite answers to the questions raised. We do not think that a longer follow-up of 6 months was necessary in our study, as any cases of deep sepsis would have declared themselves within the time period used in this study.

## CONCLUSION

Localised erythema and serous discharge surrounding pin sites is commonly observed in the early period following Kirschner-wire fixation of distal radius fractures, however the majority of cases display a negative swab culture, and settle with regular and frequent pin tract care and dressing and do not require antibiotic cover. From this study we have demonstrated that in such cases, the Kirschner-wires may be left *in situ* even when there is evidence of a positive swab culture, unless there is evidence of spreading infection not settling with intravenous systemic antibiotics. We emphasise the importance of regular pin site care following Kirschner wire fixation.



*Fig. 1.* — Flow chart for managing pin tract discharge following Kirshner-wire fixation of distal radial fractures

## REFERENCES

1. **Abbaszadegan H, Conradi P, Jonsson U.** Fixation not needed for undisplaced Colles' fracture. *Acta Orthop Scand* 1989 ; 60 : 60-62.
2. **Allain J, le Guilloux P, Le Mouël S et al.** Trans-styloid fixation of fractures of the distal radius. A prospective randomized comparison between 6- and 1-week postoperative immobilization in 60 fractures. *Acta Orthop Scand* 1999 ; 70 : 119-123.
3. **Azzopardi T, Ehrendorfer S, Coulton T et al.** Unstable extra-articular fractures of the distal radius : a prospective, randomised study of immobilisation in a cast versus supplementary percutaneous pinning. *J Bone Joint Surg* 2005 ; 87-B : 837-840.
4. **Botte MJ, Davis JLW, Rose BA et al.** Complications of smooth pin fixation of fractures and dislocations in the hand and wrist. *Clin Orthop* 1992 ; 276 : 194-201.
5. **Clancey GJ.** Percutaneous Kirschner-wire fixation of Colles fractures. A prospective study of thirty cases. *J Bone Joint Surg* 1984 ; 66-A : 1008-1114.
6. **Cummings SR, Kelsey JL, Nevitt MC et al.** Epidemiology of osteoporosis and osteoporotic fractures. *Epidemiol Rev* 1985 ; 7 : 178-208.
7. **Fernandez DL, Palmer AK.** Fractures of the distal radius. In : Green DP, Hotchkiss RN, Pederson WC (eds). *Green's Operative Hand Surgery*. 4th ed, New York, Churchill Livingstone, 1999, pp 929-985.
8. **Grabl G, Jupiter JB, Gierer P et al.** Fractures of the distal radius treated with a nonbridging external fixation technique using multiplanar k-wires. *J Hand Surg* 2005 ; 30-A : 960-968.
9. **Handoll HH, Madhok R.** Closed reduction methods for treating distal radial fractures in adults. *Cochrane Database Syst Rev* 2003 ; 1 : CD003763.
10. **Handoll HH, Vaghela MV, Madhok R.** Percutaneous pinning for treating distal radial fractures in adults. *Cochrane Database Syst Rev* 2007 ; 3 : CD006080.
11. **Hargreaves DG, Drew SJ, Eckersley R.** Kirschner wire pin tract infection rates : A randomised controlled trial between percutaneous and buried wires. *J Hand Surg* 2004 ; 29-B : 374-376.
12. **Kapandji IA, Epinette JA.** Colles' fracture : treatment by double intrafocal wire fixation. In : Razemon JP, Fisk GR (eds). *The Wrist*. Churchill Livingstone, Edinburgh, 1988, pp 65-73.
13. **Kreder HJ, Hanel DP, Agel J et al.** Indirect reduction and percutaneous fixation versus open reduction and internal fixation for displaced intra-articular fractures of the distal radius : a randomised, controlled trial. *J Bone Joint Surg* 2005 ; 87-B : 829- 836.
14. **Lenoble E, Dumontier C, Goutallier D et al.** Fracture of the distal radius. A prospective comparison between trans-styloid and Kapandji fixations. *J Bone Joint Surg* 1995 ; 77-B : 562-567.
15. **Mah ET, Atkinson RN.** Percutaneous Kirschner wire stabilisation following closed reduction of Colles' fractures. *J Hand Surg* 1992 ; 17-B : 55-62.
16. **McQueen M, Caspers J.** Colles fracture : does the anatomical result affect final function ? *J Bone Joint Surg* 1988 ; 70-B : 649-651.
17. **Munson G, Gainor B.** Percutaneous pinning of distal radial fractures. *J Trauma* 1981 ; 21 : 1032-1036.
18. **Nijs S, Broos PL.** Fractures of the distal radius : a contemporary approach. *Acta Chir Belg* 2004 ; 104 : 401-412.
19. **O'Neill TW, Cooper C, Finn JD et al.** UK Colles' Fracture Study Group. Incidence of distal forearm fracture in British men and women. *Osteoporos Int* 2001 ; 12 : 555-558.
20. **Rafique A, Ghani S, Sadiq M et al.** Kirshner wire pin tract infection rates between percutaneous and buried wires in treating metacarpal and phalangeal fractures. *J Coll Physicians Surg Pak* 2006 ; 16 : 518-520.
21. **Rayhack JM.** The history and evolution of percutaneous pinning of displaced distal radius fractures. *Orthop Clin North Am* 1993 ; 24 : 287-300.
22. **Ring D, Jupiter JB.** Percutaneous and limited open fixation of fractures of the distal radius. *Clin Orthop* 2000 ; 375 : 105-115.
23. **Robertsson GO, Jonsson GT, Sigurjonsson K.** Epidemiology of distal radius fractures in Iceland in 1985. *Acta Orthop Scand* 1990 ; 61 : 457-459.
24. **Simic PM, Weiland AJ.** Fractures of the distal aspect of the radius : changes in treatment over the past two decades. *Instr Course Lect* 2003 ; 52 : 185-195.
25. **Stahl S, Schwartz O.** Complications of K-wire fixation of fractures in the hand and wrist. *Arch Orthop Trauma Surg* 2001 ; 121 : 527-530.
26. **Van Staa TP, Dennison EM, Leufkens HG, Cooper C.** Epidemiology of fractures in England and Wales. *Bone* 2001 ; 29 : 517-522.
27. **Werber KD, Raeder F, Brauer RB et al.** External fixation of distal radial fractures : four compared with five pins : a randomized prospective study. *J Bone Joint Surg* 2003 ; 85-A : 660-666.