



## Quality of life in patients following percutaneous PMMA acetabuloplasty for acetabular metastasis due to carcinoma

Laura SCARAMUZZO, Giulio MACCAURO, Barbara ROSSI, Laura MESSUTI, Nicola MAFFULLI, Carlo Ambrogio LOGROSCINO

*From the Catholic University of Rome, Italy*

Pain is the main symptom of acetabular osteolysis from metastatic carcinoma, and it is frequently associated with pathologic fractures. Radiotherapy alone usually is not effective for pain control, and it does not allow weight bearing. Surgical procedures requiring an aggressive approach and consequently high morbidity are rarely indicated in patients with multiple metastases. Polymethylmethacrylate (PMMA) has been widely used in oncologic and spinal surgery as a bone filler. We evaluated the functional results of percutaneous injection of PMMA in 20 patients (24 acetabula) with acetabular osteolysis from metastatic carcinoma. Patients were assessed before and after percutaneous acetabuloplasty, evaluating pain, mobility of the hip joint, general condition, use of analgesics, using the SF-36, QLQ-C30, Eastern Cooperative Oncology Group (ECOG) Performance Scale and Harris Hip Score. There was a marked clinical improvement in all patients during the first six post-operative months, with gradual worsening thereafter from deterioration of their general condition over the 12-month follow-up period. Percutaneous acetabuloplasty is reliable and effective in the short term, with a statistically significant reduction of pain and improvement in quality of daily life.

**Keywords :** acetabular osteolysis ; cementoplasty ; percutaneous injections ; acrylic cement.

### INTRODUCTION

Treatment of patients with metastatic cancer has resulted in an increase in quality of life and

survival. Given the increasing longevity and detection of skeletal metastases, there is an increased incidence of their presence and complications (10). The most important functional problems are pathologic fractures of the lower limb (14). Periacetabular involvement may lead to structural weakening of the pelvis, limping, consequent inability to walk, prolonged bed rest with increase of co-morbidity. Osteolytic lesions of the acetabulum are clinically associated with pain often resistant to drugs and radiation therapy, and consequently poor quality of life. Radiotherapy often does not control the pain and/or restore the integrity of the acetabular area,

- 
- Laura Scaramuzzo, MD, Resident.
  - Giulio Maccauro, MD, Orthopaedic Surgeon, Researcher.
  - Barbara Rossi, MD Resident.
  - Laura Messuti, MD, Staff Doctor.
  - Carlo Ambrogio Logroscino, MD, Chief.  
*Orthopaedic Department, Catholic University, Rome, Italy.*
  - Nicola Maffulli, Centre Lead and Professor of Sports and Exercise Medicine, Consultant Trauma and Orthopaedic Surgeon.

*Centre for Sports and Exercise Medicine, Barts and the London School of Medicine and Dentistry, Mile End Hospital, Bancroft Road, London.*

Correspondence : Giulio Maccauro, M.D., Viale Delle Medaglie D'oro 246, 00136, Roma, Italy.

E-mail : giuliomac@tiscali.it

© 2009, Acta Orthopædica Belgica.

and therefore it cannot allow early weight-bearing (9,23). Surgical acetabular reconstruction requires bone curettage and reconstruction with prostheses, PMMA and pins (11). This technique has a high rate of local and systemic complications in patients with multiple metastases, and a survival rate no longer than 12 months postoperatively in about 50% of patients (11,24). PMMA alone has been widely used in neoplastic and spinal surgery as a bone filler (12,22). It is also used in the management of osteoporotic and pathological vertebral collapses to reduce or eliminate the local pain (7, 8,16,20). Similar techniques have been reported in the management of metastatic lesions around the acetabulum (5,6). We recently reported on 25 patients with acetabular metastases who received percutaneous acetabuloplasty, showing marked postoperative improvement (17), and we now focus on the timing of improvements of quality of life following percutaneous acetabuloplasty with PMMA for metastatic osteolytic lesions of the acetabulum.

## MATERIALS AND METHODS

In the period May to November 2007, 20 patients gave their written informed consent to undergo percutaneous acetabuloplasty. All patients affected by metastatic acetabular disease were evaluated by a multidisciplinary team, which included oncologists, radiotherapists, orthopaedic surgeons and radiologists. Patients received the procedure if it was not possible to perform surgical reconstruction of the acetabulum. The inclusion and exclusion criteria are reported in tables I and II.

All patients were evaluated before and 1, 3, 6, and 12 months after acetabuloplasty with regard to pain, hip joint mobility, general condition, quality of life using the Eastern Cooperative Oncology Group (ECOG), Short-Form-36 General Health Survey questionnaire, Quality of life questionnaire of the European Organization for Research and Treatment of Cancer (QLQ-C30), and Harris Hip Score. Moreover, the type and amounts of analgesic drugs taken to control the pain pre- and post-operatively were recorded.

Twenty patients (24 acetabuli ; 7 males and 13 female ; average age 61.3 years ; left side affected in 15 instances, right side affected in 9 instances) underwent the index procedure. At the time of percutaneous acetabuloplasty, 11 biopsies were performed using the

Table I. — Inclusion criteria to perform acetabuloplasty

Weight-bearing acetabular osteolysis
Hip pain resistant to drugs
Patients with multiple metastases
Short life expectancy
Inability to tolerate major surgery
Metastatic lesion not from kidney and thyroid cancer
Ineffective radiotherapy

Table II. — Exclusion criteria to perform acetabuloplasty

Acetabular fracture
Pelvic discontinuity
Radiographic signs of medial wall lesion
Local infection
Haemorrhagic disorders

same set of instruments (Stryker Corp. Kalamazoo, MI, USA). In two patients, together with acetabuloplasty, a proximal femur resection and reconstruction with a silver coated tumour bipolar endoprosthesis (Mutars Implantcast GmbH, Ankara Turkey) implanted for a pathologic transcervical femoral fracture. In three patients, an intramedullary reconstruction locked nail (Anterograde Femoral Nail, Synthes, USA) was implanted for a fracture or an impending fracture of the femoral diaphysis. Primary tumour location was : breast 10 cases, lung 7 cases, prostate 3 cases. The presence of an osteolytic acetabular lesion was evaluated preoperatively by standard radiography, CT and MRI.

## Statistics

Descriptive statistics were calculated. The results obtained were analysed using the  $\chi^2$  Test and Fisher's exact test. Significance was set at  $p < 0.05$ .

## RESULTS

In all patients, mechanical stabilization of the osteolytic lesion was achieved, with no pathological fractures and no clinical symptoms related to cement leakage. Five patients reported transient increased pain of the hip together with pyrexia in the immediate post-operative 48 hours. In only one patient with wide anterior osteolysis of acetabulum, acetabuloplasty did not obtain reduction of pain, and after 3 months curettage and filling with

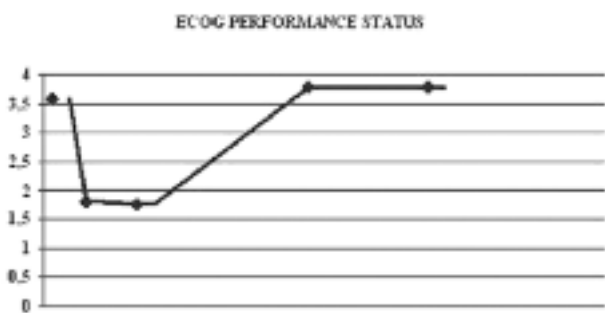


Fig. 1. — ECOG Performance Status questionnaire, patients : n = 20 ; p < 0.001, follow-up at 12 months.




Fig. 3. — Quality of Life questionnaire, patients : n = 20 ; p < 0.005, follow-up at 12 months.

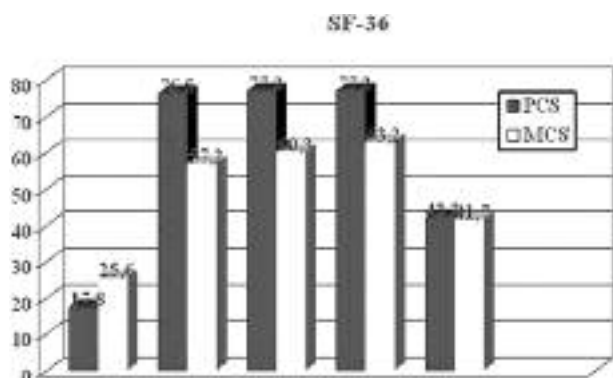


Fig. 2. — SF-36 questionnaire, patients : n = 20 ; p < 0.005, follow-up at 12 months.




Fig. 4. — Harris Hip Score questionnaire, patients : n = 20 ; p < 0.001, follow-up at 12 months.

cement through the ilioinguinal approach was required.

An overall improvement in the quality of life of the patients was evident, and patients were able to return to their activities of daily living (fig 1, 2, 3, 4). The ECOG index showed improvement of the patients' general condition up to 6 months after the index procedure, with an average score improving from 3.57 preoperatively, to 1.80 at 1 month, 1.75 at 3 months, and 1.70 at 6 months. Worsening of general condition was evident one year after surgery, with an average score of 3.76, with 7 patients dead by that time. The SF-36 questionnaire showed a marked improvement in physical functions up to 6 months after the surgical treatment, with an average score improving from 17.8% preoperatively, to 76.5% at 1 month, 77.2% at 3 months, and 77.2% at

6 months. Worsening was observed one year after the procedure, with an average score of 42.3%. A minor improvement was observed in the mental component, with the average score improving from 25.6% preoperatively, to 57.2% at 1 month, 60.3% at 3 months, and 63.2% at 6 months. Worsening of mental component was observed at one year follow-up, with an average score of 41.7%. The Questionnaire for Cancer Patients Treated with Anticancer Drugs (QOL-ACD) index showed an improvement of the patients' general condition up to 3 months after the index procedure, with an average score improving from 17% preoperatively, to 56% at 1 month, 64% at 3 months, worsening at 6 months with an average score of 50%. This resulted from worsening in the mental and emotional aspects from progression of the primary pathology.

Worsening of the general condition was observed one year after surgery, with an average score of 35%, with 7 patients dead by that time.

The HHS score showed an improvement in the ability to carry out standard daily activities autonomously, with a preoperative score of 33.6% rising to a postoperative score of 72.7% one month after percutaneous acetabuloplasty, which further improved (83.8%) 3 months after the procedure. At the one year follow-up, worsening of the general condition was observed, with reduced autonomy, with the average HHS score dropping to 60.2%, still higher however than the pre-operative score.

In summary, complete pain relief was achieved in 75% of patients ( $n = 15$ ). Pain reduction was achieved in 4 (20%), and no pain relief was achieved in 1 of 20 patients (5%). The mean duration of pain relief was 7.3 months (median : 6 months). Pain recurred in 2 patients (10%) between 2 weeks to 3 months. Seven patients died, and 13 patients were still alive by the 12 months follow up, with only 1 patient lost to follow-up. The 12 months survival rate was 65% (observation period : 1-18 months). No major complications occurred. There was transient local pain in most cases, and 2 cases of venous injection of cement without clinical consequences.

It is impossible to quantify the reduction of analgesic drug consumption in patients with systemic neoplastic disease, due to the coexistence of multiple secondary lesions. Nevertheless, some reduction of drug administration was observed in 3 patients (15%) (from 75 mg of opioids (morphine) to 50 mg), a marked reduction (from 75 mg of opioids (morphine) to 25 mg) in 13 patients (65%), and 4 patients (20%) stopped taking analgesic drugs altogether in the post-operative period, even when radiotherapy was not effective. The mean duration of the reduction of drug administration was 3 months.

## DISCUSSION

When metastatic cancer is localized in the acetabulum, surgery involves three stages : tumour resection, filling of the residual bone cavity, bone segment stabilization. The Harrington technique,

consisting in filling the cavity with acrylic cement reinforced with pins and a hip or pelvis prosthesis, is still considered useful for the management of acetabular metastasis (11). The survival rate of these patients is poor, and is generally estimated in a median period of 3 months in patients with visceral metastases, and 12 months in patients without visceral metastases (4). The rate of death and major complications is up to 50% (24), and this risk is justified only if the lesion is isolated, and the primary tumour has a good prognosis, and/or radiation therapy is not effective (such as in kidney cancer). Moreover, the acetabular lesion is not isolated (10), and most tumoral lesions producing acetabular metastases are responsive to radiotherapy.

Malignant lesions may produce pain from direct action on the nervous system (19). However, different modalities of pain production may act in the presence of skeletal metastases (18). Cement injection may immediately reduce pain in patients with acetabular metastases with no protrusion or pelvic fracture, with at least partial pain relief in about 80% of patients within two weeks of the injection (6,13). Radiotherapy alone does not improve the mechanical properties of the affected acetabular region, and transient osteoporosis is usually observed, with the risk of pathological fractures. Acetabuloplasty can aid radiotherapy, both by improving pain and by providing a mechanical support at a stage during which radiotherapy alone would not be able to prevent pathological fractures (13). Complications may also occur in pelvic cementoplasty but, in our experience, they were only relatively minor, and only one patient required curettage and cement introduction through an anterior approach. The authors analysed the functional results in terms of general and local condition's improvement, using ECOG, QOL and physical condition (SF-36). All questionnaires demonstrated a marked improvement in physical condition and quality of life in the first six months, a worsening of the quality of life was observed in the next six months due to deterioration of general condition and progression of the primary pathology. A minor and slow improvement was observed in mental condition analysed with the SF-36 and QLQ-C30.

The improvement obtained may be influenced by the psychological condition of the patients, as the mental condition of cancer patients is generally influenced by general health status and evolution of the primary pathology. Although showing a ceiling effect in mental items, SF-36 and QLQ-C30 are now used to evaluate quality of life (QOL) in cancer patients (3). The burden of this disease could then be more easily compared with that of other diseases, and the resulting standardization of QOL analysis would be simpler and more cost effective (1,2,3,21). The ceiling effects observed are not specific to patients with metastatic disease, and may therefore indicate the lack of sensitivity of some SF-36 mental scales in general, especially in patients with many co-morbidities.

Hip function was tested using the Harris Hip Score (15), which measures the daily autonomy related with hip functionality.

The mean duration of pain relief was 6 months (fig 1, 2, 3, 4). After that period, worsening of the patients' condition from progression of the underlying disease also influenced the local results, indicating that local treatment may no longer modify the natural history of the disease. At one year after acetabuloplasty, 7 patients had died from cancer progression, 13 were still alive, with only one patient lost to follow-up. No major complications were observed. In a previous report, the authors considered femoral neck fracture as an indication to cementoplasty combined with endoprosthesis if a pelvic lesion was present. In the present series, acetabuloplasty was combined with tumoral endoprosthesis if a wide lesion was present in the proximal femur and in the acetabulum: the clinical and functional results were good. Tumoral endoprosthesis allows to remove the gross cancer from the femur and acetabuloplasty improves the mechanical properties of the acetabulum involved. With this technique two effects can be obtained: the insertion of an endoprosthesis with lower risk of dislocation than a regular prosthesis, and the lower haemorrhagic risk of acetabuloplasty when compared to socket implantation.

The functional results obtained confirmed that bone cement injected into an osteolytic acetabular defect is able to restore some of the compromised

mechanical proprieties, and that the functional improvement improves the quality of life of cancer patients. Cement injection may prevent pelvic fractures from the periacetabular defects. Obviously, a randomized controlled trial comparing radiotherapy, radiofrequency ablation and cementoplasty should be considered in the future. In comparison with open surgery, the survival rate is similar (about 12 months), but the morbidities and complications of acetabuloplasty are lower.

In conclusion, percutaneous acetabuloplasty is a palliative mini-invasive technique that produces effective results in the management of acetabular osteolyses in patients with multiple metastases and with a low life expectancy. Percutaneous acetabuloplasty is effective in improving the quality of life of patients with osteolytic bone tumours, even though the improvement is observed during the first six months only. It can be an effective aid to chemo- and radiotherapy in the management of acetabular metastases.

## REFERENCES

1. **Aaronson NK, Ahmedzai S, Bergman B et al.** The European Organisation for Research and Treatment of Cancer QLQ-C30: A quality of life instrument for use in international clinical trials oncology. *J Natl Cancer Inst* 1993; 85: 365-376.
2. **Apolone G, Filiberti A, Cifani S, Ruggiata R, Mosconi P.** Evaluation of the EORTC QLQ-C30 questionnaire: A comparison with SF-36 health survey in a cohort of Italian long survival cancer. *Ann Oncol* 1998; 9: 549-557.
3. **Clohisy DR, Le CT, Umen AJ.** Measuring health status in patients with skeletal metastases treated by surgery. *Am J Clinical Oncol* 1997; 20: 424-428.
4. **Clohisy DR, Manthy PW.** Bone cancer pain. *Cancer* 2003; 97: 866-887.
5. **Cotten A, Demondion X, Boutry N et al.** Therapeutic percutaneous injections in the treatment of malignant acetabular osteolyses. *Radiographics* 1999; 19: 647-653.
6. **Cotten A, Deprez X, Migaud H et al.** Malignant acetabular osteolyses: percutaneous injection of acrylic bone cement. *Radiology* 1995; 197: 307-310.
7. **Deramond H, Depriester C, Galibert P, Le Gars D.** Percutaneous vertebroplasty with polymethylmethacrylate. Technique, indications, and results. *Radiol Clin North Am* 1998; 36: 533-546.
8. **Galibert P, Deramond H, Rosat P, Le Gars D.** [Preliminary note on the treatment of vertebral angioma by

- percutaneous acrylic vertebroplasty.] (in French). *Neurochirurgie* 1987 ; 33 : 166-168.
9. **Gilbert HA, Kagam AR, Nussbaum H.** Evaluation of radiation therapy for bone metastases : pain relief and quality of life. *AJR Am J Roentgenol* 1977 ; 129 : 1095-1096.
  10. **Habermann ET, Lopez RA.** Metastatic disease of the bone and treatment of pathological fractures. *Orthop Clin North Am* 1989 ; 20 : 469-503.
  11. **Harrington KD.** The management of acetabular insufficiency secondary to metastatic malignant disease. *J Bone Joint Surg* 1981 ; 63-A : 653-664.
  12. **Healey JH, Shannon F, Boland P, DiResta GR.** PMMA to stabilize bone and deliver antineoplastic and anti-resorptive agents. *Clin Orthop Relat Res* 2003 ; 415 Suppl : S263-S275.
  13. **Higgins KB, Harten RD, Langrana NA, Reiter MF.** Biomechanical effects of unipedicular vertebroplasty on intact vertebrae. *Spine* 2003 ; 28 : 1540-1547.
  14. **Higinbotham NL, Marcove RC.** The management of pathological fractures. *J Trauma* 1965 ; 5 : 792-798.
  15. **Kavanagh BF, Fitzgerald RH Jr.** Clinical and roentgenographic assessment of total hip arthroplasty. A new hip score. *Clin Orthop Relat Res* 1985 ; 193 : 133-140.
  16. **Lieberman I, Reinhardt MK.** Vertebroplasty and kyphoplasty for osteolytic vertebral collapse. *Clin Orthop Relat Res* 2003 ; 415 Suppl : S176-S186.
  17. **Maccauro G, Liuzza F, Scaramuzza L et al.** Percutaneous acetabuloplasty for metastatic acetabular lesions. *BMC Musculoskeletal Disorders* 2008 ; 9 : 66.
  18. **Marco RA, Sheth DS, Boland PJ et al.** Functional and oncological outcome of acetabular reconstruction for the treatment of metastatic disease. *J Bone Joint Surg* 2000 ; 82-A : 642-651.
  19. **Mirels H.** Metastasis disease in long bones : A proposed scoring system for diagnosis impending pathologic fractures. *Clin Orthop Relat Res* 2003 ; 415 Suppl : S4-S13.
  20. **Phillips FM, Pfeifer BA, Lieberman IH.** Minimally invasive treatments of osteoporotic vertebral compression fractures : vertebroplasty and kyphoplasty. *Instr Course Lect* 2003 ; 52 : 559-567.
  21. **Reulen RC, Zeegers MP, Jenkinson C et al.** The use of the SF-36 questionnaire in adult survivors of childhood cancer : evaluation of data quality, score reliability, and scaling assumptions. *Health and Quality of Life* 2006 ; 4 : 77.
  22. **Ryan JR, Begeman PC.** The effects of filling experimental large cortical defects with methylmethacrylate. *Clin Orthop Relat Res* 1984 ; 185 : 306-310.
  23. **Shepherd S.** Radiotherapy and the management of metastatic bone pain. *Clin Radiol* 1988 ; 39 : 547-550.
  24. **Wunder JS, Ferguson PC, Griffin AM, Pressman A, Bell RS.** Acetabular metastases : Planning for reconstruction and review of results. *Clin Orthop Relat Res* 2003 ; 415 Suppl : S187-S197.