



Biological plate fixation of comminuted subtrochanteric fractures with the Dynamic Condylar Screw : A clinical study

Devdatta S. NEOGI, Vivek TRIKHA, Kaushal K. MISHRA, Narender ROHILLA , Chandra S. YADAV

*From the Department of Orthopaedics & Jayprakash Narayan Apex Trauma Centre,
All India Institute of Medical Sciences, New Delhi, India*

Subtrochanteric fractures are fraught with anatomical, biological and biomechanical challenges which account for an increased incidence of nonunion and malunion. We retrospectively assessed the results achieved in 40 patients with a mean age of 36 years who were treated with biological plating using a Dynamic Condylar Screw for comminuted subtrochanteric femoral fractures between January 2004 to May 2007. Union was achieved in all cases at a mean of 15.6 weeks, with one major and 3 minor technical difficulties. There was limb length discrepancy (mean : 1 cm) in 5 cases and rotational deformity in 4 cases. Results were excellent in 45% of cases, good in 50% and fair in 5% according to Sanders' criteria. There was no statistically significant difference between the healthy and fractured sides with respect to femoral neck-shaft angles. Use of fracture table, adequate two plane fluoroscopy and adherence to technical details give predictable results with this implant available at an affordable cost, even in countries with low socio-economic status.

Keywords : subtrochanteric fractures ; biological plating ; dynamic condylar screw.

INTRODUCTION

Subtrochanteric femoral fractures, between the lower limit of the lesser trochanter to about 5 cm distal to it (1), pose certain anatomical, biological and biomechanical challenges and typically give high

complication rates. Intramedullary devices have a biomechanical advantage over extramedullary devices (1). However, when intramedullary devices cannot be used for technical reasons such as a small-size trochanter in east Asian population (14), a narrow medullary canal, proximal fracture extension into the greater trochanter and piriformis fossa, and in such conditions as polytrauma, head injury, pulmonary compromise, a fixed-angle plate such as the condylar blade plate (CBP) or the dynamic condylar screw (DCS) has been recommended for the treatment of subtrochanteric fractures (10). Biological fixation preserving the soft-tissue vascularity and encouraging rapid callus formation may decrease the complications associated with conventional plate osteosynthesis (9,27). The aim of this study was to evaluate the technical difficulties and results in

■ Devdatta Suhas Neogi, MS (Ortho), DNB, MCh Orth, MRCSEd, Dip SICOT, Senior resident.

■ Vivek Trikha, MS (Ortho), Assistant Professor.

■ Kaushal Kant Mishra, MS (Ortho), MCh Orth, Senior resident.

■ Narender Rohilla, MS (Ortho), Senior resident.

■ Chandra Shekhar Yadav, MS (Ortho), Associate Professor.

Correspondence : Dr Vivek Trikha, Department of Orthopaedics, Jayprakash Narayan Apex Trauma Centre, All India Institute of Medical Sciences, New Delhi, India.

E-mail : vivektrikhaortho@gmail.com

© 2009, Acta Orthopædica Belgica.

Table I. — Fracture patterns

Fracture type	1	2	3
3.2 B	8	9	8
3.2 C	9	0	6

Subtrochanteric fractures are classified as 3.2-(X)(Y) where in X may be A/B/C and Y may be 1/2/3 depending on the type of comminution. The last numeric symbol indicates the subtrochanteric region.

patients treated with DCS bridge plating for comminuted subtrochanteric femoral fractures.

MATERIALS AND METHODS

Patients aged between 18 and 60 years with comminuted, closed subtrochanteric fractures treated between January 2004 and May 2007 were included in the study ; open, osteoporotic and pathological fractures were excluded. Fractures were classified according to the AO/OTA classification (table I) (16). All patients were subjected to preoperative upper tibial skeletal traction following routine radiographic examination upon admission. They were kept in traction until their condition was stabilised and appropriate for an operation. Bridge plating with the DCS under fluoroscopy control, according to biological fixation principles, was carried out in all patients.

Pre-operatively routine radiological examination of the normal limb was also obtained as a part of planning. The entry point, inclination of lag screw, length of the implant were charted using templates and possible difficulties in reduction were anticipated and discussed.

Informed consent was obtained and patients were preferably operated on a fracture table with the uninjured limb flexed and abducted to enable fluoroscopy use. Longitudinal traction was applied to the extremity. Correct alignment and rotation was checked pre-operatively as described by Krettek *et al* (12). After observing satisfactory reduction the plate size was reconfirmed by fluoroscopy. During draping care was taken that the patella was palpable, as this can act as a guide for intra-operative rotation control. A 5-6 cm incision was made centered on the tip of the greater trochanter. A guide wire was passed along the anterior aspect of the neck to note the anteversion. In some cases when the proximal fragment was not getting reduced, a Schanz pin was passed such that it would not come in the way of lag screw

placement, and the proximal fragment reduction was obtained. Every step was checked using both antero-posterior (AP) and lateral views of radiographs using a C-arm, as even in experienced hands the use of biological plating is sometimes associated with unacceptable reductions in the axial view. The DCS angle guide with a guide wire was placed over the skin on the anterior aspect of the thigh and its position was adjusted using fluoroscopy guidance. The lag screw guide wire was passed parallel to the previous two wires, the entry point being in the anterior half of the greater trochanter, the wire was over-drilled with the triple reamer using all three segments and the condylar screw was driven into the femoral neck. The use of a periosteal elevator and bone holding clamps were avoided during reduction, thus preserving periosteum and soft tissue attachments. Leg length was adjusted by traction, paying attention to prevent over distraction after reduction.

A plate of predetermined length was then slipped under the vastus lateralis, with the barrel facing the surgeon. An additional lateral incision was then made over the shaft distal to the area of comminution. The plate was turned on itself and by manipulating the plate through the two incisions it was slipped over the lag screw. During this step difficulties to engage the plate into the nail were overcome by making use of all the three segments of the triple reamer when making the lag screw tract and using the compression screw holder through the barrel of the DCS plate (in the wrench) to lever the plate in the direction of the lag screw. The plate could also be manipulated distally using a bone-holding forceps or a bone hook. If reduction was adequate, the plate was then fixed distally with at least four cortical screws. If the proximal fragment reduction was unstable, then the plate was first fixed proximally with another one or two screws and later fixed distally. Separate drains were used for both the wounds.

On the second postoperative day, range of movement exercises and straight leg lifts were started. On the third postoperative day, patients began walking using crutches or a frame, with touch-down weight-bearing. Follow-up visits with radiographs took place at 6-week intervals till fracture union and subsequently every 6 months for radiographs and functional outcome assessment with Sander's criteria (2). As soon as callus was detected, progressive weight-bearing was encouraged. Crutches or a frame were used until union was achieved at four cortices and the patient could demonstrate full weight-bearing on the operated leg for 60 seconds.

The statistical analysis was done using SSPS software.




Fig. 1. – Jig placement over the skin and fluoroscopy image

RESULTS

We had 40 patients, of whom 27 patients were male and 13 females. Their mean age was 36 years (range : 20 to 61 ; SD : 10.8). All the fractures were sustained in high-energy injuries with 33 patients (82.5%) being involved in motor vehicle accidents and seven (17.5%) having fallen from a height. Average time from admission to surgery was 4 days (range : 2 to 10 ; SD : 1.5). Twenty six cases were operated on a fracture table. The mean operating time was 62 min (range : 50 to 126 ; SD : 12.7). Three cases required complete skin and tensor fascia lata incision due to inability to rotate the plate and slip it over the lag screw. Average external blood loss was 250 ml (range : 150 to 400 ; SD : 55). Average hospitalisation was 14 days (range : 7 to 21 ; SD : 3.6). We had an average follow-up of 32 months (range : 19 to 54 ; SD : 8.6). Average time to union was 15.6 weeks (range : 13 to 19 ; SD : 1.8) with no cases of delayed union and one technical failure. All patients except one returned to their pre-operative level of activity by the seventh month. The patient with technical failure was operated without a fracture table and due to inadequate imaging during surgery, had inadequate reduction subsequently detected on the post-operative lateral view and hence later underwent open reduction and internal fixation with a cephalomedullary nail and bone grafting. We had limb length discrepancy in 5 cases (average 1 cm) and external rotation deformity 10°-20° in 4 cases. According to Sanders' hip

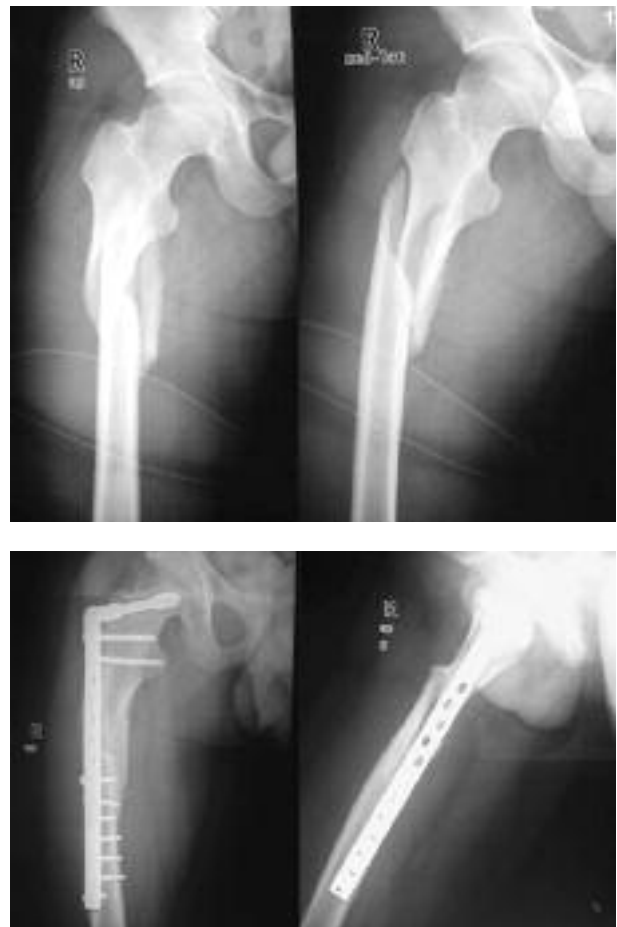

Fig. 2. – Case 1. a : Pre-operative radiograph ; b : Radiograph showing fracture union with good callus formation.

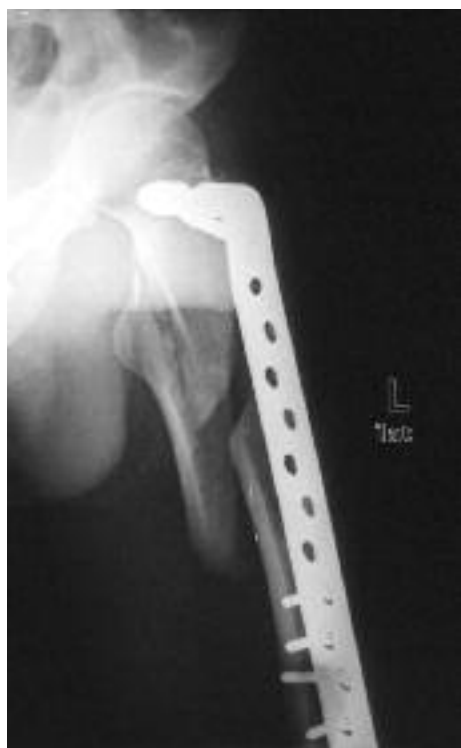

Fig. 3. – Technical failure secondary to inadequate reduction

rating scale, results were excellent in 45% cases good in 50% and poor in 5%. There was no statistically significant difference using the Fischer exact test between the healthy and fractured sides with respect to femoral shaft-neck angles ($p = 0.11$).

DISCUSSION

Subtrochanteric femoral fractures represent 7 to 34% of proximal femoral fractures (1). In young individuals they usually result from high-energy trauma and often show significant comminution (1,9,27). Major compressive stresses in the femur are greatest in the medial cortex 2.5 to 7.5 cm below the lesser trochanter, exceeding 84 kg/cm^2 (11,26). Slightly less tensile forces of 63 kg/cm^2 occur at the proximal lateral femoral cortex (11,26). Biomechanical studies have shown that the femoral cortex in the postero-medial subtrochanteric region is subjected to the highest stresses in the body (3). Restoration of the integrity

of the postero-medial column then allows the DCS to act as a tension band along the lateral femoral cortex (1,3). However, if the column's integrity is not restored, all implants are subjected to high bending stresses (3,6). It is in this situation that the cephalomedullary nail is subjected to lower bending moments as it is closer to the neutral axis of the femur (17). There is thus a race between implant failure and fracture healing. In comparing the DCS and the cephalomedullary nail, successful fracture healing has been shown to be more dependent on the indirect reduction techniques which preserve blood supply rather than being related solely to the mechanical strength of the implant (17). Current implants have shown excellent ability to withstand cyclic bending stresses while bridging callus is formed (1). Early callus formation in the medial cortex obtained by a flexible fixation and biological fixation averts implant failure (3).

Subtrochanteric fractures have a bimodal distribution with high-energy trauma causing comminuted fractures in younger adults and low-energy trauma causing mostly spiral fractures in the elderly (1). Elderly patients also have associated osteoporosis (1,21). Subtrochanteric fractures in the elderly have a high mortality rate – up to 24.5% within the first year after injury – and result in an increased level of social dependency and reduced walking ability among survivors (21). Hence this patient subset was excluded from the study and we took 60 years as an empirical dividing point. However when these patients above 60 years present to us we still often perform biological plating with DCS, while in presence of osteoporotic bone we preferentially use an intramedullary device in spite of financial constraints.

The proximal femur has a good muscular coverage all around (2) and hence exposure of bone is uncommon. However the chances of infection in open fractures are increased (2) and this may increase the complication rate unrelated to the procedure; open fractures were therefore not included in the study. Intramedullary nailing has been satisfactory for stable or non-fragmented fractures; however various complications have been encountered in comminuted fractures, especially in AO type C fractures (4,7,9). Conventional

statically locked intramedullary nails may be useful in 3.2-A subtrochanteric fractures, however when the lesser trochanter is fractured, this compromises the proximal interlocking screw placement and the biomechanical construct (1,28). In such cases cephalomedullary nails are preferable, as they have interlocking screws which gain purchase in the femoral neck and head (1,28). Deforming forces secondary to the muscles attached to the proximal fragment lead to technical challenges in cephalomedullary nailing (1,2). Fracture abduction may make finding the entry point difficult (25). Flexion of the proximal fragment, if not identified and corrected, may cause reaming of the posterior cortex and potential residual flexion after insertion of the nail (25). Other complications such as non-union, delayed union, varus deformity, peroneal nerve paralysis, shaft fracture during surgery, fracture of the greater trochanter, perforation of the knee joint and fixation device breakage have been reported (8,9,20). Cephalomedullary nails marketed in India are the Proximal femoral nail (PFN, Synthes) and the Antegrade femoral nail (Synthes). Both have two proximal screws which demand accurate nail insertion, lest the screws would miss the femoral neck. Nails with a single proximal lock such as the Gamma nail - Asia Pacific (Stryker) or the Russel-Taylor Reconstruction nail (Smith & Nephew) are not yet marketed in India and the Proximal Femoral Nail-A (Synthes) is only available since mid 2008. Moreover they are nearly four times more expensive than the DCS or DHS, and their routine use in the absence of a general health insurance is not feasible. Locally made cephalomedullary nails are also available, which are poor mimics in geometry and in addition also have nail – jig mismatch more commonly seen after nail insertion, thus making cephalomedullary locking a tedious and perilous effort. This further increases operative time and radiation exposure. These implants are also of indeterminate metallurgy. Another important concern is the large proximal diameter of these implants which may require reaming of the trochanter to 17-18 mm (25). The long term importance of removing this amount of bone from the proximal femur in a young patient is unknown and should be considered cautiously (25).

Also this amount of reaming at the greater trochanter may have an effect on the abductor insertion (25). In cases with extension of the fracture to the trochanter or piriformis fossa, the use of intramedullary nails may lead to further displacement of the inter-trochanteric component of the fracture (1,2,25).

The available literature comparing the intra and extra medullary techniques is limited. Most studies are based on experience with wide variability in patient characteristics and use of either an intramedullary or an extramedullary implant. One prospective study comparing intramedullary nailing and biological plating concluded that intramedullary nailing offered no advantage over biological plating with a DCS in young patients with comminuted subtrochanteric fractures (13). A Cochrane review has also recommended further studies to determine if intramedullary nailing is advantageous in subtrochanteric fractures (18). Schipper *et al* (24) tried to perform a meta analysis but found themselves unable to do so as methodological considerations precluded analysis. Many studies included both stable and unstable fracture patterns. Available studies are hampered by a lack of randomisation, small samples and no power calculations.

Among the extramedullary devices, the DHS, DCS and CBP are the ones most commonly used (3,9,10,27). DHS is not the preferred implant in comminuted subtrochanteric fractures because, due to comminution, the compression screw is often the only hold in the proximal fragment and hence sagittal plane control of deformities is poor, and secondly any sliding of the compression screw in the plate results in medial translation of the femoral shaft (25). DCS and CBP have a higher entry point and hence provide better proximal anchorage by using additional screws in the proximal fragment (13,25). However DHS may still have a role in low subtrochanteric fractures, where an additional screw can be inserted into the proximal fragment. Also in our experience of biological plating, passing the DHS barrel over the compression screw is easier compared to DCS or CBP.

In comparison to DCS, CBP is more technically demanding as it requires a three plane alignment

while, with the DCS, sagittal alignment can be accomplished by rotating the plate screw construct after insertion (13,23,27). Moreover in biological plating, rotating the CBP after submuscular slide is difficult while it is relatively easier with the DCS (27). The AP diameter of the femur neck is narrow in Indian bones compared to the width of the CBP and there are increased chances of cut-out in the AP plane if a CBP is used (27). The DCS provides strong fixation in the cancellous bone of the neck and head, with considerable rotational stability (27). Whenever possible, one or two cortical screws should be used through proximal plate holes so as to fix it to the calcar to improve rotational stability (17,27). Coupling screws should be used as this prevents pullout of the plate from the screw. After indirect reconstruction of the medial cortex the DCS acts as a tension band device on the lateral side (27). With insufficient reconstruction of the medial cortex the implant is loaded with substantial bending forces and we recommend a strict weight bearing protocol to be observed (27). Secondary loss of reduction and deformity and in some cases implant failure have been described when patients have not adhered to the weight bearing protocol in the post-operative period (21,27).

The only one case of major technical failure in our study was due to inadequate surgical technique and fluoroscopy and hence we recommend use of a fracture table so that adequate two-plane fluoroscopy can be performed during surgery. In three other cases, of whom two were muscular males and one was an obese female, we had difficulties with plate rotation and subsequent slippage. In these we resorted to a complete skin and fascia lata incision.. Farouk *et al* (5) did a cadaver arterial injection study to analyze the vascular supply to the femur and to study the effects of two surgical plating techniques on femoral vascularity. On one side, the plate was inserted using a conventional method with elevation of vastus lateralis to expose the shaft, on the contralateral side the plate was inserted percutaneously beneath the muscle. The results of this study indicate that the second method is superior in maintaining arterial femoral vascularity and perfusion. Biological plating does not interfere with the medullary blood supply as does reamed

intramedullary nailing (27). Viable bones unite rapidly by callus formation (15). Although our study had all cases with type 3.2-B and C pattern, the lack of medial support was compatible with safe healing due to preservation of blood supply. Implant loosening or fatigue is avoided by early callus bridging (19). When soft tissues are preserved, bone grafting may be unnecessary even in fractures with large bone defects (15). Various authors have reported a 100% union rate using this method of indirect reduction and biological plating (3,9,27). Preservation of the periosteum and soft tissue attachments of comminuted fragments helps reduce fracture fragments by soft tissue taxis while obtaining axial and rotational alignment and the correct length (15). Longer plates improve the mechanical leverage (15). Plate-related osteoporosis is less common in biological fixation than in compression plating, as the implant contact area is reduced in the fracture zone (19).

We did have minimal shortening averaging 1 cm in 5 cases and external rotation 10°-20° in 4 cases. However none of the patients had any appreciable limp. Similarly other studies have also reported shortening and rotational deformities within acceptable limits to be the most common complications (3,22,27).

CONCLUSIONS

Subtrochanteric femur fractures are often the result of complex, high-energy mechanisms and demand special surgical consideration. Emphasis on preservation of blood supply and soft tissue integrity in the fracture zone has decreased the complications and permitted earlier functional recovery. The DCS used in this technique is cheaper and more easily supplied than many others in our country. Appropriate placement of the guide wire and slipping of the plate over the lag screw are important steps and can be simplified using the technique described. The success rate is high when the technique is correctly implemented. Therefore, we believe that it is a treatment of choice in patients with good bone stock, that can be successfully used in countries at a low socioeconomic level, with no efficient health insurance system. Fluoroscopy

guidance in two planes is essential to prevent malalignment and limb length discrepancy.

REFERENCES

1. **Bedi A, Le TT.** Subtrochanteric femur fractures. *Orthop Clin North Am* 2004 ; 35 : 473-483.
2. **Behren FF, Sirkin MS.** Fractures with soft tissue injuries. In Browner BD, Jupiter JB, Levine AM *et al* (eds). *Skeletal Trauma : Basic Science, Management, and Reconstruction*. 3rd ed. Elsevier Science, Philadelphia, 2003, pp 293-319.
3. **Celebi L, Can M, Muratli HH *et al*.** Indirect reduction and biological internal fixation of comminuted subtrochanteric fractures of the femur. *Injury* 2006 ; 37 : 740-750.
4. **Ertürer E, Tekkeflin M, Dirik Y *et al*.** Radiographic and functional results of osteosynthesis with locked intramedullary nailing of subtrochanteric fractures of the femur. *Acta Orthop Traumatol Turc* 2004 ; 38 : 265-269.
5. **Farouk O, Krettek C, Miclau T *et al*.** Effects of percutaneous and conventional plating techniques on the blood supply to the femur. *Arch Orthop Trauma Surg* 1998 ; 117 : 438-441.
6. **Fielding JW, Cochran GV, Zickel RE.** Biomechanical characteristics and surgical management of subtrochanteric fractures. *Orthop Clin North Am* 1974 ; 5 : 629-650.
7. **Haidukewych GJ, Berry DJ.** Nonunion of fractures of the subtrochanteric region of the femur. *Clin Orthop* 2004 ; 419 : 185-188.
8. **Kakkar R, Kumar S, Singh AK.** Cephalomedullary nailing for proximal femoral fractures. *Int Orthop* 2005 ; 29 : 21-44.
9. **Kayali C, Agus H, Zincircioglu G.** The role of biological fixation with bridge plating for comminuted subtrochanteric fractures of the femur. *Ulus Travma Acil Cerrahi Derg* 2008 ; 14 : 53-58.
10. **Kesemenli C, Subasi M, Necmioglu S, Kapukaya A.** Treatment of multifragmentary fractures of the femur by indirect reduction (biological) and plate fixation. *Injury* 2002 ; 33 : 691-699.
11. **Koch JC.** The laws of bone architecture. *Am J Anat* 1917 ; 21 : 177-298.
12. **Krettek C, Miclau T, Grun O *et al*.** Intraoperative control of axes, rotation and length in femoral and tibial fractures – technical note. *Injury* 1998 ; 29 (Suppl 3) : SC29-SC39.
13. **Lee PC, Hsieh PH, Yu SW *et al*.** Biologic plating versus intramedullary nailing for comminuted subtrochanteric fractures in young adults : A prospective, randomized study of 66 cases. *J Trauma* 2007 ; 63 : 1283-1291.
14. **Leung KS, So WS, Shen WY.** Gamma nails and dynamic hip screws for peritrochanteric fractures. A randomized prospective study in elderly patients. *J Bone Joint Surg* 1992 ; 74-B : 345-351.
15. **Leunig M, Hertel R, Siebenrock KA *et al*.** The evolution of indirect reduction techniques for the treatment of fractures. *Clin Orthop* 2000 ; 375 : 7-14.
16. **Muller ME, Nazarian S, Koch P *et al*.** *The Comprehensive Classification of Fractures of Long Bones*. Springer-Verlag, Berlin, 1990.
17. **Nungu KS, Olerud C, Rehnberg L.** Treatment of subtrochanteric fractures with the AO dynamic condylar screw. *Injury* 1993 ; 24 : 90-92.
18. **Parker MJ, Handoll HHG.** Gamma and other cephalocondylic intramedullary nails versus extramedullary implants for extracapsular hip fractures in adults. *Cochrane Database of Systematic Reviews* 2008, Issue 3. Art. No. : CD000093. DOI : 10.1002/14651858.CD000093.pub4.
19. **Perren SM.** Evolution of the internal fixation of long bone fractures. The scientific basis of biological internal fixation : choosing a new balance between stability and biology. *J Bone Joint Surg* 2002 ; 84-B : 1093-1110.
20. **Pervez H, Parker MJ.** Results of the long Gamma nail for complex proximal femoral fractures. *Injury* 2001 ; 32 : 704-707.
21. **Robinson CM, Houshian S, Khan LAK.** Trochanteric entry long cephalomedullary nailing of subtrochanteric fractures caused by low-energy trauma. *J Bone Joint Surg* 2005 ; 87-A : 2217-2226.
22. **Rohilla R, Singh R, Magu NK *et al*.** Mini-incision dynamic condylar screw fixation for comminuted subtrochanteric hip fractures. *J Orthop Surg* 2008 ; 16 : 150-155.
23. **Sanders R, Regazonni P.** Treatment of subtrochanteric femur fractures using the dynamic condylar screw. *J Orthop Trauma* 1989 ; 3 : 206-213.
24. **Schipper IB, Marti RK, Werken CV.** Unstable trochanteric femoral fractures : extramedullary or intramedullary fixation. Review of literature. *Injury* 2004 ; 35 : 142-151.
25. **Sims SH.** Subtrochanteric femoral fractures. *Orthop Clin North Am* 2002 ; 33 : 113-126.
26. **Tordis TG.** Stress analysis of the femur. *J Biomech* 1969 ; 2 : 163-174.
27. **Vaidya SV, Dholakia DB, Chatterjee A.** The use of a dynamic condylar screw and biological reduction techniques for subtrochanteric femur fracture. *Injury* 2003 ; 34 : 123-128.
28. **Wiss DA, Brien WW.** Subtrochanteric fractures of the femur : Results of treatment by interlocking nailing. *Clin Orthop* 1992 ; 283 : 231-236.