



Isometric reconstruction of the posterolateral corner of the knee

Shi-yuan SHI, Xiao-Zhang YING, Qi ZHENG, Guo-Ping CAO

From Hangzhou Red Cross Hospital, Hangzhou City, Zhejiang province, China

To date, there is no consensus on the best technique to repair injured posterolateral structures of the knee. We evaluated the effects of a fibular head based isometric reconstruction of the posterolateral knee corner with a double bundle semitendinosus tendon. From February 2001 to February 2005, 18 isometric reconstructions of a chronic posterolateral corner (PLC) injury of the knee were performed using the semitendinosus tendon. The average age of the patients was 39 years, ranging from 19 to 52 years. Twelve were male and 6 female. The time interval between injury and treatment ranged from 1.5 to 14 months. Three patients had simple PLC injuries, 10 had combined PLC-posterior cruciate ligament (PCL) injuries and two of them had undergone a PCL reconstruction elsewhere 6.5 months prior to referral. Three other patients had an associated anterior cruciate ligament (ACL) injury and two had a combination of PLC with ACL and PCL injury. A doubled semitendinosus tendon was threaded through bony tunnels in the fibular head running from the insertion of the lateral collateral ligament (LCL) to the fibular insertion of the popliteo-fibular ligament and both ends were fixed proximally into bony tunnels of the lateral femoral condyle at their respective isometric point. The varus stress test and the posterolateral rotation test were used to evaluate stability of the posterolateral structures. Isometry was optimal between the femoral attachment site of the popliteal tendon to the anatomical insertion of the popliteo-fibular ligament at the fibular head. The fibular insertion of the LCL is isometric to the anterior or antero-inferior 8-10 mm of the femoral insertion of the LCL.

The average follow-up period was 32 months (30-42 months). There was no varus knee instability in

full extension. At 30° of flexion two cases demonstrated a grade I varus instability.

A fibular head based isometric reconstruction is a reproducible and reliable technique for reconstruction of the posterolateral corner of the knee.

Keywords : knee ; graft fixation ; posterolateral corner ; semitendinosus tendon ; isometric reconstruction.

INTRODUCTION

Ruptures of the PLC are usually seen in injuries caused by contact sports, motor vehicle accidents, and falls. Isolated injuries of the posterolateral corner of the knee are rare and represent less than 2% of all ligamentous injuries of the knee. PLC injuries are generally part of a multiligamentous injury. Combined injury patterns have been demonstrated

- Shi-yuan Shi, MD, Professor.
- Xiao-Zhang Ying, MD, Orthopaedic surgeon.
- Qi Zheng, MD, Orthopaedic surgeon.

Department of Orthopaedics, Hangzhou Red Cross Hospital, Hangzhou city, Zhejiang province, China.

- Guo-Ping CAO, MD, Orthopaedic surgeon.

Department of Orthopaedics, Mountain Area Chinese Traditional Hospital, Hangzhou China.

Correspondence : Shi-yuan Shi. Department of Orthopaedics, Hangzhou Red Cross Hospital, 208 Huancheng East Rd, Hangzhou city, Zhejiang province, China, 310003.

E-mail : yingxiaozhang@gmail.com

© 2009, Acta Orthopædica Belgica.

in 43% to 80% of patients with posterolateral lesions (1,8,13). Missing the diagnosis of this rather rare injury may have devastating consequences. Particularly in case of an associated anterior and/or posterior cruciate ligament injury, the result can be a hyperextension varus deformity, and failure of a prior cruciate ligament reconstruction (5,11,17,25).

A variety of relevant surgical techniques have been explored with moderate results (13,15,22,32). Anatomical repair of the ruptured structures and determination of the dynamic isometric points on the femur and head of the fibula have increased our ability of stabilizing these knees (7,15,19,35,36).

PATIENTS AND METHODS

Patients

Eighteen patients (12 men and 6 women) treated from February 2001 to February 2005 were retrospectively reviewed. The average age was 39 years (ranging from 19 to 52 years). The time elapsed between injury and surgery ranged from 1.5 to 14 months. Three patients had a simple PLC injury ; 10 had a combined PLC - posterior cruciate ligament (PCL) injury .Two of them had undergone a reconstruction of the PCL 6.5 months earlier. Three patients had a PLC injury combined with an ACL injury and two had an associated injury of both ACL and PCL. Patients complained of knee pain, knee insecurity and abnormal gait. None of them had a varus malalignment on radiographs. The results of the varus stress test and the posterolateral rotation test, and the Lysholm score were recorded (except in the two patients who had their PCL reconstructed elsewhere). Magnetic resonance imaging (MRI) was used to identify a PLC injury. Final confirmation was obtained by examination under anaesthesia.

Anatomical study

Numerous descriptions of the PLC anatomy have been published (28,31,35). According to Seebacher *et al*, the PLC is structured in three layers (26). Layer 1 comprises the lateral fascia, iliotibial tract, and biceps tendon. Located within layer 1 and deep to the biceps femoris tendon lies the peroneal nerve. Layer 2 comprises the patellar retinaculum and patello-femoral ligament. Layer 3 comprises the knee capsule, LCL, popliteofibular ligament (PFL), popliteus tendon, arcuate ligament, and fabellofibular ligament. Layer 3 is commonly known

as the posterolateral corner (PLC). The function of the PLC is primarily to resist varus angulation and posterolateral tibial rotation at all flexion angles. The LCL is a consistent structure of the PLC (35). It starts from the lateral femoral condyle, 18.5 mm posterior to the popliteus tendon insertion on the anterolateral aspect of the proximal fibula. It is the primary restraint to varus angulation and the secondary restraint to combined external rotation and posterior displacement of the knee (6,9,27). The popliteus has both passive and dynamic functions, with the passive function performed by the PFL and the dynamic function as a controller of the "screw home mechanism" of the knee performed by the popliteus muscle belly (27). The PFL plays a pivotal role in PLC support. Anatomical studies have shown this ligament to be present in 93% to 100% of examined specimens (33,35). The anterior portion is 14.59 +/- 2.84 mm long, the posterior length is 7.75 +/- 2.00 mm, it is 8.56 +/- 1.52 mm wide and 2.93 +/- 0.44 mm thick (36).The PLT and popliteus muscle resist excessive external rotation of the tibia and assist to resist posterior displacement and varus angulation of the tibia (6,23).

We have studied the LCL during extension and flexion of the knee in 6 freshly frozen cadavers. It has been reported that the entire fibular head is relatively isometric to the lateral epicondyle throughout the range of knee motion (7,21). The distance of the anatomic femoral insertion of the LCL to the joint space ranged from 7.5 mm to 10.5 mm at 0°, 90° and 120° of flexion. We found that the fibular insertion of the LCL is isometric at all flexion angles to a point 8-10 mm anterior or antero-inferior to the femoral insertion of the LCL and the anatomic fibular insertion of the popliteofibular ligament (PFL) has an isometric relationship with the femoral insertion of the popliteal tendon (PLT). We confirmed Larson's findings that a suture running from the posterolateral tibia to the epicondylar insertion of the popliteus tendon is not isometric through knee flexion and extension (7,20,21).

Surgical Technique

Under anaesthesia and full relaxation, the knee was examined as a final evaluation of the ligament instability. With the patient supine, the lower limb was prepared and draped. The tourniquet was inflated for one hour, deflated for 15 minutes and then re-inflated if necessary.

When a combined lesion was diagnosed, arthroscopic reconstruction of the anterior cruciate ligament was first performed with a quadruple-stranded hamstring tendon. The posterior cruciate ligament was reconstructed with a

triple-stranded hamstring tendon. The grafts were fixed with a suture plate and button. The hamstring tendons of the affected side were used, and if necessary, additional hamstring tendon material was harvested at the unaffected side.

Next, a curvilinear incision was started halfway between Gerdy's tubercle and the fibular head with the knee flexed and was extended proximally on the lateral side of the thigh for approximately 8-10 cm (29). The iliotibial tract was split longitudinally and the biceps femoris tendon and muscle, fibular head, external femoral condyle, lateral collateral ligament LCL, popliteofibular ligament PFL and popliteus tendon were exposed. The common peroneal nerve was visualized using blunt dissection in the region of the fibular head and under the biceps muscle.

Transfibular tunnels were prepared for the reconstruction of both the LCL and PFL. A first 2 mm guide wire was directed medially and inferiorly, starting at the insertion of the LCL on the anterolateral fibular head. A second guide wire was directed laterally and inferiorly from the insertion of the PFL on the posterior tip of the fibular head (fig 1). The distance between the two distal tunnel exits was nearly 10 mm. The two guide wires were overdrilled with a 4.5 or 6.5 mm drill depending on the thickness of the prepared graft.

The individual LCL isometric femoral insertion was determined, using a suture fixed at the superior edge of the LCL tunnel and held 8-10 mm antero-inferiorly of the anatomical femoral LCL insertion, while the knee was mobilized from flexion to extension (fig 2 A, B). Once the isometric point was determined a 2 mm guide wire was drilled from this femoral isometric point in a medial direction to exit at the medial cortex. A 4.5-6.5 mm LCL femoral socket was then made by overdrilling the guide wire for an approximate depth of 30 to 35 mm. Then the popliteofibular tunnel was created at the femoral insertion of the popliteus tendon in the same way (fig 1). The anatomical femoral insertion point of the popliteus is isometric to the fibular insertion of the PFL (fig 2 C, D).

After harvesting, the semitendinosus tendon graft was fashioned to a minimum length of 20 cm, and duplicated with a weaved No. 1 absorbable suture, into a double bundle tendon graft of at least 10 cm length. A non absorbable No. 5 suture was used to thread the two ends of the graft into the femoral tunnels. The doubled graft was then passed through a sizing tube to reach the size of transfibular tunnels. The graft was passed through the transfibular tunnels and firmly tensioned with the anterior and posterior limbs of equal length. The posterior limb

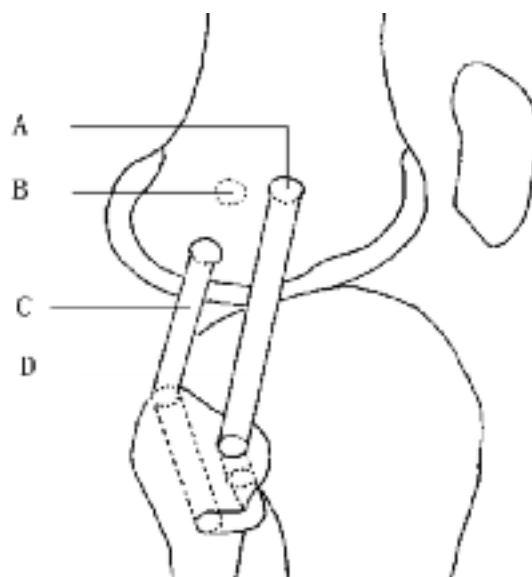


Fig. 1. — Posterolateral corner reconstruction (lateral view). A : isometric point of LCL ; B : anatomical insertion of LCL ; C : reconstruction of PFL ; D : reconstruction of the LCL.

of the graft was then threaded into the popliteal femoral socket using a looped passing suture directed to the medial cortex. The anterior limb of the graft was then pulled into the femoral LCL socket. With the knee in approximately 30° of flexion, internal rotation, and slight valgus, firm tension was applied medially to both limbs of the graft and both graft ends were secured into the sockets using a bioabsorbable interference screw or alternatively a No. 5 non absorbable suture was used with staples or button plates at the medial femoral condyle (mini-plates and endobuttons) (fig 3). The wound was closed after copious irrigation.

The knee was maintained in a brace in full extension for 4 weeks. Quadriceps isometric exercises were started immediately. Continuous passive motion was started at 24 hours postoperatively, with a range of 0° to 70° for the first 4 weeks. Closed-chain exercises were started at 4 weeks postoperatively and gradually progressed to open-chain exercises, being consistent with weight-bearing rules. Patients were protected from any varus or external rotation stress for at least 2 months. After 6 months sports and heavy labour were allowed, when the knee had sufficient strength and range of motion. At regular visits the varus laxity of the knee at 0° and 30° of flexion was recorded as well as the external rotation range of the knee at 30° and 90° of flexion.

Postoperative follow-up ranged from 30 to 42 months, averaging 32 months. At final follow-up also the

Table I. — Posterolateral rotation difference at 30° of flexion between affected and unaffected side and pre- and postoperative Lysholm knee score (Mean ± SD)

Injury type (number)	Posterolateral rotation test at 30° of flexion compared with the unaffected side		Lysholm knee score	
	preoperative	postoperative	preoperative	postoperative
PLC (3)	13.33° ± 2.89°	-1.67° ± 2.89°	74.00 ± 5.57	91.67 ± 3.34
PLC + PCL (8)	19.38° ± 2.70°	0.63° ± 1.77°	72.13 ± 3.09	89.63 ± 3.11
PLC + ACL (3)	15.00° ± 3.00°	0°	73.33 ± 3.06	91.67 ± 1.53
PLC + ACL + PCL (2)	27.50° ± 3.54°	6.50 ± 2.12°	40.00 ± 11.31	80.50 ± 6.36

Lysholm score was recorded in 16 of the 18 patients. Preoperative clinical data were unavailable in 2 patients, because they underwent reconstruction in another hospital 6.5 months before.

RESULTS

None of the 18 operated knees demonstrated varus laxity in extension and only 2 patients had a grade I varus laxity at 30° flexion (table I). Posterolateral rotation at 30° and 90° flexion was similar to the unaffected side in 14 patients, less than 5° in one patient and exceeded the value of the unaffected side by 5° to 8° in three patients. The Lysholm knee score was improved in all 16 preoperatively evaluated patients (table I).

DISCUSSION

The main mechanisms of a posterolateral corner injury are a blow to the anteromedial knee, contact or non-contact hyperextension, or an excessive non-contact varus force (18). It is important to inquire about numbness or tingling in the extremity or possible muscle weakness especially in ankle dorsiflexion and great toe extension, as 15% of posterolateral knee injuries have an associated common peroneal nerve injury (18). The main clinical symptoms of a PLC injury are lateral joint line pain, difficulties with lateral movements and cutting activities, a varus thrust gait pattern and knee insecurity. Physical examination includes the posterolateral drawer test, the reverse pivot shift test, the extension-recurvatum test, the posterolateral rotation test, the varus stress test and the posterior drawer test. The varus stress test and the posterolateral

rotation test provide a good assessment of the condition of the posterolateral corner of the knee (12). The varus stress test at 0° and 30° of knee flexion is performed by stabilising the thigh against the examination table while applying a varus force on the knee by grasping the foot or ankle (18). A positive varus stress test at 0° is often an indication of a serious posterolateral knee injury including the fibular collateral ligament, the meniscotibial portion of the mid-third lateral capsular ligament, the popliteus tendon, and possibly the superficial layer of the iliotibial band (18). The posterolateral rotation test, also called the dial test, is performed at 30° and 90° of knee flexion (9,10,30). The test can be performed either supine or prone. Our preference in the clinic is to perform the test prone with the knee flexed. The thigh is stabilised against the table and the foot externally rotated while the examiner records the amount of external rotation of the tibial tubercle in comparison to the unaffected knee. An increase of 10° to 15° of external rotation at 30° of flexion, compared with the unaffected side, indicates a posterolateral knee injury (3,9,10). The test is repeated in 90° of flexion. In an isolated posterolateral knee injury, external rotation will decrease at 90° compared with 30° due to the intact posterior cruciate ligament (10). If external rotation of the knee increases at 90°, a combined posterior cruciate ligament and posterolateral corner injury is suspected (10).

Posterolateral corner injuries can cause posterolateral instability of the knee and increase ACL / PCL loads during internal/external knee rotation. An undiagnosed posterolateral corner knee joint injury in combination with an anterior cruciate ligament or posterior cruciate ligament injury can lead

to the failure of a cruciate ligament reconstruction (26). To assess limb malalignment, long leg standing radiographs should be obtained in all cases. If the knee is in varus alignment, a staged treatment plan is preferred and an opening wedge valgisation osteotomy is performed in a first stage, otherwise the soft tissue graft may stretch out. The reconstruction of the posterolateral corner is planned 6 months after the osteotomy if the symptoms of posterolateral knee instability persist (5).

Several surgical techniques for treating posterolateral knee instability have been reported, but there is no consensus on the best technique to use. Disagreement persists concerning the part of the PLC that should be reconstructed, the insertion site and the sort of graft to be chosen : autograft or allograft (2,8,14). There is no consensus that the distal pole of the popliteus and PFT complex should be inserted to the fibula, tibia or both.

Hughston and Jacobson (13) developed the arcuate complex advancement technique, used in acute cases without sufficient tissue for reconstruction or in chronic reconstructions. The advancement of the popliteal and LCL insertion sites anterior to the center of rotation of the knee led to stretching. Veltri and Warren (31) developed a technique for augmentation of an attenuated tibial attachment of the popliteus tendon using a portion of the iliotibial band. For a PFL disruption, Veltri and Warren (32) described a technique whereby a central slip of the biceps femoris attachment to the fibular head is passed back under the biceps tendon, sutured to the posterior fibula, and secured to the lateral femoral condyle. Clancy (4) developed a biceps tenodesis technique, whereby the biceps tendon is advanced under a split in the iliotibial band and attached to the lateral femoral epicondyle, effectively recreating the LCL and restoring varus and external

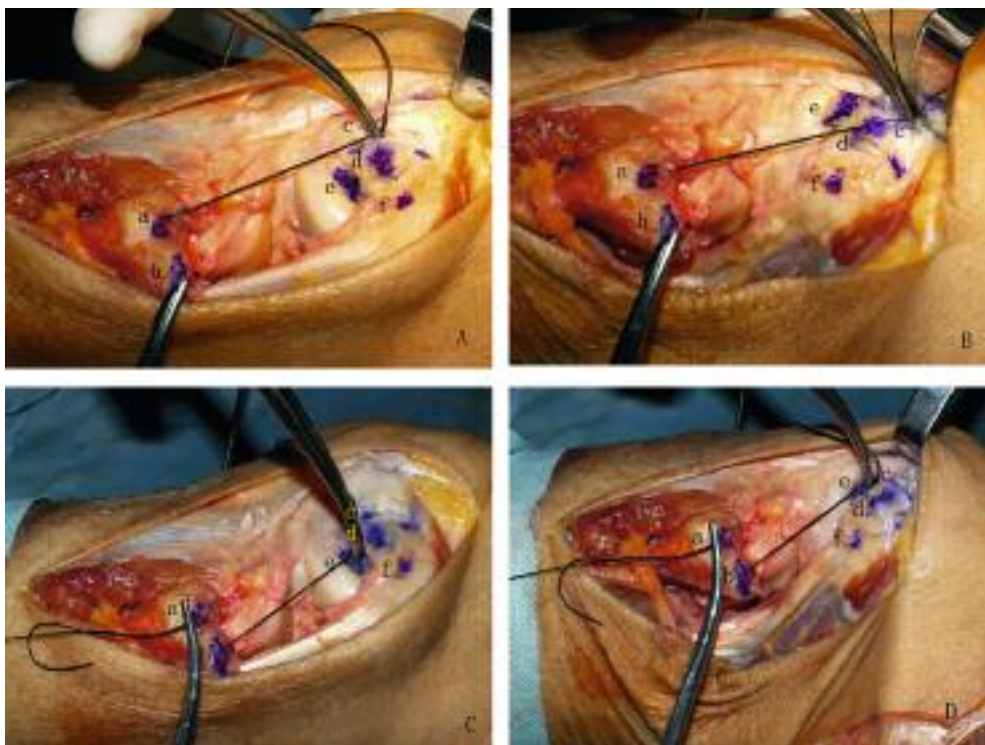


Fig. 2. — The fibular insertion of the LCL is isometric to the anterior or anterior-inferior 8-10 mm of the femoral insertion of LCL (A : extension ; B : flexion). The area from the fibular insertion of PFL to the femoral insertion of the PLT is isometric (C : extension ; D : flexion). a : the fibular insertion of the LCL ; b : the fibular insertion of the PFL ; c : the isometric point of LCL ; d : the femoral insertion of LCL ; e : the femoral insertion of PLT ; f : gastrocnemius.

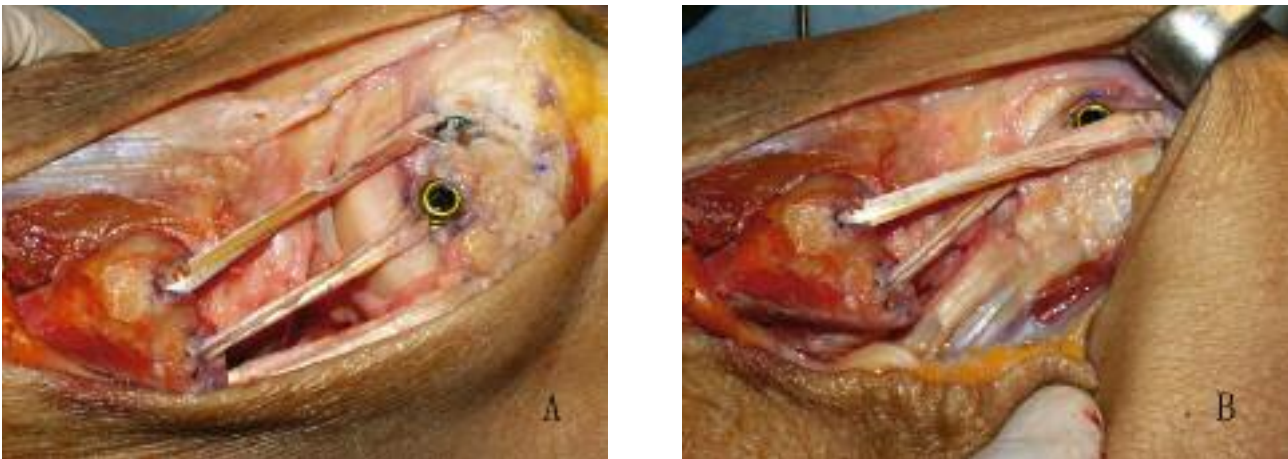


Fig. 3. — The isometric reconstruction of knee posterolateral corner with the double-bundle semitendinosus tendon fixed with the bioabsorbable interference screw (A : extension ; B flexion).

rotation laxity (34). The technique is not anatomic and does not anatomically reproduce the popliteal tendon or PFL. LaPrade *et al* (15) developed a 2 graft surgical technique to reconstruct the 3 major passive stabilising structures of the PLC (i.e. the LCL, popliteus, and PFL). In a biomechanical testing on cadaver knees with a simulated grade 3 PLC injury, the technique proved to restore passive stability in response to varus loading and external rotation torque. Latimer *et al* (22) used a bone-patellar tendon-bone allograft to reconstruct the LCL in knees with combined cruciate ligament and posterolateral instability. The fixation tunnels were drilled in the fibular head and at the isometric point on the femur, and interference screws were used for graft fixation. Noyes and Barber-Westin (24) reported on the use of allograft tissue (semitendinosus tendon) to restore fibular collateral ligament function with a 76% success rate.

Larson *et al* (7,20,21) used the tendon of semitendinosus as a graft for reconstruction. In case of an isolated posterolateral complex rupture with an intact lateral collateral ligament, they routed the semitendinosus graft from the femoral epicondyle to the posterior aspect of the fibula through a drill hole to its anterior aspect and fixed it to the tibia. However, if the lateral collateral ligament was also damaged then they would swing the same graft around from the anterior aspect of the fibula back to the femoral epicondyle in a figure of eight fashion

to reconstruct the lateral collateral ligament. Larson *et al* (7,20,21) evaluated the isometry of the ligaments on the lateral side of the knee. They demonstrated the fibular head is isometric to the epicondyle throughout knee range of motion. Their data showed that a graft taken from any position on the fibular head to the lateral epicondyle would provide restraint to varus stress at any position of knee flexion. The posterior aspect of the fibular head had a more isometric relationship with the anterior portion of the lateral epicondyle. Similarly, the anterior fibular head had an isometric relationship with the posterior aspect of the lateral epicondyle. We have also used Larson's technique to reconstruct both the LCL and PFL using semitendinosus in cadavers. We believe that the entire fibular head is relatively isometric to the lateral epicondyle throughout the range of knee motion, but our technique has several unique advantages. The PFL and LCL are reconstructed directly to their anatomic attachments on the fibular head (16,27,29). The double femoral tunnel reconstruction allows a closer reproduction of the normal anatomy and dynamic interactions of the posterolateral corner during knee motion. The fibular tunnels are created with a large bone bridge proximally, which may reduce the risk of fibular avulsion when compared to described techniques that drill transversely across the fibula. Finally, the fibular insertion of the LCL had a more isometric relationship with the

anterior or anterior-inferior 8-10 mm of the femoral insertion of LCL and the anatomic insertion of the popliteofibular ligament had a more isometric relationship with the femoral insertion of the popliteal tendon. The insertions of LCL, PFL and popliteal tendon on the fibula and femur are easily detected. So we determine the tunnel of isometric insertion more easily and precisely.

The purpose of reconstruction of the PLC is to control stability of the knee in flexion and extension and to resist excessive external rotation of the tibia and varus of the tibia. We think to this purpose reconstruction of the PLC must be anatomical and isometric. A fibula based isometric reconstruction is a reproducible, dependable technique for reconstruction of the posterolateral corner of the knee (18). It can be performed with a single autologous semitendinosus tendon. The risks of an allograft and weakening of the lateral ligamentous system using the biceps tendon or iliotibial tract can be avoided. It has been demonstrated to be isometric and thus provides support through the entire range of knee flexion. It provides stability equal to more involved techniques that require allografts and pass tissue to the posterolateral tibia.

A preliminary evaluation of the utilisation of this surgical procedure with a follow up of 2.5 to 3.5 years seems to show that it is a feasible option. A further evaluation after a longer follow-up is needed to allow for definitive conclusions.

REFERENCES

- Baker CL Jr, Norwood LA, Hughston JC.** Acute posterolateral rotatory instability of the knee. *J Bone Joint Surg* 1983 ; 65-A : 614-618.
- Bicos J, Arciero RA.** Novel approach for reconstruction of the posterolateral corner using a free tendon graft technique. *Sports Med Arthrosc* 2006 ; 14 : 28-36.
- Bleday RM, Fanelli GC, Giannotti BF, Edson CJ, Barrett TA.** Instrumented measurement of the posterolateral corner. *Arthroscopy* 1998 ; 14 : 489-494.
- Clancy WG.** Repair and reconstruction of the posterior cruciate ligament. In : Chapman M, (ed). *Operative Orthopedics*. JB Lippincott, Philadelphia, 1988, pp 1651-1665.
- Cooper JM, McAndrews PT, LaPrade RF.** Posterolateral corner injuries of the knee : anatomy, diagnosis, and treatment. *Sports Med Arthrosc* 2006 ; 14 : 213-220.
- Covey DC.** Injuries of the posterolateral corner of the knee. *J Bone Joint Surg* 2001 ; 83-A : 106-118.
- Fanelli GC, Larson RV.** Practical management of posterolateral instability of the knee. *Arthroscopy* 2002 ; 18 : 1-8.
- Frank JB, Youm T, Meislin RJ, Rokito AS.** Posterolateral corner injuries of the knee. *Bull NYU Hosp Jt Dis* 2007 ; 65 : 106-114.
- Gollehon DL, Torzilli PA, Warren RF.** The role of the posterolateral and cruciate ligaments in the stability of the human knee. A biomechanical study. *J Bone Joint Surg* 1987 ; 69-A : 233-242.
- Good ES, Stowers SF, Noyes FR.** Limits of movement in the human knee. Effect of sectioning the posterior cruciate ligament and posterolateral structures. *J Bone Joint Surg* 1988 ; 70-A : 88-97.
- Harner CD, Vogrin TM, Hoher J, Ma CB, Woo SL.** Biomechanical analysis of a posterior cruciate ligament reconstruction. Deficiency of the posterolateral structures as a cause of graft failure. *Am J Sports Med* 2000 ; 28 : 32-39.
- Hughston JC, Norwood LA.** The posterolateral drawer test and external rotation recurvatum test for posterolateral rotational instability of the knee. *Clin Orthop Relat Res* 1980 ; 147 : 82-87.
- Hughston JC, Jacobson KE.** Chronic posterolateral rotatory instability of the knee. *J Bone Joint Surg* 1985 ; 67-A : 351-359.
- Kawano CT, Bispo RZ Jr, de Oliveira MG, Soejima AT, Apostolopoulos SB.** Posterolateral knee instability : an alternative proposal for surgical treatment. *Clinics* 2007 ; 62 : 371-374.
- LaPrade RF, Johansen S, Wentorf FA et al.** An analysis of an anatomical posterolateral knee reconstruction : an in vitro biomechanical study and development of a surgical technique. *Am J Sports Med* 2004 ; 32 : 1405-1414.
- LaPrade RF, Ly TV, Wentorf FA, Engebretsen L.** The posterolateral attachments of the knee : a qualitative and quantitative morphologic analysis of the fibular collateral ligament, popliteus tendon, popliteofibular ligament, and lateral gastrocnemius tendon. *Am J Sports Med* 2003 ; 31 : 854-860.
- LaPrade RF, Muench C, Wentorf F, Lewis JL.** The effect of injury to the posterolateral structures of the knee on force in a posterior cruciate ligament graft : a biomechanical study. *Am J Sports Med* 2002 ; 30 : 233-238.
- LaPrade RF, Terry GC.** Injuries to the posterolateral aspect of the knee. Association of anatomic injury patterns with clinical instability. *Am J Sports Med* 1997 ; 25 : 433-438.
- Larsen MW, Moifar AR, Moorman CT 3rd.** Posterolateral corner reconstruction : fibular-based technique. *J Knee Surg* 2005 ; 18 : 163-166.
- Larson RV.** Isometry of the lateral collateral and popliteofibular ligaments and techniques for reconstruction using a free semitendinosus tendon graft. *Oper Tech Sports Med* 2001 ; 9 : 84-90.

21. **Larson RV, Tingstad E.** Lateral and posterolateral instability of the knee in adults. In : DeLee JC, Drez D, Miller M, eds. *Orthopaedic Sports Medicine : Principles and Practice*. 2nd ed. WB Saunders, Philadelphia, 2003, pp 1968-1994.
22. **Latimer HA, Tibone JE, ElAttrache NS, McMahon PJ.** Reconstruction of the lateral collateral ligament of the knee with patellar tendon allograft. Report of a new technique in combined ligament injuries. *Am J Sports Med* 1998 ; 26 : 656-662.
23. **Nielsen S, Helmig P.** The static stabilizing function of the popliteal tendon in the knee. An experimental study. *Arch Orthop Trauma Surg* 1986 ; 104 : 357-362.
24. **Noyes FR, Barber-Westin SD.** Surgical reconstruction of severe chronic posterolateral complex injuries of the knee using allograft tissues. *Am J Sports Med* 1995 ; 23 : 2-12.
25. **O'Brien SJ, Warren RF, Pavlov H, Panariello R, Wickiewicz TL.** Reconstruction of the chronically insufficient anterior cruciate ligament with the central third of the patellar ligament. *J Bone Joint Surg* 1991 ; 73-A : 278-286.
26. **Seebacher JR, Inglis AE, Marshall JL, Warren RF.** The structure of the posterolateral aspect of the knee. *J Bone Joint Surg* 1982 ; 64-A : 536-541.
27. **Shahane SA, Ibbotson C, Strachan R, Bickerstaff DR.** The popliteofibular ligament. An anatomical study of the posterolateral corner of the knee. *J Bone Joint Surg* 1999 ; 81-B : 636-642.
28. **Tardieu M, Lazennec JY, Christel P et al.** Normal and pathological MRI aspects of the posterolateral corner of the knee. *J Radiol* 1995 ; 76 : 605-609.
29. **Terry GC, LaPrade RF.** The posterolateral aspect of the knee. Anatomy and surgical approach. *Am J Sports Med* 1996 ; 24 : 732-739.
30. **Veltri DM, Deng XH, Torzilli PA, Warren RF, Maynard MJ.** The role of the cruciate and posterolateral ligaments in stability of the knee. A biomechanical study. *Am J Sports Med* 1995 ; 23 : 436-443.
31. **Veltri DM, Warren RF.** Anatomy, biomechanics, and physical findings in posterolateral knee instability. *Clin Sports Med* 1994 ; 13 : 599-614.
32. **Veltri DM, Warren RF.** Operative treatment of posterolateral instability of the knee. *Clin Sports Med* 1994 ; 13 : 615-627.
33. **Wadia FD, Pimple M, Gajjar SM, Narvekar AD.** An anatomic study of the popliteofibular ligament. *Int Orthop* 2003 ; 27 : 172-174.
34. **Wascher DC, Grauer JD, Markoff KL.** Biceps tendon tenodesis for posterolateral instability of the knee. An in vitro study. *Am J Sports Med* 1993 ; 21 : 400-406.
35. **Watanabe Y, Moriya H, Takahashi K et al.** Functional anatomy of the posterolateral structures of the knee. *Arthroscopy* 1993 ; 9 : 57-62.
36. **Xuan Yun, Yu Chun-Shut, Li Yun-Sheng.** Morphological features and functions of the popliteofibular ligament. *Chinese J Clin Anatomy* 2003 ; 21 : 150-151.

