



Glomus tumour of the deltoid muscle. A case report

Gunhan KARAKURUM, Ediz TUTAR, Lutfiye PIRBUDAK, Ayse MIZRAK

From Gaziantep University, Gaziantep, Turkey

Glomus tumours around the shoulder are very rare. To the best of our knowledge, seven cases have been reported to date. We present a case with special emphasis on its localization and time of appearance. Contrary to the related reports in the literature, the lesion was of short duration and it became symptomatic just 6 months before referral. Complete pain relief was achieved with surgical treatment.

Keywords: glomus tumour ; shoulder pain ; shoulder tumour.

INTRODUCTION

Glomus tumours are usually located in the finger tips, with the subungueal location being the most common. They are vascular in origin, and are characterized by pressure tenderness and cold hypersensitivity (1,5).

Glomus tumours around the shoulder are very rare : seven cases have been reported up to date (1). We present a further case, which developed in the deltoid muscle.

CASE REPORT

A 71-year-old male patient was referred with posterior shoulder pain. His symptoms had started 6 months previously, after he was involved in a traffic accident. After an unsuccessful trial of non-steroidal anti-inflammatory medication considering

soft tissue injury, he consulted at the Pain Clinic for further treatment. A mass was noted in the related area, magnetic resonance images were obtained and a lesion was detected in the posterior deltoid muscle.

The patient then consulted in orthopaedic surgery. He presented with a tender mass at his right posterior shoulder. The lesion was very sensitive to touch and cold exposure aggravated the symptoms. In his physical examination, a tender mobile mass of about 2.5×4 centimeters in size was palpable in the posterior deltoid. There was no sign of infection.

Laboratory examinations and radiographs were completely normal. Magnetic resonance imaging demonstrated a $3 \times 2 \times 2.5$ cm mass in the posterior deltoid muscle, which was hypointense in T1A

-
- Gunhan Karakurum, MD, Associate Professor.
Department of Orthopaedic Surgery.
 - Ediz Tutar, MD, Assistant Professor.
Department of Pathology.
 - Lutfiye Pırbudak, Associate Professor.
Department of Algology.
 - Ayse Mızrak, Assistant Professor.
Department of Anaesthesiology.
Gaziantep University, Faculty of Medicine, Gaziantep, Turkey.

Correspondence : Gunhan Karakurum, Department of Orthopaedic Surgery, Gaziantep University, Faculty of Medicine, 27310 Gaziantep, Turkey.

E-mail : gkarakurum@yahoo.com

© 2009, Acta Orthopædica Belgica.

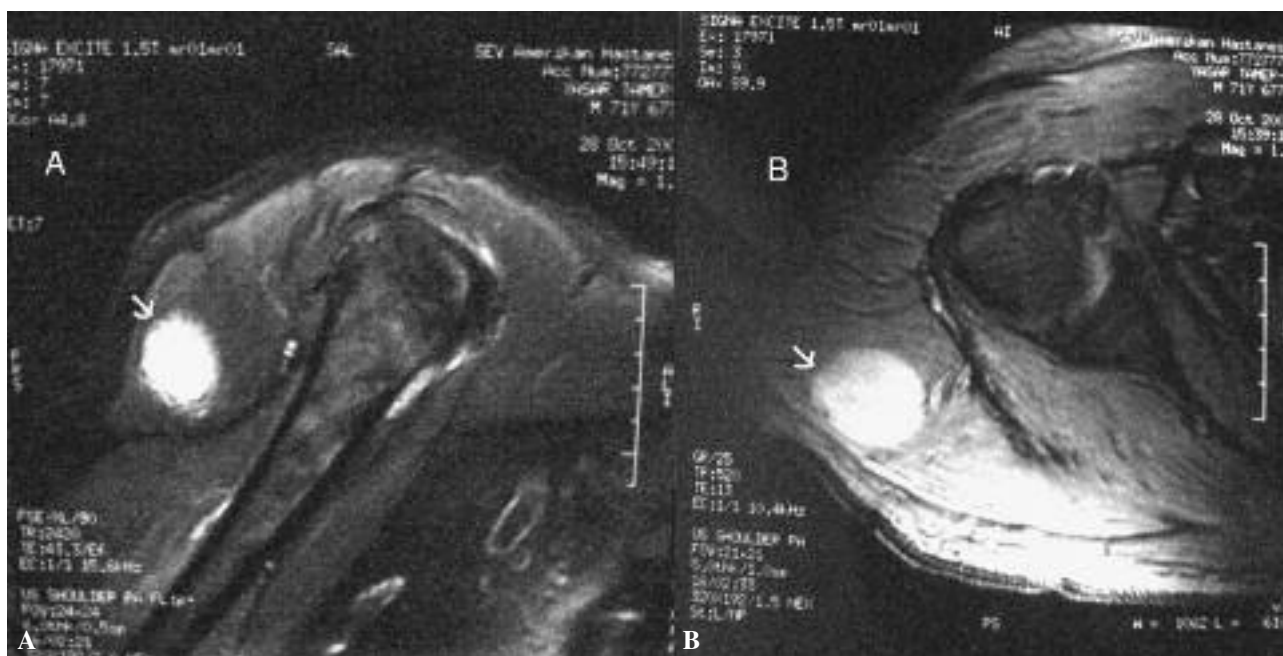


Fig. 1. — Magnetic resonance imaging of the lesion (arrow) in coronal (A) and transverse (B) planes

and hyperintense in the other sequences (fig 1A, 1B).

Considering the patient's age, a bone scintigraphy, lung CT and abdominopelvic ultrasonography were obtained in order to rule out any metastatic lesions. They were all clear and the patient was prepared for excisional biopsy after obtaining written informed consent.

Surgery

Under general anaesthesia and with the patient lying in the left decubitus position, a longitudinal incision was made directly over the palpable lesion in the posterior deltoid. After the fascia was opened, the lesion was removed with a cuff of muscle about 2 cm thick around it. It was made certain that the axillary nerve was not involved in the surgical field. The specimen was then transferred to the pathology department. The patient was completely free of pain at suture removal.

Pathology

A well-circumscribed encapsulated neoplasm composed of small, rounded cells with eosinophilic cytoplasm was examined. In focal areas, perivascular neoplastic cells were seen (fig 2A). There were no necrotic areas and no atypical mitoses (one mitosis per $50\times$ high magnification fields). Immunohistochemical studies were performed; the antibodies included were anti-cytokeratin, anti-smooth muscle actin, anti-pancytokeratin, anti-desmin, anti-S100 and anti-CD34. No staining for S-100, cytokeratin, desmin and CD34 protein was observed. The tumour cells were diffusely positive for smooth muscle actin (fig 2B). These features confirmed the diagnosis of glomus tumour.

DISCUSSION

Glomus tumours are well known for their digital localization and painful nature, and a delay in

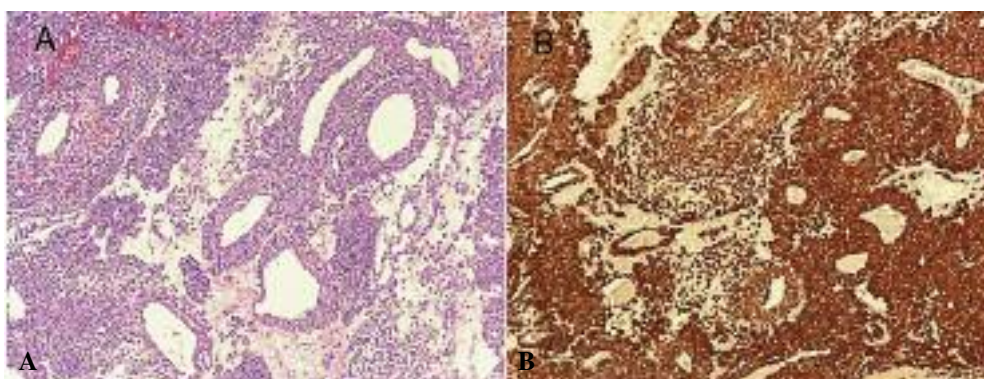


Fig. 2. — (A) Proliferation of neoplastic cells around vessels (haematoxylin and eosin, $\times 100$). (B) Diffuse expression of smooth muscle actin in glomus tumour (immunohistochemistry, $\times 100$).

diagnosis is almost warranted when localized elsewhere in the body. The cases reported in literature indicate that these tumours have gone undiagnosed clinically for many years until a biopsy was done to establish a histological diagnosis (1,3,4).

The current case, besides being the 8th case reported to our knowledge, has some points that merit discussion. First of all, the patient's history revealed that the lesion was relatively recent when compared with those in literature. The usual history is one of a painful area lasting for years, resistant to any modes of conservative treatment. In most of the other neoplastic conditions, it is not uncommon that a traumatic event makes the patient first notice an otherwise longstanding lesion. However, since glomus tumours are painful, this would not be the case in this patient.

A benign tumour would seldom, if ever, reach this size in a period of 6 months. Malignant degeneration might have been a meaningful explanation, if the pathologic examination had documented any atypical changes but the lesion was completely benign histologically. However, Folpe *et al* documented that glomus tumours which were deeply located and larger than 2 cm in size, especially with coexistence of atypical mitotic figures, should be considered as malignant (2). So, we preferred a wide margin for excision, considering this

report and the patient's history of recent growth of the tumour.

Localization in the deltoid muscle is another remarkable point of this case. Although a previous site in the deltoid tuberosity area has been reported, we are not aware of any case reported to be in the muscle substance (1).

Dramatic recovery of pain after surgery indicates that glomus tumours should be considered in the differential diagnosis of painful masses, so that early intervention may avoid unnecessary suffering for years.

REFERENCES

1. Boretto JG, Lazerges C, Coulet B, Baldet P, Chammas M. Calcified glomus tumor of the shoulder. A case report. *Chir Main* 2008 ; 27 : 183-186.
2. Folpe AL, Fanburg-Smith JC, Miettinen M, Weiss SW. Atypical and malignant glomus tumors. Analysis of 52 cases, with a proposal for the reclassification of glomus tumors. *Am J Surg Pathol* 2001 ; 25 : 1-12.
3. Ghaly RF, Ring AM. Supraclavicular glomus tumor, 20-year history of undiagnosed shoulder pain : a case report. *Pain* 1999 ; 83 : 379-382.
4. Tomak Y, Dabak N, Ozcan H. Extradigital glomus tumor of the triceps tendon as a cause of elbow pain : a case report. *J Shoulder Elbow Surg* 2003 ; 12 : 401-402.
5. Van Geertruyden J, Lorea P, Goldschmidt D *et al*. Glomus tumors of the hand. A retrospective study of 51 cases. *J Hand Surg* 1996 ; 21-B : 257-260.