



Traumatic talus extrusion : case reports and literature review

Nick VAN OPSTAL, Geoffroy VANDEPUTTE

From the Heilig Hart Hospital, Lier, Belgium

Total talar dislocation is a rare injury, which is usually open and with associated fractures. We report two cases of open anterolateral talar extrusions following high-energy traffic accidents. Both were treated with wound debridement, joint irrigation, closed reduction and external fixation. At 12 months follow-up, both patients had pain-free motion of the ankle without any signs of avascular necrosis or arthritis.

Keywords : open talar extrusion ; open reduction.

INTRODUCTION

Open total talar extrusion or dislocation of the talus from the tibiotalar, subtalar and talonavicular joints is a rare but well known severe injury. It requires a high-energy trauma and is often accompanied by fractures of the malleoli, talar body or neck. Complete dislocation without a concomitant fracture is extremely rare (31). It's true incidence is not known but is estimated at 0.06% of all dislocations (14) and 2% of all talar injuries (28). It was first reported by the German surgeon Fabricius Hildanus in 1680. The injury was treated by talectomy (11). The term 'aviator's astragalus', introduced by Anderson in 1919 for talar dislocations and fracture dislocations was taken up by Coltart in 1952 (1,4). The talus is predisposed to dislocation since it has no muscular attachment. Given the rarity of this type of injury, only case reports and small series can be found in literature. There is no established treatment protocol.

We report two cases of contaminated open talar extrusions with the second having an associated fracture through the talar neck (Hawkins III fracture dislocation).

CASE REPORTS

Case 1

A 33-year-old man driving his motorcycle at a high speed ran into the rear of a truck. He was brought to the emergency room complaining of a painful right shoulder and ankle. Movement of the shoulder was very limited and the outer contour was disrupted with a palpable acromial edge and humeral head, suggesting anterior dislocation. Examination of the right foot and ankle revealed a Gustilo-Anderson IIIa dislocation of the talus with a contaminated wound on the anterolateral side of the ankle, through which the talar cartilage could be seen. Neurovascular examination was normal. Radiographs confirmed the anterior glenohumeral

-
- Nick Van Opstal, MD, Orthopaedic Resident.
 - Geoffroy Vandeputte, MD, Orthopaedic Surgeon.
Department of Orthopaedic Surgery, Heilig Hart Hospital, Lier, Belgium.
- Correspondence : Nick Van Opstal, Aarschotsesteenweg 4 bus 5, 2230 Herselt, Belgium.
E-mail : nick.vanopstal@hotmail.com
© 2009, Acta Orthopædica Belgica.
-

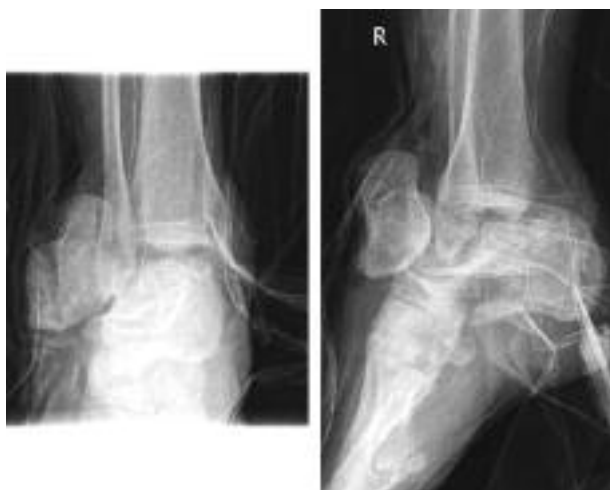

Fig. 1. — Case 1 : initial radiograph

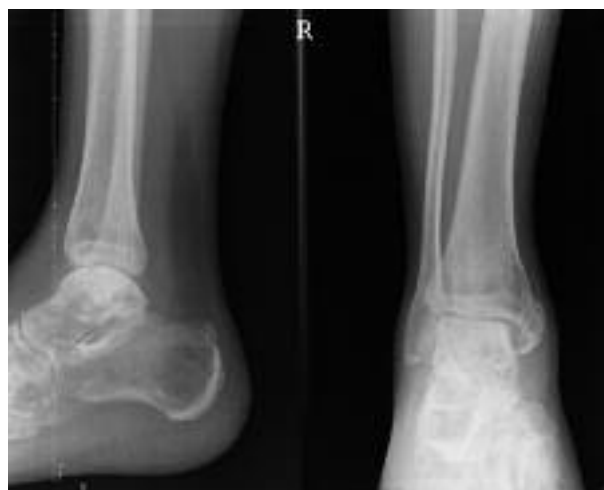

Fig. 2. — Case 1 : post-reduction image

dislocation. The talus was completely dislocated in an anterolateral direction with an associated undisplaced fracture of the medial malleolus (fig 1). After reduction of the shoulder, the patient was brought to the operating room. The wound was debrided and irrigated under general anaesthesia. Broad spectrum antibiotics were administered. All talar soft tissue attachments were found to be disrupted, except for a small strand from the talonavicular ligament. Traction was applied to the calcaneus using a Steinman pin and pressure was exerted over the talus in a posteromedial direction, thus reducing it. A tibiocalcaneal external fixator was applied to maintain the reduction. The wound was primarily closed. He was hospitalised for 5 days for neurovascular follow-up and intravenous antibiotic perfusion. After 8 weeks the external fixator was removed and range-of-motion exercises were started. Weight bearing was gradually allowed in a walking boot. Twelve months after the injury, he reported experiencing moderate pain during weight bearing. He was not able to walk without aid of crutches. He regained a painfree range of motion with a mild restriction of pro- and supination. Radiographs at 12 months follow-up showed complete union of the medial malleolar fracture, preservation of the tibiotalar joint space and no signs of avascular necrosis. Hawkins' sign was negative (fig 2).

Case 2

A 47-year-old man was brought to the emergency room after a car accident. Clinical examination revealed a contaminated wound on the anterolateral side of the right ankle through which the talar body was extruded (fig 3). Neither vascular impairment nor sensory loss was evident. Further there was swelling and tenderness of the left hand. Radiographs revealed a total dislocation of the talar body, with a concomitant fracture through the talar neck, leaving the talar head in place (fig 4). The injury was classified as a Hawkins type III fracture dislocation. Radiographs of the left hand showed an oblique diaphyseal 4th metacarpal fracture. After casting of the hand, he was taken to the operating room. Broad spectrum antibiotics were administered. Under general anaesthesia the wound and the joints were debrided and irrigated. Intra-operative examination revealed only few strands of soft tissue remaining attached to the talar body. The talar head was dislocated out of the talonavicular joint to allow irrigation. Using posteromedial pressure, holding the foot in extreme supination, the talar body was reduced. The wound was primarily closed. An external fixator was applied with 2 Steinmann pins through the distal tibia, one through the calcaneus, one in the medial cuneiform and one in the 5th metatarsal (fig 5). Postreduction

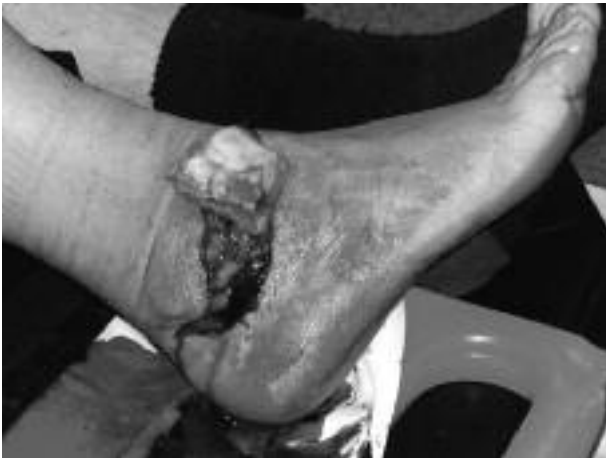

Fig. 3. — Case 2 : clinical picture

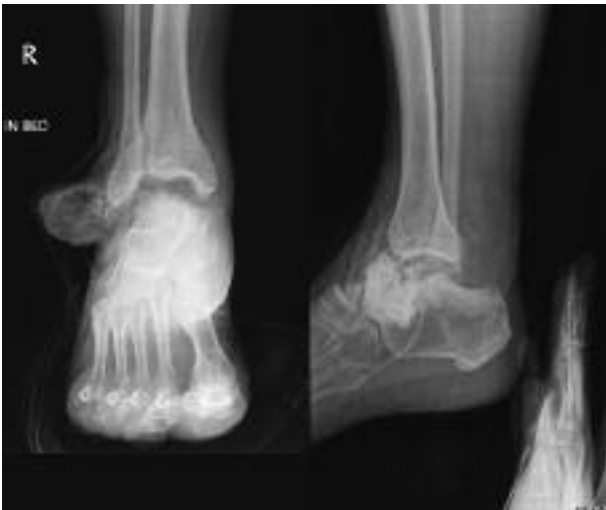


Fig. 4. — Case 2 : initial radiograph

radiographs showed complete relocation of the talar body within the ankle mortise and subtalar joint. The wound healed without problems. Antibiotics were further administered for 6 weeks. After 10 weeks, the external fixator was removed and weight bearing in a walking boot was allowed. Three weeks later, the cast was removed and gradual range-of-motion exercises were started. Four months after the injury, radiographs showed preservation of the joint line without signs of avascular necrosis. Hawkins sign was negative (fig 6). At this

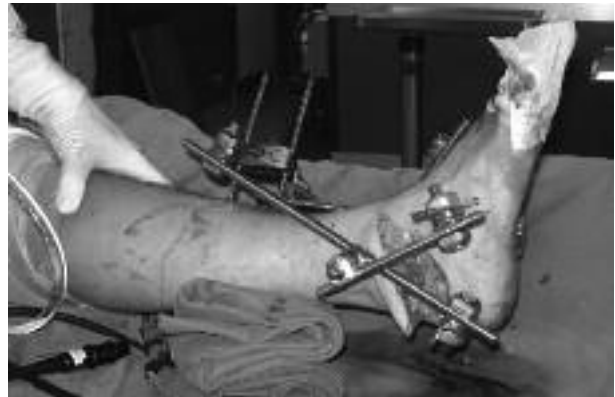

Fig. 5. — Case 2 : post-reduction and external fixation

time, a CT-scan was performed, which showed a non-union of the talar neck fracture and a fracture of the talar head, also non-consolidated. In spite of these radiographic findings, the clinical result was satisfying. There was a neutral alignment of the hindfoot, a painless motion of the ankle joint with neutral dorsiflexion and 30° of plantar flexion. He was able to walk small distances, even barefoot, without aid and without pain. For longer distances he used an ankle-foot orthosis. At latest follow-up, 14 months post-injury, range-of-motion improved to 40° of plantar flexion. He could walk longer distances without aid and without orthosis. An MRI-scan revealed no signs of avascular necrosis of the talar dome.

DISCUSSION

The talus transfers the body weight onto the hindfoot. It is the only bone in the lower extremity with no muscular attachment, making it vulnerable to dislocation (33). Open injuries account for 54% of all cases reported (12). Anterolateral dislocations are more common than anteromedial. Total talar dislocation is thought to be the endpoint of maximum pronation or supination injuries. Leitner described a 3-stage mechanism of anterolateral dislocation with medial subtalar dislocation being the first stage (14). Usually, a high-energy force is responsible, such as a fall from a height or a motor vehicle accident.

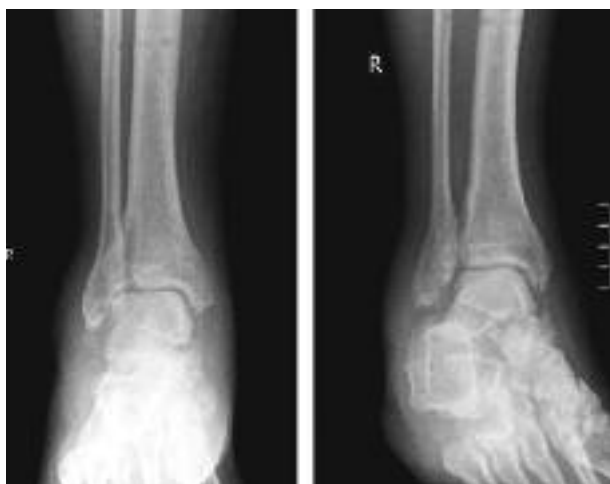


Fig. 6. — Case 2 : final radiographic appearance

Disruption of the vascular supply and contamination may lead to infection and avascular necrosis, the most common complications affecting the outcome. The fact that approximately 60% of the surface of the talus is covered with articular cartilage implies that only a limited surface is available for vascular perforation. The vascular anatomy of the talus has been well described by Gelberman and Mulfinger (7,20). The talar body receives its blood supply from the tarsal canal artery, a branch of the posterior tibial artery, from deltoid branches of the posterior tibial artery and from the sinus tarsi artery formed by the anterior tibial artery and perforating peroneal artery. The talar head receives its blood supply from branches of the dorsalis pedis and from branches from the tarsal sinus artery. There is a network of intraosseous anastomoses, which are complete in approximately 60% of cases (20). The occurrence of avascular necrosis is determined by the importance of these anastomoses and the amount of soft tissue damage. If strands of the superior talonavicular ligament remain attached, avascular necrosis may be avoided (21).

Few cases of total extrusion of the talus through the skin with disruption of all soft tissues have been reported (2,3,9,12,17,19,23).

Detenbeck and Kelly reported a very poor prognosis and believed that avascular necrosis almost

always accompanies a total dislocation (6). Infection developed even in closed injuries. However, Palomo-Traver, in a meta-analysis, reviewed all published cases until 1997 and after exclusion of the Detenbeck and Kelly series, he found a much better prognosis with no infections in closed injuries and 27.3% in open injuries, whereas the risk of avascular necrosis was 20% and 18.2% respectively (22). Serial radiographs should be performed for several months after fracture to monitor any increase in the density of the subchondral bone and the absence of a Hawkins sign (10), i.e. a subchondral radiolucent band in the dome of the talus, which does not develop in cases with avascular necrosis. Magnetic resonance imaging remains the most specific and sensitive test to detect early development of avascular necrosis. Posttraumatic arthritis may develop after several years (15,18). Collapse after revascularisation and osteochondral fractures may predispose the joint to posttraumatic arthritic changes.

Regarding the talar fracture dislocations, the Hawkins classification is the one most widely used today (11). It provides guidelines for treatment and is of prognostic value in the prediction of the development of avascular necrosis. In his series, type III fractures with dislocation of the subtalar and tibio-talar joints, non-union occurred in 11% and osteonecrosis developed in 91%. These injuries had a poorer functional outcome compared to type II fractures with subluxation of the talar body. Other authors reported similar results with higher percentages of avascular necrosis with increasing displacement (5,8,16,30,32). Posttraumatic arthritis often develops after comminution of the talar neck and with open fractures (32). Sanders *et al* found reconstructive surgery was necessary in 48% within 10 years after injury (26).

Given the rarity of talar dislocations, there is no established treatment protocol. Some authors recommend primary talectomy with tibiocalcaneal fusion, even in closed injuries (6).

Palomo-Traver suggested reduction except in cases with gross contamination or complete extrusion (22). Closed or open reduction has been mentioned as the treatment method of choice (13,24,25,29,31,33). Satisfying long-term results with good

clinical outcome and no signs of avascular necrosis or arthritis have been reported (24,27,31). If there is tendency to redislocation, K-wire transfixation may be performed. Most authors recommend an additional immobilization for six to eight weeks using a cast or external fixator (24,31,33).

In both of our cases, the wounds were contaminated with debris. Adequate debridement and irrigation was performed and broad spectrum antibiotics were administered. The talus could be reduced with traction applied to the calcaneus using a Steinmann pin. There was adequate soft tissue for wound closure. Since the wounds were contaminated we did not use K-wire transfixation but a tibio-calcaneal external fixator was applied. This allowed wound care postoperatively. Six months after the injury, both our patients experienced none of the major complications associated with total talar dislocation and fracture dislocation. On the long-term however, they may not escape posttraumatic arthritis, which may develop years after the injury. All patients who sustained an open total talar dislocation or open fracture dislocation should be informed of the uncertain and guarded long-term prognosis.

CONCLUSION

Our two cases support the concept of debridement, simple open reduction and external fixation of the ankle and hindfoot as treatment of open talus extrusions with contamination instead of more complex reconstructions.

REFERENCES

1. **Anderson HC.** *The Medical and Surgical Aspects of Aviation.* Oxford Medical Publications, London : 1919.
2. **Assal M, Stern R.** Total extrusion of the talus. A case report. *J Bone Joint Surg* 2004 ; 86-A : 2726-2731.
3. **Brewster NT, Maffulli N.** Reimplantation of the totally extruded talus. *J Orthop Trauma* 1997 ; 11 : 42-45.
4. **Coltart WD.** Aviator's astragalus. *J Bone Joint Surg* 1952 ; 34-B : 545-566.
5. **Comfort TH, Behrens F, Gaither DW.** Long-term results of displaced talar neck fractures. *Clin Orthop Relat Res* 1985 ; 199 : 81-87.
6. **Detenbeck LC, Kelly PJ.** Total dislocation of the talus. *J Bone Joint Surg* 1969 ; 51-A : 283-288.
7. **Gelberman RH, Mortensen WW.** The arterial anatomy of the talus. *Foot Ankle* 1983 ; 4 : 64-72.
8. **Grob D, Simpson LA, Weber BG.** Operative treatment of displaced talus fractures. *Clin Orthop* 1985 ; 199 : 88-96.
9. **Hardy MA, Chiunda S.** Open extrusion of the talus : a case report. *Podiatry Internet Journal* 2007 ; 2(5) : 2.
10. **Hawkins LG.** Fractures of the neck of the talus. *J Bone Joint Surg* 1970 ; 52-A : 991-1002.
11. **Hildanus FG.** Observatio LXVII (letter to Dr Philibertus). Observationum et curationum chirurgicarum centuriae. Obs 167, p.140, Beyer. *Francofurti ad Moenum* 1680.
12. **Hiraizumi Y, Hara T, Takahashi M.** Open total dislocation of the talus with extrusion (missing talus) : report of two cases. *Foot Ankle* 1992 ; 13 : 473-477.
13. **Krasin E, Goldworth M, Otremski I.** Complete open dislocation of the talus. *J Accid Emerg Med* 2000 ; 17 : 53-54.
14. **Leitner B.** The mechanism of total dislocation of the talus. *J Bone Joint Surg* 1955 ; 37-A : 89-95.
15. **Maffulli N, Francobandiera C, Lepoe L.** Total dislocation of the talus. *J Foot Surg* 1989 ; 28 : 208-212.
16. **Marti R.** [Talus fractures.] (in German). *Z Unfallmed Berufskr* 1971 ; 64 : 108.
17. **Mathieu A, Stern R.** Total extrusion of the talus. A case report. *J Bone Joint Surg* 2004 ; 86-A : 2726-2731.
18. **Mestdagh H, Duquenois H, Claisse PR, Sensey JJ, Gougeon F.** Long-term prognosis of tarsal dislocation. *Arch Orthop Trauma Surg* 1982 ; 99 : 153-159.
19. **Montoli C, De Pietri M, Barbieri S, D'Angelo F.** Total extrusion of the talus : a case report. *J Foot Ankle Surg* 2004 ; 43 : 321-326.
20. **Mulfinger GL, Trueta J.** The blood supply of the talus. *J Bone Joint Surg* 1970 ; 52-B : 160-167.
21. **Newcomb WJ, Brav EA.** Complete dislocation of the talus. *J Bone Joint Surg* 1948 ; 30-A : 872-874.
22. **Palomo-Traver JM, Cruz-Renovell E, Granell-Beltran V.** Open total talus dislocation : Case report and review of the literature. *J Orthop Trauma* 1997 ; 11 : 45-49.
23. **Papaionnou NA, Kokoroghiannis CG, Karachalios GG.** Traumatic extrusion of the talus (missing talus). *Foot Ankle Int* 1998 ; 19 : 590-93.
24. **Papanikolaou A, Siakantaris P, Maris J, Antoniou N.** Successful treatment of total talar dislocation with closed reduction : a case report. *Foot Ankle Surg* 2002 ; 8 : 245-248.
25. **Ritsem GH.** Total talar dislocation. *J Trauma* 1988 ; 28 : 692-94.
26. **Sanders DW, Busam M, Hattwick E.** Functional outcomes following displaced talar neck fractures. *J Orthop Trauma* 2004 ; 18 : 265-270.
27. **Schiffer G, Jubel A, Elsner A, Andermahr J.** Complete talar dislocation without late osteonecrosis : clinical case and anatomic study. *J Foot Ankle Surg* 2007 ; 46 : 120-123.

28. **Schuind F, Andrianne Y, Burny F.** [Fractures and dislocations of the talus.] (in French). *Acta Orthop Belg* 1983 ; 49 : 652-689.
29. **Sharma S, Mainds CC.** Closed total talar dislocation – a case report. *Grand Rounds* 2002 ; 2 : 29-31.
30. **Szyszkowitz R, Reschauer R, Seggl W.** Eighty-five talus fractures treated by ORIF with five to eight years of follow-up study of 69 patients. *Clin Orthop Relat Res* 1985 ; 199 : 97-107.
31. **Taymaz A, Gunal I.** Complete dislocation of the talus unaccompanied by fracture. *J Foot Ankle Surg* 2005 ; 44 : 156-158.
32. **Vallier HA, Nork SE, Barei DP.** Talar neck fractures : results and outcomes. *J Bone Joint Surg* 2004 ; 86-A : 1616-1624.
33. **Wagner R, Blattert TR, Weckbach A.** Talar dislocations. *Injury* 2004 ; 35 : 36-45.