



Paediatric hip fractures : A systematic review of incidence, treatment options and complications

Richard BIMMEL, Alex BAKKER, Ben BOSMA, Joseph MICHELSEN

From Algemeen Ziekenhuis Monica, Deurne, Belgium

Hip fractures in children are rare ; when not properly treated, they can be disastrous for the growing child. We present the incidence, causes, treatment options and possible complications.

A good understanding of classification and treatment options is of great importance to minimize complications. A clear evidence- based algorithm, however, cannot be proposed. Further multi-centre studies should be performed to come to such a consensus on the treatment of pediatric hip fractures.

Keywords : hip fracture ; children ; treatment ; outcome.

INTRODUCTION

Hip fractures in children are rare ; they account for less than one percent of all paediatric fractures. The incidence of paediatric hip fractures is highest in children above the age of eleven. The most common cause is a high-energy trauma such as motor vehicle accidents and falls from a height. There is a thirty percent chance of associated injuries (12). Fractures can also occur spontaneously, after low-energy trauma or through proximal femoral bone cysts as described by Roposh *et al* and Vigler *et al* (34,43). Hip fractures can be part of a “battered child syndrome”. A very rare cause is a stress fracture of the neck of the femur (33). Hormone based Slipped Upper Femoral Epiphysis (SUFE) has also been described incidentally as a cause of hip fractures (3). Standard radiographs of hip and pelvis are usually sufficient to make the diagnosis. If radio-

graphs are not conclusive CAT scan, MRI or bone scan can be used.

Hip fractures can have important implications on hip development. The vascular anatomy of the proximal femoral physis is therefore of great importance when dealing with these fractures. Complications are avascular necrosis (AVN), non-union, malunion and premature closure of the proximal femoral physis leading to leg length discrepancy.

Treatment related complications are infection, skin problems and chondrolysis.

To come to a better understanding of this type of fracture and its implications, a classification system was proposed. The classification by Delbet (*in 3*) is the most frequently used. This review article will give an overview of the literature on treatment and complications of hip fractures in children.

■ Richard Bimmel, MD, Consultant orthopaedic surgeon.
Ziekenhuis Nij Smellinghe, Drachten, The Netherlands.

■ Ben Bosma, Medical student, UMCG.
Groningen, The Netherlands.

■ Alex Bakker, MD, Specialist registrar emergency medicine.
■ Joseph Michielsen, MD, Consultant orthopaedic surgeon,
Head of the department of orthopaedic surgery.
Algemeen Ziekenhuis Monica, Deurne, Belgium.

Correspondence : Richard Bimmel, MD, Nij Smellinghe,
Compagnonsplein 1, 9202 NN Drachten, The Netherlands.

E-mail : r.bimmel@nijsmellinghe.nl

© 2010, Acta Orthopædica Belgica.

VASCULARISATION

Vascularisation of the femoral head in children differs from the blood supply to the adult hip. This makes the femoral head particularly vulnerable to trauma to the proximal femur. The blood supply to the femoral head has been studied extensively and described (37,40,41,42). Post mortem injection and micro angiographic studies have provided us with insights as to how the vascular anatomy changes with age. The vessels from the ligamentum teres contribute little to the vascularisation of the femoral head until the age of eight years. In adults, their contribution is around twenty percent and further decreases with age.

At birth the branches of the medial and lateral femoral circumflex arteries traverse the femoral neck and predominantly supply the femoral head. With increasing size of the cartilaginous physis, these vessels diminish gradually and this blood supply is practically non-existing from the age of four. The lateral epiphyseal vessels predominate and the femoral head is primarily irrigated by these vessels, which bypass the physeal barrier (27).

Two branches arise from the lateral circumflex artery, the postero-superior (PS) and the postero-inferior (PI) branch. The medial circumflex artery anastomoses with the posterosuperior branch of the lateral circumflex artery. At the intertrochanteric groove the medial circumflex artery ends into a retinacular system and enters the capsule. This vascular web ascends along the neck of the femur to irrigate the head of the femur. An anterior capsulotomy will therefore not damage the blood supply of the femoral head when stopped at this level. Damage to the notch or lateral ascending arteries however, will leave the head avascular. From the age of three to four, the lateral postero-superior vessels appear to predominate and supply the entire antero-lateral portion of the capital femoral epiphysis (9). The postero-inferior and postero-superior vessels persist throughout life and supply the femoral head. The multiple small vessels of the young child join to form a limited number of larger vessels ; as a result, damage to a single vessel may lead to AVN in the older child. From the age of fourteen to seventeen the physis closes and the epiphyseal and metaphy-

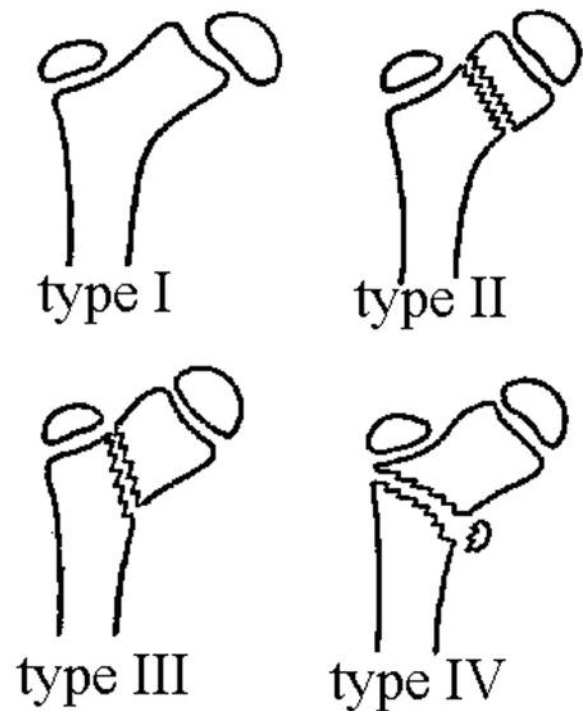


Fig. 1. — Delbet Classification

seal vessels join to supply the femoral head and neck. In adults there is one system that irrigates the entire head of the femur.

DELBET'S CLASSIFICATION

Delbet's classification (fig 1) was described in 1928 and popularized in 1929 by Colonna (10). It describes four different types of proximal femoral fractures in children. It is widely used to classify hip fractures in children.

Type I

A type I fracture is a transepiphyseal fracture with or without dislocation of the femoral head. Dislocation occurs in about fifty percent of these cases. This type of fracture is the least common. In a review study by Canale and Bourland (8) it represented a total of 8% of 471 fractures. Conversely, in the infant, type I fractures were more common than type II, III, and IV. Diagnosis of a type I fracture

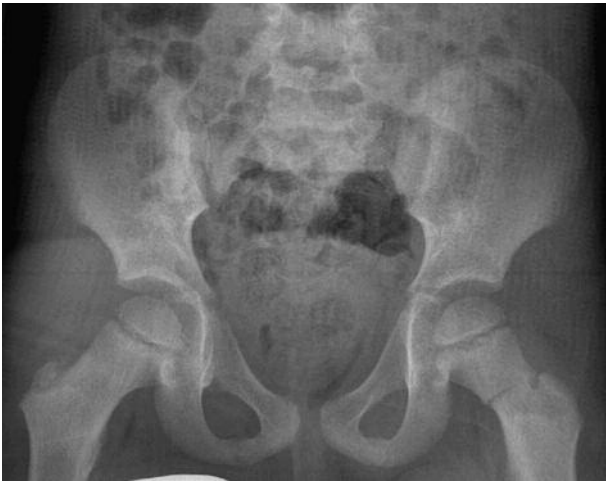

Fig. 2. — Type II fracture left, AP view

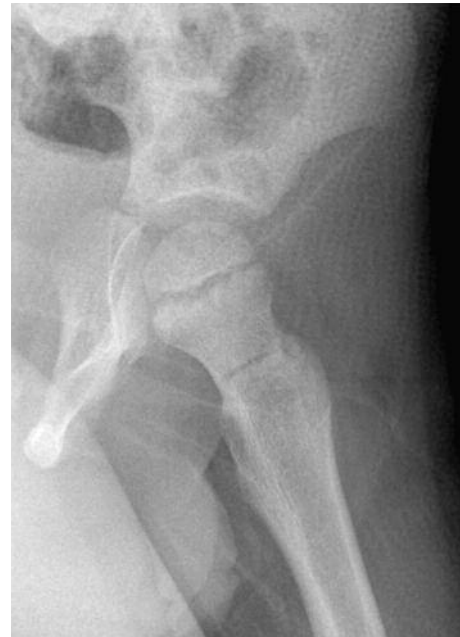

Fig. 3. — Type II fracture. Lateral view

may be difficult in an infant, as the femoral head is not yet ossified. Clinically, the limb is usually positioned in flexion, abduction and internal rotation. The differential diagnosis includes developmental dislocation of the hip and septic arthritis of the hip joint. An arthrogram and MRI may sometimes be necessary. Type I fractures have also been described following closed reduction of a traumatic dislocation of the hip (14).

Type II

Type II is described as a transcervical fracture (fig 2, 3). This type represents the largest group of fractures, about 45% (8). Transcervical fractures are mostly due to a high-velocity accident involving direct impact. The incidence of AVN after transcervical fracture varies from 16 to 78% (8,25,32). The chance of AVN occurring is directly related to the initial displacement.

Type III

Type III in Delbet's classification presents as a cervicotrochanteric fracture, it is found in approximately 25 to 34% (19,25,32). One quarter of type III fractures is said to develop AVN (12,21,22,32).

Type IV

Type IV is an intertrochanteric hip fracture. In Canale and Bourland's review, it represented 12%. This fracture type has been reported to have the most favourable outcome (8,29,32).

TREATMENT OPTIONS

The low incidence of these injuries may be the reason why a universal treatment protocol has not yet become available. After the first description by Cromwell (11) in 1885, only a few reports were published until half of the 20th century, and all these patients were treated non-operatively (28,44,45).

Until the 1970's it was recommended that all non- or minimally displaced fractures should be treated with cast immobilization. Closed reduction and a plaster spica cast were recommended for displaced transcervical and cervico-trochanteric fractures. A recently published paper shows that fair results still can be obtained with conservative

treatment ; however less adverse effects are noted when operative treatment is used (25).

Type I

Fixation with smooth pins is indicated for fractures without displacement (35). Conservative management with plaster spica cast however remains an option. In two papers by Feigenberg *et al* (13) and Forlin *et al* (16), results of conservative treatment with skin traction or hip spica were fair in most patients. No comparison was made with operative treatment.

For hip fractures with dislocation of the femoral head, a gentle closed reduction can be attempted after which the head is fixed with a smooth pin. If closed reduction fails, an open reduction with pin fixation is recommended. As described previously, an anterior approach to the hip is best because it spares the blood supply to the femoral head. An additional benefit of open reduction is that the hip joint is decompressed (6,36). However, there is still no consensus that urgent decompression of the joint reduces the rate of complications, such as AVN.

Type II and III

Type II fractures should be treated with anatomical reduction and stable fixation to minimize the risk of late adverse effects (17,22). In type II fractures without much displacement, good to fair results have also been reported with conservative treatment (13,16). In fractures with substantial displacement results are poor with conservative management. There is a high incidence of AVN, coxa vara or secondary displacement (7,18,36). Canale and Bourland (8) reported a decrease in complications in all, undisplaced or displaced, type II fractures, after reduction and internal fixation by pins or screws. Heiser (18) stated that if it is necessary to bridge the physis, it is preferable to do so with smooth Kirschner wires to prevent premature closure of the physis. An anterior capsulotomy could reduce the occurrence of AVN in these fractures. When an open reduction has to be performed, the approach according to Watson-Jones is to be

preferred. The treatment options for type III are the same as for type II.

Type IV

We will not discuss type IV fractures because of the favourable outcome related to their inter- and sub- subtrochanteric location.

COMPLICATIONS

Avascular Necrosis

Avascular necrosis (AVN) is the most frequent and serious complication of proximal femoral fractures in children. It has been reported to be the primary cause of poor results. The chance of AVN occurring after a fracture is directly related to the amount of initial displacement, or the displacement as a result of the reduction attempts. Most papers report an incidence of about 17% of AVN, however AVN has been described in up to 59% of all paediatric hip fractures (39). As discussed above the compromise to the blood supply is of eminent importance and can occur either by disruption or kinking of the vessels. Besides displacement of the fracture (2), other risk factors for AVN include a type I or displaced type II fracture and age of more than ten years (25). However there are authors who regard the type of treatment of greater importance than the type of fracture (38). Delay in fracture treatment has also been postulated as a risk factor for AVN (5). Early reduction and safe fixation are the most important factors in reducing the risk of AVN (15). The adjunct of decompression of the hip joint has not yet been proven to reduce the incidence of AVN (1).

The first signs of AVN can be pain and limitation of range of motion. It can be seen as early as one and a half months after the trauma. Repeat radiographs and bone scan can result in the diagnosis. Ogden (27) recommends repeat bone scan at three and twelve months. Ratliff described three types of AVN after a hip fracture (31). In type I the entire femoral head is involved. Type II involves only a portion of the head. When there is a zone of AVN from the fracture line to the physis it is described as

type III. The Ratcliff classification type I has the worst prognosis.

The consequences of AVN can be devastating and further treatment may be needed. If internal fixation is in place when AVN develops it should be removed after union of the fracture. Remodeling of the femoral head may occur, especially in the younger child, but may take up to five years (20). Maeda *et al* (23) proposed a non weight-bearing regime for more than one year to avoid severe collapse. It may be necessary to perform a rotational osteotomy or even a total hip replacement.

Mal-union

Mal-union may occur after conservative or invasive treatment of a proximal femoral fracture. Two types have been described, coxa vara and coxa valga. Coxa vara occurs in 20 to 30% of all paediatric hip fractures. The incidence of coxa vara decreases when internal fixation is performed in fractures with displacement (22). Coxa vara may develop secondary to AVN, non-union and premature physeal closure, or a combination of all above. Severe coxa vara shortens the limb. It causes abductor weakness and may result in early development of osteoarthritis of the hip. Remodeling of the hip can be expected in the very young child. If the neck-shaft angle is 110° or less, a subtrochanteric valgus osteotomy may be considered as suggested by Canale and Bourland (8) and Morrissy (26). A very rare type of malunion is coxa valga. Coxa valga has been described in one study (24) in which the cause of the mal-union was iatrogenic.

Non-union

Non-union may occur in hip fractures in children. It has been reported in 6 to 10% of all paediatric hip fractures (4,15,16,35). Primary cause of non-union is failure to obtain, or maintain, anatomical reduction. Most non-unions occur in displaced fractures.

In a series of 16 fractures in 16 children published by Forlin *et al* (16), seven non-unions were described, six where in displaced type II fractures. Four were treated with open reduction and internal fixation, two were treated with closed reduction and

internal fixation and one was treated with traction and an immobilization cast. Non-union should be treated operatively, unlike AVN, as soon as possible. Valgus osteotomy usually leads to secondary union. Bone grafts can be used if necessary. In an attempt to minimize the occurrence of AVN and non-union Qi *et al* used a vascularised greater trochanter periosteal flap transposition (30). They achieved excellent to good union rates in 87%. They state that this method may accelerate union and may decrease AVN.

Premature closure of the proximal femoral physis

Premature closure of the proximal femoral physis has been reported in 5 to 65% of all paediatric hip fractures. The prevalence increases when the physis is bridged by osteosynthetic material. It also increases in the presence of AVN. When crossing the physis with internal fixation is necessary, pins are preferred to cannulated screws. A minimal number of pins should be used. Beaty (2) however stated that it is more important to have stable fixation than sparing the physis. Premature closure of the physis leads to leg length discrepancy. Contralateral epiphysiodesis may be necessary when leg length difference becomes more than 2.5 centimeters.

CONCLUSION

Paediatric hip fracture is not a large burden in the orthopaedic traumatology. The incidence is one percent of all paediatric fractures. An orthopaedic surgeon will however be, most likely, confronted in his/her career with a paediatric hip fracture. It is important to know how to treat these fractures. Classifying these fractures according to Delbet indicates the possible treatment options. The potential adverse events following these fractures are of great implication to the growing child. Undisplaced fractures can be treated conservatively. However, Delbet's type 2 and 3 fractures are known to have greater risk for secondary displacement ; fixation of these fractures gives a more predictable result. In general the advice should be to reduce and stabilize

all displaced hip fractures, closed or open. Gentle closed reduction should be tried first, with a maximum of one or two reduction attempts. It is important to prevent greater displacement with risk of greater damage to the blood supply. After reduction, stable fixation is important. Stability is more important than sparing the growth plate. The most dangerous and frequent complication is avascular necrosis. Frequent follow-up clinically, radiographically and with repeated bone scanning is recommended. Another less frequent complication is non-union. A vascularised greater trochanter periosteal flap transposition may be a solution. There is however no large follow-up study to make this treatment the standard of care at this stage. Follow-up until the child has reached skeletal maturity is necessary to determine if mal-union or leg length discrepancy is present. A prospective randomized multicenter study may give answers to the question whether standard decompression of the hip joint can lower the risk of avascular necrosis. It would also be interesting to have a standardised treatment protocol for hip fractures in children, mainly because of their low frequency and their high rate of complications.

REFERENCES

- 1. Bagatur AE, Zorer G.** Complications associated with surgically treated hip fractures in children. *J Pediatr Orthop* 2002 ; 11-B : 219-228.
- 2. Beaty JH.** Fractures of the hip in children. *Orthop Clin North Am* 2006 ; 37 : 223-232, vii. Review.
- 3. Blasier RD.** Fractures of the hip. In : Beaty JH, Kasser JR (eds). *Rockwood and Wilkin's Fractures in Children*. Lippincott Williams & Wilkins, Philadelphia, 5th ed, 2001.
- 4. Boitzy A.** Fractures of the proximal femur. In : Boitzy A (ed). *Treatment of Fractures in Children and Adolescents*. Springer, New York, 1971, p 254-267.
- 5. Bombaci H, Centel T, Babay A, Turkmen IM.** [Evaluation of complications of femoral neck fractures in children operated on at least 24 hours after initial trauma.] (in Turkish). *Acta Orthop Traumatol Turc* 2006 ; 40 : 6-14.
- 6. Calandruccio RA, Anderson WE 3rd.** Post-fracture avascular necrosis of the femoral head : correlation of experimental and clinical studies. *Clin Orthop Relat Res* 1980 ; 152 : 49-84.
- 7. Canale ST.** Fractures and dislocations. In : Canale ST, Beaty JH (eds). *Operative Pediatric Orthopedic*, Mosby, St.-Louis 1991, pp 885-899.
- 8. Canale ST, Bourland WL.** Fracture of the neck in the intertrochanteric region of the femur in children. *J Bone Joint Surg* 1977 ; 59-A : 431-443.
- 9. Chung SMD.** The arterial supply of the developing proximal end of the human femur in childhood. A report of six cases. *Ann Surg* 1928 ; 88 : 902-907.
- 10. Colonna PC.** Fractures of the neck of the femur in children. *Am J Surgery* 1929 ; 6 : 793-797.
- 11. Cromwell BM.** A case of intracapsular fracture of the neck of the femur in a young subject. *NC Med J* 1885 ; 15 : 309.
- 12. Davidson BL.** Hip fractures in children : a long-term follow up study. *J Pediatr Orthop* 1992 ; 12 : 355-358.
- 13. Feigenberg Z, Pauker M, Levy M, Seelenfreund M, Fried A.** Fractures of the femoral neck in childhood. Results of conservative treatment. *J Trauma* 1977 ; 17 : 937-942.
- 14. Fiddian NJ, Grace DL.** Traumatic dislocation of the hip in adolescence with separation of the capital epiphysis. Two case reports. *J Bone Joint Surg* 1983 ; 65-B : 148-149.
- 15. Flynn JM, Wong KL, Yeh GL, Meyer JS, Davidson RS.** Displaced fractures of the hip in children : management by early operation and immobilisation in a hip spica cast. *J Bone Joint Surg* 2002 ; 84-B : 108-112.
- 16. Forlin E, Guille JT, Kumar SJ, Rhee KJ.** Non-operative treatment of pediatric hip fractures. *J Pediatr Orthop* 1992 ; 12 : 503-509.
- 17. Forster NA, Ramseier LE, Exner GU.** Undisplaced femoral neck fractures in children have a high risk of secondary displacement. *J Pediatr Orthop* 2006 ; 15-B : 131-133.
- 18. Heiser JM.** Fractures of the hip in children : a review of forty cases. *Clin Orthop Relat Res* 1980 ; 149 : 177-184.
- 19. Hoekstra HJ.** [Fractures of the proximal part of the femur in children and adolescents.] (in Dutch). *Ned Tijdschrift voor Geneeskunde* 1988 ; 21 ; 132 : 401-404.
- 20. Hughes LO, Beaty JH.** fractures of the head and neck of the femur in children. *J Bone Joint Surg* 1994 ; 76-A : 283-292.
- 21. Ingram AJ.** Fractures of the hip in children. treatment and results. *J Bone Joint Surg* 1953 ; 35-A : 867-887.
- 22. Lam S.** Fractures of the neck of the femur in children. *J Bone Joint Surg* 1971 ; 53-A : 1165-1179.
- 23. Maeda S, Kita A, Fujii G et al.** Avascular necrosis associated with fractures of the femoral neck in children : histological evaluation of core biopsies of the femoral head. *Injury* 2003 ; 34 : 283-286.
- 24. Mirdad T.** Fractures of the neck of femur in children : an experience at the Aseer Central Hospital, Abha, Saudi-Arabia. *Injury* 2002 ; 33 : 823-827.
- 25. Moon ES, Mehlman CT.** Risk factors for avascular necrosis after femoral neck fractures in children : 25 Cincinnati cases and meta-analysis of 360 cases. *J Orthop Trauma* 2006 ; 20 : 323-329.

26. **Morrissy RT.** Fractures of the hip in childhood. *Instructional course lectures, AAOS* 1984 ; 33 : 229-241.
27. **Ogden JA.** Changing patterns of the proximal femoral vascularity. *J Bone Joint Surg* 1974 ; 56-A : 941-950.
28. **Pape HC MD, Krettek C, Friedrich A et al.** Long-term outcome in children with fractures of the proximal femur after high-energy trauma. *J Trauma-Injury Infection & Critical Care* 1999 ; 46 : 58-64.
29. **Pförringer W.** Fractures of the hip in children and adolescents. *Acta Orthop Scand* 1980 ; 51 : 91-108.
30. **Qi B, Yu A, Zhang Gi et al.** The treatment of displaced femoral neck fractures with vascularized great trochanter periosteal flap transposition in children. *Microsurgery* 2008 ; 28 : 21-24.
31. **Ratliff AHC.** Complications after fractures of the femoral neck in children and their treatment. *J Bone Joint Surg* 1970 ; 52-B : 175.
32. **Ratliff AHC.** Fractures of the neck of the femur in children. *J Bone Joint Surg* 1962 ; 44-B : 528-542.
33. **Román M, Recio R, Moreno JC, Fuentes S, Collantes F.** Stress fracture of the femoral neck in a child. Case report and review of the literature. *Acta Orthop Belg* 2001 ; 67 : 286-289.
34. **Roposch A, Saraph V, Linhart WE.** Treatment of femoral neck and trochanteric simple bone cysts. *Arch Orthop Trauma Surg* 2004 ; 124 : 437-442. Epub 2004 Jun 15.
35. **Shrader MW, Jacofsky DJ, Stans AA, Shaughnessy WJ, Haidukewych GJ.** Femoral neck fractures in pediatric patients : 30 years experience at a level 1 trauma center. *Clin Orthop Relat Res* 2007 ; 454 : 169-173.
36. **Soto-Hall R.** variations in the intra-articular pressure of the hip joint in injury and disease. A probable factor in avascular necrosis. *J Bone Joint Surg* 1964 ; 46-A : 509-516.
37. **Tachdjian MO.** Fractures of the neck of the femur. In : Tachdjian MO (ed). *Pediatric Orthopedics*, 2nd ed. WB Saunders, Philadelphia, 1990, p 3231-3247.
38. **Togrul E, Bayram H, Gulsen M, Kalaci A, Ozbarlas S.** Fractures of the femoral neck in children : long-term follow-up in 62 hip fractures. *Injury* 2005 ; 36 : 123-130.
39. **Trueta J.** The normal vascular anatomy of the human femoral head during growth. *J Bone Joint Surg* 1957 ; 39-B : 358-393.
40. **Trueta J.** The vascular contribution to osteogenesis. Studies by injection method. *J Bone Joint Surg* 1960 ; 42-B : 97-109.
41. **Trueta J, Amato VP.** The vascular contribution to osteogenesis. III. Changes in the growth cartilage caused by experimentally induced ischaemia. *J Bone Joint Surg* 1960 ; 42-B : 571-587.
42. **Trueta J, Trias A.** The vascular contribution to osteogenesis. IV. The effect of pressure on the epiphyseal cartilage of the rabbit. *J Bone Joint Surg* 1961 ; 43-B : 800-813.
43. **Vigler M, Weigl D, Schwarz M et al.** Subtrochanteric femoral fractures due to simple bone cysts in children. *J Pediatr Orthop* 2006 ; 15-B : 439-442.
44. **Whitman R.** further observations on depression of the neck of the femur in early life, including fractures of the neck of the femur, separation of the epiphysis and simple coxa vara. *Ann Surg* 1900 ; 31 : 145-149.
45. **Wilson JC.** fractures of the neck of the femur in childhood. *J Bone Joint Surg* 1940 ; 22-A : 531-546.