



## Radiological determination of the anatomic hip centre from pelvic landmarks

Markus D. SCHOFER, Thomas PRESSEL, Thomas J. HEYSE, Jan SCHMITT, Ulrich BOUDRIOT

*From the University Hospital Marburg, Marburg, Germany*

**There are various methods to locate the rotation centre of the hip joint on standard pelvic radiographs. When the geometry of both femoral heads is abnormal, a number of methods are available to locate the physiological hip centre from anatomical landmarks on pelvic radiographs.**

**The accuracy and reliability of six methods were retrospectively investigated on 115 standard pelvic radiographs of both hips of healthy individuals. As a reference against the hip joint centre predicted by these methods, we used the true anatomical centre of the femoral head. Measurements were normalized in relation to pelvic height.**

**The calculated hip rotation centre most closely approached the true anatomical centre of the femoral head when the acetabular teardrop was used as a landmark.**

Keywords : hip joint centre ; anatomic hip centre ; total hip arthroplasty ; landmarks.

### INTRODUCTION

Many factors influence the longevity of hip prostheses, such as implant design and implant materials, body weight and joint loading, but also surgical technique and reconstruction of the anatomic hip centre. Several authors have described the negative effects of an incorrect reconstruction of the hip joint centre leading to increased hip joint forces, early wear and loosening (2,7,10,17,19).

Accurate positioning of the components implies knowledge of the physiological hip joint centre. In

patients with unilateral hip disease the centre of rotation can easily be determined by mirroring the opposite unaffected hip joint. However, if both hip joints show pathological deviations of the rotational centre, other methods have to be applied. Most methods determine the centre of rotation on antero-posterior radiographs of the pelvis, using various pelvic radiographic landmarks as a reference (11,18,25,26).

The aim of this study is to compare different methods used to predict the position of the anatomical hip centre.

### MATERIALS AND METHODS

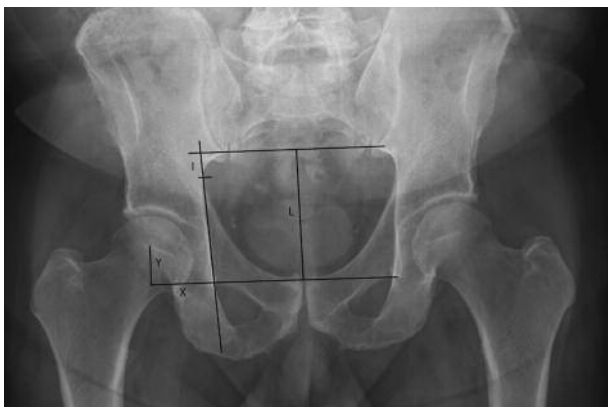The study has been approved by the local hospital ethics committee. Six methods previously described to determine the theoretical anatomical hip centre were compared with the geometrical centre of a normal hip

- Markus D. Schofer, MD, Consultant orthopaedic surgeon.
  - Thomas Pressel, MD, Consultant orthopaedic surgeon.
  - Thomas J. Heyse, MD, Registrar in orthopaedic surgery.
  - Jan Schmitt, MD, Consultant orthopaedic surgeon.
  - Ulrich Boudriot, MD, Consultant orthopaedic surgeon.
- Department of Orthopaedics and Rheumatology, University Hospital Marburg, Marburg, Germany.*

Correspondence : Dr Thomas Pressel, Department of Orthopaedics and Rheumatology, University Hospital Marburg, Baldingerstrasse, 35043 Marburg, Germany.

E-mail : thomas.pressel@gmx.de

© 2010, Acta Orthopædica Belgica.



**Fig. 1.** — Analysis of pelvic radiograph according to Fessy *et al* (11) (method 1). L is the vertical distance between the inter-teardrop line and the inter-sacroiliac line, I the distance between the contact point of the medial ilium with Koehler's line and the inter-sacroiliac line.

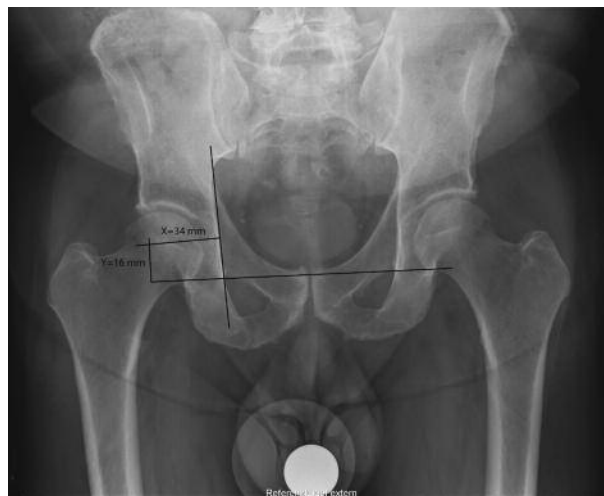which served as a reference for the centre of the hip joint. All authors who reported their calculation methods performed their measurements on pelvic radiographs of individuals with normal hips.

### Method 1

Fessy *et al* (11) calculated the horizontal (X) and vertical (Y) distance of the hip joint centre from the distal end of the acetabular teardrop and the vertical distance (L) between the lines connecting the inferior edge of both sacroiliac joints and both teardrop figures :  $Y = 0.204 L - 0.794$  (fig 1). To calculate X they used Koehler's line as a reference : the distance of Koehler's line from the medial edge of the ilium to the intersection with the line connecting both inferior sacroiliac joints (I). It was found to be different in men and women. X was defined as  $0.093 I + 33.195$  in men (fig 1). In women, the horizontal position of the hip joint centre X was directly correlated with Y :  $X = 0.284 Y + 29.016$ .

### Method 2

Fessy *et al* (11) defined the mean horizontal distance (X) from a perpendicular to the inter-teardrop line and the mean vertical distance (Y) from a perpendicular to Koehler's line (fig 2). Koehler's line and the inter-teardrop line were drawn on x-ray images, and the hip joint centre was located : the mean X distance was 33.6 mm and the mean Y distance was 16.34 mm.



**Fig. 2.** — Analysis of pelvic radiograph according to Fessy *et al* (11) (method 2). The mean perpendicular distances from Koehler's line (X) and the inter-teardrop line (Y) are indicated.

### Method 3

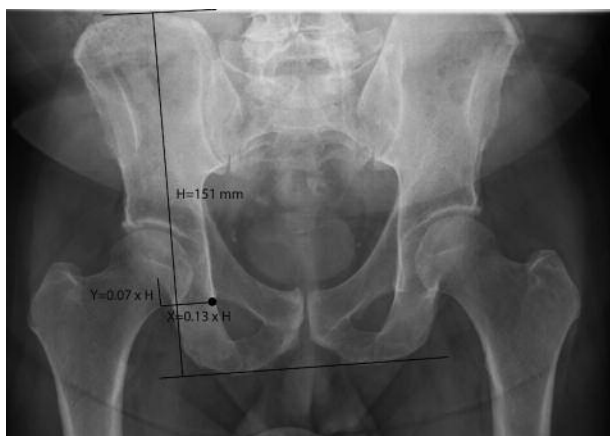John and Fisher (18) measured the vertical and horizontal distance of the femoral head centre from the inferior edge of the teardrop figure. The pelvic height was defined as the vertical distance between lines connecting the superior pelvic rim and the ischiatic tuberosity on both sides (fig 3). The authors divided the vertical and horizontal distance of the femoral head from the teardrop figure by pelvic height and defined the horizontal distance as 13% of pelvic height and the vertical distance as 7% of pelvic height. These mean values were used to determine the hip joint centre on pelvic radiographs.

### Method 4 and 5

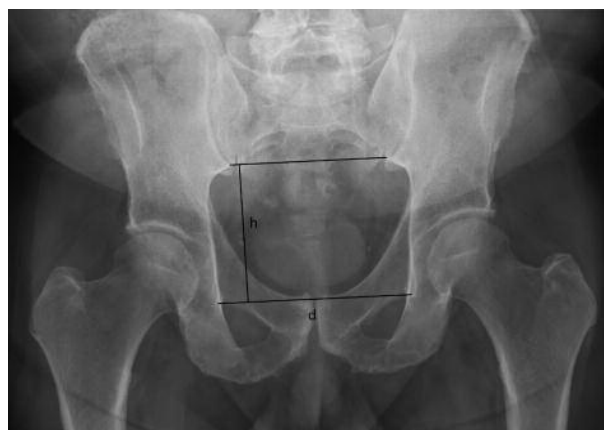Pierchon *et al* (25) constructed horizontal lines through both teardrop figures and the inferior edge of the sacroiliac joint (fig 4) ; the vertical and horizontal distance from the teardrop figure was normalised by dividing them by the inter-teardrop distance (method 4) and the distance between the inter-teardrop line and the inferior sacroiliac joint line (method 5), respectively. The hip joint centre was reconstructed from the normalised values published by Pierchon *et al*.

### Method 6

Ranawat *et al* (26) published an estimation of the acetabular position and indirectly constructed the hip joint



**Fig. 3.** — Analysis of pelvic radiograph according to John and Fisher (18) (method 3). The inferior teardrop figure is marked by a black dot; the hip joint centre is defined relative to this point by mean horizontal (X) and vertical (Y) distances normalized by pelvic height (H).



**Fig. 4.** — Analysis of pelvic radiograph according to Pierchon *et al* (25). The hip joint centre was determined by using the mean distance from the teardrop figure as published by Pierchon *et al*. Distances were normalized by the inter-teardrop distance (d, method 4) and the distance between the inter-teardrop and inter-sacroiliac line (h, method 5) as shown above.

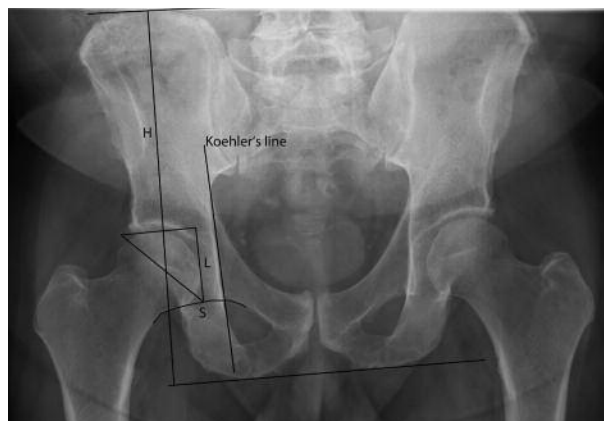centre from an isosceles right triangle located 5 mm laterally from the intersection of Koehler's and Shenton's line. The side length of the triangle was defined by one fifth of pelvic height and the edge of the acetabulum (fig 5).

These six methods were applied to both hips on 115 standard pelvic radiographs of patients (69 males, mean age :  $35 \pm 11.48$  years, ranging from 17 to 73, and 46 females, mean age :  $41 \pm 17.8$  years, ranging from 18 to 74) to determine the hip rotation centre. All radiographs were taken in 2001 in a consecutive series of patients presenting with symptoms attributed to the hip joint or pelvis but without structural pathological findings.

The X-ray images were digitised using a VIDAR® VXR-12 scanner (VIDAR Systems Corporation, Herndon VA, USA). For digitisation, data analysis and storage, the DiagnostiX® software system was used (Gemed, Freiburg, Germany).

The true centre of the femoral head was determined by fitting a circle to the femoral head, and the centre was determined by the intersection of two perpendicular diameters (13). This point was defined as the physiological hip centre. The distance between the rotation centre that was predicted by each method and the centre of the femoral head was calculated. The precision of prediction and the reliability of the method were calculated. The results were presented in two dimensions ( $x/y$ ).

The exact magnification factor of pelvic radiographs is usually unknown and cannot be determined without a



**Fig. 5.** — Measurement on pelvic radiograph according to Ranawat *et al* (26). The pelvic height (H) is measured, and a right isosceles triangle is constructed starting about 5 mm lateral to the intersection of Shenton's line (S) and Koehler's line. The size of the triangle L is one fifth of pelvic height H.

reference object (5). Therefore, a numerical calculation of the  $x/y$  coordinates would not supply reliable data in comparison to other studies. To avoid this problem, in addition to absolute values the  $x/y$  coordinates were normalised by dividing them by the pelvic height which was defined by the vertical distance between the most cranial point of the iliac crest and the most caudal point of the ischial tuberosity. This allowed for comparison of pelvic radiographs independent of the magnification factor,

similar to the approach of Pierchon *et al* (25). The difference between the hip centre calculated by the methods described above and the anatomical hip centre was statistically tested by Student's t-test and the Wilcoxon test.

The 90% confidence interval of differences between the geometrical centres of the femoral heads and the predicted rotation centres of the hip joint was also calculated for all methods.

## RESULTS

Both hip joints were analysed, which led to a total number of 138 male and 92 female hip joints. In some cases the methods according to Ranawat *et al* (26) and Fessy *et al* (11) could not be applied. This led to the exclusion of one male patient's radiograph for Ranawat's method and eight radiographs of female patients for Fessy's method because parts of the pelvis were obstructed by radioprotective shields.

The medial and caudal deviation of the rotation centre was defined as positive, the lateral and cranial position as negative. The method for calculating the horizontal hip centre position according to Fessy *et al* (11) (mean  $-1.69 \pm 0.87$  mm) was found to be the most precise in male subjects (fig 6 a, b). This was also true for the relative values. For the vertical deviation, variations between the different measuring methods were less distinct (fig 6 c, d). Only the method according to Ranawat *et al* (26) varied significantly. The data for female individuals basically showed the same distribution (fig 7 a-d). Remarkably, there was a larger variation in the horizontal than in the vertical direction for all subjects. The smallest 90% confidence intervals of distances between the geometrical hip joint centre and the predicted joint centre were also found in method 1 (fig 8).

We examined whether the different determination methods adequately describe the anatomic hip centre. Both the Student's t-test and Wilcoxon test demonstrated that in all cases the calculated assumption of the rotational centre was significantly different from the true centre of the femoral head which was used as reference ( $p < 0.05$ ). These results indicate that all methods locate the hip centre in a significantly different position compared to the anatomic hip centre.

The results obtained by the method according to Ranawat *et al* (26) differ significantly from other methods. The predicted hip rotation centre was placed more proximally in relation to the pelvic height (male 2.7% of pelvic height, female 3.1%) and more medially (male 5.4%, female 3.6%). The prediction of the joint centre according to the method of John and Fisher (18) came to similar results.

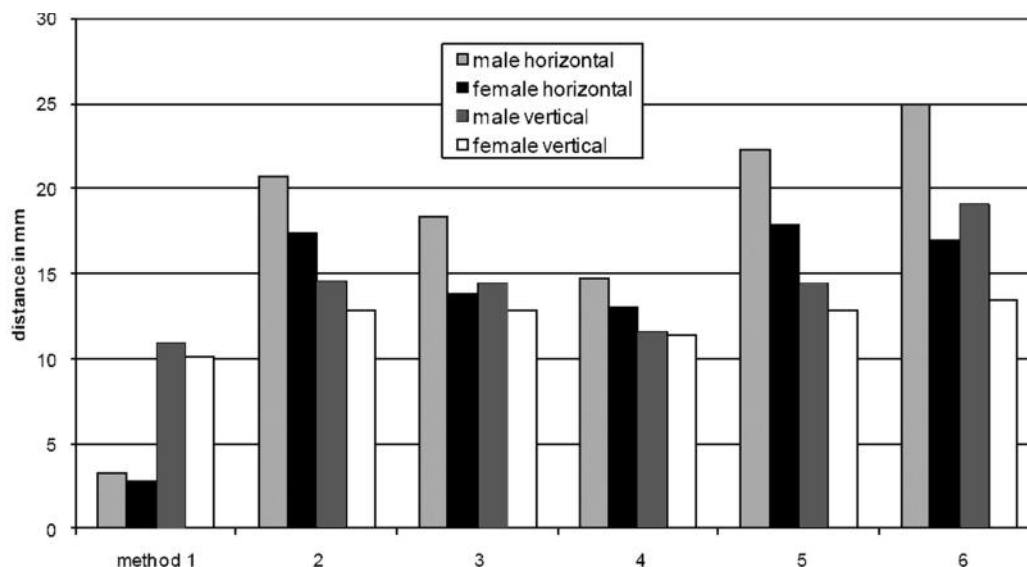
## DISCUSSION

We found that the method according to Fessy *et al* (11) determines the anatomic hip centre most precisely. Furthermore, this method shows the smallest statistical spread for both males and females, in vertical as well as in horizontal directions.

The common characteristic of the hip joint centre calculation methods is that the authors define standard data in order to locate the physiological hip centre relative to different anatomic landmarks or reference lines. As mentioned above, most of the authors neglect the X-ray magnification factor, which may explain the different results compared to our data. Apart from the methods according to John and Fisher (18) and Pierchon *et al* (25), all other authors use absolute instead of relative or normalised data.

John and Fisher (18) use the pelvic height as a reference, whereas Pierchon *et al* (25) refer their results to the inter-teardrop line. We demonstrate that the use of the inter-teardrop line leads to a smaller standard deviation which is comparable in both vertical and horizontal directions and independent of gender. For methodological reasons, this could only be demonstrated for the method according to Pierchon *et al* (25), which uses both lines as references.

The use of radiological landmarks presumes that these landmarks can be determined precisely. Robb *et al* (27) were only able to define the teardrop figure in 93% of the pelvic radiographs. In this study the teardrop figure could be defined in all cases, since measurements were done mainly on healthy individuals. In case of hip dysplasia or after hip replacement this number decreases to 16% (1), limiting the applicability of all those methods.



**Fig. 6.** — 90% confidence interval span of the horizontal and vertical distance between predicted and real hip joint centre in millimetres. Results are grouped by calculation method

An additional problem consists in the retrospective determination of pelvic tilt and rotation. Sutherland *et al* (30) analysed the influence of pelvic tilt and rotation and found that the maximum error due to incorrect pelvic rotation is 2 mm in each direction. The measuring error can be reduced by locating the reference point close to the rotation centre (29). The teardrop figure represents an appropriate radiological landmark, which is situated in the same plane as the hip rotation centre (23). Another important radiological landmark is Köhler's line, which is located posterior to the acetabulum (24). Gates *et al* (12) and Goodman *et al* (14) demonstrated that pelvic rotation influences the position of the teardrop figure less than the location of Köhler's line. However, Russotti and Harris (28) showed that a 10° increase in pelvic tilt leads to a 2 mm shift of the rotation centre.

None of the measured pelvic radiographs were analysed with regard to the amount of pelvic tilt and rotation. This factor was omitted deliberately for the following reasons: First, it is impossible to determine the real inclination and rotation of the pelvis retrospectively as it only can be estimated from the relationship of different pelvic landmarks.

Secondly, this study was performed to find a simple, exact method to determine the anatomic hip centre. The position of the pelvis cannot be exactly controlled in routine pelvic radiographs, so this study intended to represent the situation in a typical hospital or office setting.

Mathematical analyses, as well as experimental investigations, demonstrated that hip forces increase with an incorrectly reconstructed hip centre. Considering an increase in hip joint resultant forces of up to ten times the body weight during single limb stance with dynamic loading (jumping), the significance of small changes in the position of the hip centre becomes obvious (3,6). Increased hip forces thus increase the loading of the implant-bone interface. Antoli *et al* (2) demonstrated that a medial shift of the hip joint centre significantly decreases and a lateral shift strongly increases the magnitude of hip joint forces. A superior shift of the rotation centre diminishes the strength of the hip abductor muscles and should therefore also be avoided.

The most detrimental effects were observed with a proximal-lateral position of the rotation centre (10,17,20,22). Igli *et al* (17) did not find an alteration of forces by shifting the hip centre towards an

anterior-posterior direction, whereas Johnston *et al* (20) demonstrated that a posterior shift increases the resultant hip forces. Similar results were reported by Lengsfeld *et al* (22) in a multibody computer simulation. Furthermore, the alteration of the rotation centre strongly influences the forces of the abductor muscles (2,7,19), the bending forces (2), and the extent of micromotions at the bone-prosthesis interface (9).

An alteration of the hip centre may influence the loosening rate of the prosthesis (31). The higher hip forces in a superior-lateral position of the rotation centre correlate with a higher migration and loosening rate of the implants (4,8,15,16,21).

Despite a limited accuracy of the methods presented for determining the centre of the hip joint, there is hardly an alternative method available. Our study showed that of all methods analysed, the calculation according to Fessy *et al* (11) provides the most reliable data. Except for the method according to Ranawat *et al* (26), all other methods allowed the prediction of the physiological rotation centre within an acceptable deviation of  $\pm 5$  mm. This range is supposed to be harmless regarding a potential increase in hip forces and consecutive loosening of the implants (22). Interestingly, this relatively small deviation has been determined independently of pelvic tilt and rotation.

In conclusion, the methods based on the radiological teardrop figure provide a sufficiently precise determination of the hip joint centre. Normalisation of the results by a parameter such as the inter-teardrop distance or pelvic height accounts for varying X-ray magnification factors and therefore facilitates using these calculation methods in the clinical routine.

## ACKNOWLEDGEMENT

The authors wish to thank Dr Johanna Schmitt for proof reading of the manuscript.

## REFERENCES

1. Albinana J, Morcuende JA, Weinstein SL. The teardrop in congenital dislocation of the hip diagnosed late. a quantitative study. *J Bone Joint Surg* 1996 ; 78-A : 1048-1055.
2. Antolic V, Iglie A, Herman S *et al*. The required resultant abductor force and the available resultant abductor force after operative changes in hip geometry. *Acta Orthop Belg* 1994 ; 60 : 374-377.
3. Bergmann G, Deuretzbacher G, Heller M *et al*. Hip contact forces and gait patterns from routine activities. *J Biomech* 2001 ; 34 : 859-871.
4. Callaghan JJ, Salvati EA, Pellicci PM, Wilson PD Jr, Ranawat CS. Results of revision for mechanical failure after cemented total hip replacement, 1979 to 1982. a two to five-year follow-up. *J Bone Joint Surg* 1985 ; 67-A : 1074-1085.
5. Crooijmans HJ, Laumen AM, Van PC, Van Mourik JB. A new digital preoperative planning method for total hip arthroplasties. *Clin Orthop Relat Res* 2009 ; 467 : 909-916.
6. Crowninshield RD, Johnston RC, Andrews JG, Brand RA. A biomechanical investigation of the human hip. *J Biomech* 1978 ; 11 : 75-85.
7. Delp SL, Maloney W. Effects of hip center location on the moment-generating capacity of the muscles. *J Biomech* 1993 ; 26 : 485-499.
8. Dihlmann Sw, Ochsner Pe, Pfister A, Mayrhofer P. [Analysis of migration of screwed acetabular components following revision arthroplasty of the hip joint. Results of single-image roentgen analysis.] (in German). *Z Orthop Ihre Grenzgeb* 1994 ; 132 : 286-294.
9. Doehring TC, Rubash HE, Dore DE. Micromotion measurements with hip center and modular neck length alterations. *Clin Orthop Relat Res* 1999 ; 361 : 230-239.
10. Doehring TC, Rubash HE, Shelley FJ *et al*. Effect of superior and superolateral relocations of the hip center on hip joint forces. an experimental and analytical analysis. *J Arthroplasty* 1996 ; 11 : 693-703.
11. Fessy MH, N'diaye A, Carret JP, Fischer LP. Locating the center of rotation of the hip. *Surg Radiol Anat* 1999 ; 21 : 247-250.
12. Gates HS III, Poletti SC, Callaghan JJ, Mccollum DE. Radiographic measurements in protrusio acetabuli. *J Arthroplasty* 1989 ; 4 : 347-351.
13. Genda E, Iwasaki N, Li G, Macwilliams BA, Barrance PJ, Chao EY. Normal hip joint contact pressure distribution in single-leg standing – effect of gender and anatomic parameters. *J Biomech* 2001 ; 34 : 895-905.
14. Goodman SB. Comparison of radiographic parameters for analysis of normal and dysplastic hips in the adult. *Contemp Orthop* 1990 ; 20 : 505-511.
15. Griss P, Jentschura G, Heimke G. [A new technique for socket implantation into dysplastic acetabula.] (in German). *Arch Orthop Trauma Surg* 1978 ; 93 : 57-63.
16. Hirakawa K, Mitsugi N, Koshino T *et al*. Effect of acetabular cup position and orientation in cemented total hip arthroplasty. *Clin Orthop Relat Res* 2001 ; 388 : 135-142.
17. Iglie A, Antolic V, Srakar F. Biomechanical analysis of various operative hip joint rotation center shifts. *Arch Orthop Trauma Surg* 1993 ; 112 : 124-126.

18. **John JF, Fisher PE.** Radiographic determination of the anatomic hip joint center. A cadaver study. *Acta Orthop Scand* 1994 ; 65 : 509-510.
19. **Johnston RC.** Mechanical considerations of the hip joint. *Arch Surg* 1973 ; 107 : 411-417.
20. **Johnston RC, Brand RA, Crowninshield RD.** Reconstruction of the hip. A mathematical approach to determine optimum geometric relationships. *J Bone Joint Surg* 1979 ; 61-A : 639-652.
21. **Lachiewicz PF, McCaskill B, Inglis A, Ranawat CS, Rosenstein BD.** Total hip arthroplasty in juvenile rheumatoid arthritis. two to eleven-year results. *J Bone Joint Surg* 1986 ; 68-A : 502-508.
22. **Lengsfeld M, Bassaly A, Boudriot U, Pressel T, Griss P.** Size and direction of hip joint forces associated with various positions of the acetabulum. *J Arthroplasty* 2000 ; 15 : 314-320.
23. **Nunn D, Freeman MA, Hill PF, Evans SJ.** The measurement of migration of the acetabular component of hip prostheses. *J Bone Joint Surg* 1989 ; 71-B : 629-631.
24. **O'Sullivan GS, Goodman SB, Jones HH.** computerized tomographic evaluation of acetabular anatomy. *Clin Orthop Relat Res* 1992 ; 277 : 175-181.
25. **Pierchon F, Migaud H, Duquennoy A, Fontaine C.** [Radiologic evaluation of the rotation center of the hip] (in French). *Rev Chir Orthop Reparatrice Appar Mot* 1993 ; 79 : 281-284.
26. **Ranawat CS, Dorr LD, Inglis AE.** Total hip arthroplasty in protrusio acetabuli of rheumatoid arthritis. *J Bone Joint Surg* 1980 ; 62-A : 1059-1065.
27. **Robb JE, Rymaszewski LA, Bentley HB, Donnan PT.** Reliability of the acetabular teardrop as a landmark. *Surg Radiol Anat* 1991 ; 13 : 181-185.
28. **Russotti GM, Harris WH.** Proximal placement of the acetabular component in total hip arthroplasty. a long-term follow-up study. *J Bone Joint Surg* 1991 ; 73-A : 587-592.
29. **Sutherland CJ, Bresina SJ.** Measurement of acetabular component migration using two-dimensional radiography. *J Arthroplasty* 1992 ; 7 suppl : 377-379.
30. **Sutherland CJ, Wilde AH, Borden LS, Marks KE.** A ten-year follow-up of one hundred consecutive Muller curved-stem total hip replacement arthroplasties. *J Bone Joint Surg* 1982 ; 64-A : 970-982.
31. **Yoder SA, Brand RA, Pedersen DR, O'Gorman TW.** Total hip acetabular component position affects component loosening rates. *Clin Orthop Relat Res* 1988 ; 228 : 79-87.