



Iliotibial band traction syndrome in guided motion TKA A new clinical entity after TKA

Lucas LUYCKX, Thomas LUYCKX, Johan BELLEMANS, Jan VICTOR

From the University Hospitals UZ Pellenberg, KUL, Leuven, Belgium

This study aimed at systematic documentation of lateral knee pain in a consecutive series of 1102 cruciate-substituting, guided motion total knee arthroplasties (TKA) (Journey®, Smith and Nephew, Memphis, TN, USA) performed in 1085 patients; 1070 knees were available for review. Follow-up time ranged from one to five years, with a mean of 2.5 years. Symptoms mimicking the well known iliotibial band (ITB) friction syndrome were observed in 77 knees (7.2%). Initial conservative treatment consisted of anti-inflammatory medication (77 knees) and local steroid injection (35 knees). The pain persisted in 22 knees (2%), leading to a surgical release of the iliotibial band. Other surgical interventions included revision for infection (6 knees, 0.5%), revision for tibial component loosening (6 knees, 0.5%), revision for tibiofemoral dislocation (3 knees, 0.3%), revision for patellar component loosening (5 knees, 0.4%), revision for instability (1 knee, 0.1%) and secondary patellar resurfacing (1 knee, 0.1%). The overall survivorship with partial or total implant revision as an endpoint was 98%. The development of lateral knee pain in association with the use of a guided motion design can be explained by the forced posterior translation of the lateral condyle in flexion. The asymmetric cam and post mechanism, acting as a hard driver of posterior femoral translation and internal tibial rotation during flexion, does not allow for the natural kinematic variability occurring in native knees. This repetitive and forced stretching of the ITB seems to induce a painful traction syndrome in some patients.

Keywords : guided motion TKA ; ITB traction syndrome ; lateral knee pain.

INTRODUCTION

Outcomes research after TKA has unveiled several functional deficits in the activities of daily living (17). In recent years, several new knee implants have been introduced aiming at better stability and higher flexion (1,2,10,20,21). One implant (Journey®, Smith & Nephew, Memphis, TN, USA) followed the principle of guided motion through asymmetric tibiofemoral surface geometry and an asymmetric cam and post design, in an attempt to reproduce a specific kinematic model (21). Clinical research and fluoroscopic analysis on a large patient cohort confirmed the validity of the concept in showing femoral posterior translation and tibial internal rotation with increasing flexion (23).

However, concerns have been raised regarding potential adverse effects of high-flexion guided motion designs (4,9).

-
- Lucas Luyckx, Research Student.
 - Thomas Luyckx, MD, Resident Orthopaedic Surgeon.
 - Johan Bellemans, MD, PhD, Professor and head of the department of Orthopaedic Surgery.
Orthopaedic Department, University Hospitals UZ Pellenberg, KUL, Leuven, Belgium.
 - Jan Victor, MD, PhD, Orthopaedic Surgeon and head of the department of Orthopaedic Surgery.
Orthopaedic Department of A.Z.-St-Lucas, Brugge.
- Correspondence : Lucas Luyckx, Eernegemweg 14, 8490 Jabbeke, Belgium. E-mail : lucas.luyckx@gmail.com
© 2010, Acta Orthopædica Belgica.
-

Table I. — Demographic distributions N = 1056

gender	male	378	36%
	female	678	64%
side	Right	550	52%
	left	492	47%
	Bilateral	14	1%
mean age (years)	66.5		

As the incidence of lateral knee pain associated with the Journey® implant appeared to occur far more frequently compared to other implants used by the senior authors (JB, JV), a dedicated study was undertaken. The goal of the study was to document the incidence of lateral knee pain and subsequent associated treatment modalities in a consecutive cohort of 1085 patients and to provide a biomechanical explanation of the observed symptoms.

MATERIAL AND METHODS

Relevant data of 1102 consecutive cruciate substituting, guided motion TKA's (Journey®, Smith and Nephew, Memphis TN, USA) implanted in 1085 patients, were extracted from the database and patient files. All patients underwent surgery between April 2005 and January 2009. Thirty-two knees (2.9%) were lost to follow-up, leaving 1070 knees available for review. The minimum follow-up was one year and the mean follow up 2.5 years (range, 1-4.7 ; standard deviation [SD] : 1.0).

The average age for all patients included was 66.5 years (range : 22-90 ; SD : 9.83). There were 36% (378) men and 64% (678) women (table I). Of the 1056 patients, 550 received a TKA on the right side, 492 on the left side and 14 had a bilateral TKA.

Center 1 (AZ-St-Lucas, Brugge) provided 355 TKA's, center 2 (UZ-Pellenberg, Leuven) provided 715 TKA's. There were no significant differences between the two centers with respect to revision ratios (2% in center 1 (7 knees), 2% in center 2 (15 knees)), the male-female

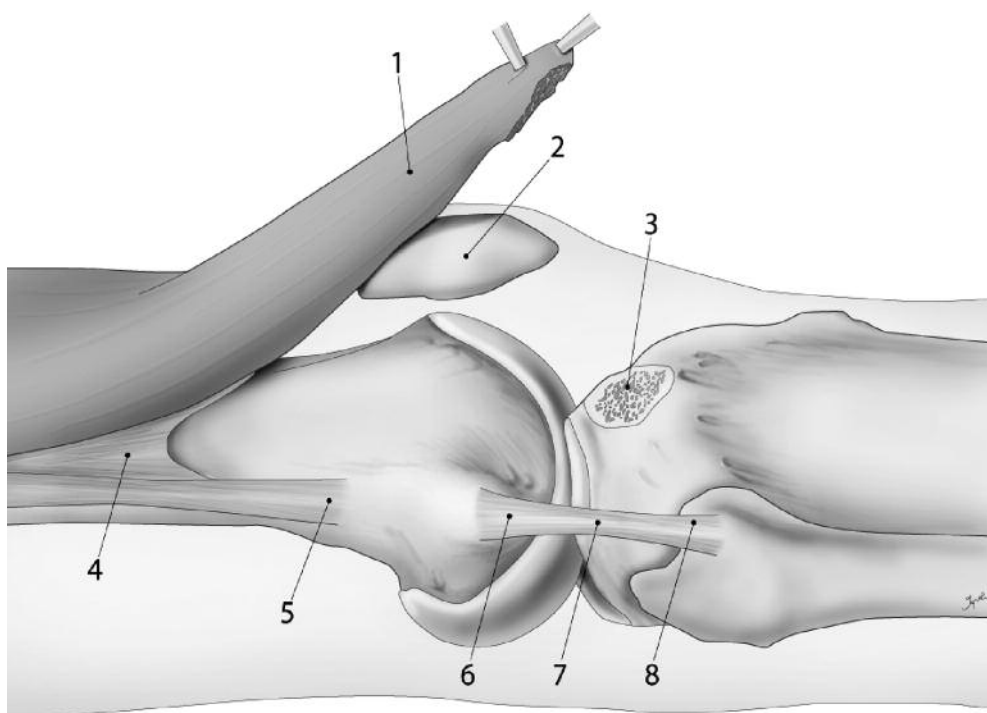


Fig. 1. — The superficial and deep layer of the ITB : (1) superficial layer, (2) patella, (3) Gerdy's tubercle after osteotomy, (4) insertion at the linea aspera, (5) lateral epicondylar insertion of the ITB, (6) lateral epicondylar insertion of the fibular collateral ligament, (7) fibular collateral ligament and (8) head of the fibula.

Table II. — Subgroup ITB traction syndrome

	Number of knees	% of total	% of subgroup
ITB-like symptoms	77	7.2%	100%
Treatment			
oral NSAID's	77	7.2%	100%
steroid infiltration	35	3.3%	45.5%
ITB release	22	2.1%	28.6%

ratio (both centers 36% men and 64% women), the incidence of ITB friction like symptoms (9.2% in center 1, 6.6% in center 2) or demographic variables, allowing the data to be pooled.

We systematically reviewed the patient files, aiming at documentation of symptoms mimicking the well known ITB friction syndrome : symptoms of focal tenderness over the lateral femoral epicondyle and lateral knee pain between 20° and 80° of motion, known as a painful arc (19). Interventions such as oral medication, lateral steroid injection and lateral release were recorded. In an attempt to quantify the severity of complaints, we registered the number of follow-up visits. Also, the time of onset of symptoms, relative to the date of the index operation was noted.

Statistical analysis

Statistical analysis was undertaken using Student's *t* test and the Chi² test. This was performed using SPSS statistical software (version 16.0 ; SPSS Inc., Chicago, Illinois). All *p*-values were two-sided and considered significant when smaller than 0.05.

RESULTS

Symptoms mimicking the ITB friction syndrome were observed in 81 knees (7.6%). Four patients were excluded from subsequent analysis because further investigation revealed an occult infection, leaving us with 77 knees (7.2%). The mean age for all patients included in this subgroup was 66 years (range, 44-83 ; SD : 9.42). There were 36 (47%) men and 41 women (53%). The right knee was concerned in 38 of them, the left in another 38 and one was the left knee of a bilateral TKA (table II).

The mean number of follow-up visits in this group was 7.1 (range, 2-29 ; SD : 4.37) compared to 2.8 (range, 1-8 ; SD : 1.15) in the group without problems. This was a statistically significant difference. The time of onset of ITB friction-like symptoms was on average 6.3 months after TKA (SD : 5.59).

Initial conservative treatment for the ITB friction like symptoms consisted of anti inflammatory medication. All patients with the 77 knees exhibiting ITB friction like symptoms received oral NSAID's. In 46% of these (35 knees), pain persisted and symptoms were prominent, so that a local steroid injection was given. In 22 knees (28.6%) the pain still persisted, leading to a surgical release of the ITB.

The overall survivorship with partial or total implant revision as an endpoint was 97.9%. Twenty-two knees needed partial or total implant revision, consisting of revision for infection (6 knees, 0.5%), revision for tibial component loosening (6 knees, 0.5%), revision for tibiofemoral dislocation (3 knees, 0.3%), revision for patellar component loosening (5 knees, 0.4%), revision for instability (1 knee, 0.1%) and secondary patellar resurfacing (1 knee, 0.1%).

DISCUSSION

This study aimed at documenting a specific lateral pain syndrome after implantation of a guided-motion knee implant, which we defined as the ITB traction syndrome.

The study has several limitations. First, it was conducted in a retrospective manner. Second, pain is a subjective outcome variable and pain rating scales were not available. We decided to quantify the severity of symptoms by the number of the follow-up visits, which was significantly larger in the ITB traction subgroup (mean of 7.1 follow-up visits, compared to 2.8 in the group without problems). Also the use of anti inflammatory medication, corticosteroid injections and surgical release of the ITB, as objective outcome parameters were noted.

Seventy seven patients (7.6%) were identified with a specific lateral pain syndrome, mimicking ITB friction syndrome. This syndrome was previ-

ously unreported in association with TKA. Tendonitis of the patellar tendon or pes anserinus has been reported after TKA, but lateral knee pain is rather uncommon. Pandher *et al* reported a case of posterolateral knee pain after TKA, but they stated that the pain was caused by biceps femoris tendonitis and did not resemble the ITB friction syndrome (18). Symptoms of the ITB traction syndrome are lateral and anterolateral knee pain, occurring with motion, and leading to a painful arc. Symptoms started at a mean of 6.3 months post-operatively, suggesting the guided motion pattern imposed by the implant was generating the pain syndrome as patients became more active after the operation.

The ITB is a complex structure, receiving the insertions from the gluteus maximus and tensor fasciae latae muscles. The ITB does not have a single insertion at Gerdy's tubercle, as is generally thought, but has a wide periarticular insertion: an insertion at the linea aspera, one at the lateral epicondyle, a patellar insertion, which is wide and fuses itself to the lateral retinaculum, a direct insertion, which widely inserts at Gerdy's tubercle and a capsular-osseous insertion, also known as the femorotibial ligament (25). Especially the patellar insertion, which connects the ITB to the patella and forms the lateral retinaculum has been described by many authors, but the literature includes different interpretations of the tissue bands, the layers and their denominations.

Earlier studies, as those by Fulkerson and Gosseling described the anatomy of the lateral retinaculum in two separate layers: the superficial oblique layer and the deep layer (7). Currently it is agreed that there are three distinct layers: a superficial, an intermediate and a deep layer. The superficial layer consists of the deep fascia of the thigh. The deep fascia is not attached to the patella but is adherent to deeper tissues laterally, thus acting as a brace. The ITB is a derivative of the deep fascia and by its expansions contributes to the retinaculum. The longitudinal fibres of the ITB merge with those of the quadriceps aponeurosis lateral and adjacent to the patella, forming an intermediate layer. These longitudinal fibres are reinforced by the transverse retinaculum, which consists of superficial fibers of

the ITB, the iliopatellar or arciform fibres, and the deeper transverse fibres of the ITB. The most substantial structure consists of the deeper transverse fibres which are dense and anchor the lateral edge of the patella and the tendon of vastus lateralis obliquus to the ITB. They are not a distinctly separate layer, but adhere to the deep aspect of the ITB.

The deep layer consists of the joint capsule. The joint capsule is thickened laterally and forms the lateral patellofemoral ligament. Similarly, another condensation of the joint capsule is termed the meniscopatellar or patellomeniscal ligament. Some studies noted however that these capsular ligaments vary considerably and are not always found (13).

The most prominent structure of the lateral retinaculum and the strongest, as shown by Merican *et al* consists of the ITB-patellar fibres (16). The location, bulk and orientation of those fibers suggests that they may play an important role in the lateral restraint of the patellofemoral joint. However these transverse fibres lack a direct connection to the femur, and they are more prominent and are consistently found, as compared to the lateral patellofemoral ligament.

Moreover, the part of the ITB to which the deeper transverse band is attached is relatively fixed in a longitudinal direction as a short segment. Proximally, it is anchored to the proximal aspect of the femoral condyle and distally to Gerdy's tubercle on the tibia. In view of its longitudinal orientation, tension in the ITB would not be thought to affect patellofemoral tracking. However, when the bony fixation mentioned above and the transverse fibres are taken into account, it is likely that tension in the iliotibial band plays a role in the function of the lateral retinaculum (13).

This was confirmed by Merican *et al*, who demonstrated that with increasing ITB loads, the patella tracked and tilted more laterally in the mid flexion range and rotated more laterally later in the flexion cycle. Simultaneously, the tibia rotated externally up to 13° (90N load) (14).

The function of the ITB is complex. Together with the tensor fasciae latae and the gluteus maximus fibers, it plays a role in stance and monopodal balance. It also plays a role in the external rotation of the tibia and it is considered as a primary lateral

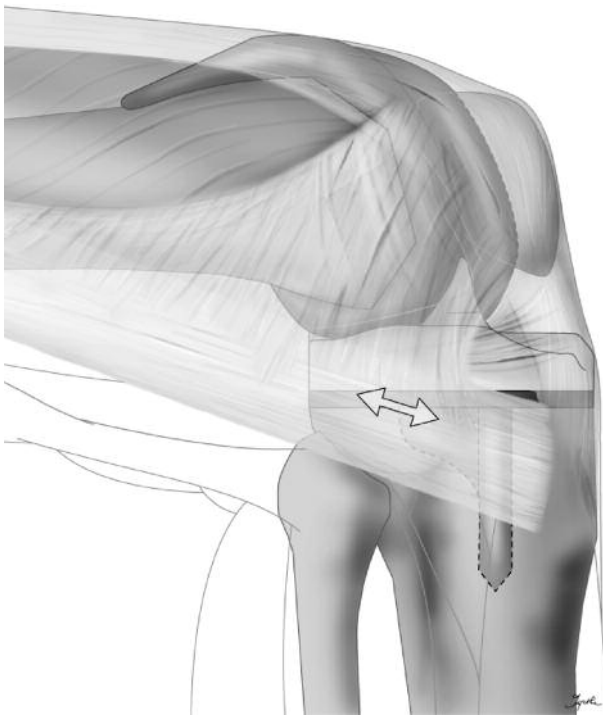


Fig. 2. — Stretching of the ITB imposed by the cam-post geometry of the implant.

stabilizing ligament of the knee. This stabilizing effect is provided by its attachments to the patella preventing the ITB from shifting posteriorly during flexion, creating a higher tension in the transverse fibres of the ITB. This tension provides a lateral stabilizing effect on the knee during flexion (26).

Some authors have stated that the ITB friction syndrome is not caused by friction between the ITB and the lateral femoral epicondyle, but rather by compression of the ITB against a layer of highly innervated fat tissue that intervenes between the ITB and the epicondyle. This compression occurs mainly at 30° of flexion, probably as a result of the internal rotation of the tibia at that point (5,6).

Gosh *et al* demonstrated that a conventional cruciate retaining TKA (Genesis 2, Smith & Nephew, Memphis, Tennessee) did not cause significant elongation of the lateral retinaculum. The lateral retinaculum of the native knee was longest in the flexed position and slackened in the final 70° of knee extension, which is consistent with the anatomy. After TKA no significant changes could be found (8).

In contrast, *ex vivo* experimental data comparing case to case tibial rotation in the native knee to tibial rotation after Journey TKA clearly showed excessive internal rotation of the prosthetic knee in the loaded setting (24). Where the axial kinematic pattern of the prosthetic knee mimicked well the passive kinematics of the native knee, the prosthetic knee failed to adapt to loading as did the native knee in the experimental setting. These findings were confirmed *in vivo*, based on fluoroscopic kinematic analysis (23). In some patients posterior femoral translation exceeded 23 mm, creating internal tibial rotation over 10.8° with increasing flexion. This kinematic pattern is imposed by the cam-post geometry of the implant and partially dependent on the axial alignment of the tibial component. In patients with excessive internal rotation of the tibia during flexion, the length of the ITB is greater than in patients with a natural rotational pattern (fig 2). In the native knee, contraction of the biceps femoris reduces internal rotation of the tibia with increasing flexion and thereby reduces traction on the ITB (11,12,22). Excessive internal rotation, as observed in some patients after Journey TKA could lead to eccentric loading of the ITB and induce the observed symptoms.

We noted a tendency to a higher percentage of men amongst the patients with ITB traction syndrome : 46% compared to 36% in the overall group (not statistically significant). Possible explanations for this tendency could be related to gender associated general ligament laxity, activity level or muscular force.

Patients presenting with the ITB traction syndrome were initially treated conservatively, using oral medication and local injections with steroids. This treatment was significantly helpful in 71.4% of the patients. Symptoms persisted in 28.6% and those patients were treated with a surgical release of the ITB. This release was performed through a lateral skin incision and transected the anterior fibres of the ITB extending into the lateral retinaculum (3,15,26) (fig 3).

Based on the observed symptoms and the incidence of occurrence after TKA, we believe that a modification of the prosthetic design is desirable. The amount of posterior translation of the lateral




Fig. 3. — Surgical release of the lateral retinaculum and ITB.

femoral condyle during flexion needs to be reduced, resulting in less guided internal rotation of the tibia.

REFERENCES

1. **Argenson J, Komistek RD, Mahfouz M et al.** A high flexion total knee arthroplasty design replicates healthy knee motion. *Clin Orthop Relat Res* 2004 ; 428 : 174-179.
2. **Clayton RA, Amin AK, Gaston MS, Brenkel IJ.** Five-year results of the Sigma total knee arthroplasty. *Knee* 2006 ; 13 : 359-364.
3. **Clifton R, Ng CY, Nutton RW.** What is the role of lateral retinacular release ? *J Bone Joint Surg* 2010 ; 92-B : 1-6.
4. **Dorr LD.** Contrary view : wear is not an issue. *Clin Orthop Relat Res* 2002 ; 404 : 96-99.
5. **Fairclough J, Hayashi K, Toumi H et al.** Is iliotibial band syndrome really a friction syndrome ? *J Sci Med Sport* 2007 ; 10 : 74-76.
6. **Fairclough J, Hayashi K, Toumi H et al.** The functional anatomy of the iliotibial band during flexion and extension of the knee : implications for understanding iliotibial band syndrome. *J Anat* 2006 ; 208 : 309-316.
7. **Fulkerson JP, Gossling HR.** Anatomy of the knee joint lateral retinaculum. *Clin Orthop Relat Res* 1980 ; 153 : 183-186.
8. **Gosh KM, Merican AM, Iranpour F, Deehan DJ, Amis AA.** Length change patterns of the extensor retinaculum and the effect of total knee replacement. *J Orthop Res* 2009 ; 27 : 865-870.
9. **Han HS, Kang SB, Yoon KS.** High incidence of loosening of the femoral component in legacy posterior stabilised-flex total knee replacement. *J Bone Joint Surg* 2007 ; 89-B : 1457-1461.
10. **Kolisek FR, Barnes CL.** Scorpio posterior-stabilized knee system : 5-year clinical and functional results. *J Arthroplasty* 2006 ; 21 : 1187-1192.
11. **Kwak SD, Ahmad CS, Gardner TR et al.** Hamstrings and iliotibial band forces affect knee kinematics and contact pattern. 2000 ; 18 : 101-108.
12. **MacWilliams BA, Wilson DR, DesJardins JD, Romero J, Chao EY.** Hamstrings cocontraction reduces internal rotation, anterior translation, and anterior cruciate ligament load in weight-bearing flexion. *J Orthop Res* 1999 ; 17 : 817-822.
13. **Merican AM, Amis AA.** Anatomy of the lateral retinaculum of the knee. *J Bone Joint Surg* 2008 ; 90-B : 527-534.
14. **Merican AM, Amis AA.** Iliotibial band tension affects patellofemoral and tibiofemoral kinematics. *J Biomech* 2009 ; 42 : 1539-1546.
15. **Merican AM, Kondo E, Amis AA.** The effect on patellofemoral joint stability of selective cutting of lateral retinacular and capsular structures. *J Biomech* 2008 ; 42 : 291-296.
16. **Merican AM, Sanghavi S, Iranpour F, Amis AA.** The structural properties of the lateral retinaculum and capsular complex of the knee. *J Biomech* 2009 ; 42 : 2323-2329.
17. **Noble PC, Conditt MA, Cook KF, Mathis KB.** The John Insall Award : Patient expectations affect satisfaction with total knee arthroplasty. *Clin Orthop Relat Res* 2006 ; 452 : 35-43.
18. **Pandher DS, Boparai RS, Kapila R.** Biceps tendinitis as a cause of acute painful knee after total knee arthroplasty. *J Arthroplasty* 2009 ; 24 : 1292.e15-8.
19. **Renne JW.** The iliotibial band friction syndrome. *J Bone Joint Surg* 1975 ; 57-A : 1110-1111.
20. **Tarabichi S, Tarabichi Y, Hawari M.** Achieving deep flexion after primary total knee arthroplasty. *J Arthroplasty* 2010 ; 25 : 219-224.
21. **Victor J, Bellemans J.** Physiologic kinematics as a concept for better flexion in TKA. *Clin Orthop Relat Res* 2006 ; 452 : 53-58.
22. **Victor J, Labey L, Wong B, Innocenti B, Bellemans J.** The influence of muscle load on tibiofemoral kinematics. *J Orthop Res* 2009 ; 28 : 419-428.
23. **Victor J, Mueller JK, Komistek RD et al.** In vivo kinematics after a cruciate-substituting TKA. *Clin Orthop Relat Res* 2010 ; 468 : 807-814.
24. **Victor J, Van Glabbeek F, Vander Sloten J et al.** An experimental model for kinematic analysis of the knee. *J Bone Joint Surg* 2009 ; 91-A : 150-163.
25. **Vieira EL, Vieira EA, Teixeira da Silva R. et al.** An anatomic study of the iliotibial tract. *Arthroscopy* 2007 ; 23 : 269-274.
26. **Whiteside LA, Roy ME.** Anatomy, function, and surgical access of the iliotibial band in total knee arthroplasty. *J Bone Joint Surg* 2009 ; 91-A : 101-106.