

A simplified technique for anterior cervical discectomy and fusion using a screw-plate implanted over the Caspar distractor pins

Patrick FRANSEN

From the Clinique du Parc Léopold, Brussels, Belgium

The author presents a simplified technique for midline screw-plate fixation in fusion procedures after anterior cervical discectomy, in which the plate is introduced over the Caspar distractor pins. The Uniplate® system used, with a single screw in each vertebral body, minimizes bone damage to the vertebral body as the screws can be fixed in the holes previously used for the Caspar distractor pins. This simplified version of the classical anterior cervical fusion technique saves surgical time, facilitates screw insertion, and obviates the need for manipulations to stabilize the plate before the screws are inserted. It provides immediate stability comparable to other plate systems. To the author's knowledge, this is the first report on cervical fusion with the Uniplate® system with the plate being introduced over the Caspar distractor pins.

Keywords: anterior cervical discectomy ; cervical fusion ; anterior cervical plate.

INTRODUCTION

Reducing the duration and invasiveness of surgical procedures is an important aspect of surgical progress: the risk of injury to anatomical structures will also be reduced by limiting the number of surgical steps.

Anterior cervical discectomy and fusion (ACDF) is a widely used procedure for the treatment of cervical degenerative disc disease. Kaiser *et al* (4) reported that the use of anterior cervical plating with

one-level and even more so with two-level ACDF, significantly enhanced fusion, supporting its use in the treatment of cervical spondylosis. One of the problems encountered with this approach is that the use of a Caspar intersomatic distractor and a classical 4-screws plate requires drilling three holes in each vertebral body. This may weaken the vertebral body and result in a loose grip of the screws. For this reason, the author chose to use a midline plate (fig 1), secured by only one screw per vertebra



Fig. 1. — Anterior view of the Uniplate® anterior cervical plate.

■ Patrick Fransen, MD, Head of Department.
Department of Neurosurgery, Clinique du Parc Léopold, Brussels, Belgium.
Correspondence : Patrick Fransen, MD, Department of Neurosurgery, Clinique du Parc Léopold, 38 rue Froissart, 1040 Brussels, Belgium.
E-mail : p.fransen@neurobrussels.be
© 2010, Acta Orthopædica Belgica.

(Uniplate®, DePuy Spine), so as to minimize the bone weakening, in patients with degenerative cervical disc disease without instability. Moreover, this single screw vertebral body system allowed positioning of the plate on top of the modified Caspar distractor pins.

TECHNIQUE

An anterior cervical approach is performed through a transversal incision. The anterior aspect of the cervical spine is reached between the trachea and oesophagus medially, and the carotid-jugular group laterally. A self-retaining transversal retractor is positioned under the longissimus colli. After fluoroscopic control of the disc level, Caspar distractor pins are inserted on the midline into the vertebral bodies (fig 2a), under fluoroscopic control, parallel to the endplates. The intersomatic distractor is subsequently positioned. Great care is taken not to damage the adjacent discs.

The discectomy is then performed according to the local standard of care, which includes systematic opening of the posterior longitudinal ligament and bilateral exploration of the neuroforamina. A polyetheretherketon (PEEK) cage filled with tricalcium phosphate bone substitute is inserted into the intersomatic space. Some axial distraction may be used at this stage to facilitate insertion of the cage. The Caspar distractor is then removed while the pins are left in place. The cross-guard of the

Caspar retractors pins has been reduced to a diameter just under the diameter of the holes in the plate. After measuring the distance between the two Caspar pins, the appropriate anterior plate is slid over the two pins until contact with the bone is reached. The distal pin is then removed and is immediately replaced with a screw (fig 2b). Finally, the proximal pin is removed and the second and last screw is inserted. The screws are then locked to the plate (fig 2c). The wound is closed in the usual fashion. Fig 3 illustrates a C5-C6 fusion performed with the technique described.

DISCUSSION

Several anterior cervical screw-plate systems are available, including static, semi-constrained rotational and dynamic translational plates. No clinical study definitively suggests that any type of anterior cervical plate is superior to another, although some biomechanical tests have been done (2). Previously, the Caspar pins had to be removed before the plate could be inserted, because of their diameter. This increased the operative time and the number of manipulations, while it could cause unnecessary bleeding.

The Uniplate® Anterior Cervical Plate System is a simplified system for a one- or two-level ACDF. It is a midline system which was designed to achieve a plate-secured cervical fusion with a less invasive method than with the traditional plates with two

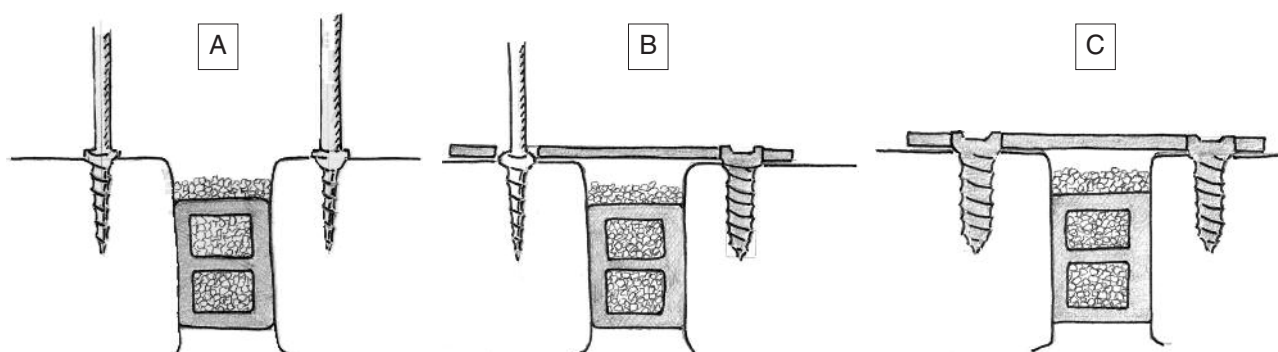


Fig. 2. — Artist drawing : lateral view of the surgical site after implantation of an intersomatic cage filled with and surrounded by bone grafts. (A). The Caspar distractor pins are still inserted into the vertebral bodies. (B). The midline plate has been slid over the Caspar pins. One of the pins has been removed and replaced with a screw. (C). Final view after removal of the last pin and insertion of the second screw.

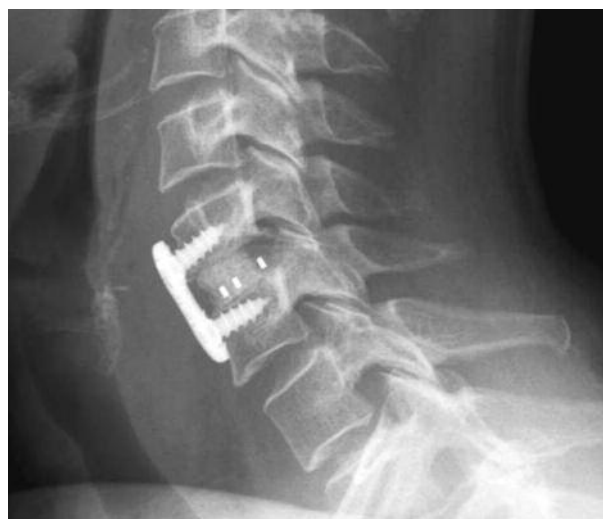
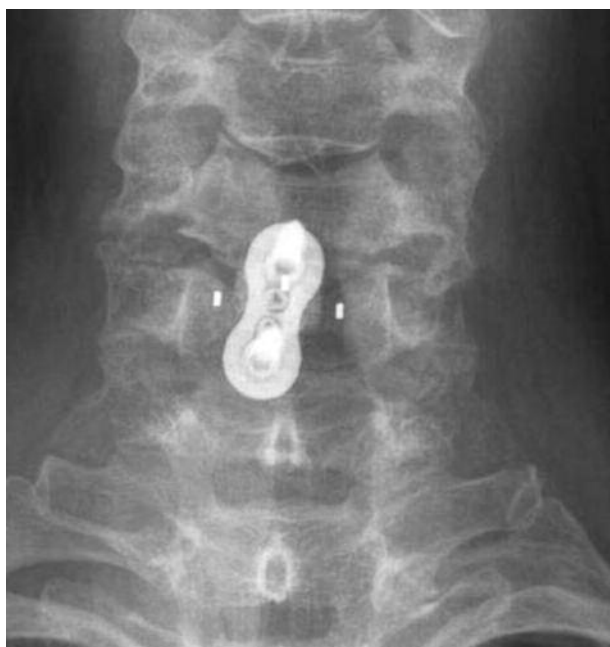
Fig. 3. – Cervical spine antero-posterior and lateral view after anterior cervical discectomy and fusion using a PEEK cage filled with tri-calcium phosphate bone substitute and the Uniplate® system.

screws per vertebral body. The plate is low profile, semi-rigid, 10.5 mm wide, 2.3 mm thick, maintained by a single screw in each vertebra, and secured by a tri-lobe locking mechanism. We asked the manufacturer (DePuy Spine) to slightly diminish the diameter of the Caspar pins, in order to make it possible to slide the plate over the Caspar pins, which were then removed and replaced by screws with appropriate length.

This plate therefore allows the surgeon to re-use the Caspar pin hole in the vertebral body for screw insertion. A 5mm margin between the plate extremities and the neighbouring discs should be respected in order to avoid anterior osteophyte formation (5,6). This technique also has the advantage to achieve more easily perfect midline positioning of the plate, although a rotated or lateralized position of the plate has been reported to have little short-term effect on the clinical outcome (3). From a biomechanical point of view there are no significant differences in the stiffness of the construct between this plate and a system with two screws per vertebra. Although one might intuitively believe this system to be less rigid in lateral flexion and torsion, the *in vitro* ROM was reduced by 67% compared to the situation without plate, independently of the direc-

tion of loading (1), for single or double level constructs. However, the author accepts that the midline plate has not yet been evaluated in cases with significant spondylolisthesis, trauma with compromised facet joints or tumour with major instability.

REFERENCES

1. **Brodke DS, Clark R, Bachus KN.** Biomechanical evaluation of a novel anterior cervical plate Poster presentation, 22nd Annual Meeting of AANS/CNS Section on Disorders of the Spine and Peripheral Nerves, Orlando, Florida, March 15-18, 2006
2. **Fassett DR, Csaszar DJ, Albert TJ.** Anterior cervical plating update. *Current Opinion in Orthopedics* 2007 ; 18 : 282-288.
3. **Ipsen BJ, Kim DH, Jenis LG, Tromanhauser SG, Banco RJ.** Effect of plate position on clinical outcome after anterior cervical spine surgery. *Spine J* 2007 ; 7 : 637-642.
4. **Kaiser MG, Haid RW Jr, Subach BR, Barnes B, Rodts GE Jr.** Anterior cervical plating enhances arthrodesis after discectomy and fusion with cortical allograft. *Neurosurgery* 2002 ; 50 : 229-236.
5. **Park JB, Cho YS, Riew KD.** Development of adjacent-level ossification in patients with an anterior cervical plate. *J Bone Joint Surg* 2005 ; 87-A : 558-563.
6. **Park JB, Watthanaaphisit T, Riew KD.** Timing of development of adjacent-level ossification after anterior cervical arthrodesis with plates. *Spine J* 2007 ; 7 : 633-636.