

The accessory soleus muscle as a cause of persistent equinus in clubfeet treated by the Ponseti method : A report of 16 cases

Waleed E. KISHTA, Emad H. MANSOUR, Mazen M. IBRAHIM

From Al-Razi Hospital, State of Kuwait

Encountering an accessory soleus muscle in children undergoing surgical release for clubfeet is not a frequent occurrence and only a few reports could be traced in literature.

The purpose of this study is to report a series of 20 observations in 16 patients with idiopathic clubfeet treated by the Ponseti technique where the accessory soleus muscle was responsible in preventing full ankle dorsiflexion after Achilles tendon tenotomy. Following its division, adequate dorsiflexion could be achieved. To our knowledge this is the largest series published to date on this topic. In addition, we discuss the frequency and epidemiology, as well as the anatomy of the accessory soleus muscle, its innervation and embryology.

The mean age at presentation was 40.7 days (range : 6 to 210 days). The accessory soleus tendon was observed in 6 right and 6 left feet, 4 feet had bilateral involvement. The average ankle dorsiflexion after complete tendo Achilles tenotomy was 2.5° (SD : 6.38), and after sectioning of the accessory soleus tendon, it was 19.5° (SD : 5.59) ($p < 0.001$). Correction was obtained in all patients, after 3 to 10 casts.

In conclusion, the recognition of an accessory soleus muscle, in patients with clubfeet, is important, and its release is necessary to fully correct the deformity. Failure to recognize this muscle may lead to persistent hindfoot deformity.

Keywords : clubfoot ; Ponseti method ; accessory soleus.

INTRODUCTION

Clubfoot deformity is probably the most common (1 to 2 in 1,000 live births) congenital orthopaedic condition requiring intensive treatment. It represents a congenital dysplasia of all musculoskeletal tissues distal to the knee (11). This deformity represents a pathological condition consisting of adduction of the forefoot, inversion of the heel and equinus at the ankle. The condition has also been described as a congenital subluxation of the talo-calcaneo-navicular joint (19).

Most orthopaedic surgeons agree that the initial treatment should be non-surgical and should start soon after birth (11). In 1963, Ponseti and Smoley published their first report on 67 patients who were

-
- Waleed E. Kishta, MD, MSc, PhD, Senior Registrar in Orthopaedic surgery
 - Emad H. Mansour, FRCS©, Specialist in Orthopaedic surgery
 - Mazen M. Ibrahim, MSc, Registrar in Orthopaedic surgery. *Pediatric Orthopaedic unit, Al-Razi Hospital, State of Kuwait*
- Correspondence : Mazen M. Ibrahim,
P.O. Box 18927, Code 81010, Farwania, State of Kuwait.
E-mail : mazenabdallah79@yahoo.com
© 2010, Acta Orthopædica Belgica.
-

younger than 6 months of age and were treated by the Ponseti method in the form of serial manipulation and casting, with or without Achilles tenotomy, followed by the use of a foot abduction orthosis (FAO) for maintenance of the correction. They demonstrated satisfactory and rapid initial correction in the majority of cases (83%) with minimal complications (19).

The pathological anatomy of a clubfoot has been well defined, with tightness of posterior and medial muscle tendon units, including the gastro-soleus, plantaris if present, tibialis posterior, flexor digitorum longus, flexor hallucis longus and the short plantar muscles, along with changes in the calcaneus, talus, navicular, cuboid and their articulations and capsules. Encountering an accessory soleus muscle in children undergoing surgical release of clubfeet is not a frequent occurrence and only a few reports could be traced in the literature (3,6).

The accessory soleus muscle is a supernumerary muscle bundle developed from the soleus muscle, situated in front of the Achilles tendon, ending either on the Achilles tendon or on the calcaneus itself. The muscle is composed of normal muscle fibers. Like all other anatomical variations of the human muscular system, the accessory soleus muscle was well known to early anatomists. It has been described at the end of the 19th century by Luschka (1865), Bankart and Pye-Smith (1869), Testut (1884), all referred to in the study by Ledouble (1897) (1).

The occurrence of an accessory soleus muscle seems to be the most frequently described anatomical variation in the calf muscles (16). The incidence ranges from 0.7 to 5.5%. Recently, Kouvalchouk *et al* (13) estimated that it was present in 10% of all individuals. Some authors, like Christodoulou *et al* (6) and Kendi *et al* (12), considered that the occurrence of an accessory soleus muscle was a rare anatomical variation. Downey and Siegeman found 13 cases of an accessory soleus muscle in a study of 689 cadavers or 1.9%. A bilateral variant was observed in 30 to 50% of these cases. Other findings support those of our series : young adult, no preferential side and male predominance (8).

The proximal insertion is relatively constant : the posterior aspect of the tibia and the aponeurosis of

the muscles of the deep compartment at the anterior aspect of the soleus muscle. The distal insertion on the contrary is much more variable (15,16). Yu and Resnick (26) defined five different types : along the Achilles tendon, on the superior aspect of the calcaneus via a separate tendon or directly via the muscle body and on the medial aspect of the calcaneus, here too, either via a separate tendon or via the muscle body. Bonnel and Cruess (2) observed a forked tendon inserted on either side of the calcaneus. The body of the muscle is situated in front of the Achilles tendon. The Achilles tendon runs through the muscle and, in front, enters in relationship with the muscles and tendons of the posterior compartment in the same way as the vascular nervous bundle. Sekiya *et al* (22) have provided most of our knowledge of the innervation. The accessory muscle is innervated by branches of the anterior branch to the soleus muscle, coming from the posterior tibial nerve. This seems to suggest that the supernumerary muscle derives from a part of the soleus muscle that is innervated by the anterior branch.

According to Gordon and Matheson (10), the human soleus and gastrocnemius muscles have their own and separate origin. However, they can be incompletely divided, and therefore can have a common origin or can have stayed merged together along the entire length or can have experienced a different growth resulting in a disparity of size. Besides, their premature separation could explain the existence of a supernumerary muscle. Ledouble (13) was first to show that this accessory muscle does not derive from the plantar muscle, but from the soleus muscle.

The purpose of our study is to report a series of clubfeet, treated by the Ponseti technique, where the accessory soleus muscle was responsible for preventing full ankle dorsiflexion after Achilles tendon tenotomy. To our knowledge this is the largest series published to date on this topic, and the only one in using the Ponseti technique.

PATIENTS AND METHODS

Between May 2007 and February 2010, 209 congenital idiopathic clubfeet in 148 patient, 91 boys and 57 girls, were treated at the clubfoot clinic, in

Al-Razi Hospital, Kuwait, with serial manipulation and casting performed at weekly intervals, with or without Achilles tenotomy as described by Ponseti (21). We noticed in 20 feet in 16 patients with 25 clubfeet a failure to obtain full dorsiflexion even after complete Achilles tendon tenotomy. There were 15 boys and 5 girls, The mean age at presentation was 40.7 days (range : 6 to 210 days).

A modification in the technique of Achilles tenotomy, as described by Ponseti, was considered by making a minimal incision for an open tendo-achilles tenotomy to detect any other tight posterior structure. In these 20 cases, another tendon deeper to the Achilles tendon was encountered. This was inserted anteromedially to the insertion of the tendoachilles. The accessory soleus tendon was observed in 6 right feet (37.5%) and in 6 left feet (37.5%), and bilaterally in 4 feet (25%) .

All the children in this study were followed up clinically for an average period of 24.7 months (ranging from 19 to 26 months). No patient was lost to follow-up.

RESULTS

The results were evaluated and considered good when there was no residual equinus in the hindfoot, a clear valgus position of the calcaneus, no residual endorotation in the hindfoot and a fully restorable adduction of the forefoot by slight pressure on the medial side of the first metatarsal. Residual deformity of one of these criteria was considered to be a failure and resulted in a decision for operative treatment. Correction was obtained in all patients except in one who required a total release (fig 1). Correction was obtained with 3 to 10 casts. The average ankle dorsiflexion after complete tendoachilles tenotomy was 2.5° (SD : 6.38), and after sectioning of the accessory soleus tendon, it was 19.5° (SD : 5.59) which was statistically significant ($p < 0.001$). The majority of patients started walking at an age of 13 months (range : 9-17 months). One case was treated previously by the Ponseti method in another center and presented to us with a residual equinus. Corrective surgery was recommended initially by the treating physician. When we revised the tenotomy at the age of 7 months, 10°

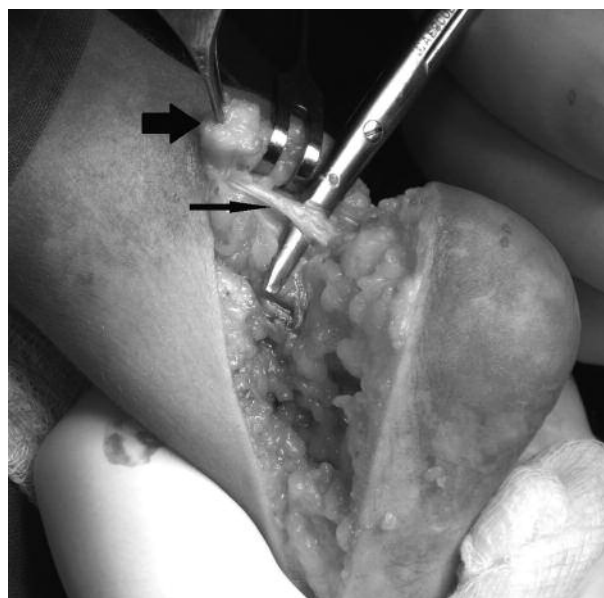


Fig. 1. — Intraoperative photograph showing a full posterior release of a recurrent right clubfoot treated previously by the Ponseti technique. The sectioned proximal end of the tendo Achillis (thick arrow) and the accessory soleus muscle (thin arrow) are shown.

of equinus remained after Achilles tenotomy. After inspection, however, an accessory soleus tendon was found and sectioned, resulting in 15° dorsiflexion, without recurrence after 11 months.

DISCUSSION

Anomalies pertaining to the soleus muscle have been described in the literature, the most common among them being the presence of an accessory soleus muscle anterior to the soleus ; supernumerary fascicles of the soleus have also been described (10). The accessory soleus muscle is thought to be formed by the splitting of the anlage of the soleus (2). The insertion may be variable and it may be inserted on the Achilles tendon, the superior or medial surface of the calcaneus, as a tendon or as a fleshy belly (14). It may also have a bifid tendon which is inserted on the medial and lateral aspects of the calcaneum (2). Dunn (9) is credited with the report of the first clinical case of accessory soleus in the English literature. Previously, this muscle was reported only in cadaveric

specimens (10). The commonest presentation of accessory soleus muscle is not in the form of any associated deformity, but in the form of a swelling at the posteromedial aspect of the ankle in adolescents or young adults, which is often painful (18). The pain occurs mostly on activity and these cases are usually diagnosed by imaging studies, of which computed tomography (CT) and magnetic resonance imaging (MRI) are most useful (17). Before the advent of MRI and CT, the diagnosis of symptomatic accessory muscle was made only on surgical exploration (18). No case with a presentation of swelling and pain in infancy or early childhood could be traced in the literature. Only few reports of accessory soleus muscle in association with clubfoot deformity were found. Chotigavanichaya *et al* reported a case with an accessory soleus muscle in a persistent equinus deformity after percutaneous tenotomy, which was also resistant to standard posteromedial release, but which was finally corrected after tenotomizing the tendon of this muscle during a subsequent open surgical release (5). Danielsson *et al* reported two children with an accessory soleus muscle contributing to hindfoot varus. Release of the accessory muscle during a standard posteromedial release considerably diminished hindfoot varus (7). In the study by Chittaranjan *et al*, the muscle was found in one patient at surgery and was released at its insertion (4). The discovery of the accessory soleus muscle in association with clubfoot deformity was incidental in all the reported cases (4,7). Turco noted the presence of an accessory soleus muscle in sixteen feet (6.6 %) in an overall series of 240 operations. The accessory soleus was attached to the calcaneus or to the intrinsic flexors of the toe. In three feet the muscle was so well developed that it was transferred to the tendo Achillis. A well developed plantaris muscle was also present in two (24).

In all our patients, the discovery of the accessory soleus muscle was also incidental during surgery. In all of the 20 feet, despite performing a complete tendo Achillis tenotomy, the equinus persisted. The correction of this deformity was possible only after tenotomy of the accessory muscle at the insertion. The muscle was present deep and medial to the Achilles tendon.

Recognition of an accessory soleus muscle is an issue that needs to be addressed. Pre-operatively, in children with a clubfoot, there is no recognizable swelling in the ankle region as seen in adolescents and adults. This swelling in adults is possibly due to the increase in muscle mass during adolescence and early adulthood (3). The relevance of awareness about the accessory soleus muscle is more pertinent, particularly with conservative methods of clubfoot management requiring additional minimal surgery, like the Ponseti method (20) and the physical functional treatment method (23).

REFERENCES

1. **Bejjani FJ, Jahss MH.** Le Double's study of muscle variations of the human body. Part I: Muscle variations of the leg. *Foot Ankle*, 1985 ; 6. (part I) : 111-134.
2. **Bonnel J, Cruess RL.** Anomalous insertion of the soleus muscle as cause of the fixed equinus deformity : a case report. *J Bone Joint Surg* 1969 ; 51-A : 999-1000.
3. **Brodie JT, Dormans JP, Gregg JR, Davidson RS.** Accessory soleus muscle : a report of 4 cases and review of literature. *Clin Orthop Relat Res* 1997 ; 337 : 180-187.
4. **Chittaranjan BS, Babu NV, Abraham G.** Accessory soleus muscle, a problem of awareness. *Aust NZ J Surg* 1994 ; 64 : 503-509.
5. **Chotigavanichaya C, Scaduto AA, Jadhav A, Otsuka NY.** Accessory soleus muscle as a cause of resistance to correction in congenital clubfoot : a case report. *Foot Ankle Int* 2000 ; 21 : 948-950.
6. **Christodoulou A, Terzidis I, Natsis K, Gigis I, Pournaras J.** Soleus accessorius, an anomalous muscle in a young athlete : case report and analysis of the literature. *Br J Sports Med* 2004 ; 38 (6) : e38.
7. **Danielsson LG, EL-Haddad I, Sabri T.** Clubfoot with supernumerary soleus muscle. *Acta Orthop Scand* 1990 ; 61 : 371-373.
8. **Downey MS, Siegeman J.** Accessory soleus muscle : a review of the literature and case report. *J Foot Ankle Surg* 1996 ; 35 : 537-543.
9. **Dunn AW.** Anomalous muscles simulating soft-tissue tumours in the lower extremity. *J Bone Joint Surg* 1965 ; 47-A : 1397-1400.
10. **Gordon SL, Matheson DW.** The accessory soleus. *Clin Orthop Relat Res* 1973 ; 97 : 129-132.
11. **Herring JA.** Congenital Talipes Equinovarus. In : *Tachdjian's Pediatric Orthopedic* : WB Saunders, Philadelphia, 2002.
12. **Kendi TK, Erakar A, Oktay O, Yildiz HY, Saglik Y.** Accessory soleus muscle. *J Am Podiatr Med Assoc* 2004 ; 94 : 587-589.

13. **Kouvalchouk JF, Lecocq J, Parier J, Fischer M.** [The accessory soleus muscle : a report of 21 cases and a review of the literature.] (in French) *Rev Chir Orthop Réparatrice Appar Mot* 2005 ; 91 : 232-238.
14. **Lorentzon R, Wirell S.** Anatomic variations of the accessory soleus muscle. *Acta Radiol* 1987 ; 28 : 627-629.
15. **Lozach P, Conrad JP, Delarue P, Le Saout J, Courtois B.** [A case of an accessory soleus muscle] (in French) *Rev Chir Orthop Réparatrice Appar Mot* 1982 ; 68 : 391-393.
16. **Motto S, Holloway G.** The accessory soleus muscle. *Br. J Sports Med* 1996 ; 30 : 185.
17. **Nicholas GW, Kalenak A.** The accessory soleus muscle. *Acta Orthop Scand* 1984 ; 190 : 279-280.
18. **Paul MA, Imanse J, Golding RP, Koomen AR, Meijer S.** Accessory soleus muscle mimicking a soft tissue tumor. *Acta Orthop Scand* 1991 ; 62 : 609-611.
19. **Ponseti IV, Smoley EN.** Congenital clubfoot : the results of treatment. *J Bone Joint Surg* 1963 ; 45-A : 261-275.
20. **Ponseti IV.** Clubfoot management. *J Pediatr Orthop.* 2000 ; 20 : 699-700.
21. **Ponseti IV.** Treatment of congenital clubfoot. Current concepts review. *J Bone Joint Surg* 1992 ; 74-A : 448-454.
22. **Sekiya S, Kumaki K, Yamada TK, Horiguchi M.** Nerve supply to the accessory soleus muscle. *Acta Anat* 1994 ; 149 : 121-127.
23. **Souchet P, Bensahel H, Themar-Noel C, Pennecot G, Csukonyi Z.** Functional treatment of clubfoot : a new series of 350 idiopathic clubfeet with long-term follow-up. *J Pediatr Orthop* 2004 ; 13-B : 189-196.
24. **Turco VJ.** Resistant congenital club foot—one-stage posteromedial release with internal fixation : A follow-up report of a fifteen-year experience. *J Bone Joint Surg* 1979 ; 61-A : 805-814.
25. **Vizkelety T, Szepesi K.** Reoperation in treatment of club-foot. *J Pediatr Orthop* 1989 ; 9 : 144-147.
26. **Yu JS, Resnick D.** Imaging of the accessory soleus muscle appearance in six patients and review of the literature. *Skeletal Radiol* 1994 ; 23 : 525-528.