



Is repeated repair of the meniscus worthwhile ?

John P. DILLON, David K. MARTIN

From Sportsmed SA, Stepney, Australia

Meniscal injuries are one of the most commonly encountered problems by orthopaedic surgeons. It is well established that meniscectomy will result in increased joint surface contact forces and the predictable progression of arthritis. The management of meniscal tears has evolved and current evidence would suggest that every attempt should be made to repair meniscal tears when appropriate. The reported success rate of meniscal repair is encouraging, but relatively little is known about the outcome of repeated repair of a re-torn meniscus. This review presents an illustrative case of a recurrent lateral meniscal tear in a young female, that has required surgical repair on three occasions over a fourteen year period. Despite recurrent tears of her lateral meniscus, the patient was symptom-free in the intervening periods and at her latest operation, her articular cartilage showed minimal evidence of chondral damage. Longer term follow-up is required to determine whether repair of a re-torn meniscus prevents the progression of degenerative changes within the knee joint that is associated with meniscectomy.

Keywords : recurrent meniscal tear ; repeated repair ; knee osteoarthritis.

INTRODUCTION

The importance of meniscal tissue has been demonstrated by the predictable development of osteoarthritis in a setting of a previous meniscectomy (3). While it was once thought to be of little significance, it is now appreciated that the meniscus

plays a part in shock absorption, proprioception, load transmission and joint stability (8). This has resulted in attempted preservation and repair of meniscal tissue, particularly in the younger more active patient, whenever possible. The deleterious effects of meniscectomy have been shown by Seedhom and Hargreaves who demonstrated increased joint surface contact forces by 350% following removal of 16-34% of the meniscus (5). While primary repair of a repairable meniscus has become the standard of care, relatively little is known about the outcome of repeat meniscal repair. While the reported success of surgical repair is less encouraging in the revision scenario, the effect of repeat repair on the onset of degenerative changes within the knee is unknown.

This review describes an illustrative case of a 16-year-old girl who first presented in 1996 with a right knee injury. This occurred following a twisting injury while dancing and she presented with episodes of recurring locking of her knee. At surgery, she was found to have a bucket handle tear of

■ John P. Dillon, MB, B Med Sc, MD, FRCS (Orth), Clinical Fellow.

■ David K. Martin, MBBS, B Med Sc(Hons), FRACS, FAOrthA, Orthopaedic Surgeon.
Sportsmed SA, Australia.

Correspondence : John P. Dillon, Sportsmed SA, 32 Payneham Road, Stepney, South Australia 5069, Australia.

E-mail : dillon.jp@hotmail.com

© 2011, Acta Orthopædica Belgica.

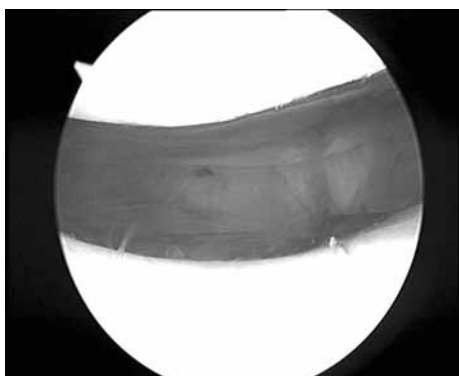


Fig. 1. — Patello-femoral joint

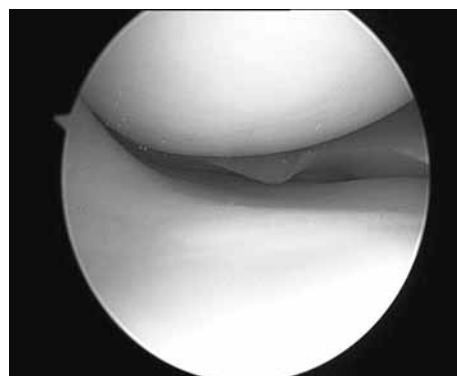


Fig. 2. — Medial compartment

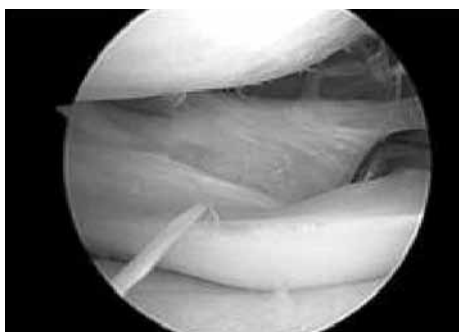


Fig. 3. — Recurrent lateral meniscal tear with minimal chondral damage.

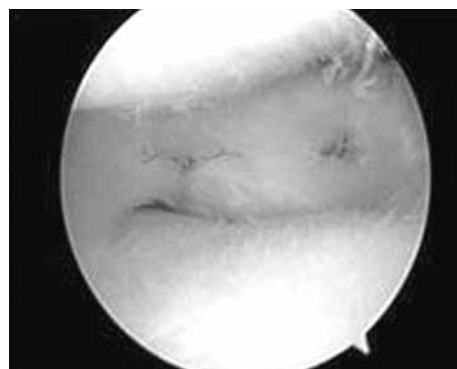


Fig. 4. — Lateral meniscal tear post repair

the posterior horn of the lateral meniscus. A postero-lateral skin incision was made and the tear repaired by an inside-out technique. She made an unremarkable recovery and re-presented five years later in 2001 with similar complaints. A further arthroscopy was performed which confirmed a recurrent bucket handle tear of the posterior horn of her lateral meniscus. The tear was posterior to the popliteal hiatus and was moderately unstable. A repair was performed with three meniscal arrows and a good recovery was made. She presented for a third time in 2010 with a few months history of locking symptoms and a further arthroscopy was performed which confirmed a recurrent lateral meniscal tear which was repaired with a FasT-Fix® Meniscal Repair device (Smith & Nephew). Arthroscopic findings revealed normal chondral surfaces with the exception of minimal fibrillation of the articular surface of the lateral femoral

condyle and no significant changes on the lateral tibial plateau (Figs. 1-4). At her last review, the patient was progressing well and had returned to sporting activities.

DISCUSSION

The management of meniscal tears has evolved over time and the techniques include open, outside-in, inside-out and all-inside repairs. However, not all meniscal tears are amenable to repair and several factors have to be taken into consideration. It is well documented that the peripheral 10-30% of the meniscus is vascularised, which provides the appropriate cellular and biochemical environment for healing. In relation to this particular case, it is worth noting that the postero-lateral aspect of the lateral meniscus is relatively hypovascular secondary to the popliteal hiatus. However, this should not be an

exclusion criterion for meniscal repair in a young patient as attempted repair is associated with a favourable outcome (4). Other factors that have to be taken into consideration are the pattern and complexity of the tear, the chronicity of the tear, the age of the patient and whether the tear is traumatic or degenerative in nature (6). Additionally, resection of the torn portion of a lateral meniscal tear has been shown to be associated with a higher rate of radiographic osteoarthritis when compared to resection of a torn portion of a medial meniscal tear and should therefore encourage surgical repair whenever feasible (1).

Several studies have looked at the healing rate of meniscal tears and documented a 90% success rate (2). However, the results of repair of a re-torn meniscus are not as encouraging. Voloshin *et al* have demonstrated a 72% survival rate with an average follow-up of 7.3 years following repair of a re-torn meniscus (7). While we cannot accurately predict the long term prognosis of repeat meniscal repair, the healthy appearance of the articular cartilage in this case is encouraging. Longer-term follow-up is required to determine whether repair of a re-torn meniscus prevents the progression of

degenerative changes within the knee joint that is associated with meniscectomy.

REFERENCES

1. **Englund M, Lohmander LS.** Risk factors for symptomatic knee osteoarthritis fifteen to twenty-two years after meniscectomy. *Arthritis Rheum* 2004 ; 50 : 2811-2819.
2. **Horibe S, Shino K, Nakata K et al.** Second-look arthroscopy after menisci repair : review of 132 menisci repaired by an arthroscopic inside-out technique. *J Bone Joint Surg* 1995 ; 77-B : 245-249.
3. **McDermott ID, Amis AA.** The consequences of meniscectomy. *J Bone Joint Surg* 2006 ; 88-B : 1549-1556.
4. **Noyes FR, Barber-Westin SD.** Arthroscopic repair of meniscal tears extending into the avascular zone in patients younger than twenty years of age. *Am J Sports Med* 2002 ; 30 : 589-600.
5. **Seedhom BB, Hargreaves DJ.** Transmission of the load in the knee joint with special reference to the role of the menisci. Part II : Experimental results, discussion and conclusions. *Eng Med* 1979 ; 8 : 220-228.
6. **Stärke C, Kopf S, Petersen W, Becker R.** Meniscal repair. *Arthroscopy* 2009 ; 25 : 1033-1044.
7. **Voloshin I, Schmitz MA, Adams MJ, DeHaven KE.** Results of meniscal repair. *Am J Sports Med* 2003 ; 31 : 874-880.
8. **Wojtys EM, Chan DB.** Meniscus structure and function. *Instr Course Lect* 2005 ; 54 : 323-330.