



Multilevel spinal fusion in the aged : not a panacea

Marc RÖLLINGHOFF, Kourosh ZARGHOONI, Daniel GROOS, Jan SIEWE, Peer EYSEL, Rolf SOBOTTKE

From the University of Cologne, Cologne, Germany

The authors conducted a retrospective study on the outcome after multilevel spine fusion in elderly patients. Seventy-two out of 80 patients were available after a mean follow-up period of 29.4 months. There were 47 females and 25 males. Their mean age at operation was 68.7 years, which means that many complaints may have been due to an underlying osteoporosis, unresponsive to surgical treatment, and exposing to loosening of the implants. The outcome was indeed rather poor : only 50% of the patients were satisfied. VAS and ODI improved slightly, but not significantly. Implant loosening was the main complication : it occurred in 35 patients, but necessitated re-operation in only 8. Adjacent segment degeneration (ASD) occurred in 26 patients, and necessitated re-operation in 17. This study should be a warning against an interventionist attitude in older patients with so-called spondylosis, where osteoporosis should be excluded and, if present, should be treated as a first step.

Keywords : multilevel fusion ; spine ; implant loosening ; adjacent segment degeneration.

INTRODUCTION

Lumbar fusion has become popular in the last decades as the standard surgical treatment for a variety of spine conditions, ranging from degenerative disc disease to high-grade spondylolisthesis. Various methods for achieving successful fusion have been suggested. No particular technique has as yet been demonstrated to yield superior results (9,11,20), and all techniques are associated

with complications (11,15,25). When considering operative treatment, multilevel degenerative diseases of the lumbar spine pose a significant problem regarding length of spondylodesis and considerations above the level of fusion (12,16,22). Unfortunately, spinal fusion alters the normal biomechanics of the spine, and loss of motion at the fused levels is compensated for by increased motion at the remaining, non-fused segments (17), leading to adjacent segment degeneration (ASD). Moreover, failed back surgery syndrome (FBSS), implant failure, and/or pseudarthrosis (3,4,11,15) are classical complications. As a result, disc arthroplasty and dynamic stabilization techniques have been developed, hoping that technology might prevent degeneration of adjacent segments (6). The prevalence of ASD has been reported in more than 30% of patients (9,15,16) undergoing lumbar fusion.

-
- Marc Röllinghoff, MD, Orthopaedic Surgeon.
 - Kourosh Zarghooni, MD, Orthopaedic Surgeon.
 - Daniel Groos, Medical Student.
 - Jan Siewe, MD, Orthopaedic Surgeon.
 - Peer Eysel, MD, PhD, Professor of Orthopaedic Surgery.
 - Rolf Sobottke, MD, Orthopaedic Surgeon.
- Department of Orthopaedic and Trauma Surgery,
University of Cologne, Cologne, Germany.*
- Correspondence : M. Röllinghoff, Department of Orthopaedic Surgery, University of Cologne, Joseph-Stelzmann Straße 9, 50924 Köln, Germany.
- E-mail : marc.roellinghoff@gmx.de
© 2011, Acta Orthopædica Belgica.
-

Predisposing patient factors are age, obesity, preexisting degeneration of the adjacent discs, menopause, and sacral inclination (1,6,10). Predisposing surgical factors include length of fusion, implant stiffness, radical decompression, loss of lumbar lordosis, and sagittal and coronal imbalance (26).

The number of lumbar spinal fusions performed has increased dramatically in recent years (7), and most studies report good results (13,28). However, few studies address the issue of unsatisfactory results with high complication rates (9,11,19,20). The aim of the current study was to use well-defined and validated criteria to examine patients undergoing multilevel fusion for degenerative spine disease, with special emphasis on serious complications. It underscores that indications for this surgical intervention should be limited, certainly in the elderly.

MATERIALS AND METHODS

Inclusion criteria for this retrospective study were: 1. multiple verifiable degenerative changes of the lumbar spine (Table I), 2. low back pain (LBP) lasting longer than one year, 3. previous conservative treatment, and 4. posterior fusion of three or more lumbar (and possibly thoracic) segments (Fig. 1), with or without interbody fusion (see further). Between 2002 and 2008, 80 patients underwent multilevel fusion of at least three segments for degenerative lumbar spine disease. Eight patients (10%) were lost to follow-up, leaving 72 patients: their mean age at the time of surgery was 68.7 ± 4.8 years (range: 46-81 years), with a mean follow-up of 29.4 ± 5.4 months (range: 15.6-71.8 months). There were 47 women, with an average age of 68 years, and 25 males with an average age of 65 years. Five of the 72 patients died from circulatory collapse without requiring revision surgery. Most often 3 segments (20 patients) or 4 segments (17 patients) were fused (Fig. 1).

Flexion-extension as well as standing radiographs of the lumbar spine were carried out in two planes, in all patients. Spinal canal stenosis (Table I) was determined by magnetic resonance imaging or computed tomography in combination with clinical examination. Instability of intervertebral segments was defined as sagittal translation of 4 mm or more (21). Postoperative radiographs were evaluated for quality of intervertebral osseous

Table I. — Diagnosis on admission (n = 72)

Diagnosis	N	%
Spinal stenosis	17	24
Degenerative scoliosis	18	25
Instability/spondylolisthesis	17	24
Osteochondrosis	13	17
Post nucleotomy syndrome	4	6
Collapsing spine	3	4
Total	72	100

fusion and implant position. Seams around pedicle screws were considered a sign of implant loosening. Successful fusion was defined as an adequate intervertebral, posterior or posterolateral bone mass, without movement on flexion-extension radiographs. Because of the increased radiation exposure, routine CT scans were performed only when pseudarthrosis or implant failure were suspected. Adjacent disc degeneration was graded using the Weiner classification (30). *Radiographic ASD* was defined by the development of spondylolisthesis > 4 mm, segmental kyphosis > 10°, complete collapse of the disc space, or by a deterioration in the Weiner classification of 2 or more grades (6). *Clinical ASD* was defined as symptomatic spinal stenosis, mechanical back pain, or symptomatic sagittal or coronal imbalance. The radiographs were analyzed independently by one of the authors and a consultant radiologist. In addition to the radiographic analysis, the patients' medical records were analyzed to determine the nature and extent of postoperative complaints.

The operation was performed by one of three senior spine surgeons. All 72 patients were operated upon in the prone position; the 24 requiring decompression with the hips in approximately 100° of flexion (26). Three techniques were used: 1. posterolateral spondylodesis with pedicle screws plus rods with allogenic femoral head grafts over decorticated facets and transverse processes (34 patients or 47%); 2. posterior spondylodesis with pedicle screws combined with ALIF and autologous iliac bone grafts (26 patients or 34%); and 3. posterior spondylodesis with pedicle screws combined with ALIF and titanium cages (12 patients or 17%). The same transpedicular fixation device was used in all cases: the ART instrumentation system (Advanced Medical Technologies AG, Nonnweiler, Germany). Twenty-four of these 72 patients underwent additional decompression because of spinal canal or foraminal stenosis; this included bilateral laminotomy and foraminotomy. As a

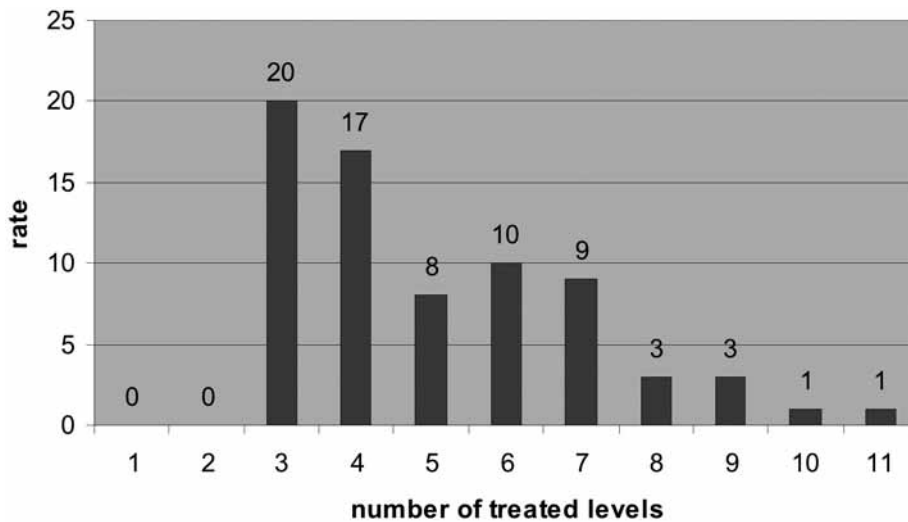


Fig. 1. — Frequency distribution of multilevel fusions

rule, patients over 70 years and patients with serious cardiac disease underwent posterolateral spondylodesis alone, while younger patients without serious concomitant illness underwent posterior spondylodesis with ALIF.

The authors, members of the international “Spine Tango” spine register, used the “Spine Tango” questionnaire, based on the Oswestry Disability Index (ODI) (29). Also a 10 cm Visual Analog Scale (VAS) was used: unbearable back pain was recorded as 10. Both tests evaluated the patients’ condition preoperatively, postoperatively, and after a mean of 29.4 months, but always retrospectively.

All results were assessed by two different investigators and averaged when necessary. The data were expressed as mean \pm standard deviation (SD). Comparison between two groups was made with the Mann-Whitney-Wilcoxon test. Results were considered significant when the p-value was less than 0.05. All statistical analyses were performed using SPSS 15.0 (SPSS 15.0, Inc. Chicago, Illinois, USA).

RESULTS

Clinical outcome

Only 50% of the patients were pleased with the outcome after surgery. VAS and ODI did not decrease significantly ($p > 0.05$) (Table II). There was no significant difference in either clinical or radiographic outcome and complication rates

between the three operative techniques used. The fusion rate was 90.2%; in the literature fusion rates vary from 77 to 100% for lumbar fusion (8,18,24,31). There was no significant correlation between a solid osseous fusion and VAS or ODI scores. Patients with radiographic ASD had worse ODI scores than the patients without, at follow-up after 29.4 months (54.7% vs 36.6%; $p < 0.001$).

Complications

Altogether, there was a high rate of complications (Table III). Thirty-five out of 72 patients (48%) showed signs of pedicle screw loosening, especially at S1 (74%). However, only 8 of these 35 patients complained of corresponding back pain and needed re-operation. Pedicle screw breakage occurred in 3 patients at L5 and S1, without clinical relevance; screw displacement lateral to the vertebral body in 3 other patients, also without clinical relevance. Implant loosening and breakage occurred as well in case of successful fusion as in case of pseudarthrosis. Adjacent segment degeneration was noted in 26 out of 72 patients (36%), of whom 17 were symptomatic. Most ASD’s occurred proximal to the fusion area (24 out of 26). Distally, there was only one case at L4/L5 and another one at L5/S1.

Table II. — Clinical outcome : slight improvement but not significant

	preoperatively	postoperatively	after +/- 29 months
VAS	8.7 ± 1.4	7.5 ± 1.7	5.7 ± 3.2
ODI	58.2 ± 23.3	54.7 ± 17.3	46.3 ± 24.4

Table III. — Complications

	N	%
Implant loosening	35 (8 symptomatic)	48
Pedicle screw breakage	3	4
Pedicle screw dislocation	3	4
Adjacent segment degeneration (but only 17 symptomatic)	26 (17 symptomatic)	36
Sensory damage	10	14
Motor damage	7	10
Iliac crest pain	5	7
Wound infection	5	7
Thrombosis	2	3
Pulmonary embolus	1	1
Defecation problems	1	1
Urinary problems	1	1

Neurologic complications : 10 out of 72 patients (14%) exhibited sensory damage with paraesthesiae in the lower limb ; 7 out of 72 patients, or 10%, had motor damage as to foot extension (3), foot flexion (2), and hip flexion (2). Six of these 17 neurologic complications occurred after iliac crest grafting, 4 after spinal canal decompression, 4 after correction of extreme lumbar scoliosis, and 3 one year after surgery because of adjacent segment spinal canal stenosis. Autologous bone graft harvesting from the iliac crest is often associated with persistent pain, meralgia paresthetica, or deep wound infection (2). The type of fusion (i.e. posterior alone or 360° fusion) did not influence the occurrence of sensory/motor damage or adjacent segment disease. Wound infection, thrombosis, pulmonary embolism, defecation problems and urinary problems were noted in 10 cases or 14%, which corresponds to the numbers reported in the literature after fusion surgery (11,25).

Revision surgery

Revision surgery was necessary in 26 out of 72 patients (36%) : 17 with symptomatic ASD,

necessitating extension spondylodesis, 8 with persistent back pain due to implant loosening, necessitating replacement, and one with deep infection necessitating implant removal (4%).

DISCUSSION

Clinical outcome

The clinical outcome after multilevel spinal fusion in these elderly patients was deceiving : VAS and ODI barely improved, while only 50% of the patients were satisfied. Osteoporosis, unresponsive to surgical treatment, might have been the deeper cause of pain in many of them. In addition, osteoporosis certainly played a role in loosening of the implants. Of course, a number of studies have reported good clinical outcomes after lumbar fusion (18,23,24,33), but others report even higher complication rates than ours, ranging from 27 to 51% per technique, with re-operation rates from 10 to 40% (9,14,19,20). The classical posterolateral fusion and the 360° fusion groups did not lead to significantly different clinical or radiographic

outcomes and complication rates. These findings correlate with those of Fritzell *et al* (11), who found no significant difference between the clinical outcome of three different fusion techniques, in younger patients.

Complications

The high complication rate was impressive. Loosening was the most frequent complication, followed by Adjacent Segment Degeneration. In the literature these proportions are reversed : classically, the most common complication is ASD, followed by implant failure, or pseudarthrosis (3,4,11,15).

The authors identified radiographic signs of implant loosening in 48% of the patients (35 out of 72), but only 8 of these 35 patients showed clinical signs of implant loosening, deeming re-operation necessary. Screw fatigue occurred only at the cranial or caudal margins of the fusion, with 26 of 35 cases (74%) occurring in the S1 screws. Implant loosening is caused by leverage, particularly when the instrumentation ends at the sacrum. In the present study there was radiographic evidence of adjacent segment degeneration in 36% of the patients (26 of 72) ; these findings correlate with those of Cheh *et al* (6) and Penta *et al* (22) : respectively 42% and 32%. However, only 17 of these 26 patients needed re-operation. Posterior fusion has been blamed for ASD : degenerative changes at the level adjacent to the fused segment have been reported (10,26). Stiffness of the fusion area would lead to overload of the adjacent motion segment. Theoretically, additional instrumentation should increase stiffness and ASD, but this was contradicted by Wiltse *et al* (31). Also Cheh *et al* (6) found that circumferential fusion (360°), which would increase the stiffness even more, did not increase the incidence of ASD compared to posterolateral spondylodesis.

Revision surgery

In the current study there were two major problems requiring revision surgery. For 17 out of 72 patients, or 24%, it was ASD, and for 8 out of 72, or 11%, it was loosening. New implants might

obviate ASD, by combining rigid spondylodesis with dynamic instrumentation to the adjacent segment ("topping off"), but to date no publications confirm their efficiency.

REFERENCES

1. Aota Y, Kumano K, Hirabayashi S. Postfusion instability at the adjacent segments after rigid pedicle screw fixation for degenerative lumbar spinal disorders. *J Spinal Disord* 1995 ; 8 : 464-473.
2. Banwart JC, Asher MA, Hassanein RS. Iliac crest bone graft harvest donor site morbidity. A statistical evaluation. *Spine* 1995 ; 20 : 1055-1060.
3. Blumenthal S, Gill K. Complications of the Wiltse pedicle screw fixation system. *Spine* 1993 ; 18 : 1867-1871.
4. Bohnen IM, Schaafsma J, Tonino AJ. Results and complications after posterior lumbar spondylodesis with the "Variable screw placement spinal fixation system". *Acta Orthop Belg* 1997 ; 63 : 67-73.
5. Boucher HH. A method of spinal fusion. *J Bone Joint Surg* 1959 ; 41-B : 248-259.
6. Cheh G, Bridwell KH, Lenke LG *et al*. Adjacent segment disease following lumbar/thoracolumbar fusion with pedicle screw instrumentation : a minimum 5-year follow-up. *Spine* 2007 ; 32 : 2253-2257.
7. Davis H. Increasing rates of cervical and lumbar spine surgery in the United States, 1979-1990. *Spine* 1994 ; 19 : 1117-1123.
8. Epstein NE. Fusion rates and SF-36 outcomes after multi-level laminectomy and noninstrumented lumbar fusions in a predominantly geriatric population. *J Spinal Disord Tech* 2008 ; 21 : 159-164.
9. Esses SI, Sachs BL, Dreyzin V. Complications associated with the technique of pedicle screw fixation. A selected survey of ABS members. *Spine* 1993 ; 18 : 2231-2238.
10. Etebar S, Cahill DW. Risk factors for adjacent-segment failure following lumbar fixation with rigid instrumentation for degenerative instability. *J Neurosurg* 1999 ; 90 (2 Suppl) : 163-169.
11. Fritzell P, Hägg O, Nordwall A. Swedish Lumbar Spine Study Group. Complications in lumbar fusion surgery for chronic low back pain : comparison of three surgical techniques used in a prospective randomized study. *Eur Spine J* 2003 ; 12 : 178-189.
12. Frymoyer JW, Hanley EN Jr, Howe J, Kuhlmann D, Matteri RE. A comparison of radiographic findings in fusion and non fusion patients ten or more years following lumbar disc surgery. *Spine* 1979 ; 4 : 435-440.
13. Gibson JN, Grant IC, Waddell G. The Cochrane review of surgery for lumbar disc prolapse and degenerative lumbar spondylosis. *Spine* 1999 ; 24 : 1820-1832.
14. Greiner-Perth R, Boehm H, Allam Y, Elsaghir H, Franke J. Reoperation rate after instrumented posterior

- lumbar interbody fusion : a report on 1680 cases. *Spine* 2004 ; 29 : 2516-2520.
15. **Kumar MN, Jacquot F, Hall H.** Long-term follow-up of functional outcomes and radiographic changes at adjacent levels following lumbar spine fusion for degenerative disc disease. *Eur Spine J* 2001 ; 10 : 309-313.
 16. **Lee CK.** Accelerated degeneration of the segment adjacent to a lumbar fusion. *Spine* 1988 ; 13 : 375-377.
 17. **Lee CK, Langrana NA.** Lumbosacral spinal fusion. A bio-mechanical study. *Spine* 1984 ; 9 : 574-581.
 18. **Lemcke J, Klötzer S, Klötzer R, Meier U.** [PLIF and ALIF for the degenerative spondylolisthesis of the lumbar spine.] (in German). *Z Orthop Ihre Grenzgeb* 2007 ; 145 : 48-54.
 19. **Ohlin A, Karlsson M, Düppe H et al.** Complications after transpedicular stabilization of the spine. A survivorship analysis of 163 cases. *Spine* 1994 ; 19 : 2774-2779.
 20. **Okuyama K, Abe E, Suzuki T et al.** Posterior lumbar interbody fusion : a retrospective study of complications after facet joint excision and pedicle screw fixation in 148 cases. *Acta Orthop Scand* 1999 ; 70 : 329-334.
 21. **Park P, Garton HJ, Gala VC et al.** Adjacent segment disease after lumbar or lumbosacral fusion : review of the literature. *Spine* 2004 ; 29 : 1938-1944.
 22. **Penta M, Sandhu A, Fraser RD.** Magnetic resonance imaging assessment of disc degeneration 10 years after anterior lumbar interbody fusion. *Spine* 1995 ; 20 : 743-747.
 23. **Riesner HJ, Matzen KA, Mlinaric M, Wild A.** [Therapeutic efficiency in multisegmental fusions of the lumbar spine.] (in German). *Z Orthop Unfall* 2008 ; 146 : 444-451.
 24. **Rompe JD, Eysel P, Hopf C.** Clinical efficacy of pedicle instrumentation and posterolateral fusion in the symptomatic degenerative lumbar spine. *Eur Spine J* 1995 ; 4 : 231-237.
 25. **Röllinghoff M, Siewe J, Eysel P, Delank KS.** Pulmonary cement embolism after augmentation of pedicle screws with bone cement. *Acta Orthop Belg* 2010 ; 76 : 269-273.
 26. **Schlegel JD, Smith JA, Schleusener RL.** Lumbar motion segment pathology adjacent to thoracolumbar, lumbar, and lumbosacral fusions. *Spine* 1996 ; 21 : 970-981.
 27. **Schöllner D, Szöke N.** [A new positioning board in the preparation for surgery.] (in German). *Z Orthop Ihre Grenzgeb* 1985 ; 123 : 422-423.
 28. **Turner JA, Ersek M, Herron L et al.** Patient outcome after lumbar spinal fusion. *JAMA* 1992 ; 268 : 907-911.
 29. **Vianin M.** Psychometric properties and clinical usefulness of the Oswestry Disability Index. *J Chiropr Med* 2008 ; 7 : 161-163.
 30. **Weiner DK, Distell B, Studenski S et al.** Does radiographic osteoarthritis correlate with flexibility of the lumbar spine ? *J Am Geriatr Soc* 1994 ; 42 : 257-263.
 31. **Wiltse LL, Radecki SE, Biel HM et al.** Comparative study of the incidence and severity of degenerative change in the transition zones after instrumented versus noninstrumented fusions of the lumbar spine. *Spinal Disord* 1999 ; 12 : 27-33.
 32. **Zdeblick TA.** A prospective, randomized study of lumbar fusion. Preliminary results. *Spine* 1993 ; 18 : 983-991.
 33. **Zouboulis P, Karageorgos A, Dimakopoulos P et al.** Functional outcome of surgical treatment for multilevel lumbar spinal stenosis. *Acta Orthop* 2006 ; 77 : 670-676.