



Osteochondral allograft transplantation after excision of femoral head giant cell tumour : A case report

Ramesh K. SEN, Sujit K. TRIPATHY, Dharm S. MEENA, Nalini GUPTA

From the Postgraduate Institute of Medical Education and Research, Chandigarh, India

We report a case of Giant Cell Tumour of the femoral head in a 22-year-old man that was excised and reconstructed with an osteochondral allograft. After 3.5 years follow-up, the graft had completely united and there were no signs of recurrence or resorption ; the patient had an excellent functional outcome. Osteochondral allograft transplantation may provide a viable option for joint salvage after excision of a benign or locally aggressive tumour in the femoral head in selected cases.

Keywords : giant cell tumour ; benign bone tumour ; osteochondral allograft ; femur head.

INTRODUCTION

Giant cell tumour (GCT) of bone is classically described as a locally aggressive tumour that commonly occurs at the end of long bones. Approximately 50% of GCTs are located around the knee joint, with the distal femur as the most frequent site followed by the proximal tibia (1,6,12) ; the proximal humerus and distal radius represent the third and fourth most common sites. The proximal femur is an uncommon site for this rare tumour (17). Mirra has reported less than 4% incidence of GCT at this anatomical site (11). GCT in the femur head is extremely rare, with a handful of cases in literature (2,10,14,15,17). There is no specific form of treatment for GCT at this uncommon site. Tibrewal treated four cases of femoral head and neck GCT with curettage and bone grafting.

However there was recurrence in all cases within two years of surgery and ultimately they needed arthroplasty. He concluded that primary arthroplasty should be considered as the treatment of choice for GCT at the femoral head and neck (17).

Because GCT often occurs in young adults (in the third and fourth decades) with a normal life expectancy, a durable and functional resection with low risk of recurrence is essential. Sacrificing the hip joint and implanting an artificial prosthesis in a young individual have severe functional limitations. The age old idiom of 'joint conservation' should be considered even for this rare tumour of the femoral head and neck (2). We report a case of GCT of the femoral head (Campanacci grade II) that we excised completely and the defect of femoral head was reconstructed successfully with

-
- Ramesh K. Sen, M.S., DNB, PhD, Additional Professor.
 - Sujit K. Tripathy, M.S., DNB, Dip SICOT, MNAMS, Senior Resident.
 - Dharm S Meena, Junior Resident.
Department of Orthopaedics, Postgraduate Institute of Medical Education and Research, Chandigarh.
 - Nalini Gupta, MD, Additional Professor.
Department of Cytopathology, Postgraduate Institute of Medical Education and Research, Chandigarh.

Correspondence : Dr Sujit Kumar Tripathy, Senior Resident, Department of Orthopaedics, Postgraduate Institute of Medical Education and Research, Sector-12, Chandigarh-160012, India. E-mail : sujithortho@yahoo.co.in

© 2011, Acta Orthopædica Belgica.

an osteochondral allograft. This appears to be the first report of allograft implantation in the femoral head after GCT excision.

CASE REPORT

A 22-year-old young man presented with a 3 months history of pain about the right hip joint and a limp. The problem started insidiously with mild pain in the hip joint, which gradually increased in severity. The pain was radiating to the thigh. There was no history of trauma, fever, loss of appetite, weight loss, night cries, tubercular contact, birth abnormalities or any childhood illness. On clinical examination there was no swelling palpable around the hip joint. Mild joint line tenderness was elicited over the anterior aspect of the hip. The ranges of flexion, extension and abduction movements of the hip were similar to the other side. However the terminal 20° of flexion were painful. Adduction of the hip joint was extremely painful and was limited to 10°. Both internal and external rotations were painful and were 10° less compared to the opposite side. Bilateral femoral pulses were equally palpable and there was no limb length discrepancy. There were no lymphadenopathy and neurological deficit.

Radiographs of the pelvis with both hip joints showed a large eccentric osteolytic lesion in the lower half of the right femoral head (Fig. 1). Computed tomogram and magnetic resonance imaging of the hip joint further delineated the extent of the lesion (Fig. 2 & 3). The lesion was hypointense on T1WI and measured about 5.2 × 3.3 cm. No soft tissue involvement was noted (Fig. 3). The haemogram and calcium profile of the patient were within normal limits. Skeletal survey could not isolate any other lytic or sclerotic focus. These radiologic pictures raised the possibility of aneurysmal bone cyst or giant cell tumour in this atypical site.

Histological confirmation of the diagnosis was obtained by performing a needle biopsy under CT guidance. The histological picture showed multinucleated giant cells (10-30 nuclei) admixed with stromal fragments in a background of blood. The nuclei of stromal cells and multinucleated giant

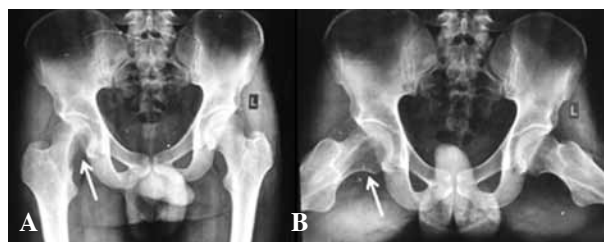

Fig. 1A,B. — Antero-posterior and lateral radiographs of pelvis with bilateral hip joints show a large radiolucent lesion in the inferior part of the femoral head on the right side.

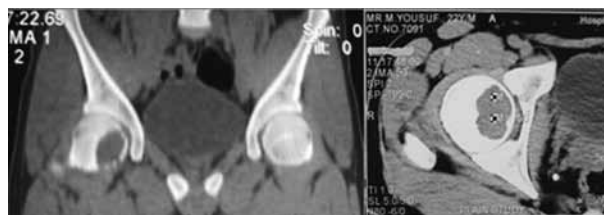

Fig. 2. — Coronal and trans-axial cut sections of Computed Tomographic scan delineates the femoral head lesion.

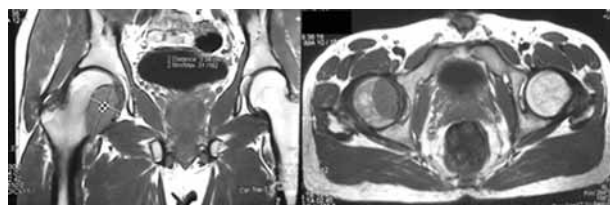


Fig. 3. — Magnetic resonance imaging (sagittal and trans-axial cut sections) clearly delineates the extent of the lesion with low to intermediate intensity signal on T1W image without any signal changes in the surrounding soft tissues.

cells had similar morphology (vesicular chromatin with inconspicuous nucleoli). The tumour cells were mitotically active, but no cellular atypia or necrosis was noticed in the field. The diagnosis of Giant Cell Tumour was confirmed.

We discussed all the surgical options, i.e., en-bloc tumour resection followed by arthroplasty/arthrodesis or joint conservation using osteochondral allograft with the patient. Considering the young age, hip arthroplasty was not deemed appropriate for the patient. Because of the associated morbidity with hip arthrodesis (difficulty in sitting, kneeling, squatting and abnormal gait pattern), the

patient did not consent for it. Ultimately, we decided to go for a joint conservation procedure and planned excision of the tumour followed by allograft transplantation. The patient consented to undergo this surgical procedure. The lesion was accessed through the Smith Petersen approach. The joint was dislocated anteriorly. The tumour was clearly visible in the inferior part of the femoral head. The overlying cartilage was soft, like a membrane. The lesion was further demarcated using image intensifier. A 5 mm margin surrounding the lesion was marked for en bloc resection of the tumour. The lesion along with 5 mm cuff of normal surrounding bone was excised with a sharp thin osteotome. This method of resection avoided the possibility of spillage of the tumour in the surgical field. Bone biopsy from the excised margin of the parent bone was taken for histological examination to make sure there was a negative tumour margin. On cut section of the tumour, dark haemorrhagic necrotic tissues were found. After the excision of the tumour, there was a large defect in the inferior part of the femoral head.

We took a fresh-frozen femoral head allograft from our bone bank; its diameter was almost identical to that of the patient's femoral head. This allograft was appropriately cut (with the help of vibrating saw and bone nibbler) to provide a shape that would match with the remaining part of the femoral head of the patient to form a sphere. The graft was fixed to the femoral head with a partially threaded cancellous screw (3.5 mm), inserted from the non articular side. The screw head was buried inside the osteochondral allograft articular cartilage. The wound was closed in layers over a suction drain.

Postoperative recovery was uneventful and immobilisation was done for 6 weeks. The biopsy samples from the tumour margin did not show any remnant of tumour. Skin traction was applied to the lower limb in an abducted position. This method of immobilization kept the joint distracted and avoided undue force over the graft. Active hip joint flexion and extension in abducted position (with traction *in situ*) was initiated within the first week. Bedside mobilisation was started after three weeks. After 6 weeks, partial weight bearing was allowed

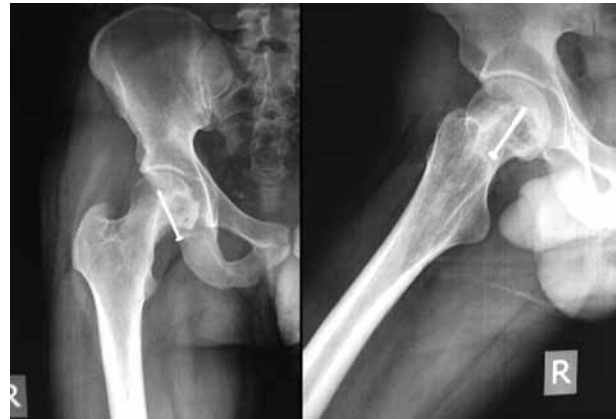

Fig. 4. — Three and half years after excision of the tumour and allograft reconstruction of the defect, radiographs show graft union without signs of recurrence.

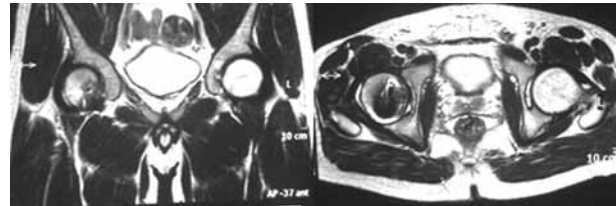


Fig. 5. — Three and half years after surgery, no recurrence was noted even on magnetic resonance imaging (sagittal and trans-axial cut sections).

with the help of crutches. Full weight bearing was restricted until radiologic evidence of union was noted. The graft had completely united at the end of three months. After three and a half years, the patient had a painless normal range of movement around the hip joint and there was no radiological evidence of graft resorption or recurrence (Fig. 4, 5). The Harris Hip Score improved to 100 from the initial score of 54 (9). The functional score of the International Society of limb salvage was 30 (maximum) (5).

DISCUSSION

The treatment of GCT is directed towards local control without sacrificing joint function. Curettage and bone grafting remains the standard method of treatment in most cases of benign GCT's. However

Table I. — Management of GCT of femoral head and/or neck as reported in literature

Study	No of cases	Treatment method	Follow up	Recurrence	Management of recurrence
Tibrewal <i>et al</i> (1986)	4	Curettage and BG	> 2 years	4 (100%)	THA
Sim and Lang (1995)	One	Valgus osteotomy, curettage, BG and DHS	35 months	–	–
Kulkarni <i>et al</i> (1996)	One	THA	32 months	–	–
Sakayama <i>et al</i> (2007)	7	2 curettage with cement	90.5 months	2 recurrences	THA
		4 THA/BHA	77.5 months	–	–
		1 arthrodesis	178 months	–	–
Cho <i>et al</i> (2010)	12	Curettage and BG/ cement	58.3 months	5 (41.7%)	3 repeat curettage and 2 THA

BG : Bone Grafting, DHS : Dynamic Hip Screw, THA : Total Hip Arthroplasty, BHA : Bipolar Hip Arthroplasty.

intralesional curettage often leaves microscopic remnants of the tumour and it recurs in more than 10% of cases. Marginal or wide excision provides better chance of cure with minimal recurrence (13). As the involvement of GCT is epiphyseo-metaphyseal, such treatment often sacrifices the articular surface leading to disability, deformity and more complex reconstructive procedure (2).

Femoral head GCT is an extremely uncommon occurrence and there are no standard treatment guidelines. Unlike other areas, GCT at this site may have more devastating outcome. GCT by producing an osteolytic defect in the femoral head weakens the bone and predisposes to pathological fracture. There are other problems such as high chances of recurrence, difficulty in accessibility and chances of vascular compromise to the femur head with the surgical approaches. The tumour in the neck and trochanteric region of the proximal femur can be curetted/ excised with the support of a fixed angle device that withholds mechanical loading over the weakened part of the proximal femur. However this is not applicable for the femoral head as it is the most proximal part of the femur and bears direct mechanical load. Hence an urgent attention is necessary to prevent pathological fracture and preserve the joint function. As stressed by Puri *et al*, the joint conservation should be attempted with equal impor-

tance of local disease control (13). In an attempt to preserve the hip joint with curettage and bone grafting, Tibrewal failed and found recurrence in all of his four cases which eventually needed arthroplasty (17); Kulkarni *et al* treated a case of GCT in the femoral head and neck with Charnley arthroplasty. The presentation of the patient in that case was with pathological transcervical neck fracture (10). Cho *et al* also found a high rate of recurrence in the femoral head and neck GCTs; five of twelve hips had recurrence in their series. Despite a high recurrence rate, they stressed on joint conservation and concluded that curettage should be considered as the primary treatment (2). Several procedures such as atraumatic surgical dislocation, trapdoor procedure and endoscopic excision have been reported in literature; the aim of all these surgical procedures is to decrease the risk of local recurrence of GCT and preserve the femoral head (2).

If we analyse the studies as mentioned in table I, 13 out of 25 GCTs of the femoral head and neck ultimately needed arthroplasty. It seems that intralesional curettage is ineffective in controlling the local disease at this particular site. Though it is possible to cure the disease with marginal or wide resection, it leaves a large defect in the femoral head. Osteochondral allograft is a good substitute to fill the defect; the use of this allograft has been

reported in non-tumorous condition (osteonecrosis) of the femoral head. The concept of frozen-allograft transplantation in tumorous condition of the femur head was first reported in a chondroblastoma (16). The present case appears to be the first where a frozen allograft could be successfully implanted in the femoral head after excision of a GCT. The graft incorporated well into the parent bone after 3 months and the patient was completely asymptomatic even after 3.5 years. Although the use of osteochondral allografts has been widely reported in tumorous conditions of other locations (proximal tibia, distal femur etc), the literature is silent about its use in tumorous conditions of the femur head and neck. As mentioned earlier, difficulty in accessibility, proximity to a major weight bearing joint, need for a small volume of graft (difficult to prepare), fixation problem and providing proper shape (spherical) to the graft, are the major limitations for its use at this anatomical site.

Fresh frozen allograft as used in the present case is not completely safe. There is risk of transmission of many bacterial and viral diseases including HIV, hepatitis B or C. American Association of Tissue Banks has established guidelines to preserve osteochondral graft in the bone bank and all bone banks should strictly follow these guidelines to avoid biological hazards. The laboratory processing in our institution strictly adheres to these guidelines. Despite that, a written informed consent should be obtained from the patient before use of an osteochondral allograft. Other than infection, the allograft also poses risks of non-union, fracture and graft resorption (4).

Though slower, the stages of allograft incorporation are the same as those defined for autograft. Goldberg and Stevenson (7) described five basic stages : inflammation, vascularization, osteoinduction, osteoconduction, and remodeling. The graft functions mainly as a scaffold for bony ingrowth (4). Considering the different stages of autograft and allograft incorporation, we have sufficient follow-up to say that the graft is unlikely to go resorption in the future. The defect in our case was on the inferior aspect of the femoral head and there is no risk of collapse and further arthritis. Rather, the graft provided structural support to the

weakened femoral head and neck in the present case and hence the risk of pathologic fracture was avoided.

In fixation of an allograft to the femoral head, every effort should be made to restore articular congruency to prevent development of arthritis. The frozen femoral head allograft in this case was prepared perfectly to match with the defect and complete joint congruency was restored. Ideally the screw should be bioabsorbable or titanium made, so that magnetic resonance imaging of the hip joint can be safely performed in the future. Because of the poor affordability we had fixed the allograft with a stainless steel screw. No part of the screw should protrude into the joint and ideally it should be inserted from the non-articular side. If it is necessary to insert it from the articular side, use of a headless Herbert or Accutrak screw should be considered and it should be buried inside the cartilage. As previously mentioned surgical approach to the femur head is of utmost importance to preserve the vascularity of the femoral head. The anterior Smith Petersen approach and anterior dislocation allow better accessibility with minimal vascular compromise (8). Even after 3.5 years of follow-up we have not noted any signs of osteonecrosis in the present case.

As per the literature, majority of recurrences (80%) occur within the first two years. Hence regular radiographic follow-up every 6 months is recommended till two years. After that, an annual visit is recommended during the ensuing ten years (13). The index case had 3.5 years of follow-up till this report and he is still under our follow-up. The risk factors for recurrence as outlined by Devita *et al* (3) include pathologic fracture, stage III disease, anatomic site and the use of adjuvant treatment. Maximum recurrences are usually seen in GCTs of the distal radius (50%) and proximal tibia (28%). As per the literature, the chances of recurrence in Campanacci grade I and II GCTs are usually 7%, whereas it is about 29% in grade III that involves the overlying soft-tissue. The patient reported had a grade II GCT without pathological fracture, hence less chance of recurrence. Again, the tumour was excised en bloc and the biopsy from the excised margin did not reveal any tumour remnant.

This case report demonstrated the successful use of an osteochondral allograft in femoral head reconstruction after excision of a locally aggressive tumour in the femoral head.

REFERENCES

1. **Campanacci M, Baldini N, Boriani S, Sudanese A.** Giant cell tumour of bone. *J Bone Joint Surg* 1987 ; 69-A : 106-114.
2. **Cho HS, Park IH, Han I, Kang SC, Kim HS.** Giant cell tumour of the femoral head and neck : result of intralesional curettage. *Arch Orthop Trauma Surg* 2010 ; 130 : 1329-1333. DOI 10.1007/s00402-009-1026-2
3. **DeVita VT, Lawrence TS, Rosenberg SA, DePinho RA, Weinberg RA.** Giant cell tumor of bone. In : *DeVita, Hellman, and Rosenberg's Cancer : Principles and Practice of Oncology*, 8th ed. Lippincott Williams & Wilkins, Philadelphia, 2008.
4. **Douglas E, Alexander V.** The use of allograft bone in lumbar spine surgery. *Clin Orthop Relat Res* 2000 ; 371 : 38-45.
5. **Enneking WF, Dunham W, Gebhardt MC, Malawar M, Pritchard DJ.** A system for the functional evaluation of reconstructive procedures after surgical treatment of tumours of the musculoskeletal system. *Clin Orthop Relat Res* 1993 ; 286 : 241-246.
6. **Goldenberg RR, Campbell CJ, Bonfiglio M.** Giant cell tumour of bone. An analysis of two hundred and eighteen cases. *J Bone Joint Surg* 1970 ; 52-A : 619-64.
7. **Goldberg VM, Stevenson S.** Natural history of autografts and allografts. *Clin Orthop Relat Res* 1987 ; 225 : 7-16.
8. **Guo JJ, Tang N, Yang HL, Qin L, Leung KS.** Impact of surgical approach on postoperative heterotopic ossification and avascular necrosis in femoral head fractures : a systematic review. *Int Orthop* 2010 ; 34 : 319-322.
9. **Harris WH.** Traumatic arthritis of the hip after dislocation and acetabular fractures : treatment by mold arthroplasty. An end-result study using a new method of result evaluation. *J Bone Joint Surg* 1969 ; 51-A : 737-755.
10. **Kulkarni SS, Dogra AS, Bhosale PB.** Total hip arthroplasty for giant cell tumour. *J Postgrad Med* 1996 ; 42 : 82-84.
11. **Mirra JM.** Giant Cell Tumour. In : Mirra JM (ed). *Bone Tumours, Clinical, Radiological and Pathological Correlations*. vol. 2. Lea and Febiger, Philadelphia, 1989 ; p 942.
12. **McDonald DJ, Sim FH, McLeod RA, Dahlin DC.** Giant cell tumour of bone. *J Bone Joint Surg* 1986 ; 68-A : 35-242.
13. **Puri A, Agarwal M.** Treatment of giant cell tumour of bone : current concepts. *Ind J Orthop* 2007 ; 41 : 101-108.
14. **Sakayama K, Sugawara Y, Kidani T et al.** Diagnostic and therapeutic problems of giant cell tumour in the proximal femur. *Arch Orthop Trauma Surg* 2007 ; 127 : 867-872.
15. **Sim E, Lang S.** Joint salvaging surgery for an extensive giant cell tumour of the proximal femur complicated by a transcervical fracture. *Arch Orthop Trauma Surg* 1997 ; 116 : 431-434.
16. **Stilli S, Marchesini Reggiani L, Boriani L, Donzelli O.** Osteochondral allograft in a femoral head chondroblastoma : a case report. *Hip Int* 2010 ; 20 : 280-283.
17. **Tibrewal SB.** Treatment of giant cell tumour of the femoral head and neck. *J R Soc Med* 1986 ; 79 : 401-404.