



## Femoral neuropathy following total hip arthroplasty Review and management guidelines

Alice J.S. FOX, Asheesh BEDI, Florian WANIVENHAUS, Thomas P. SCULCO, John S. FOX

*From the Hospital for Special Surgery, New York City, NY, USA*

**Femoral neuropathy following primary or revision total hip arthroplasty (THA) is a rare but acknowledged complication. Treatment of femoral neuropathy has long been debated and there is a paucity of accepted principles on which to base management. Currently, no definitive management protocol exists in the literature. A literature search was performed by a review of PubMed, Google Scholar and OVID articles published from 1972-2011. The literature reports an incidence rate of femoral neuropathy following THA ranging from 0.1 to 2.4 percent. Determining the precise aetiology, establishing a diagnosis and subsequent treatment of femoral nerve injury remains a difficult task, with conservative management remaining the treatment benchmark. In this review, we aim to summarise the aetiologies and risk factors associated with femoral neuropathy following THA and provide management guidelines.**

**Keywords :** femoral neuropathy ; total hip arthroplasty ; nerve palsy ; management ; review.

### INTRODUCTION

Total hip arthroplasty (THA) is a widely recognized procedure for the treatment of degenerative hip disease. THA has evolved considerably in recent years and is highly effective in relieving pain, improving function and restoring motion (11,14-16,23).

Femoral neuropathy following primary or revision THA is a rare but acknowledged complication

and represents a challenge for both the patient and orthopaedic surgeon. Treatment of femoral neuropathy has long been debated and there is a paucity of accepted principles on which to base management of this rare complication (42). Currently, no definitive management protocol exists in the literature.

A literature search was performed from PubMed, Google Scholar and OVID articles published from 1972-2011. The purpose of this study was to provide

- 
- Alice J.S. Fox, B.Med.Sc, MSc.  
*Laboratory for Soft Tissue Research, Hospital for Special Surgery, New York, NY, USA.*
  - Asheesh Bedi, MD, Assistant Professor.  
*Department of Orthopaedic Surgery, University of Michigan, Ann Arbor, MI, USA.*
  - Florian Wanivenhaus, MD.  
*Laboratory for Soft Tissue Research, Hospital for Special Surgery, New York, NY, USA.*
  - Thomas P. Sculco, MD, Surgeon-in-Chief, Professor of Orthopaedic Surgery.  
*Hospital for Special Surgery, New York, NY, USA.*
  - John S. Fox, BE MBBS FRACS(Orth) FAOrthA, Director and Consultant Orthopaedic Surgeon.  
*Department of Orthopaedics, Westmead Hospital, Westmead, NSW Australia.*

Correspondence : Alice Fox, Laboratory for Soft Tissue Research, Hospital for Special Surgery, 535 East 70<sup>th</sup> Street, New York, NY 10021, USA.

E-mail : foxa@hss.edu

© 2012, Acta Orthopædica Belgica.

a concise and detailed description of the incidence, presentation, aetiology, risk factors, prevention, treatment and prognosis associated with femoral neuropathy following THA.

## Anatomy

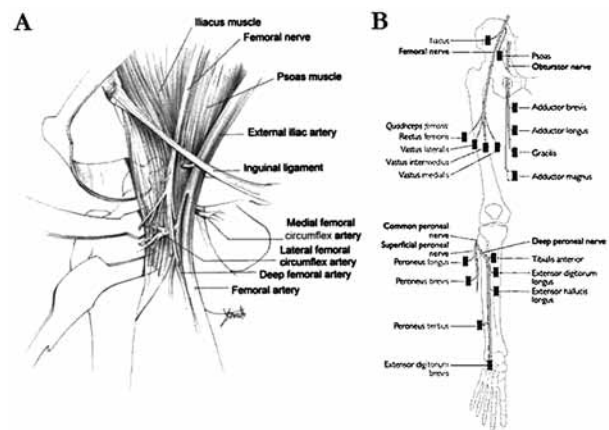
The femoral nerve is the largest branch of the lumbar plexus, arising from the dorsal divisions of the ventral rami of the second, third and fourth lumbar nerves. The nerve originates in the abdomen within the psoas major and descends postero-laterally through the pelvis to approximately the mid-point of the inguinal ligament. It then passes deep to this ligament and enters the femoral triangle, lateral to the femoral vessels. After entering the triangle, the femoral nerve divides into several branches to the hip and knee joints and provides several cutaneous branches to the anteromedial side of the thigh (Fig. 1A). The terminal cutaneous branch of the femoral nerve, the saphenous nerve descends through the femoral triangle, lateral to the femoral sheath containing the femoral vessels. The femoral nerve supplies motor innervation to the iliopsoas, pectineus, sartorius and quadriceps femoris muscles (Fig. 1B).

## Incidence

Determining the incidence of femoral nerve injury is difficult, partially because of under diagnosis. A review of the literature reports an incidence rate ranging from 0.1% to 2.4% following primary THA (mean 0.8%) and 0.3% to 2.3% following revision THA (mean 1.1%) (Table I) (3,5,6,9,10,12,13,17,24,26-28,30,31,34-36,39-41).

## Presentation

Symptoms and signs of femoral neuropathy may vary depending on both severity and location of the injury, but are characterized typically by groin or thigh pain, weakness of the iliopsoas, paralysis of the quadriceps femoris, loss of the knee jerk and sensory loss over the anteromedial aspect of the lower extremity and swelling or haematoma in the



**Fig. 1.** — A. The anterior thigh showing the neuromuscular anatomy of the femoral triangle (Reprinted with permission from Callaghan *et al.*, 2007). B. The femoral nerve and the muscle it supplies. (Reprinted with permission from Hankey & Wardlaw, Clinical Neurology, Manson Publishing, 2002).

wound or in the inguinal region (18). Patients are often able to stand and walk on flat surfaces with the usual postoperative assistive devices; however the majority of patients will experience difficulty with climbing stairs. The residual functional disability, instability and pain associated with nerve injuries may be incomplete or prolonged. Any persistent postoperative motor and sensory abnormalities may impair the rehabilitation process and adversely affect patient satisfaction.

## Aetiology

It is often difficult to ascertain the precise aetiology of femoral nerve injury following THA, partially because of a lack of reporting in the literature (19). Farrell *et al* reported that only 55% of patients had a presumably identifiable cause of the nerve injury (13), whilst Barrack reported that the aetiology was unknown in 47% of patients (1). Schmalzried *et al* reviewed 126 consecutive total hip replacements in which the cause of the nerve palsy remained unknown in 57% of cases (34). Potential mechanisms of femoral neuropathy associated with THA have been variously reported (Table II).

Table I. — Incidence of reported femoral nerve palsies in primary and revision total hip arthroplasty. An asterisk (\*) indicates data not available. No, number

Study	No. of patients	Total no. of femoral palsies (%)	No. of primary cases	Total no. of femoral palsies in primary cases (%)	No. of revision cases	Total no. of femoral palsies in revision cases (%)
Chapchal <i>et al</i> , 1973	340	2 (0.6)	340	2 (0.6)	*	*
Coventry <i>et al</i> , 1974	1684	5 (0.3)	1,684	*	328	*
Eggl <i>et al</i> , 1999	370	2 (0.5)	508	*	*	*
Eskelinen <i>et al</i> , 2006	63	1 (1.6)	75	1 (1.3)	0	0
Evarts <i>et al</i> , 1973	200	3 (0.5)	152	*	48	*
Farrell <i>et al</i> , 2005	27004	47 (0.2)	27,004	47 (0.2)	*	*
Hartofilakidis <i>et al</i> , 1998	67	1 (1.5)	*	*	*	*
Lazansky, 1973	501	3 (0.6)	403	*	98	*
Moczynski <i>et al</i> , 1973	237	4 (1.3)	155	*	82	*
Murray, 1973	808	15 (1.9)	557	10 (1.8)	251	5 (2.0)
Navarro <i>et al</i> , 1995	1000	8 (0.8)	630	3 (0.5)	370	5 (1.4)
Nercessian <i>et al</i> , 1994	7133	45 (0.5)	*	*	*	*
Oldenburg & Müller, 1997	2721	15 (0.6)	2394	*	327	*
Schmalzried <i>et al</i> , 1991	2355	43 (1.8)	1661	21 (1.3)	694	22 (3.2)
Simmons <i>et al</i> , 1991	440	10 (2.3)	360	7 (1.9)	80	3 (3.8)
Solheim & Hagan, 1980	825	1 (0.1)	*	*	*	*
Van der Linde & Torino, 1997	600	1 (0.2)	*	*	*	*
Weale <i>et al</i> , 1996	42	1 (2.4)	42	1 (2.4)	0	0
Weber <i>et al</i> , 1976	2012	14 (0.7)	2012	14 (0.7)	0	0

## Risk Factors

Owing to its infrequent occurrence, it is difficult to determine the precise risk factors that predispose certain patients to femoral neuropathy following THA.

Patients taking anticoagulants, or those with intrinsic coagulopathies such as haemophilia, may develop spontaneous bleeding in the soft tissues adjacent to the nerve. The formation of a haematoma may be the result of the perforation of the medial wall of the acetabulum during the arthroplasty and can produce delayed onset nerve palsy (4,25,35,43).

In a study of 2012 THA's, Weber *et al* reported that the female gender was the only factor that correlated with development of neuropathy (41). Johanson *et al* reported that 79% of the patients who sustained nerve injuries in their study were female – a finding consistent with that of several

other authors who attributed increased risk to the female gender (19,31,36). The higher incidence of femoral neurologic injuries in females versus males has been postulated to result from females' reduced muscle mass, different local vascular anatomy and shorter limbs (36,41). Experimental models have shown that neural injury will occur if the nerve is elongated more than 6 percent of its length. Given this limit, smaller individuals with shorter limbs, and thus shorter nerves, have less of a tolerance for absolute neural retraction than do much larger individuals (19,36). This factor may help to partially explain the differences in prevalence observed between genders (25).

Several studies have evaluated the prevalence of femoral nerve palsy based on the origin of hip disease (including hip dysplasia and dislocation). Altered anatomy in the region of the hip has been considered a factor that increases the potential for

Table II. — Possible aetiologies of femoral neuropathy following total hip arthroplasty, as reported in the literature

Haemorrhage/Haematoma	Fixation	Anatomical	Surgical
Anticoagulant therapy	Extravasation/Impingement	Anatomy	Difficulty of surgery
Coagulopathy	Cement Pressuring-Device	Displasia of hip	Intraoperative positioning
Haematoma	Direct encasement of nerve	Female gender	Leg lengthening or stretch
	Heat of polymerization		Post-operative anterior dislocation
			Revision surgery
			Surgical approach
			Trauma of instrumentation

neural injuries (28). Schmalzried *et al* reported that patients with developmental dysplasia of the hip (DDH) and patients undergoing revision surgery were at significantly increased risk for neurologic injury (34). In a series of 27,004 patients, Farrell *et al* reported that DDH was a significant risk factor in those undergoing primary THA and concluded that excessive limb lengthening, post-traumatic arthritis and cementless femoral fixation were risk factors ; and proposed that the increased risk associated with cementless femoral fixation was related to the need for forceful impaction of the femoral component (13). Acute limb-lengthening of more than two to four centimetres during arthroplasty has been associated with an increased risk of neural injury (19).

There has been some disagreement in the literature regarding the evaluation of the role of surgical approach in the development of femoral neuropathy following THA. Navarro *et al* prospectively compared 1000 consecutive primary and revision THA cases for neurologic injury when performed through the transtrochanteric or posterior approach and concluded that anatomical variation and the complexity of the reconstruction, but not the surgical approach was associated with femoral neurologic injury (28). Johansen *et al* and Weale *et al* also concurred that incidence of neurologic injury was unrelated to surgical approach (19,40).

However, several authors have disputed that surgical approach is unrelated to incidence of femoral neuropathy following THA. Simmons *et al* reported 10 femoral nerve palsies from a review of 440 (360 primary, 80 revision) THA's. All were associated with anterolateral approach. Their anatomic

studies show the proximity of the femoral nerve to the anterior aspect of the hip joint and thus to anterior acetabular retractors (35).

Revision of a failed implant has been associated with an increased risk of injury to the femoral nerve after THA (28,34). This increased risk may be due to the more extensive and difficult dissection required with revision procedures and perhaps, in some patients, to uncertainty regarding the location of major neurological and vascular structures when a previous operative exposure has been performed (25,27). In addition, tethering by scar tissue may predispose the nerve to stretch with retraction, dislocation of the hip, or limb-lengthening. During isolated revision of the acetabular component through a posterior approach, retraction of the intact femoral component anteriorly may increase the risk of compression of the femoral nerve (25).

### Prevention

The best treatment of any complication is prevention. It is advised that the treating surgeon preoperatively identify the patients who are most at risk and take the measures necessary to avoid nerve injury. Once a patient is identified as being at an increased risk, preoperative planning is mandatory.

Identification and protection of the nerve, particularly when there may be alterations in the local anatomy, is indicated. Careful surgical technique and avoidance of direct injury of the nerve during exposure, gentle retraction and judicious placement of the retractors are important. Operative techniques that emphasize the use of instruments and sharp dissection away from rather than toward

important neurological or vascular structures are suggested. Such techniques make it possible to avoid neural injury when those instruments slip. There is no strong evidence favouring any one approach for preventing nerve injury (7,25).

Maintenance of the knee in flexion during retraction for exposure about the acetabulum through a posterior approach can reduce tension on the nerve. Avoidance of acetabular screw-placement in the anterior-superior and anterior-inferior quadrants is recommended (25). Minimizing the amount of leg lengthening during preoperative planning and using leg-length measurement techniques may decrease the risk of the nerve. Less than four centimetres or six percent of the calculated length of the nerve (which ever is less) should be used as an approximate guideline.

Intraoperative neural monitoring has been explored as a potential means to reduce the risk of nerve injury (2,20,29,33). It is possible to document intraoperative irritation of the nerve and, if necessary, to alter the operative technique or the position of the limb. Such monitoring has been recommended as a surveillance method during revision total hip arthroplasty or when major limb-lengthening efforts are planned (25,33). Simultaneous changes in amplitude and latency appear to be predictive of an alteration in the function of the nerve postoperatively. However, the actual reduction in the risk of nerve palsy due to intraoperative neural monitoring has not been well established and thus the ability of this method to prevent neural injury remains in debate (2,20,29,33).

## TREATMENT

### Recommended Pre-Operative Considerations and Management

Patients should be advised of the possibility of developing femoral neuropathy, particularly high-risk patients. With challenging surgery or uncommon anatomic variations, an experienced orthopaedic surgeon should be involved. There is no proven benefit of preoperative neurophysiological testing to predict or prevent femoral nerve damage.

### Recommended Intra-Operative Considerations and Management

It is recommended that the following precautions be taken :

- A thorough awareness of the regional anatomy, its relevant functions and associated patterns of pain is essential ;
- Care with the use of surgical instruments, especially retractors ; avoid excessive traction, especially during dislocation of the hip ;
- The limb should be supported throughout the operation ;
- Consideration for intraoperative monitoring of the femoral nerve in high risk cases, and precise documentation of intraoperative (and postoperative) findings.

### Recommended Post-Operative Considerations and Management

It is often difficult to establish a diagnosis of nerve injury following THA. It is recommended that the following be considered :

- The neurological status should be examined and recorded on the first post-operative day and repeated during the first post-operative week. Some authors recommend the routine use of electrodiagnostic testing however this has not been substantiated (8,13,37,38).
- Post-surgical care should include attention to the clinical recognition, accurate diagnosis and assessment of severity of nerve damage that may occur as a complication of the surgery.
- If femoral nerve damage is indicated and requires surgery (such as those caused by haematomas), early surgical decompression may be recommended to prevent further nerve compression and irreversible damage (13). However, this decision should be determined by the treating surgeon. The surgeon should also provide realistic recovery outcomes to the patient.
- If femoral nerve damage is indicated but surgery is not required, conservative management is the cornerstone treatment of the neuropathy (36,43). An electromyogram at six weeks and at three

months should be performed. If by three months, there is no improvement, magnetic resonance imaging may be of assistance.

### PROGNOSIS

The potential for recovery (whether partial or complete) of femoral neuropathy after THA is generally proportional to the severity and location of the injury, although clinical factors such as unrecognized severity of the injury and delays in diagnosis, have precluded establishing an exact relation. This principle underlies the policy of watchful waiting in certain surgical aetiologies where the nerve is known or even suspected to be intact.

Establishing the degree of damage early (within 2-4 months) may minimize further nerve damage (21). Optimal management of femoral nerve injuries can be obtained by close interdisciplinary co-operation among the treating orthopaedic surgeon, neurologists and physical therapists.

Pess *et al* recommend decompression and/or neurolysis to improve motor function and relieve the pain associated with femoral nerve injury following cement encasement (32). However, direct envelopment of the nerve by cement carries a worse prognosis than injury by retractors or haemorrhage (35).

We recommend that the surgeon discuss with the patient the realistic outcome of recovery based on the location and severity of the femoral nerve injury. Improvements may continue for at least one year after the injury but the status is unlikely to change after two years (4,21,22,25,32,43). Some patients may never fully recover.

### REFERENCES

- Barrack RL.** Economics of revision total hip arthroplasty. *Clin Orthop Relat Res* 1995 ; 319 : 209-214.
- Black DL, Reckling FW, Porter SS.** Somatosensory-evoked potential monitored during total hip arthroplasty. *Clin Orthop Relat Res* 1991 ; 262 : 170-177.
- Brown GD, Swanson EA, Necessian OA.** Neurologic injuries after total hip arthroplasty. *Am J Orthop* 2008 ; 37 : 191-197.
- Butterfield WC, Neviasser RJ, Roberts MP.** Femoral neuropathy and anticoagulants. *Ann Surg* 1972 ; 176 : 58-61.
- Chapchal GJ, Slooff TJ, Nollen AD.** Results of total hip replacement. A clinical follow-up study. *Clin Orthop Relat Res* 1973 ; 95 : 111-117.
- Coventry MB, Beckenbaugh RD, Nolan DR, Ilstrup DM.** 2,012 total hip arthroplasties. A study of post-operative course and early complications. *J Bone Joint Surg* 1974 ; 56-A : 273-284.
- DeHart MM, Riley LH, Jr.** Nerve injuries in total hip arthroplasty. *J Am Acad Orthop Surg* 1999 ; 7 : 101-111.
- Edwards BN, Tullos HS, Noble PC.** Contributory factors and etiology of sciatic nerve palsy in total hip arthroplasty. *Clin Orthop Relat Res* 1987 ; 218 : 136-141.
- Eggl S, Hankemayer S, Muller ME.** Nerve palsy after leg lengthening in total replacement arthroplasty for developmental dysplasia of the hip. *J Bone Joint Surg* 1999 ; 81-B : 843-845.
- Eskelinen A, Helenius I, Remes V et al.** Cementless total hip arthroplasty in patients with high congenital hip dislocation. *J Bone Joint Surg* 2006 ; 88-A : 80-91.
- Ethgen O, Bruyere O, Richey F et al.** Health-related quality of life in total hip and total knee arthroplasty. A qualitative and systematic review of the literature. *J Bone Joint Surg* 2004 ; 86-A : 963-974.
- Evarts CM, DeHaven KE, Nelson CL et al.** Interim results of Charnley-Muller total hip arthroplasty. *Clin Orthop Relat Res* 1973 ; 95 : 193-200.
- Farrell CM, Springer BD, Haidukewych GJ, Morrey BF.** Motor nerve palsy following primary total hip arthroplasty. *J Bone Joint Surg* 2005 ; 87-A : 2619-2625.
- Fortin PR, Clarke AE, Joseph L et al.** Outcomes of total hip and knee replacement : preoperative functional status predicts outcomes at six months after surgery. *Arthritis Rheum* 1999 ; 42 : 1722-1728.
- Harris WH, Sledge CB.** Total hip and total knee replacement (2). *N Engl J Med* 1990 ; 323 : 801-807.
- Harris WH, Sledge CB.** Total hip and total knee replacement (1). *N Engl J Med* 1990 ; 323 : 725-731.
- Hartofilakidis G, Stamos K, Karachalios T.** Treatment of high dislocation of the hip in adults with total hip arthroplasty. Operative technique and long-term clinical results. *J Bone Joint Surg* 1998 ; 80-A : 510-517.
- Ide T, Akamatsu N, Nakajima I.** Arthroscopic surgery of the hip joint. *Arthroscopy* 1991 ; 7 : 204-211.
- Johanson NA, Pellicci PM, Tsairis P, Salvati EA.** Nerve injury in total hip arthroplasty. *Clin Orthop Relat Res* 1983 ; 179 : 214-222.
- Kennedy WF, Byrne TF, Majid HA, Pavlak LL.** Sciatic nerve monitoring during revision total hip arthroplasty. *Clin Orthop Relat Res* 1991 ; 264 : 223-227.
- Komurcu F, Zwolak P, Benditte-Klepetchko H, Deutinger M.** Management strategies for peripheral iatrogenic nerve lesions. *Ann Plast Surg* 2005 ; 54 : 135-139.
- Kuntzer T, van Melle G, Regli F.** Clinical and prognostic features in unilateral femoral neuropathies. *Muscle Nerve* 1997 ; 20 : 205-211.

23. **Laupacis A, Bourne R, Rorabeck C et al.** The effect of elective total hip replacement on health-related quality of life. *J Bone Joint Surg* 1993 ; 75-A : 1619-1626.
24. **Lazansky MG.** Complications revisited. The debit side of total hip replacement. *Clin Orthop Relat Res* 1973 ; 95 : 96-103.
25. **Lewallen DG.** Neurovascular injury associated with hip arthroplasty. *Instr Course Lect* 1998 ; 47 : 275-283.
26. **Moczynski G, Abraham E, Barmada R, Ray RD.** Evaluation of total hip replacement arthroplasties. *Clin Orthop Relat Res* 1973 ; 95 : 213-216.
27. **Murray WR.** Results in patients with total hip replacement arthroplasty. *Clin Orthop Relat Res* 1973 ; 95 : 80-90.
28. **Navarro RA, Schmalzried TP, Amstutz HC, Dorey FJ.** Surgical approach and nerve palsy in total hip arthroplasty. *J Arthroplasty* 1995 ; 10 : 1-5.
29. **Nercessian OA, Gonzalez EG, Stinchfield FE.** The use of somatosensory evoked potential during revision or reoperation for total hip arthroplasty. *Clin Orthop Relat Res* 1989 ; 243 : 138-142.
30. **Nercessian OA, Macaulay W, Stinchfield FE.** Peripheral neuropathies following total hip arthroplasty. *J Arthroplasty* 1994 ; 9 : 645-651.
31. **Oldenburg M, Muller RT.** The frequency, prognosis and significance of nerve injuries in total hip arthroplasty. *Int Orthop* 1997 ; 21 : 1-3.
32. **Pess GM, Lusskin R, Waugh TR, Battista AE.** Femoral neuropathy secondary to pressurized cement in total hip replacement : treatment by decompression and neurolysis. Report of a case. *J Bone Joint Surg* 1987 ; 69-A : 623-625.
33. **Porter SS, Black DL, Reckling FW, Mason J.** Intraoperative cortical somatosensory evoked potentials for detection of sciatic neuropathy during total hip arthroplasty. *J Clin Anesth* 1989 ; 1 : 170-176.
34. **Schmalzried TP, Amstutz HC, Dorey FJ.** Nerve palsy associated with total hip replacement. Risk factors and prognosis. *J Bone Joint Surg* 1991 ; 73-A : 1074-1080.
35. **Simmons C Jr., Izant TH, Rothman RH et al.** Femoral neuropathy following total hip arthroplasty. Anatomic study, case reports, and literature review. *J Arthroplasty* 1991 ; 6 Suppl : S57-66.
36. **Solheim LF, Hagen R.** Femoral and sciatic neuropathies after total hip arthroplasty. *Acta Orthop Scand* 1980 ; 51 : 531-534.
37. **Sutherland CJ, Miller DH, Owen JH.** Use of spontaneous electromyography during revision and complex total hip arthroplasty. *J Arthroplasty* 1996 ; 11 : 206-209.
38. **Unwin A, Scott J.** Nerve palsy after hip replacement : medico-legal implications. *Int Orthop* 1999 ; 23 : 133-137.
39. **van der Linde MJ, Tonino AJ.** Nerve injury after hip arthroplasty. 5/600 cases after uncemented hip replacement, anterolateral approach versus direct lateral approach. *Acta Orthop Scand* 1997 ; 68 : 521-523.
40. **Weale AE, Newman P, Ferguson IT, Bannister GC.** Nerve injury after posterior and direct lateral approaches for hip replacement. A clinical and electrophysiological study. *J Bone Joint Surg* 1996 ; 78-B : 899-902.
41. **Weber ER, Daube JR, Coventry MB.** Peripheral neuropathies associated with total hip arthroplasty. *J Bone Joint Surg* 1976 ; 58-A : 66-69.
42. **Wood MN.** Peripheral nerve injuries to the lower extremity. In : Gelberman RH (ed). *Operative Nerve Repair and Reconstruction*, Lippincott, Philadelphia 1991 ; pp 489-504.
43. **Wooten SL, McLaughlin RE.** Iliacus hematoma and subsequent femoral nerve palsy after penetration of the medical acetabular wall during total hip arthroplasty. Report of a case. *Clin Orthop Relat Res* 1984 ; 191 : 221-223.