



## Management of anterior sternoclavicular dislocation : A survey of orthopaedic surgeons

Alexander VAN TONGEL, Sheila McRAE, Alexandra GILHEN, Jeff LEITER, Peter MACDONALD

*From the PanAm Clinic, University of Manitoba, Winnipeg, Manitoba, Canada*

**Acute and chronic symptomatic anterior sternoclavicular (SC) dislocations are rare ; various treatment options have been described. With the purpose of surveying current practices and opinions concerning treatment of these lesions, we sent a questionnaire to members of a general orthopaedic society, a national shoulder society and an international shoulder society. Closed reduction was attempted by 52% of the respondents, but > 80% of the surgeons stated that the reduction was not maintained in more than half of the dislocations. The procedure preferred by the respondents – explicitly by members of the international shoulder society – to deal with chronic symptomatic anterior SC dislocation, is reconstruction of the ligaments. Members of the international shoulder society are more likely to choose operative treatment for chronic symptomatic anterior SC dislocations.**

**Keywords :** survey ; anterior sternoclavicular dislocation ; acute ; chronic.

### INTRODUCTION

Sternoclavicular (SC) joint dislocations are rare injuries, representing only 2-3% of the injuries of the upper limb (15). Most subluxations or dislocations are anterior. Posterior dislocation is less common, but is potentially more dangerous and even life threatening because of the proximity of mediastinal structures (main vessels, trachea, oesophagus, brachial plexus). The natural history of these conditions remains controversial and no consensus

regarding their management currently exists. To our knowledge, this is the first investigation of surgical practice in the treatment of anterior SC dislocation.

We conducted a survey regarding treatment options in acute and chronic symptomatic anterior SC dislocation, between three groups of orthopaedic surgeons : members of a general orthopaedic society (Canadian Orthopaedic Association (COA)), members of a society with interest in shoulder and elbow surgery (Flemish Elbow and Shoulder Surgeons Society [FLESSS]), and members of a society of leading national and international orthopaedic surgeons who specialize in surgery of the shoulder and elbow (American Shoulder and Elbow Society [ASES]). Identifying areas of disagreement may allow investigators to focus basic science research and clinical trials around those

- 
- Alexander Van Tongel, MD, Orthopaedic Surgeon.  
*Department of Orthopaedic Surgery and Traumatology, Ghent University Hospital, Gent, Belgium.*
  - Sheila McRae, MSc, Research Associate.
  - Alexandra Gilhen M.Sc, Research Assistant.
  - Jeff Leiter, PhD, Research Director.
  - Peter Macdonald, MD, FRCSC, Orthopaedic Surgeon.  
*PanAm Clinic, University of Manitoba, Winnipeg, Manitoba, Canada.*
- Correspondence : Alexander Van Tongel, Department of Orthopaedic Surgery and Traumatology, Ghent University Hospital, De Pintelaan 185, 9000 Gent, Belgium.  
E-mail : Alexander\_vantongel@hotmail.com  
© 2012, Acta Orthopædica Belgica.
-

areas, create a more unified understanding and evidence-based management approach to the treatment of acute and chronic symptomatic anterior SC dislocation.

## METHODS

Approval was obtained from the appropriate research ethics board prior to commencement of study activities. Orthopaedic surgeons who were listed as active members of their respective organizations were invited by email to take part in an internet-based survey.

Questionnaire distribution and analysis followed the process used in a previous study on ACL reconstruction (22). The questionnaire comprised of six multiple-choice questions regarding years of experience, numbers of cases of anterior SC dislocations seen, treatment preference for acute and chronic symptomatic SC dislocation and two statements to be accepted or rejected by the respondents. Not all respondents were required to answer all questions as the applicability of some questions was based on previous responses. Three questions allowed for multiple responses so the sum of all response percentages sometimes exceeded 100%. The current questionnaire was tested on three fellowship-trained orthopaedic sports medicine surgeons not involved in the study, revised accordingly and then distributed. An e-mail invitation was distributed via SurveyMonkey.com™ (Palo Alto, California) with a link to the survey. Reminder emails were sent out at 1- and 3-months after the initial email. Responses were de-identified using study numbers and were kept separate from the names/emails of the respondents.

### Data Analysis

Frequency distributions were generated for all questions. Not all respondents answered all questions; therefore, actual number of responses is noted for each question and is specified in the description of results. Clinical agreement has been inconsistently and somewhat arbitrarily defined in the literature. Wright *et al* defined agreement as > 90% of physicians answering similarly on a survey (33), whereas others have suggested that a value of > 95% indicates strong agreement and a value of > 60% indicates general agreement (31). Marx *et al* defined clinical agreement as 80% of surgeons answering similarly (21), and for the purposes of the study we used this threshold. This threshold is, of course, arbitrary and is only used to highlight areas of consensus. Actual

counts and percentages are provided in the Results section to allow for deriving ones' own conclusions regarding clinical agreement. For comparisons between the COA, FLESSS, and ASES groups, either chi-square or Fisher's exact tests were performed, depending on the expected frequencies for each question. Significance level for all comparisons was  $p < 0.05$ .

## RESULTS

The email invitation to participate was sent out to 752 orthopaedic surgeons of whom 212 responded (28%). The response rate for COA was 24% (131/537), for FLESSS 33% (28/85) and for ASES was 41% (53/130).

Thirty-nine percent (83/212) of respondents had more than twenty years of clinical experience, 37% (48/131) in the COA, 14% (4/28) in FLESSS, and 59% (31/53) in ASES (Fig. 1). Fifty-three percent (110/207) of surgeons indicated seeing one or more anterior SC dislocation per year, with 12% (24/207) seeing three or more per year. There was a difference between groups ( $p < 0.05$ ) regarding frequency of seeing this pathology since 5% in the COA (6/128), 19% in FLESSS (5/27), and 25% (13/52) in ASES indicated seeing three or more anterior sternoclavicular dislocations every year.

Based on 80% threshold for clinical agreement, surgeons did not agree on the appropriateness of performing a closed reduction in an acute anterior sternoclavicular dislocation. Fifty-two percent of surgeons (110/207) indicated that they would perform a closed reduction. There is no difference between groups regarding this issue ( $p = 0.305$ ). Surgeons did agree that less than 50% of the closed reductions remain reduced (85% or 85/100) (Fig. 2), 39% stated that between 50% and 25% of closed reductions remain reduced and 46% (46/100) chose 25% or less.

Although not at the threshold of "clinical agreement", a majority of surgeons (69/100) would not perform an open reduction in an acute situation if a closed reduction failed or redislocation occurred. There was no significant difference between the three groups ( $p = 0.156$ ).

The preferred method for operative treatment of acute SC dislocation was open reduction and

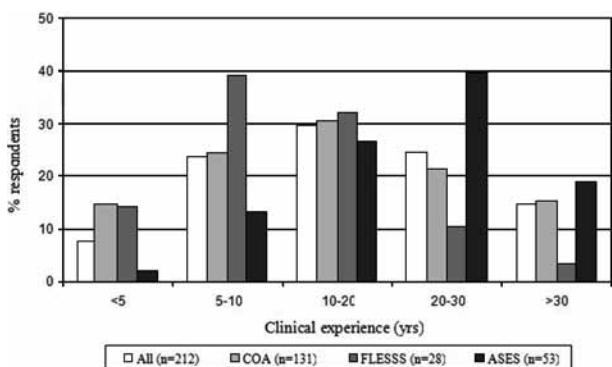


Fig. 1. — Years of clinical experience overall and by group

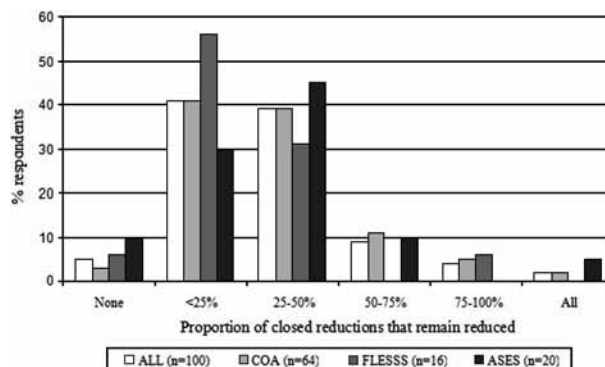


Fig. 2. — Proportion of respondents indicating the proportion of closed reductions that remain reduced.

Table I. — Procedure which respondents indicated they would perform in a sternoclavicular dislocation if doing an open reduction. COA = Canadian Orthopedic Association ; FLESSS = Flemish Elbow and Shoulder Surgeons Society ; ASES = American Shoulder and Elbow Society

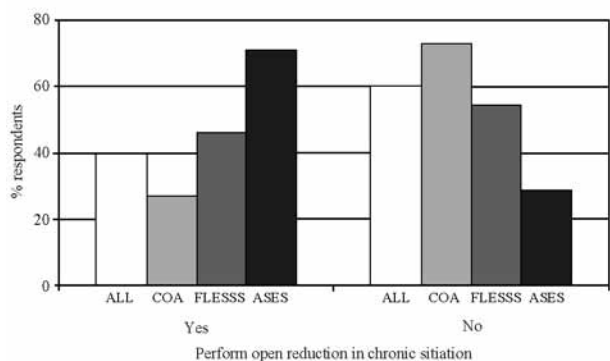
	Acute				Chronic			
	ALL (n = 31)	COA (n = 20)	FLESSS (n = 14)	ASES (n = 7)	ALL (n = 80)	COA (n = 34)	FLESSS (n = 11)	ASES (n = 35)
Open reduction and suturing sternoclavicular capsule and costoclavicular ligament	87	85	100	86	34	44	36	23
Medial claviculectomy	3	0	25	0	28	29	27	26
Reconstruction of anterior sternoclavicular ligaments	26	15	50	43	40	41	55	57
Reconstruction of costoclavicular ligaments	19	10	25	43	22	6	18	21
Other	10	15	0	0	9	15	0	11

suturing of SC and costoclavicular ligaments by 27 of 31 surgeons (87%) (Table I). Only one respondent indicated performing a medial claviculectomy in this situation. There was no difference between groups, concerning surgical technique ( $p = 0.526$ ).

Concerning the treatment for chronic symptomatic anterior SC dislocation, 60% of respondents (115/193) chose conservative treatment (Fig. 3). There was a significant difference between groups regarding performing open treatment on a symptomatic chronic anterior SC dislocation with 27% of COA respondents (33/121), 46% of FLESSS respondents (11/24), and 71% of ASES respondents (34/48) indicating they would perform open treatment for a chronic symptomatic anterior SC dislo-

cation ( $p < 0.001$ ). There was no clinical agreement with regard to the technique preferred (Table I). There was a significant difference between groups in choosing the option of reconstruction of the costoclavicular ligament ( $p < .001$ ). Respondents of the ASES would perform this surgery more commonly than those from the FLESSS and the COA.

With respect to operative treatment of acute and chronic symptomatic anterior SC dislocations, suturing of the capsule and ligament is done more in the acute situation than in the chronic situation ( $p < 0.001$ ). Respondents reported performing a medial claviculectomy significantly more in the chronic situation than in the acute situation ( $p < 0.01$ ).



**Fig. 3.** — Proportion of respondents performing an open reduction in a chronic situation if closed reduction fails or redislocation occurs.

## DISCUSSION

This study illustrates the diversity of approaches in current practice in the treatment of acute and chronic SC dislocation. The response rate was 28%, which is lower than the rate of other surveys of this type (10,20,34). In our opinion, one of the main reasons for this lower rate is the fact that SC dislocations are rare in contrast to pathologies discussed in other surveys and operative treatment is uncommon in daily practice. Surgeons may feel that their opinion is not relevant due to their lack of experience in this area. This hypothesis was confirmed by the fact that the response rate was higher from members of a group with more specific interest in shoulder and elbow pathology and more experience in the treatment of this pathology. This hypothesis is also described by Chassin *et al.* as the ‘enthusiasm hypothesis’ which postulates that the variation is due to differences in surgeons’ enthusiasm for procedures, which may not be evidence-based (8).

We found no clinical agreement on the necessity of a closed reduction in an acute dislocation. The literature leaves both options open. Savastano *et al* proposed that a closed reduction should not be performed in an acute situation because stability of the sternoclavicular joint is not necessary to ensure normal function of the involved limb (29). De Jong *et al* described the results in 10 patients with acute SC dislocations that were treated without closed reduction (9) : seven patients were good, two patients fair,

and one patient poor. Several tried closed reduction with variable success. Their recurrence rates were between 21 and 100% (11,23,28). When reduction was successful, cosmesis was served (15).

Concerning operative treatment of an acute and chronic anterior SC dislocation, several options have been proposed in literature and in the context of the current survey ; we divided these into four techniques that can be used in isolation or combined. Respondents were also given the option to choose ‘Other’.

The first option, suturing of SC ligaments and CC ligaments was proposed by 87.1% in an acute situation. After open reduction ligaments and capsule are sutured, followed by temporary SC transfixation (11,32) or suture anchor fixation to the sternum (17). In our survey, 1/4 of respondents chose this option in the operative treatment of chronic symptomatic dislocation.

The second option was resection of the medial clavicle. This option in literature is described to be a poor choice (1,12,24,25). If a resection is to be performed, a stabilisation of the medial clavicle is necessary (25).

The third option was a reconstruction of the anterior SC ligament. This option was preferred in chronic symptomatic anterior dislocation by the respondents and is the technique most closely examined in the literature (2-4,7,16,18,30). Various autografts have been proposed to reconstruct the ligament, such as fascia lata (2,4,18), semitendinosus (7) or the medial portion of the sternal part of the sternocleidomastoid muscle (3,16). In 2004, Spencer *et al* (30) found that the use of the semitendinosus in a figure of eight configuration has initial biomechanical properties that are superior to other known techniques to treat chronic SC dislocation.

The fourth option was reconstruction of the costoclavicular ligament. Respondents from the ASES proposed this option significantly more than those from the FLESSS and COA. Also with this technique, several different autografts (2,5,6,19) have been described to reconstruct the ligament. The most performed technique is a transposition of the subclavius muscle (6). Temporary fixation with a Steinman pin, as proposed by Lunseth (19) is not recommended because of the high risk of migration,

and possible injury to the mediastinal structures (13). All these techniques have been studied in a small group of patients with favourable results.

Fifteen percent of respondents from the general orthopaedic association, the COA, chose the 'Other' option in the acute situation. Unfortunately, based on the format of the survey, respondents were not given an opportunity to describe these other techniques. There were limited descriptions in the literature of techniques other than those specified in the survey. Franck *et al* used a Balsler plate in six patients to stabilize reduced acute anterior SC dislocation with good results (14). The Balsler plate acts as a hook plate in acute acromioclavicular dislocations (27). Disadvantages of this technique are the dimensions of the Balsler plate and the need for implant removal.

The obvious difference between general and "specialised" orthopaedic surgeons with a keen interest in shoulder and elbow problems as to the operative treatment in chronic symptomatic anterior SC dislocations may be a reflection of more technical expertise or up-to-date knowledge of research supporting certain choices.

It is important to note that all these surgical techniques have been described in patients with a traumatic anterior dislocation. Patients with atraumatic spontaneous anterior subluxation should be treated non-operatively (26). Non-operative treatment, consisting of education and reassurance of the patient and family, allows the individual to understand the benign natural course of the problem. Operative treatment for spontaneous anterior subluxation of the sternoclavicular joint is rarely, if ever, indicated.

The significance of survey studies like ours is that they allow for the identification of areas of disagreement, and can direct future research. Based on the findings in this study, it would be useful to investigate the long-term follow-up after acute SC dislocation in patients treated without and with closed reduction. Furthermore an interesting study would be the evaluation of the results obtained in patients with chronic symptomatic anterior dislocation that are treated conservatively and operatively and a comparison between several surgical techniques.

A major limitation of this study is the low response rate, attributable, in part, to the low incidence of this condition with a limited number of surgeons actually involved in managing such cases. Another limitation is that only members of three specific societies were surveyed.

## CONCLUSIONS

Orthopaedic surgeons do not frequently see anterior SC dislocation and there is no clear clinical agreement concerning the treatment of acute and chronic symptomatic dislocation. If a closed reduction is performed, surgeons agree that less than 50% will remain stable. If operative treatment is proposed in an acute situation, the most common procedure is suturing of the SC ligaments and costoclavicular ligaments. Concerning the treatment of chronic symptomatic anterior SC dislocation, there are significant differences between the three groups. Respondents of the ASES would consider operative treatment more than members of the COA. The most common procedure performed in the ASES group in this situation is reconstruction of the anterior SC ligament and/or costoclavicular ligament.

## REFERENCES

1. **Acus RW 3rd, Bell RH, Fisher DL.** Proximal clavicle excision : an analysis of results. *J Shoulder Elbow Surg* 1995 ; 4 : 182-187.
2. **Allen AW.** Living suture grafts in the repair of fractures and dislocations. *Arch Surg* 1928 ; 16 : 1007-1020.
3. **Armstrong AL, Dias JJ.** Reconstruction for instability of the sternoclavicular joint using the tendon of the sternocleidomastoid muscle. *J Bone Joint Surg* 2008 ; 90-B : 610-613.
4. **Bankart ASB.** An operation for recurrent dislocation (subluxation) of the sternoclavicular joint. *Brit J Surg* 1938 ; 26 : 320-323.
5. **Booth CM, Roper BA.** Chronic dislocation of the sternoclavicular joint : an operative repair. *Clin Orthop Relat Res* 1979 ; 140 : 17-20.
6. **Burrows HJ.** Tenodesis of subclavius in the treatment of recurrent dislocation of the sterno-clavicular joint. *J Bone Joint Surg* 1951 ; 33-B : 240-243.
7. **Castropil W, Ramadan LB, Bitar AC, Schor B, de Oliveira D'Elia C.** Sternoclavicular dislocation – reconstruction with semitendinosus tendon autograft : a case

- report. *Knee Surg Sports Traumatol Arthrosc* 2008 ; 16 : 865-868.
8. **Chassin MR.** Explaining geographic variations. The enthusiasm hypothesis. *Med Care* 1993 ; 31 : YS37-44.
  9. **de Jong KP, Sukul DM.** Anterior sternoclavicular dislocation : a long-term follow-up study. *J Orthop Trauma* 1990 ; 4 : 420-423.
  10. **Dunn WR, Schackman BR, Walsh C et al.** Variation in orthopaedic surgeons' perceptions about the indications for rotator cuff surgery. *J Bone Joint Surg* 2005 ; 87-A : 1978-1984.
  11. **Eskola A.** Sternoclavicular dislocation. A plea for open treatment. *Acta Orthop Scand* 1986 ; 57 : 227-228.
  12. **Eskola A, Vainionpaa S, Vastamaki M, Slatis P, Rokkanen P.** Operation for old sternoclavicular dislocation. Results in 12 cases. *J Bone Joint Surg* 1989 ; 71-B : 63-65.
  13. **Fernandez L, Yubero J, Usabiaga J, No L, Martin F.** Sternoclavicular dislocation. Treatment and complications. *Ital J Orthop Traumatol* 1988 ; 14 : 349-355.
  14. **Franck WM, Jannasch O, Siassi M, Hennig FF.** Balser plate stabilization : an alternate therapy for traumatic sternoclavicular instability. *J Shoulder Elbow Surg* 2003 ; 12 : 276-281.
  15. **Groh GI, Wirth MA.** Management of traumatic sternoclavicular joint injuries. *J Am Acad Orthop Surg* 2011 ; 19 : 1-7.
  16. **Lee SU, Park IJ, Kim YD, Kim YC, Jeong C.** Stabilization for chronic sternoclavicular joint instability. *Knee Surg Sports Traumatol Arthrosc* 2010 ; 18 : 1795-1797.
  17. **Lehmann W, Laskowski J, Grossterlinden L, Rueger JM.** [Refixation of sternoclavicular luxation with a suture anchor system.] (in German). *Unfallchirurg* 2010 ; 113 : 418-421.
  18. **Lowman CL.** Operative correction of old sternoclavicular dislocation. *J Bone Joint Surg* 1928 ; 10 : 740-741.
  19. **Lunseth PA, Chapman KW, Frankel VH.** Surgical treatment of chronic dislocation of the sterno-clavicular joint. *J Bone Joint Surg* 1975 ; 57-B : 193-196.
  20. **Luyckx T, Debeer P.** Management of full thickness rotator cuff tears. A survey amongst members of the Flemish Elbow and Shoulder Surgeons Society (FLESSS). *Acta Orthop Belg* 2010 ; 76 : 14-21.
  21. **Marx RG, Jones EC, Angel M, Wickiewicz TL, Warren RF.** Beliefs and attitudes of members of the American Academy of Orthopaedic Surgeons regarding the treatment of anterior cruciate ligament injury. *Arthroscopy* 2003 ; 19 : 762-770.
  22. **McRae S, Chahal J, Leiter J, Marx R, MacDonald P.** Survey study of members of the Canadian Orthopaedic Association on the natural history and treatment of anterior cruciate ligament injury. *Clin J Sport Med* 2011 ; 21 : 249-258.
  23. **Nettles JL, Linscheid RL.** Sternoclavicular dislocations. *J Trauma* 1968 ; 8 : 158-164.
  24. **Panzica M, Zeichen J, Hankemeier S et al.** Long-term outcome after joint reconstruction or medial resection arthroplasty for anterior SCJ instability. *Arch Orthop Trauma Surg* 2010 ; 130 : 657-665.
  25. **Rockwood CA Jr, Groh GI, Wirth MA, Grassi FA.** Resection arthroplasty of the sternoclavicular joint. *J Bone Joint Surg* 1997 ; 79-A : 387-393.
  26. **Rockwood CA Jr, Odor JM.** Spontaneous atraumatic anterior subluxation of the sternoclavicular joint. *J Bone Joint Surg* 1989 ; 71-A : 1280-1288.
  27. **Salem KH, Schmelz A.** Treatment of Tossy III acromioclavicular joint injuries using hook plates and ligament suture. *J Orthop Trauma* 2009 ; 23 : 565-569.
  28. **Salvatore JE.** Sternoclavicular joint dislocation. *Clin Orthop Relat Res* 1968 ; 58 : 51-55.
  29. **Savastano AA, Stutz SJ.** Traumatic sternoclavicular dislocation. *Int Surg* 1978 ; 63 : 10-13.
  30. **Spencer EE, Jr., Kuhn JE.** Biomechanical analysis of reconstructions for sternoclavicular joint instability. *J Bone Joint Surg* 2004 ; 86-A : 98-105.
  31. **Tierney WM, Fitzgerald JF, Heck DA et al.** Tricompartmental knee replacement. A comparison of orthopaedic surgeons' self reported performance rates with surgical indications, contraindications, and expected outcomes. Knee Replacement Patient Outcomes Research Team. *Clin Orthop Relat Res* 1994 ; 305 : 209-217.
  32. **Witvoet J, Martinez B.** [Treatment of anterior sternoclavicular dislocations. Apropos of 18 cases.] (in French). *Rev Chir Orthop Réparatrice Appar Mot* 1982 ; 68 5 : 311-316.
  33. **Wright JG, Coyte P, Hawker G et al.** Variation in orthopedic surgeons' perceptions of the indications for and outcomes of knee replacement. *Can Med Ass J* 1995 ; 152 : 687-697.
  34. **Zuckerman JD, Rokito A.** Frozen shoulder : A consensus definition. *J Shoulder Elbow Surg* 2011 ; 20 : 322-5.