



Advancement of the Vastus Lateralis muscle for irreparable hip abductor tears : Clinical and morphological results

Michael BETZ, Patrick O. ZINGG, Christian W. PFIRRMANN, Claudio DORA

From the Balgrist University Hospital, Zurich, Switzerland

Outcome after advancement of the vastus lateralis muscle for irreparable disruption of the hip abductor mechanism was evaluated in 9 patients. Seven to 10 cm defects were bridged without complications. After a mean follow-up of 33 months (range : 12-60 months), the majority of patients reported a 69% satisfaction and a reduction of both pain medication and gait assists. Six out of 9 patients would undergo the same treatment again and one was undecided. On physical examination hip function was significantly improved but still poor. A significant loss of quadriceps muscle strength was the only donor site morbidity encountered. Overall, very modest but relevant improvement of hip function can be achieved with this procedure without relevant donor site morbidity and complications.

Keywords : hip abductor mechanism ; disruption ; surgical repair.

can be well visualized by magnetic resonance imaging, even in the presence of a THA (15). Endoscopic debridement and anchor repair has been described (17), but most published reports describe open surgical repair of the disrupted parts of the abductor tendons to the greater trochanter and report clinical improvement especially in terms of pain relief (1,7,9,10,16,18). However, a segmental defect may persist in large tears or delayed repairs and direct repair to bone of the hip abductor muscles may be impossible, even with maximal muscle mobilization. In such instances bridging with Achilles tendon allograft (5), synthetic material (1,

INTRODUCTION

Disruption of the hip abductor mechanism may result from spontaneous tears (3) of the hip abductor insertion, failure of an abductor repair after lateral approaches to the hip for hip arthroplasty (9,13,16, 18), avulsion fractures of the greater trochanter or oncologic resections. Disruption of the hip abductor mechanism may be associated with intractable pain, limping, and hip instability especially after THA (4). Often misdiagnosed as trochanteric bursitis or postoperative rehabilitation deficit, disruption

-
- Michael Betz, MD, Resident.
 - Patrick O. Zingg, MD, Deputy Head of hip and pelvic surgery.
 - Claudio Dora, MD, Deputy Chief Department of Orthopaedics.
Department of Orthopaedics, Balgrist University Hospital, Zurich, Switzerland.
 - Christian W. Pfirrmann, MD, MBA, Chief, Department of Radiology.
Department of Radiology, Balgrist University Hospital, Zurich, Switzerland.
- Correspondence : Claudio Dora, Department of Orthopedics, Balgrist University Hospital, Forchstrasse 340, CH 8008 Zürich. E-mail : claudio.dora@balgrist.ch
© 2012, Acta Orthopædica Belgica.
-

14) or advancement of the vastus lateralis muscle (2) have been proposed.

Vastus lateralis advancement has been occasionally used in our institution and the purpose of the present investigation was to review this experience and to document clinical results and donor site morbidity.

PATIENTS AND METHODS

Patients

During the years 2005-2010 eleven consecutive patients with irreparable hip abductor tears underwent advancement of the vastus lateralis muscle in our institution. All presented with intractable pain and limping and had undertaken a trial of active and passive physical therapy of at least three months duration without improvement. Preoperative magnetic resonance imaging (MRI) confirmed gross hip abductor discontinuity in all patients and a residual segmental defect after maximal mobilization of the tendon-muscle unit was predicted. The definitive decision on irreparability and the need for vastus lateralis advancement was made during surgery.

Surgical technique

Surgery was performed in the lateral position. A lateral approach to the greater trochanter was used. The gluteus medius and minimus muscles and tendons were completely separated by sharp dissection from the overlying iliotibial band and tensor fascia latae muscle and the underlying joint pseudocapsule and ilium to permit maximal advancement of the muscle tendon unit. The insertion site on the greater trochanter was debrided back to a bleeding bone surface. When in approximately 30° of hip abduction a residual gap persisted between the end of the hip abductors and the greater trochanter that impaired direct repair, the definite decision for vastus lateralis advancement was made. The incision was extended distally in the direction of Gerdy's tubercle to the proximal border of the patella and the iliotibial band was split longitudinally. According to Beck's original description (2) the entire vastus lateralis was exposed and the interval between rectus femoris and vastus lateralis was developed, facilitating visualization of the neurovascular pedicles to the different heads of the quadriceps muscle (Fig. 1a). After division of its insertion into the quadriceps tendon distally, the plane between the vastus lateralis and intermedius was dissected from distal to

proximal. Once mobilized the neurovascular pedicle was followed back to the femoral nerve but left within the surrounding fatty tissue.

With the leg in approximately 30° of abduction the vastus lateralis was sutured to the remaining abductors and with transosseous sutures to the greater trochanter as well as to the lateral intermuscular septum (Fig. 1b). Postoperatively touch weight bearing was allowed in an abduction splint which was worn for 6 weeks. Abductor strengthening exercises were started after six weeks.

Follow-up examination

Ethics Committee approval was obtained. Two patients (1 and 3) had died from causes unrelated to the index surgery, leaving 9 patients for follow-up investigation. All 9 patients gave informed consent to participate. They were asked to participate on a clinical, radiological and MRI follow-up investigation after a minimum follow-up of 12 months (mean : 33 months, range : 12-60 months). Patient benefit was evaluated using standardized questions and the Western Ontario and McMaster University Osteoarthritis Index (WOMAC) score.

The Harris Hip Score (HHS) was recorded and hip abductor strength was measured in the lateral position and graded from M0 to M5 according to the Medical Research Council scale (12) (Table I). Quadriceps muscle strength was measured with the Isobex device in kilograms and the presence of any knee extension lag was recorded.

Antero-posterior pelvic and cross table lateral radiographs were obtained to evaluate femoral offset, implant loosening and leg length discrepancy.

An MRI of the hip abductors was acquired following a protocol described by Pfirrmann *et al* (15). The integrity of the reconstruction was assessed and the grade of muscle fatty infiltration graded according to Goutallier *et al* (8) on two different planes (at one third and two thirds of the distance between the iliac crest and the tip of the greater trochanter).

Additionally, an MRI scan of both thighs was acquired and fatty infiltration of the advanced vastus lateralis muscle and the remaining muscles of the quadriceps femoris graded at four different planes (at the tip of the greater trochanter and 5, 10 and 15 cm distally) and compared to the non-operated side.

Because of the small sample size few statistical analyses were performed. A paired two sided t-test was used when bilateral and pre- and postoperative continuous variables were compared.

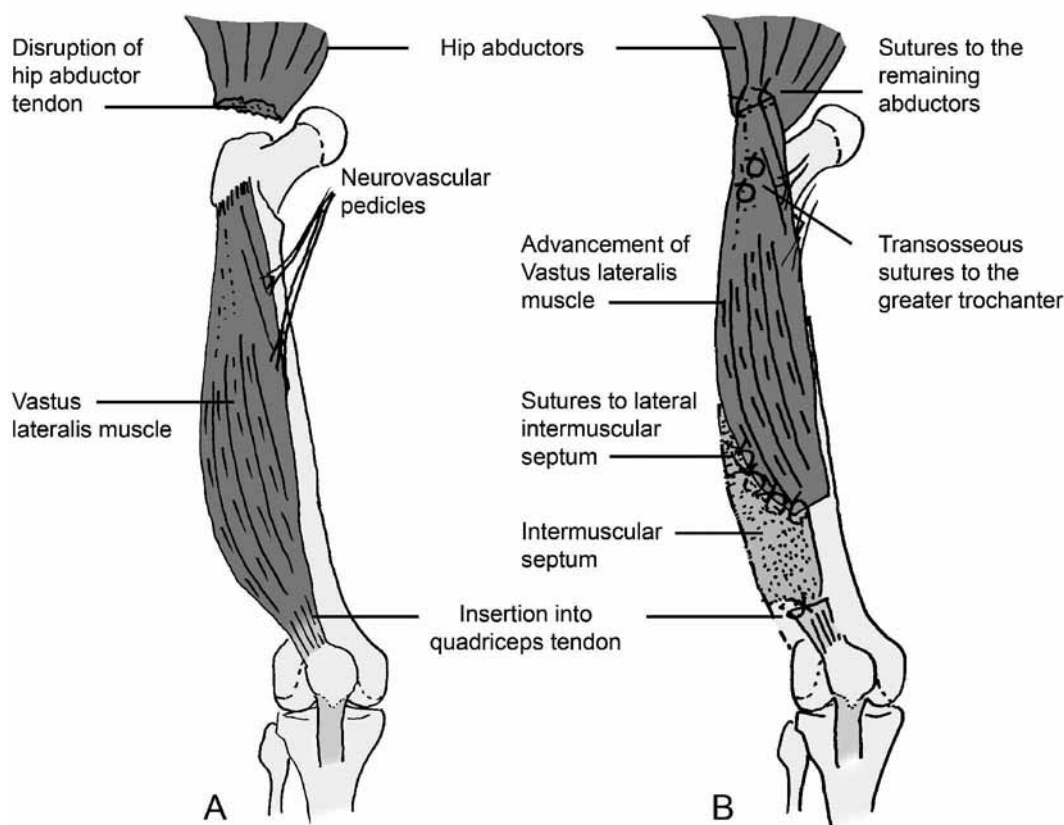


Fig. 1. — A) Exposed vastus lateralis muscle with neurovascular pedicle ; B) Advanced vastus lateralis muscle sutured to the remaining abductors, the greater trochanter and the intermuscular septum.

Table I. — Medical Research Council Scale

M0	No contraction
M1	Flicker or trace contraction
M2	Active movement, with gravity eliminated
M3	Active movement against gravity
M4	Active movement against gravity and resistance
M5	Normal power

RESULTS

Patient demographics and relevant history are summarized in table II. They are listed in chronological order. Age and BMI averaged 66 years and 27, respectively. Two patients (6 and 8) suffered from spontaneous rotator cuff tear of the hip and had been treated for years with repeated corticoid

infiltration of the trochanteric bursa. The remaining had all undergone primary THA with up to 7 revisions before the index procedure. In 3 patients vastus lateralis advancement was accompanied with revision of the implants and in 1 patient a primary THA was performed during the same surgery. No intraoperative or postoperative complications occurred.

Outcome parameters from the patient questionnaire after a mean follow-up of 33 months are summarized in table III. The WOMAC score, the subjective hip value and the overall satisfaction with the index procedure (mean ± standard deviation) averaged 2.6 ± 1 , $65 \pm 15\%$ and $69 \pm 38\%$, respectively. Three out of 9 patients exhibited improved gait in terms of dependency on walking aids and 5 of 9 patients reported a reduced need of analgesics. Six patients stated that they would

Table II. — Patient's demography and relevant history

Case	Age (y)	Gender	Side	BMI	Origin of tendon defect	Prior revisions	Additional surgeries
1	74	F	L		THA, trochanteric non-union	7	
2	70	F	L	24.2	THA	1	
3	63	M	R	28.7	THA	4	
4	53	F	R	23.4	THA	>5	
5	56	M	R	28.3	THA, recurrent dislocation	5	cup and stem revision
6	63	F	L	35.2	spontaneous	0	
7	65	M	L	27.6	THA, recurrent dislocation	4	cup and stem revision
8	62	F	R	30.1	spontaneous	0	primary THA
9	73	M	L	26.6	THA	5	
10	71	F	L	22.1	THA	> 5	
11	71	F	R	21.6	THA, cup loosening	2	cup revision

Table III. — Outcome from patient's perspective

Case #	F-up in months	WOMAC	Subj. hip value %	Satisfaction %	Would do transfer again	Use of crutches or canes		Pain killers on a daily basis	
						Pre-op	F-up	Pre-op	F-up
1	lost					1			
2	60	5.1	50	50	undecided	1	1	none	none
3	lost					2			
4	57	0.8	70	100	yes	2	0	none	none
5	57	3.7	60	80	yes	2	1	Opiate NSAR	NSAR
6	35	1.5	70	100	yes	1	1	NSAR	none
7	24	2.6	70	100	yes	2	0	NSAR	none
8	20	1.2	80	100	yes	0	0	NSAR	none
9	17	3.8	40	20	no	1	1	NSAR	NSAR
10	14	2.3	60	0	no	1	1	NSAR	NSAR
11	12	2.7	90	70	yes	1	1	NSAR	none

undergo the same treatment again, 1 patient was undecided and 2 were disappointed with the result of surgery and would not have it repeated.

Results from physical examination are summarized in table IV. The average HHS improved from 45 ± 14 preoperatively to 61 ± 17 points postoperatively ($p = 0.04$). Grading of hip abductor strength improved from 3 ± 0.7 to 3.8 ± 1 ($p = 0.02$) and all but one patient showed a limp. Though normal knee range of motion and no knee extension lag was encountered, quadriceps muscle strength was

reduced when compared to the opposite side (8.6 ± 4 kg versus 11.7 ± 5 kg, $p = 0.007$).

Results from imaging are summarized in table V. On conventional radiographs no signs of prosthetic loosening were detected. Mean advancement of the vastus lateralis was 6 ± 2 cm. MRI of the hip abductors and the advanced vastus lateralis revealed a continuous musculotendinous layer covering the greater trochanter in all patients. The advanced vastus lateralis muscle showed higher grade of muscular fatty involution when compared to the opposite

Table IV. — Results from physical examination

Case	HHS		Limp	Abductor strength M0-5		Knee extension lag	Quadriceps strength Kg		Knee ROM, °
	Pre-Op	F-Up		Pre-Op	F-Up		F-Up		
							Donor	Opposite	
1	lost			3					
2	66	50	yes	3	4	0	§	6	130
3	lost			3					
4	59	79	yes	2	2	0	9	11	130
5	34	39	Yes	3	4	0	11	20	95
6	23	72	Yes	3	4	0	7	8	130
7	47	69	no	4	5	0	16	20	130
8	50	75	Yes	4	3	0	6	7	110
9	40	40	Yes	3	4	0	5	7	130
10	31	53	Yes	3	5	0	6	11	130
11	53	53	yes	2	3	0	9	15	130

§ : measurement of quadriceps strength was not possible because of trochanteric hip pain.

Table V. — Results for Imaging

Case	Advan cement cm	Offset compared to opposite side	Integrity of greater trochanter	Integrity of repair	Mean fatty atrophy (Goutallier grade)					
					Vastus lateralis		Quadriceps		Abductors	
					Transfer	Opposite	Donor	Opposite	Pre-op	F-Up
1	lost									
2	10	equal	partial	yes	1	1	1	1	2.9	3.3
2	lost									
4	7	equal	vanished	yes	2	1	1	1	3.2	4
5	8	equal	vanished	yes	1	1	1	1	2.6	3.2
6	4	equal	intact	yes	2.5	1	1	1	3.4	4
7	7	equal	intact	yes	1	1	1	1	3.2	4
8	4	equal	intact	yes	2.25	1	1	1	2.8	4
9	6	reduced	partial	Yes	2	1	1	1	3.2	3.8
10	4	equal	intact	Yes	1.25	1	1	1	3.4	4
11	5	equal	vanished	yes	2	1	1	1	2.8	3

vastus lateralis muscle (1.7 ± 0.6 versus 1, $p = 0.01$). The grade of muscular fatty involution of the gluteus medius and minimus muscle increased when compared to the pre-operative MRI from 3 ± 0.3 to 3.7 ± 0.4 ($p = 0.0001$). Fatty involution within the remainder of the quadriceps muscles on MRI did not differ between the donor site and the opposite side.

DISCUSSION

The present investigation deals with gross disruption of the hip abductor mechanism, which is not amenable to direct repair due to the extent and grade of retraction. Advancement of the vastus lateralis muscle has been described and studied on anatomical specimens for such situations by Beck

et al and used in 3 patients with promising results (2). We are not aware of other reports on clinical outcome after this procedure in the current literature and aimed to assess patient's benefit and possible donor site morbidities after this procedure.

From a technical point of view advancement of the vastus lateralis muscle up to 10 cm was achieved in our patients, which is similar to the 7 to 10 cm reported by Beck *et al* (2). Having encountered no complications in our series we conclude that the technique is safe.

With respect to the recorded WOMAC, HHS and subjective hip value at follow-up, the outcomes recorded were poor, especially if they are compared to outcomes after primary and simple revision arthroplasty. Rajkumar *et al* reported improvement of the HHS from 77 to 87 points and patient satisfaction in 9 out of 11 patients after gluteus medius repair following hip arthroplasty (16).

Even when compared to the mean HHS of 75 points reported after late direct repair of abductor avulsions in a similar patient population by Miozzari *et al* (13), the results of the present series are inferior. A high proportion of patients in the present series had undergone repeated prior revision surgeries of their hip, which not only explains the irreparable extent of the hip abductor disruption, but also illustrates the generally poor situation of the hip and its surrounding soft tissue envelope. Nevertheless, when compared to the preoperative status the majority of patients got some benefit in terms of reduced analgesic requirement and reduced dependency on gait assistive devices or both. This is also reflected by an overall improved HHS at follow-up and by an overall patient satisfaction of 69%.

It is a weakness of this investigation that self administered scores such as the WOMAC and the subjective Hip value were not recorded before the index procedure. A further weakness arises from the fact that four patients had additional procedures at the time of vastus lateralis advancement potentially biasing the impact of the latter on outcome.

Unfortunately the size of our case series was too small to allow identifying factors associated with poorer outcomes. The impact of offset restoration

and the integrity of the greater trochanter on outcome for example cannot be estimated from the presented data. Nevertheless, we feel that bony reconstruction of a vanished greater trochanter could improve the hip abductor lever arm and thus consider doing so in future cases.

MRI investigations revealed that advancement of the vastus lateralis muscle was associated with mild fatty infiltration of the muscle in all cases. The two most probable explanations for this phenomenon are: 1) a mechanical effect due to release of the vastus lateralis tendon and fixation with altered tension, allowing the muscle to retract to some extent. In a sheep model it has been shown that tenotomy and subsequent retraction of a musculotendinous unit lead to muscular atrophy and fatty infiltration (6); 2) Partial denervation of the vastus lateralis muscle during mobilization leading to the same phenomenon. Both mechanisms are inherent to the act of advancement.

In terms of donor site morbidity, MRI investigation showed no differences in the grade of fatty muscular infiltration between the remainder of the quadriceps on the operated and the non-operated sides. We therefore conclude that any neurological impairment of the remaining muscle bellies of the quadriceps muscle due to mobilization of the vastus lateralis muscle is minimal. Despite that, when compared to the opposite side, strength of the quadriceps muscle on the operated side was significantly less. To what extent this muscular deficit results from a muscular rehabilitation deficit secondary to a poor hip function and repeated surgical hip revision surgeries or to the advancement of the vastus lateralis itself can not be clarified with our data. Nevertheless, a knee extension lag or reduced knee range of motion were not encountered in our series.

In summary, the reconstruction of irreparable discontinuities of the hip abductor mechanism using advancement of the vastus lateralis muscle proved a reliable and safe technique for bridging 7 to 10 cm defects without relevant donor site morbidity. Small clinical improvements were documented in the majority of patients but overall hip function remained modest.

REFERENCES

1. **Bajwa AS, Campbell DG, Comely AS, Lewis PL.** Gluteal tendon reconstruction in association with hip arthroplasty. *Hip Int* 2011 ; 21 : 288-292.
2. **Beck M, Leunig M, Ellis T, Ganz R.** Advancement of the vastus lateralis muscle for the treatment of hip abductor discontinuity. *J Arthroplasty* 2004 ; 19 : 476-480.
3. **Bunker TD, Esler CAN, Leach WJ.** Rotator- cuff tear of the hip. *J Bone Joint Surg* 1997 ; 79-B : 618-620.
4. **Daly PJ, Morrey BF.** Operative correction of an unstable total hip arthroplasty. *J Bone Joint Surg* 1992 ; 74-A : 1334-1343.
5. **Fehm MN, Huddleston JI, Burke DW, Geller JA, Malchau H.** Repair of deficient abductor mechanism with Achilles tendon allograft after total hip replacement. *J Bone Joint Surg* 2010 ; 92-A : 2305-2311.
6. **Gerber C, Meyer DC, Schneeberger, Hoppeler H, von Rechenberg B.** Effect of tendon release and delayed repair on the structure of the muscles of the rotator cuff : an experimental study in sheep. *J Bone Joint Surg* 2004 ; 86-A : 1973-1982.
7. **Giurea A, Paternostro T, Heinz-Peer G, Kaider A, Gottsauner-Wolf F.** Function of reinserted abductor muscles after femoral replacement. *J Bone Joint Surg* 1998 ; 80-B : 284-287.
8. **Goutallier D, Postel JM, Bernageau J, Lavau L, Voisin MC.** Fatty muscle degeneration in cuff ruptures. Pre- and postoperative evaluation by CT scan. *Clin Orthop Relat Res* 1994 ; 304 : 78-83.
9. **Groot D, Van Ooij A, Haverkamp D, Morrenhof W.** Repair of gluteus medius muscle avulsion following transgluteal hip replacement. *Hip Int* 2011 ; 21 : 284-287.
10. **Lübbecke A, Kampfen S, Stern R, Hoffmeyer P.** Results of surgical repair of abductor avulsion after primary total hip arthroplasty. *Arthroplasty* 2008 ; 23 : 694-698.
11. **McGrory BJ, Morrey BF, Cahalan TD, An K, Cabanela ME.** Effect of femoral offset on range of motion and abductor strength after total hip arthroplasty. *J Bone Joint Surg* 1995 ; 77-B : 865-869.
12. **Medical Research Council.** Aids to examination of the peripheral nervous system. Memorandum no. 45. London : Her Majesty's Stationery Office ; 1976.
13. **Miozzari HH, Dora C, Clark JM, Nötzli HP.** Late repair of abductor avulsion after the transgluteal approach for hip arthroplasty. *J Arthroplasty* 2010 ; 25 : 450-457.
14. **Ozaki T, Kaniko S, Kunisada T et al.** Reconstruction of the hip abductors after resection of the proximal femur. *Int Orthop* 1999 ; 23 : 182-183.
15. **Pfarrmann CWA, Nötzli HP, Dora C, Hodler J, Zanetti M.** Abductor tendons and muscles assessed at MR imaging after total hip arthroplasty in asymptomatic and symptomatic patients. *Radiology* 2005 ; 235 : 969-976.
16. **Rajkumar S, Singer GC, Jones JR.** Results following repair of gluteus medius defects following total hip arthroplasty. *Hip Int* 2011 ; 21 : 293-298.
17. **Voos JE, Shindle MK, Pruett A, Asnis PD, Kelly BT.** Endoscopic repair of Gluteus medius tendon tears of the hip. *Am J Sports Med* 2009 ; 37 : 743-747.
18. **Weber M, Berry DJ.** Abductor avulsion after primary total hip arthroplasty. Results of repair. *J Arthroplasty* 1997 ; 12 : 202-206.