



## Diagnostic accuracy of ACL tears according to tear morphology

Ajit K. DHILLON, Oday AL-DADAH, Christopher T.J. SERVANT

From Ipswich Hospital, Ipswich, U.K.

This retrospective analysis of 182 consecutive patients who underwent anterior cruciate ligament (ACL) reconstruction aimed to assess the clinical examination under anaesthetic and the MRI diagnostic accuracy of arthroscopically-proven, complete ACL ruptures, depending on the morphology of the torn ligament. Patients were then assigned to Group 1 (ACL not re-attached) or Group 2 (ACL re-attached abnormally). Of 104 patients (57.1%) in Group 2, 94 (51.7%) had an abnormal re-attachment of the torn ACL to the posterior cruciate ligament (PCL). There was no significant difference between the groups on MRI reporting of a complete ACL tear ( $p = 0.123$ ) and pivot shift test. On Lachman testing, more patients in Group 1 had an increased laxity compared with Group 2 ( $p = 0.014$ ); similarly, more patients in Group 1 had an absent endpoint compared with Group 2 ( $p = 0.008$ ).

An ACL-deficient knee with an abnormal re-attachment of the torn ligament appears to be more difficult to diagnose than if there has been no re-attachment.

**Keywords :** ACL ; Lachman test ; pivot shift ; laxity ; IKDC.

### INTRODUCTION

A complete anterior cruciate ligament (ACL) injury may be diagnosed on clinical examination, on radiological investigation using magnetic resonance imaging (MRI) or at arthroscopy. Some completely ruptured ACL's may re-attach abnormally, for

instance the torn ends may re-attach to form an elongated ACL, or the torn ACL may re-attach to the posterior cruciate ligament (PCL) (1,4,5,10). Although the ACL is functionally incompetent, it is our anecdotal experience that an abnormally healed ACL may produce knee laxity that is more difficult to assess on clinical examination and the corresponding MRI scan may be interpreted as showing an intact or partially torn ACL (1,3,4).

Although this view may be shared by other surgeons, it is not supported by much concrete evidence. There is little in the published literature on how the morphology of an ACL tear may affect the clinical examination of ACL laxity, although studies using intra-operative arthrometry (1,5) showed that arthrometer laxity measurements were reduced in cases where the ACL had re-attached abnormally compared to cases where the ACL was absent.

- Ajit K. Dhillon, MBBS, MRCS, General Surgery, Core Surgical Trainee Year 2.
- Oday Al-Dadah, MD, FRCS (Tr & Orth), Specialist Registrar, Trauma and Orthopaedics.
- Christopher T.J. Servant, FRCS (Tr & Orth), Consultant Trauma and Orthopaedics.

*Ipswich Hospital, Heath Road, Ipswich, IP4 5PD, U.K.*

Correspondence : Ajit K. Dhillon, General Surgery, Kettering General Hospital, Rothwell Road, Kettering. NN16 8UZ, United Kingdom. E-mail : ajitdhillon@doctors.org.uk

© 2013, Acta Orthopædica Belgica.

MRI is often performed to confirm or refute the clinical diagnosis of a suspected ACL injury. The accuracy of MRI in confirming a complete ACL injury has been studied widely (3) but the published studies do not differentiate between acute and chronic ACL injuries. This is despite the fact that it has been recognised that the MRI appearances of acute and chronic ACL tears differ (10,12).

The aim of this study was to review a cohort of patients who had undergone ACL reconstruction surgery and compare the intra-operative appearance of the ACL with the pre-operative clinical and MRI assessment. Our hypothesis was that an ACL tear which re-attaches abnormally results in less clinical and subjective laxity and may produce more normal appearances on MRI compared with an ACL tear that does not re-attach, such that it may be reported incorrectly.

## PATIENTS AND METHODS

This study was a retrospective analysis of prospectively collected data from the senior author's database; hence a power calculation was not carried out. The senior author was not blinded to the data as it accumulated. The sample analysed was a total of 182 consecutive patients who underwent ACL reconstruction between 2007 and 2011. In all cases the clinical diagnosis of a complete ACL injury was made after examination by the senior author, either after clinical examination or MRI scan, or both if there was diagnostic uncertainty. Specifically we compared patients with ACL tears which had not re-attached with patients with ACL tears which had re-attached abnormally.

Pre-operative clinical function was assessed using the IKDC Committee subjective knee form (2), which generates a score based on a patient's symptoms, function and sporting activity. An MRI scan was performed using a 1.5T Achieva Intera Nova MR system (Philips Healthcare, Guildford, Surrey, UK) with a 16 channel sense knee coil. The knee protocol was standardised to include coronal, axial and sagittal proton density-weighted turbo spin echo sequence with fat saturation (TR/TE 2671/15, FOV 250 mm, 3.5 mm slice thickness, 512 matrix), with sagittal T1-weighted turbo spin echo sequence (TR/TE 500/100, FOV 180 mm, 3 slice thickness, 256 matrix). One hundred thirty patients had an MRI scan, either prior to being seen in the senior author's outpatient clinic or after being examined by the senior author, if further diag-

nostic information was required. It is not the senior author's practice to request MRI routinely for suspected ACL-deficient knees. MRI is reserved for those cases where the clinical examination of ACL laxity is equivocal or if a significant associated injury is suspected (e.g. a locked knee with a possible prolapsed meniscal tear). All MRI scans were reported by one of 3 senior musculoskeletal radiologists. Twenty six patients in Group 1 and 26 patients in Group 2 did not undergo an MRI scan of their knee and so were excluded from the MRI data analysis.

At the time of surgery an examination under anaesthesia (EUA) was performed by the senior author. The examination included (a) a Lachman test, recording the degree of anterior laxity (normal, 3-5 mm, 6-10 mm or greater than 10 mm) and the quality of the end-point (firm, indeterminate or absent), and (b) a pivot shift test, recording the amount of shift (normal, glide, clunk or gross). No arthrometry was performed.

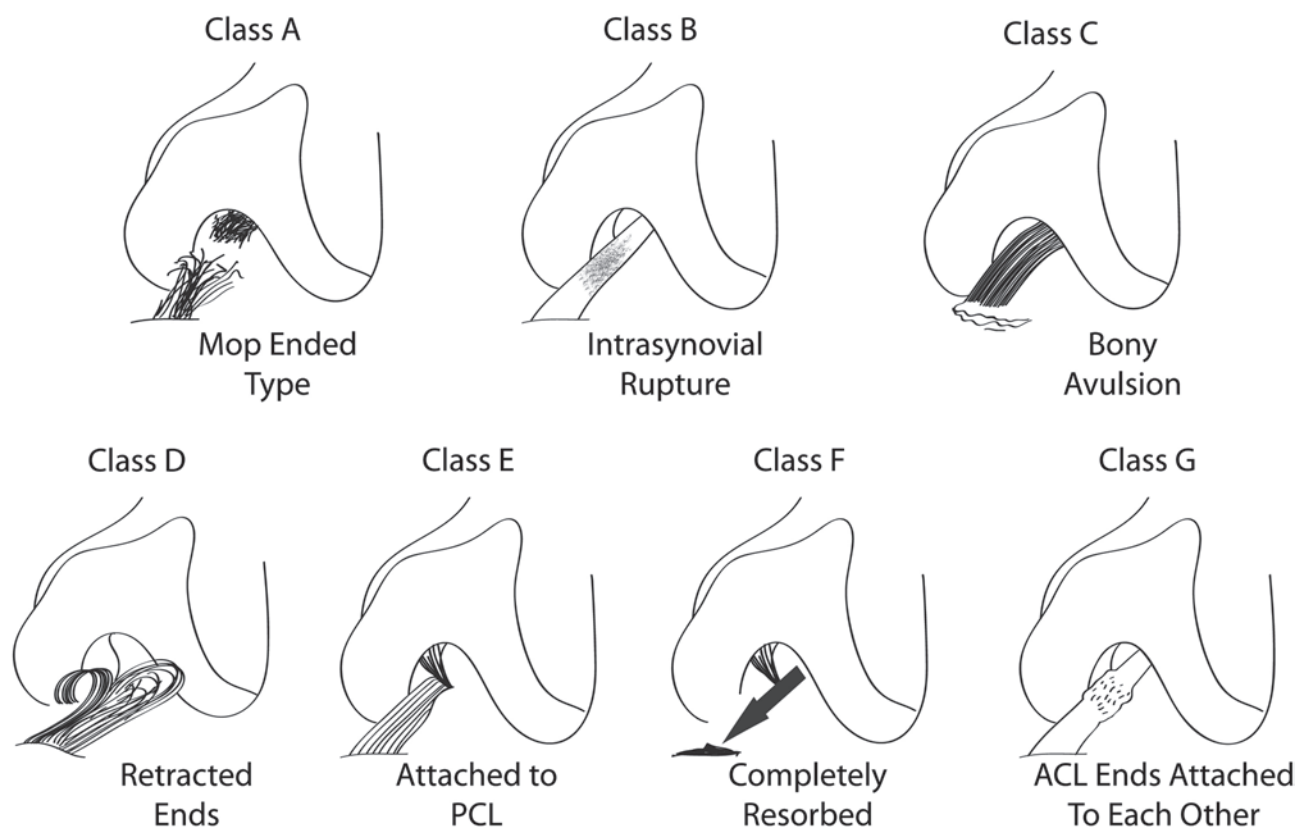
Intra-operatively the arthroscopic appearance of the injured ACL was classified according to the modified Gachter classification used by Lo *et al* (4) (Fig. 1). Patients were divided into two groups depending on the appearance of the injured ACL: Group 1 included injured ACLs without an intra-articular re-attachment (classes A, C, D & F), and Group 2 included injured ACLs with an intra-articular re-attachment (classes B, E & G).

## Statistical analysis

The unpaired Student's *t*-test was used to analyse the IKDC results and the 2-tailed Fisher's exact test was used to analyse all the remaining (categorical) data variables. Statistical analysis was performed using GraphPad statistics software (Version 5, San Diego, California). The statistical significance level was set at  $p < 0.05$ .

## RESULTS

The patient demographic details are shown in Table I. Although the mean age in both groups did not differ, the ratio of males to females in Group 1 was slightly higher than in Group 2. The IKDC scores for both groups were not significantly different ( $p = 0.977$ ), with mean scores of 50.6 (14.9-88.5) for Group 1 and 50.5 (23.0-79.3) for Group 2 as shown in Table III. For Group 2 the mean time from injury to MRI scan was approximately 13 weeks longer and the time from injury to surgery



**Fig. 1.** — Classification of the intra-articular morphology of the anterior cruciate ligament disruptions. Class H (not shown) is defined as a combination of 2 or more classes (reproduced with permission from Lo IK, de Maat GH, Valk JW, Frank CB. The gross morphology of torn human anterior cruciate ligaments in unstable knees. *Arthroscopy* 1999 ; 15 : 301-306).

was approximately 6 weeks longer than for Group 1. The fresh lesions (i.e. less than 6 weeks after injury) were not separated as they were too few in number to allow for meaningful analysis.

The intra-operative findings showed that 78 (42.6%) patients had no re-attachment of the torn ACL (Group 1). The remaining 104 (57.4%) patients had an abnormal re-attachment of the ACL (Group 2). The majority of abnormal re-attachments were to the PCL, as shown in Table II.

### MRI findings

Of the patients who did undergo MRI, a greater proportion of the patients in Group 1 were reported correctly as having a completely torn ACL (Table IV). The difference between the two groups was not statistically significant ( $p = 0.123$ ).

### Clinical examination findings

Whilst 98.7% of patients in Group 1 and 89.4% of patients in Group 2 had laxity on a Lachman test of greater than 5 mm, 1.3% and 10.6% of the patients respectively had a statistically significant ( $p = 0.014$ ) lesser laxity of 3-5 mm (Table IV). Similarly, 7.7% of the patients in Group 1 were found to have a firm or indeterminate endpoint, compared with 23.1% of the patients in Group 2 ( $p = 0.008$ ).

On pivot shift testing, 7.7% of the patients in Group 1 and 18.3% of the patients in Group 2 were found to have only a glide on pivot shift testing. Although these results showed a strong trend between the two groups, the difference did not quite reach statistical significance ( $p = 0.050$ ).

Table I. — Patient Demographics

	Group 1	Group 2
Mean Age (yrs)	29.6	29.9
Gender Ratio (M:F)	5:1	3:1
Knee Ratio (Left:Right)	38:4	52:5
Mean time from injury to MRI (wks)	79.9	92.9
Mean time from injury to Surgery (wks)	117.3	123.1

Table II. — Prevalence of each type of tear on arthroscopy

Category	Arthroscopic findings	Number (%)
A	Mop-ended (frayed ends)	11 (6.0)
B	Intra-synovial (in-substance) tear	0
C	Bony avulsion	1 (0.9)
D	Retracted ends ('Cyclops' lesion)	7 (3.9)
E	Re-attachment to PCL	94 (51.7)
F	Complete resorption (absent)	55 (30.2)
G	Re-attachment of torn ends (elongated)	10 (5.5)
H	Combination of more than 1 group	4 (2.2)

Table III. — Pre-operative IKDC score

Total n = 182	IKDC	
	Mean (SD ; Range)	p value* (95% CI)
Group 1 (n = 78)	50.6 (16.1 ; 14.9-88.5)	0.977  (-5.7 to 5.8)
Group 2 (n = 104)	50.5 (13.8 ; 23.0-79.3)	

Group 1 = No re-attachment of ACL Tear

Group 2 = Re-attachment of ACL Tear

\* Unpaired Student's *t*-test.

## DISCUSSION

We found that a re-attached ACL was statistically less likely to be associated with a strongly positive Lachman test. There was also a non-significant trend for such knees to be less likely to produce a clunk on pivot shift testing. On MRI there was a non-significant trend for re-attached ACLs to be

more difficult to diagnose. There was no difference in the patients' subjective experience, as recorded on IKDC questionnaires. Allowing for variations in patient groups studied, the pre-operative IKDC scores were similar to those reported by Osti *et al* (6).

Others (1,5,7,8) have reported that completely ruptured ACLs can heal but often the torn ligament re-attaches abnormally and so the healing is non-

Table IV. — Surgical, radiological and clinical findings

Total n = 182		MRI			Lachman Laxity			Lachman Endpoint			Pivot Shift		
		Intact / Partial Tear	Complete tear	p value*	3-5 mm	> 5 mm	P value*	Firm / Indeterminate	Absent	p value*	Glide	Clunk / Gross	p value*
Group 1 (n = 78)	N	7	45	0.123	1	77	0.014**	6	72	0.008**	6	72	0.050
	%	13.5	86.5		1.3	98.7		7.7	92.3		7.7	92.3	
Group 2 (n = 104)	N	20	58		11	93		24	80		19	85	
	%	25.6	74.4		10.6	89.4		23.1	76.9		18.3	81.7	

Group 1 = No re-attachment of ACL Tear (26 patients excluded from MRI analysis)

Group 2 = Re-attachment of ACL Tear (26 patients excluded from MRI analysis)

\*2-tailed Fisher's Exact Test

\*\*Statistically significant at  $p < 0.05$ .

functional. Lo *et al* (4) found that 72% of their patients who underwent ACL reconstruction had re-attachment of the torn ACL to the PCL. This tear pattern was present in 57.1% of our patients. Our results show that, when comparing patients with and without re-attachment of the torn ACL, there was a statistically significant difference on Lachman testing with regards to both the degree of anterior laxity and the quality of the endpoint. A re-attached ACL was associated more often with lesser laxity (3-5 mm rather than greater than 5 mm) and a firm endpoint. Both groups of patients demonstrated a positive pivot shift test, as would be expected in a group of patients undergoing ACL reconstruction. However, there was a strong but non-significant trend for more patients to demonstrate a pivot glide, rather than a pivot clunk, if the ACL had re-attached. There was a greater degree of diagnostic inaccuracy on MRI if the ACL had re-attached abnormally, although this did not reach statistical significance. This may have been due to a type II statistical error as 29% of the patients did not undergo MRI and so this aspect of the study may have been underpowered. Those patients who did not undergo pre-operative MRI are more likely to have had ACL injuries that were straightforward to diagnose clinically.

We believe that this is the first study to analyse the accuracy of clinical examination and MRI based on the ACL injury pattern, specifically on whether the ACL has re-attached or not. Other studies (7,9) have assessed the accuracy of clinical examination

and MRI for all ACL injuries but have not differentiated between different patterns of ACL injury or between acute and chronic injuries.

#### Accuracy of clinical examination versus MRI

Rayan *et al* (7) assessed clinical examination, MRI and arthroscopy for meniscal and ACL injuries. Using arthroscopy as the gold standard, they found that the diagnostic accuracy was 0.96 for clinical examination and 0.93 for MRI. They concluded that a carefully performed clinical examination could provide an equal, if not better, diagnosis of an ACL injury compared to MRI. They suggested performing MRI only when the clinical signs and symptoms are inconclusive.

In a series of 48 patients who were reported to have complete ACL tears on MRI, Tsai *et al* (9) found that 32 patients were confirmed as having a complete tear at arthroscopy, 39 patients had a positive Lachman test and 30 of these had a complete tear confirmed. The authors calculated a true-positive rate (equivalent to a positive predictive value) of 67% for MRI and 77% for clinical examination using a Lachman test.

#### Accuracy of clinical examination

There is some published evidence on the differences in clinical ACL laxity of acute and chronic injuries. Crain *et al* (1) performed intra-operative ligament arthrometry on a cohort of 48 patients

undergoing ACL reconstruction, both before and immediately after debridement of the ACL remnant. They found that there was a significant increase in anterior laxity after debridement if the ACL had re-attached, either to the PCL, the roof of the notch or abnormally to the lateral wall of the notch. Matsumoto *et al* (5) performed KT-2000 arthrometer measurements on ACL-injured knees prior to ACL reconstruction and found that, although the magnitude of anteroposterior displacement was increased regardless of the presence of an ACL remnant, joint stiffness under an anterior force remained normal when a substantial remnant was present but was significantly reduced when no remnant or only a stump was observed. These findings support the premise that an ACL that re-attaches abnormally may result in a less marked Lachman test than an ACL that does not re-attach.

A systematic review (11) of clinical examination of the knee, comparing the pivot shift test, Lachman test and anterior drawer test, found that a positive pivot shift was best for ruling in an ACL rupture, a negative Lachman test was best for ruling out an ACL rupture, and the anterior drawer test was inconclusive either way. Based on sensitivity and specificity values, the conclusion was that the Lachman test is the best overall test.

### Accuracy of MRI

In a review of MRI for ACL injuries, Klass *et al* (3) quoted sensitivities and specificities of 90-95% and 95-100% from the published literature. However, the focus of their review was on acute ACL injuries. Typically the studies that report the accuracy of MRI in diagnosing a complete ACL injury either include only acute ACL injuries or do not state the chronicity of the injuries. Thus, the accuracy of MRI in diagnosing a chronic ACL injury is unclear. Vlychou *et al* (11) performed MRI using a 3.0T scanner on a group of patients who had sustained an ACL injury at least 3 months previously. They found that MRI correctly detected an ACL tear in all 43 patients. In contrast, Vahey *et al* (10) found that chronic ACL tears were more difficult to diagnose than acute ACL tears. They performed a retrospective evaluation of 81 MRI scans of ACL-

injured knees and correlated the MRI appearance of the ACL with their findings at arthroscopy. They found that there was a sensitivity, specificity and accuracy of 100%, 93% and 96% respectively for acute ACL tears (MRI performed within 6 weeks of injury) and 87%, 93% and 90% respectively for chronic ACL tears (MRI performed more than 6 months after injury). They highlight the fact that chronic ACL injuries may have a confusing appearance due to the presence of healing that may mimic an intact ligament. This is supported by the findings of Yoon *et al* (12), who studied the sequential changes of torn ACLs on MRI. At more than 3 months after injury 59% of knees demonstrated a type 3 morphology of the ACL, which they defined as an ACL either with low signal intensity and a band-like fragmented shape or as "non-visualised". In other words, if visualised on MRI, a chronically injured ACL may mimic an intact ligament.

### Limitations of the study

ACL laxity was assessed using standard clinical tests (the Lachman and pivot shift tests) but no arthrometry was performed. We feel that this should not deter from the clinical relevance of this study as many knee surgeons use standard clinical tests, rather than arthrometry, to determine whether a patient has clinically significant ACL laxity.

Three different radiologists assessed the pre-operative MRI scans. This situation reflects the fact that this was essentially a pragmatic study and it is the usual practice for most surgeons to receive MRI reports from more than one radiologist. We could not calculate the inter-observer reliability of the radiologists as each scan was only reported by one of the three radiologists. The clinical examination and arthroscopic assessment of all the knees in the study were performed by a single surgeon and the data was recorded prospectively, thus minimising bias and eliminating inter-observer error for the clinical data.

We do not know the accuracy of MRI or clinical examination for ACL-deficient knees that did not undergo reconstruction, but usually this has not been assessed within the published literature, given that the gold standard for establishing the diagnosis

of a complete ACL injury is the arthroscopic diagnosis at the time of ACL reconstruction. There were very few patients in the study who underwent reconstruction of the torn ACL acutely i.e. within 6 weeks from injury. Therefore we were not able to compare the findings between acute and chronic ACL tears.

### Clinical relevance of the study

We believe that our findings should be borne in mind when examining a chronic knee injury and when reviewing the MRI scan of a possible chronic ACL injury. The decision to treat a chronic ACL injury should be based on the history and clinical examination. A healed but functionally abnormal ACL may produce less pronounced laxity on performing a Lachman test but should still produce a positive pivot shift test. MRI should be interpreted with caution as the re-attached ligament may be confused with a partially injured or uninjured ligament.

### Acknowledgement

Copyright permission via RightsLink, Copyright Clearance Centre, to include Figure 1, from Lo IK, de Maat GH, Valk JW, Frank CB: The gross morphology of torn human anterior cruciate ligaments in unstable knees. *Arthroscopy* 1999 Apr; 15(3): 301-6.

### REFERENCES

1. **Crain EH, Fithian DC, Paxton EW, Luetzow WF.** Variation in anterior cruciate ligament scar pattern : does the scar pattern affect anterior laxity in anterior cruciate ligament-deficient knees ? *Arthroscopy* 2005 ; 21 : 19-24.
2. **Irrgang JJ, Anderson AF, Boland AL et al.** Development and validation of the International Knee Documentation Committee subjective knee form. *Am J Sports Med* 2001 ; 29 : 600-613.
3. **Klass D, Toms AP, Greenwood R, Hopgood P.** MR imaging of acute anterior cruciate ligament injuries. *Knee* 2007 ; 14 : 339-347.
4. **Lo IK, de Maat GH, Valk JW, Frank CB.** The gross morphology of torn human anterior cruciate ligaments in unstable knees. *Arthroscopy* 1999 ; 15 : 301-306.
5. **Matsumoto H, Toyoda T, Kawakubo M, Otani T, Fujikawa K.** The end-point and the remnant of the injured cruciate ligaments of the knee. *Knee* 1999 ; 6 : 43-47.
6. **Osti L, Papalia R, Buono AD et al.** Surgery for ACL deficiency in patients over 50. *Knee Surg Traumatol Arthrosc* 2011 ; 19 : 412-417.
7. **Rayan F, Bhonsle S, Shukla DD.** Clinical, MRI, and arthroscopic correlation in meniscal and anterior cruciate ligament injuries. *Int Orthop* 2009 ; 33 : 129-132.
8. **Scholten RJ, Opstelten W, van der Plas CG et al.** Accuracy of physical diagnostic tests for assessing ruptures of the anterior cruciate ligament : a meta-analysis. *J Fam Pract* 2003 ; 52 : 689-694.
9. **Tsai K, Chiang H, Jiang C.** Magnetic resonance imaging of anterior cruciate ligament rupture. *BMC Musculoskeletal Disorders* 2004 ; 5 : 21.
10. **Vahey TN, Broome DR, Kayes KJ, Shelbourne KD.** Acute and chronic tears of the anterior cruciate ligament : differential features at MR imaging. *Radiology* 1991 ; 181 : 251-253.
11. **Vlychou M, Hantes M, Michalitsis S et al.** Chronic anterior cruciate ligament tears and associated meniscal and traumatic cartilage lesions : evaluation with morphological sequences at 3.0 T. *Skeletal Radiol* 2011 ; 40 : 709-716.
12. **Yoon JP, Chang CB, Yoo JH et al.** Correlation of magnetic resonance imaging findings with the chronicity of an anterior cruciate ligament tear. *J Bone Joint Surg* 2010 ; 92-A : 353-360.