



## The effect of shoulder manipulation on rotator cuff integrity

Ehud ATOUN, Lennard FUNK, Stephen A. COPLAND, Tirtza EVEN, Ofer LEVY, Ehud RATH

*From the Royal Berkshire Hospital, Reading, Berkshire, United Kingdom*

The use of shoulder manipulation in the treatment of frozen shoulder remains controversial. Humeral fractures and neurological damage are the risks associated with the procedure. A concern of causing a rotator cuff tear exists but the incidence of iatrogenic rotator cuff tears is not reported. The purpose of this study was to assess the effect of shoulder manipulation for frozen shoulder on the integrity of the rotator cuff.

In a prospective study, 32 consecutive patients (33 shoulders) with the diagnosis of frozen shoulder underwent manipulation of the shoulder under anaesthesia (MUA), 18 female and 15 males with mean age at manipulation of 50.3 years (range : 42-63). The average duration of symptoms before treatment was 6.2 months (range : 2-18 months). The patients were examined prior to the manipulation and at follow-up for combined shoulder range of motion, external and internal rotation and strength. All patients had an ultrasound assessment of the rotator cuff before and at 3 weeks after manipulation of the shoulder. Mean time between manipulation and last follow-up was 13.3 weeks.

None of the patients had ultrasound findings of a rotator cuff tear, prior to the manipulation. In all patients the rotator cuff remained undamaged on ultrasound examination at 3 weeks after the procedure. The mean improvement in motion was 81.2° (from 93.3° pre-op to 174.5° at last follow-up) for forward flexion ; 102.6° (from 68.8° pre-op to 171.4° at last follow-up) for abduction, 49.4° (from 8.8° pre-op to 58.2° at last follow-up) for external rotation and 3.5 levels of internal rotation (range : 2 to 5 levels). These gains in motion were all highly significant ( $p < 0.0001$ ). No fractures, dislocations or nerve palsies were observed.

**In this study, manipulation of the shoulder has not been associated with rotator cuff tears. If done properly the procedure appeared to be safe and to result in a marked improvement of range of movement and function.**

**Keywords :** manipulation ; frozen shoulder ; ultrasound ; rotator cuff tear.

---

### INTRODUCTION

Frozen shoulder is a common cause of shoulder pain and disability. Its prevalence is reported as 2-5% (5,7,14). Although the condition is believed to

- 
- Ehud Atoun, MD, Head of the Shoulder Surgery and Sports Medicine Service.  
*Orthopaedic Department, Faculty of Health Sciences, Ben-Gurion University, Barzilai Medical Center Campus, Ashkelon, Israel.*
  - Lennard Funk, MD, FRCS (Orth), Consultant.  
*Wrightington Hospital, Wigan, Lancashire, United Kingdom.*
  - Stephen A. Copland, FRCS, Consultant.
  - Tirtza Even, MD MSc, Statistician.
  - Ofer Levy MD, MCh Orth, Professor, Consultant.  
*Reading Shoulder Unit, Royal Berkshire Hospital, Reading, Berkshire, United Kingdom.*
  - Ehud Rath, MD, Head of the Minimal Invasive Surgery Unit.  
*Orthopaedic division, Tel Aviv Souraski Medical Center, Tel Aviv, Israel.*  
Correspondence : Ehud Atoun, Barzilai medical center, Ashkelon, Israel. E-mail : dratoun@gmail.com  
© 2013, Acta Orthopædica Belgica.
-

be self-limiting, numerous treatment protocols to relieve pain and accelerate return to normal function have been described, including systemic corticosteroids (1,6), subacromial and/or glenohumeral joint corticosteroid injections (4,18,27), and physical therapy (29,32). Patients who do not progress with conservative management may require manipulation under anaesthesia to relieve pain and restore shoulder range of motion and function (10,11,20,33).

Although reported results of manipulation under anaesthesia have been generally good, the procedure is not without risks and several complications were described including humeral (15,24) and glenoid (19) fractures, shoulder dislocations and subluxations (13,21,30) and brachial plexus injury (3,23). Although iatrogenic rotator cuff tears have been described as a possible complication of manipulation (16,35), we have not found a report in the medical literature of the incidence and mechanism of such risk.

The purpose of this study was to evaluate the incidence of rotator cuff tears associated with manipulation of the shoulder for frozen shoulder.

## MATERIALS AND METHODS

In a prospective study, 32 consecutive patients (33 shoulders) with the diagnosis of idiopathic frozen shoulder underwent manipulation of the shoulder under anaesthesia (MUA).

The inclusion criterion was a global loss of active and passive range of motion in all planes of motion with less than 90 degrees of forward flexion and abduction in the scapular plane and less than 20 degrees of external and internal rotation. Exclusion criteria were trauma to the involved shoulder, previous shoulder operation, diabetes melitus, radiographic evidence of severe osteopenia or glenohumeral arthrosis and evidence of a rotator cuff tear on ultrasound or MRI.

### Clinical Assessment

The patients were examined prior to the manipulation and at follow-up for combined shoulder range of motion, external and internal rotation and strength. Passive range of motion was evaluated and compared to the uninvolved shoulder. The extent of forward elevation, abduction and external rotation in adduction was expressed in degrees. Internal rotation was documented on a scale of 5 accord-

ing to the level the hand of the patient could reach : 1 = thigh, 2 = buttock, 3 = sacrum, 4 = lower lumbar vertebrae, 5 = lower thoracic vertebrae and 6 = between shoulder blades.

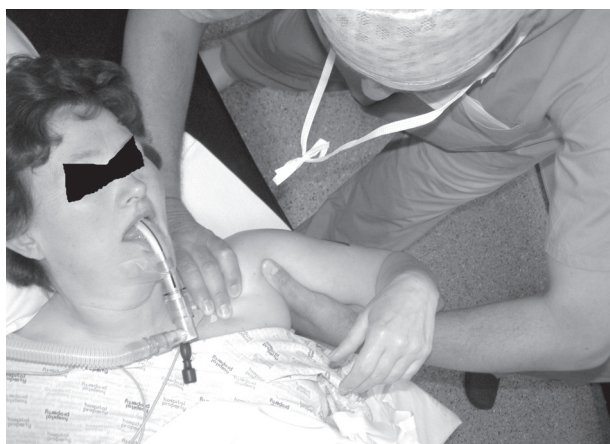Radiographs for anteroposterior and axillary views of the affected shoulder were routinely taken to rule out a concurrent pathology or profound osteopenia. Analysis of the surgical findings and arthroscopic images of capsular tear patterns in patients that underwent arthroscopy after manipulation was performed.

### Ultrasound Scan Technique

All patients underwent diagnostic ultrasonography of the shoulder using an ultrasound scanner a Sonosite 180 (Sonosite, Bothell, WA, USA). Using a linear 3-11 MHz transducer, the depth of the ultrasound was adjusted to accommodate for differences in soft tissue mass among the patients and ranged from 3 to 5 cm. Sonographic assessment was performed before and at 3 weeks after manipulation of the shoulder. All sonographic examinations were performed by a single experienced shoulder surgeon. A systematic sonographic examination of the shoulder was performed assessing the long head of the biceps, the supraspinatus, infraspinatus and the subscapularis tendons in both the longitudinal and the transverse planes.

### Manipulation technique (9)

With the patient supine, under general anaesthesia and interscalene nerve block, a thorough examination of the involved shoulder was performed and the true passive restriction of motion was confirmed. Forward elevation, abduction, external rotation in adduction, external and internal rotation in 90 degrees of coronal plane abduction and cross-body adduction were documented before and after the manipulation. The manipulation was performed in the following order : one hand of the surgeon stabilized the scapula while the other hand held the arm of the patient as close to the axilla as possible to diminish the lever arm acting on the humerus (Fig. 1). The manipulation is carried out in 4 stages : 1) abduction to tear the inferior capsule, at this stage the patient arm is in full abduction and in external rotation (ER) 2) the arm is brought down while in external rotation to the side to tear the anterior capsule 3) cross body adduction is performed to extend the tear of the capsule posteriorly and 4) the arm is internally rotated and an adduction force is applied to complete the capsular tear postero-superiorly. No rotational torque is applied to the arm at any time. A



**Fig. 1.** — Manipulation technique : note the position of the surgeon's hands that diminishes the lever arm force acting on the shoulder.

definitive audible and palpable snap represents capsular tearing may be felt on each manoeuvre. The resultant improvement in range of motion in all directions following manual manipulation was recorded. An interscalene nerve block with Bupivacaine for post operative analgesia was routinely used.

### Rehabilitation and follow-up

Physical therapy was initiated immediately post manipulation. Under an interscalene nerve block, pendulum exercises and passive range of motion exercises were begun. Stretching, passive and active range of motion exercises followed by strengthening of the rotator cuff and scapula stabilizers musculature were encouraged on the following weeks. Patients were followed at 3 and 12 weeks.

### Statistical Analysis

Statistical comparison between the preoperative and outcome range of motion was performed with the use of the Student t-test. The level of significance was set at  $p < 0.05$ .

Statistical Analysis was carried out using SAS release 8.2.

## RESULTS

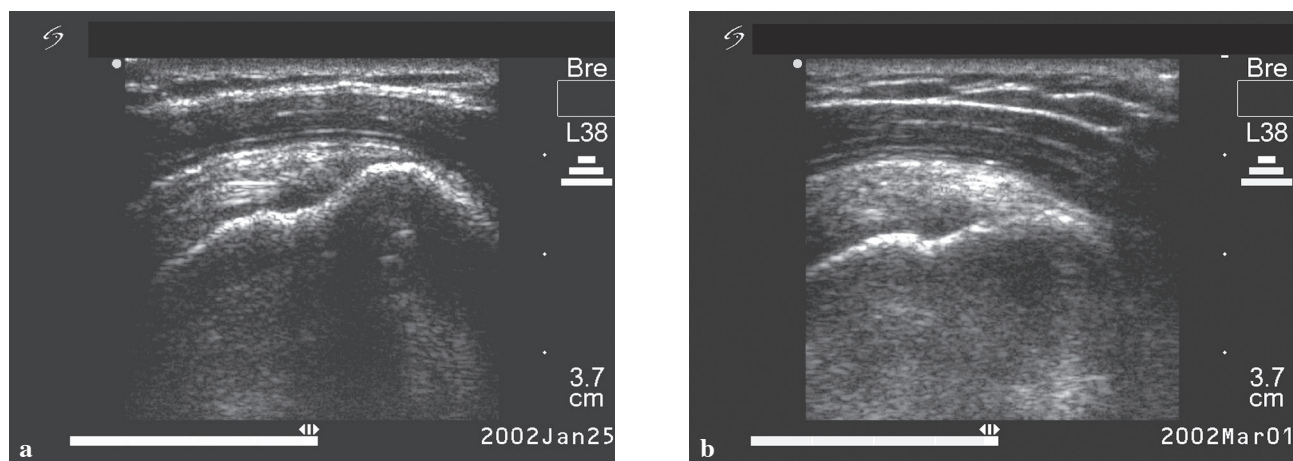
Eighteen female and 15 male patients matched our inclusion and exclusion criteria. The right shoulder

was affected in 18 patients, the left shoulder in 15 (one patient had bilateral involvement). The mean age at manipulation was 50.3 years (range : 42-63), average duration of symptoms before treatment was 6.2 months (range : 2-18 months). All patients had a trial of physical therapy for 6 to 12 weeks before considering manipulation. The mean follow-up was 13.3 weeks (range : 10 to 16).

All patients demonstrated immediate improvement in passive motion after manipulation. The mean improvement in motion was  $81.2^\circ$  (from  $93.3^\circ$  pre-op to  $174.5^\circ$  at last follow-up) for flexion ;  $102.6^\circ$  (from  $68.8^\circ$  pre-op to  $171.4^\circ$  at last follow-up) for abduction,  $49.4^\circ$  (from  $8.8^\circ$  pre-op to  $58.2^\circ$  at last follow-up) for external rotation and 3.5 levels of internal rotation (range : 2 to 5 levels). These gains in motion were all highly significant ( $p < 0.0001$ ). All patients stated that they had no pain or only occasional, mild discomfort when using the shoulder forcefully. Ultrasound assessment prior to manipulation showed intact normal looking rotator cuff in all patients. At 3 weeks no rotator cuff tear was observed by ultrasound. Figures 2a and 2b demonstrate intact rotator cuff in a pre- and post-manipulation ultrasound examination. No fracture, dislocation, nerve damage or rotator cuff tear was reported. No other complications after manipulation were recorded.

## DISCUSSION

Frozen shoulder is still an enigma. The precise trigger or cause is unknown ; however, several theories exist regarding the aetiology. Several studies have suggested a pathological process similar to Dupuytren's contracture (8,22). Although the natural history of the condition is for spontaneous resolution in most cases, studies on the natural history of this condition have shown that resolution of the disease often takes up to 2 to 3 years and even more (12,15,28). Long term follow-up of patients treated conservatively shows measurable restriction in 39 to 76 % of patients and persistent symptoms in as many as 45 % (2,25,28). As it is difficult to predict the exact time-course of the disease for any particular patient there is a place to consider surgical intervention such as manipulation under anaesthesia and



**Fig. 2a & 2b.** — Ultrasound assessment of the shoulder (a) Pre- and (b) post-manipulation. An intact rotator cuff is demonstrated in both examinations.

injection to the shoulder with local anaesthetic and steroid. Manipulation under anaesthesia is performed in an effort to alter the natural course of this disease. The duration of stiffness is shortened and the eventual range of motion has been shown to improve with this intervention (10,17,26,31). At our unit, patients are candidates for manipulation at the second stage of frozen shoulder, when the pain subsides or plateaus and no progress in physical therapy is noted (10). We believe it is crucial to wait for the painful phase to resolve before manipulation is considered. In this series of patients the average duration of symptoms before treatment was 6.2 months (range: 2-18). Manipulation of the shoulder is thought to be associated with risk of complications such as humeral fracture, neural injury, and dislocation of the shoulder (15,33,34). Our main question in this study was whether manipulation is associated with increased risk for iatrogenic tearing of the rotator cuff. This prospective study shows that when performed carefully and properly, manipulation causes no iatrogenic tear of the rotator cuff. Ultrasound scan 3 weeks post manipulation showed consistently intact rotator cuff in all patients.

The manipulative manoeuvre starts with abduction of the humerus while the scapula is stabilized. This starts the capsular rupture at the axillary fold. At this stage the patient arm is in full abduction and in external rotation (ER). The arm is brought down

while in external rotation to the side to tear the anterior capsule. Cross body adduction is performed to extend the tear of the capsule posteriorly and the arm is then internally rotated and an adduction force is applied to complete the capsular tear postero-superiorly. No rotational torque is applied to the arm at any time.

In this study we were interested in the early results of manipulation within the first 3 months after the intervention. Similar to previous studies, we have shown that at this stage most of the patients have already achieved substantial improvement with regaining good functional range of motion and pain relief (10,17,26,31).

In our study manipulation of the shoulder has not been associated with rotator cuff tears. If done properly, the procedure was found to be safe and to result in a marked early improvement of range of movement and function, while shortening the overall duration of the process and providing early recovery and return to activity.

## REFERENCES

1. Binder A, Hazleman BL, Parr G, Roberts S. A controlled study of oral prednisolone in frozen shoulder. *Br J Rheumatol* 1986; 25: 288-292.
2. Binder AI, Bulgen DY, Hazleman BL, Roberts S. Frozen shoulder: a long-term prospective study. *Ann Rheum Dis* 1984; 43: 361-364.



3. **Birch R, Jessop J, Scott G.** Brachial plexus palsy after manipulation of the shoulder. *J Bone Joint Surg* 1991 ; 73-B : 172.
4. **Blanchard V, Barr S, Cerisola FL.** The effectiveness of corticosteroid injections compared with physiotherapeutic interventions for adhesive capsulitis : a systematic review. *Physiotherapy* 2010 ; 96 : 95-107.
5. **Bridgman JF.** Periarthritis of the shoulder and diabetes mellitus. *Ann Rheum Dis* 1972 ; 31 : 69-71.
6. **Buchbinder R, Hoving JL, Green S et al.** Short course prednisolone for adhesive capsulitis (frozen shoulder or stiff painful shoulder) : a randomised, double blind, placebo controlled trial. *Ann Rheum Dis* 2004 ; 63 : 1460-1469.
7. **Bunker TD.** Frozen shoulder : unravelling the enigma. *Ann R Coll Surg Engl* 1997 ; 79 : 210-213.
8. **Bunker TD, Anthony PP.** The pathology of frozen shoulder. A Dupuytren-like disease. *J Bone Joint Surg* 1995 ; 77-B : 677-683
9. **Copeland S.** *Operative Shoulder Surgery*. Churchill Livingstone, Edinburgh, 1995, pp 41-44.
10. **Dodenhoff RM, Levy O, Wilson A, Copeland SA.** Manipulation under anesthesia for primary frozen shoulder : effect on early recovery and return to activity. *J Shoulder Elbow Surg* 2000 ; 9 : 23-26.
11. **Farrell CM, Sperling JW, Cofield RH.** Manipulation for frozen shoulder : long-term results. *J Shoulder Elbow Surg* 2005 ; 14 : 480-484.
12. **Grey RG.** The natural history of "idiopathic" frozen shoulder. *J Bone Joint Surg* 1978 ; 60-A : 564-564.
13. **Haines JF, Hargadon EJ.** Manipulation as the primary treatment of the frozen shoulder. *J R Coll Surg Edinb* 1982 ; 27 : 271-275.
14. **Hannafin JA, Chiaia TA.** Adhesive capsulitis. A treatment approach. *Clin Orthop Relat Res* 2000 ; 372 : 95-109.
15. **Harryman DT 2nd, Matsen FA 3rd, Sidles JA.** Arthroscopic management of refractory shoulder stiffness. *Arthroscopy* 1997 ; 13 : 133-147.
16. **Harryman DT LMTss.** In : Rockwood JR CA, Matsen III FA (eds). *The Shoulder*, WB Saunders, Philadelphia, 2004, pp 1121-1172.
17. **Hill JJ, Jr, Bogumill H.** Manipulation in the treatment of frozen shoulder. *Orthopedics* 1988 ; 11 : 1255-1260.
18. **Klinger HM, Otte S, Baums MH, Haerer T.** Early arthroscopic release in refractory shoulder stiffness. *Arch Orthop Trauma Surg* 2002 ; 122 : 200-203.
19. **Magnussen RA, Taylor DC.** Glenoid fracture during manipulation under anesthesia for adhesive capsulitis : a case report. *J Shoulder Elbow Surg* 2011 ; 20 : e23-26.
20. **Neviasser AS, Hannafin JA.** Adhesive capsulitis : a review of current treatment. *Am J Sports Med* 2010 ; 38 : 2346-2356.
21. **Othman A, Taylor G.** Manipulation under anaesthesia for frozen shoulder. *Int Orthop* 2002 ; 26 : 268-270.
22. **Pal B, Griffiths ID, Anderson J, Dick WC.** Association of limited joint mobility with Dupuytren's contracture in diabetes mellitus. *J Rheumatol* 1987 ; 14 : 582-585.
23. **Parker RD, Froimson AI, Winsberg DD, Arsham NZ.** Frozen shoulder. Part II : Treatment by manipulation under anesthesia. *Orthopedics* 1989 ; 12 : 989-990.
24. **Quigley TB.** Treatment of checkrein shoulder by use of manipulation and cortisone. *J Am Med Assoc* 1956 ; 161 : 850-854.
25. **Reeves B.** The natural history of the frozen shoulder syndrome. *Scand J Rheumatol* 1975 ; 4 : 193-196.
26. **Reichmister JP, Friedman SL.** Long-term functional results after manipulation of the frozen shoulder. *Md Med J* 1999 ; 48 : 7-11
27. **Ryans I, Montgomery A, Galway R et al.** A randomized controlled trial of intra-articular triamcinolone and/or physiotherapy in shoulder capsulitis. *Rheumatology (Oxford)* 2005 ; 44 : 529-535.
28. **Shaffer B, Tibone JE, Kerlan RK.** Frozen shoulder. A long-term follow-up. *J Bone Joint Surg* 1992 ; 74-A : 738-746.
29. **Sharma RK, Bajekal RA, Bhan S.** Frozen shoulder syndrome. A comparison of hydraulic distension and manipulation. *Int Orthop* 1993 ; 17 : 275-278.
30. **Thomas D, Williams RA, Smith DS.** The frozen shoulder : a review of manipulative treatment. *Rheumatol Rehabil* 1980 ; 19 : 173-179.
31. **van Royen BJ, Pavlov PW.** Treatment of frozen shoulder by distension and manipulation under local anaesthesia. *Int Orthop* 1996 ; 20 : 207-210.
32. **Vermeulen HM, Rozing PM, Obermann WR et al.** Comparison of high-grade and low-grade mobilization techniques in the management of adhesive capsulitis of the shoulder : randomized controlled trial. *Phys Ther* 2006 ; 86 : 355-368.
33. **Warner JJ.** Frozen Shoulder : Diagnosis and management. *J Am Acad Orthop Surg* 1997 ; 5 : 130-140.
34. **Warner JJ, Allen A, Marks PH, Wong P.** Arthroscopic release for chronic, refractory adhesive capsulitis of the shoulder. *J Bone Joint Surg* 1996 ; 78-A : 1808-1816.
35. **Warner JJP.** Management of the stiff shoulder. Conference Proceeding, the 68th annual meeting, *American Academy of Orthopedic Surgeons* 2001 ; 244-252.