



Stage I compression-extension injury of the cervical spine A rotationally unstable injury

Mohamed Adel EL MASRY, Walaa EL ASSUITY, Daniel CHAN

Stage I compression-extension injury of the cervical spine, as described by Allen *et al*, is not always a stable injury. The combined unilateral failure of the posterior structures under compression together with failure of the anterior structures under tension will lead to rotational instability around the intact lateral mass. We report on 10 consecutive patients who presented with this type of injury. The surgical protocol consisted of early reduction followed by anterior cervical fusion using a tricortical iliac graft and a locking plate. Mean follow-up was 38.5 months. Intra-operative assessment revealed disc injury in all patients. Anatomical realignment and solid fusion were achieved in all cases. All 10 patients showed improvement of their neurological deficit. One patient remained with some residual weakness in his triceps, and another required removal of a prominent screw.

INTRODUCTION

Trauma of the lower cervical spine remains a leading cause of morbidity and mortality. Woodring *et al* (15) reported that 67% of fractures and 45% of subluxations and dislocations of the cervical spine were not detected by routine lateral cervical spine radiographs. It is estimated that 26% of cervical spine injuries are due to a hyperextension mechanism (8).

Fracture classifications based on the mechanism of injury are useful in categorising trauma of the lower cervical spine. The classification of Allen *et al* (1) remains one of the most widely used today. They described five stages of compression-extension injury of the cervical spine, where stage I was

a unilateral fracture of the vertebral arch (either through the articular process, pedicle or lamina) with or without rotatory spondylolisthesis.

Lifeso *et al* (9) reported this fracture as a rotationally unstable injury and hypothesised this fracture pattern to involve “a hyperextension mechanism combined with a degree of lateral tilt or lateral rotation, producing an anterior annular disruption under tension and a unilateral posterolateral mass or lamina fracture under compression, with a resultant rotational instability around the intact lateral mass”.

The purpose of this study was to further define this type of fracture and to assess a method for treatment.

MATERIALS AND METHODS

A prospective study of 10 consecutive patients was conducted between 1996 and 2001. There were 7 males and 3 females, with an average age of 39 years (range 16-70 years). A road traffic accident was the cause of the injury in six cases ; a fall in two others ; various injuries in two more. The C6/7 level was involved in 9 patients,

From the Department of Orthopaedic Surgery, Royal Devon and Exeter Hospital, Exeter, United Kingdom.

Mohamed Adel El Masry, Orthopaedic Surgeon, Spinal Fellow.

Walaa El Assuity, Orthopaedic Surgeon, Spinal Fellow.

Daniel Chan FRCS (Orth.), Consultant Spinal Surgeon.

Correspondence : Mohamed El Masry, 40 Braithwaite Tower, Hall Place, London W2 1LP, UK.

E-mail : drmedoelmasry@yahoo.co.uk.

© 2003, Acta Orthopædica Belgica.

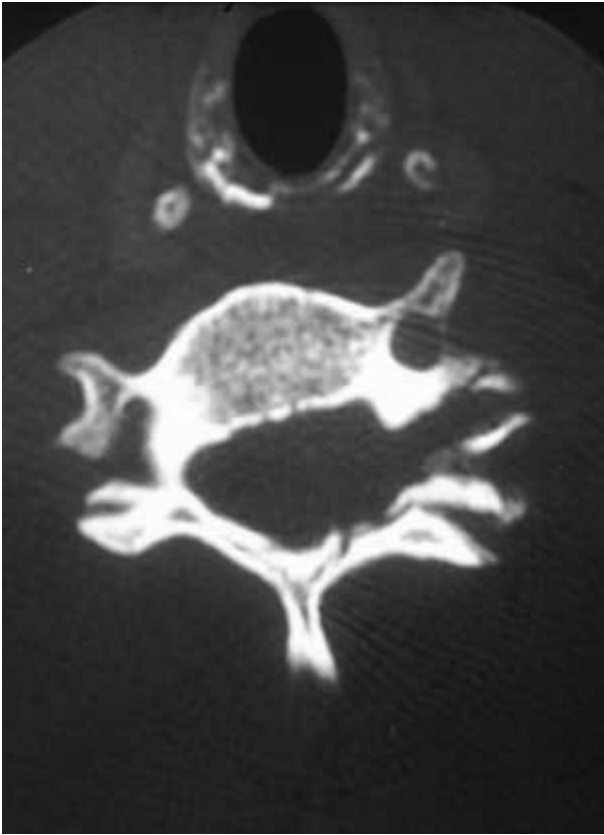


Fig. 1. — CT scan showing the fracture through the left facet joint of C5, extending into the lamina. Rotational spondylolisthesis of C5 around the intact right facet joint of C5.

while the C5/6 level was involved in only one patient. Subluxation was present in all cases and was measured between the posterior edge of the subluxed vertebral body and the posterior edge of the adjacent inferior vertebral body ; an average displacement of 4.5 mm (range 3.8 to 6 mm) was established. Five patients presented with an isolated unilateral fracture through the articular process, three patients with an isolated fracture of the entire lateral mass, and two patients with either an articular or a lateral mass fracture combined with a laminar fracture. Nine patients presented with radiculopathy, while only one patient presented with an incomplete cord injury. All patients were submitted to a neurological assessment, plain radiographs of the cervical spine, and CT scan (fig 1, 2) of the involved segment ; two out of 10 patients also had an MRI scan.

The treatment protocol consisted of reduction at the time of presentation, followed after an average of 6 days (range 0-14 days), by anterior fusion with a tricortical

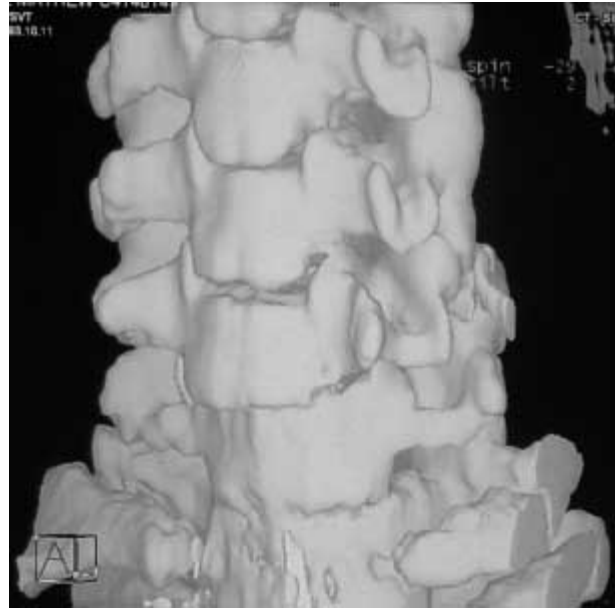

Fig. 2. — 3D reconstruction CT showing the rotatory subluxation of C6/C7.

iliac graft and an anterior self-locking cervical plate. The reduction was easily achieved in all cases by applying traction to the cervical spine in a neutral position using cervical tongs with a maximum weight of 15 kilograms. The fusion was performed through a standard left sided approach. All fusions involved only one disc space. The surgeon looked for any evidence of disc disruption. All patients were allowed to ambulate with a soft cervical collar immediately after surgery. Patients were seen at 6 weeks after surgery and then routinely followed up at 3 and 6 months. A neurological assessment and plain radiographs to assess the fusion were routine. Fusion was considered solid when there was loss of the lucent lines between the graft and the vertebral end plate, and no shift or breakage of the instrumentation. Successful outcome criteria included stabilisation or improvement of a cord deficit, complete recovery from radiculopathy, and anatomic restoration of the spinal column.

RESULTS

The mean follow-up period was 38.5 months (range 7-66 months). There were no intraoperative complications. All patients had improvement of the neurological deficit. The patient with the incomplete cord injury recovered completely from his paraparesis, but remained with a residual impairment in

his right upper limb. All patients with radiculopathy had complete resolution of pain and complete neurological recovery, apart from one patient who remained with some weakness in his left triceps (grade 4) and residual tingling in his left index finger (C7 dermatome). Anatomic realignment without kyphosis, and solid fusion were achieved in all the patients. Only one complication was noted: a screw became prominent and required removal. Intra-operative assessment at screw removal revealed a solid fusion.

DISCUSSION

Bone failure per se is rarely of great significance in lower cervical spine injuries except as a marker for the actual or expected ligamentous failure. In the cervical spine, the anterior two thirds of the vertebral body along with the anterior longitudinal ligament and the annulus fibrosus act as a tension band limiting extension, while the posterior ligaments and bony complex act as a tension band in flexion. The most important anterior structure is the intact annulus fibrosus. The posterior longitudinal ligament provides relative stability, although the joint capsules and the posterior articulations are the most important posterior elements (13). Intra-operatively there was evidence of disc disruption in all the cases; also the two MRI scans done in this study revealed evidence of disc injury. The combination of anterior disc injury and sagittal translation more than 3.5 mm. will render the involved segment unstable.

Immobilisation in a halo vest has proved unreliable in maintaining stability according to many authors (2, 11, 14); two patients included in this study were referred to our unit after failure of the halo-vest to maintain alignment.

Posterior plating techniques are more able to control rotational instability (3, 10), but in the presence of disc injury and subsequent disc space collapse this may result in late kyphosis (9). Moreover, in the presence of posterior element fractures one may need to stabilise and fuse other unaffected levels in order to achieve a rigid stable construct. This undue sacrificing of normal motion segments may contribute to a poor range of cervical motion.

Anterior plating at a single level with grafting provides long-term stability without major complications (4, 5, 7). The complication rate for anterior cervical surgery according to the Cervical Spine Research Society is 0.64% (6). Another advantage of anterior plating in this type of injury is the fact that the plate is applied at the site of soft tissue disruption.

This study confirms the findings reported recently by Lifeso and Colucci (9).

CONCLUSION

The fracture and the minimal subluxation that accompany a stage I compression-extension injury of the cervical spine can be easily missed on the initial radiographs. Any patient presenting with radiculopathy should be assessed with oblique radiographs or computed tomography, which may reveal the fracture of the posterior articulation. The presence of such a fracture should arouse the suspicion for the more important failure of the anterior annulus fibrosus, and an MRI scan may be required to detect evidence of disc disruption.

REFERENCES

1. Allen BL Jr, Ferguson RL, Lehman TR, O'Brien RP. A mechanistic classification of closed, indirect fractures and dislocations of the lower cervical spine. *Spine* 1982; 7: 1-27.
2. Anderson PA, Budorick TE, Easton KB, Henley MB, Saliccioli GG. Failure of halo vest to prevent in vivo motion in patients with injured cervical spines. *Spine* 1991; 16 (suppl): S501-505.
3. Anderson PA, Henley MB, Grady MS, Montesano PX, Winn HR. Posterior cervical arthrodesis with AO reconstruction plates and bone graft. *Spine* 1991; 16 (suppl): S64-71.
4. Bohler J, Gaudernak T. Anterior plate stabilization for fracture dislocations of the lower cervical spine. *J Trauma* 1980; 20: 203-205.
5. de Oliveira JC. Anterior plate fixation of traumatic lesions of the lower cervical spine. *Spine* 1987; 12: 324-329.
6. Garvey TA, Eismont FJ, Roberto LJ. Anterior decompression, structural bone grafting, and Caspar plate stabilization for unstable cervical spine fractures and/or dislocations. *Spine* 1992; 17(suppl): S431-435.
7. Graham JJ. Complications of cervical spine surgery. A five-year report on a survey of the membership of the

- Cervical Spine Research Society by the morbidity and the mortality committee. *Spine* 1989 ; 14 : 1046-1050.
8. **Kiwerski J.** Hyperextension-dislocation injuries of the cervical spine. *Injury* 1993 ; 24 : 674-677.
 9. **Lifeso RM, Colucci MA.** Anterior fusion for rotationally unstable cervical spine fractures. *Spine* 2000 ; 25 : 2028-2034.
 10. **Nazarian SM, Louis RP.** Posterior internal fixation with screw plates in traumatic lesions of the cervical spine. *Spine* 1991 ; 16 (suppl) : S64-71.
 11. **Sears W, Fazl M.** Prediction of stability of cervical spine fractures managed in the halo vest and indications for surgical interventions. *J Neurosurg* 1990 ; 72 : 426-32.
 12. **White AA III, Panjabi MM.** *Clinical Biomechanics of the Spine*. JB Lippincott, Philadelphia, 2nd edition, 1990, pp 277-378.
 13. **White AA III, Panjabi MM, Posner I et al.** Spinal stability : evaluation and treatment. *Instr Course Lect* 1981 ; 30 : 457-483.
 14. **Whitehill R, Richman JA, Glaser JA.** Failure of immobilization of the cervical spine by the halo vest. A report of five cases. *J Bone Joint Surg* 1986 ; 68-A : 326-332.
 15. **Woodring JH, Lee C.** Limitations of cervical radiography in the evaluation of acute cervical trauma. *J Trauma* 1993 ; 34 : 32-39.