



## Surgical treatment outcome for open supracondylar humerus fractures in children

Emin ÖZKUL, Mehmet GEM, Hüseyin ARSLAN, Celil ALEMDAR, Abdullah DEMİRTAŞ, Bülent KİŞİN

From Dicle University Medical Faculty, Diyarbakir, Turkey

Although numerous studies have been conducted on supracondylar humerus fractures in children, there is only a limited number of studies regarding the outcome of open fractures. In this study, the early and late outcome of open supracondylar humerus fractures in children were evaluated.

The outcome in 26 children (19 males, 7 females) treated for open supracondylar humerus fractures was evaluated retrospectively. The mean age was 7.3 years (range : 4 to 14) and the mean follow-up period was 4.3 years (range : 2-8). According to the Gustilo-Anderson classification, 18 patients (69%) had type 1 and 8 patients (31%) type 2 open fractures. Nine patients (34%) presented with a nerve injury. Distal pulses could not be detected in four patients (15%). Functional outcomes were evaluated according to the scoring criteria by Flynn *et al.*

Pin tract infection developed in one patient (3%). Artery repair via an anterior approach was performed in one patient. In nine patients with neurological symptoms, nerve functions were restored within three to six months. The mean union time was six weeks (5-8 weeks). According to the scoring criteria by Flynn *et al.*, an excellent outcome was achieved in 23 patients, and a successful outcome in 3 patients.

According to these findings, although vascular and nerve injuries frequently accompany open supracondylar humerus fractures in children, the late radiological and functional outcome was as good as in closed fractures.

**Keywords :** open fracture ; supracondylar humerus ; infection ; vascular injury ; nerve injury.

### INTRODUCTION

Supracondylar humerus fractures are common during childhood ; they constitute 17.4% of all paediatric fractures and 60% of paediatric elbow fractures (6,7). While closed supracondylar humerus fractures are frequently observed in children, open supracondylar humerus fractures are uncommon. Despite the high number of studies on paediatric open fractures in the lower extremity, the number of studies on paediatric open fractures in the upper

- Emin Özkul, MD, Assistant Professor, Orthopaedic surgeon.
- Mehmet Gem, MD, Assistant Professor, Orthopaedic surgeon.
- Hüseyin Arslan, MD, Professor, Orthopaedic surgeon.
- Celil Alemdar, MD, Assistant Professor, Orthopaedic surgeon.
- Abdullah Demirtaş, MD, Assistant Professor, Orthopaedic surgeon.  
*Department of Orthopaedics and Traumatology, Dicle University Medical Faculty, Diyarbakir, Turkey.*
- Bülent Kişin, MD, Orthopaedic surgeon.  
*Department of Orthopaedics and Traumatology, Diyarbakir Training and Educational Hospital, Diyarbakir, Turkey.*

Correspondence : Emin Özkul, Department of Orthopaedics and Traumatology, Dicle University Medical Faculty, 21280, Diyarbakir, Turkey.

E-mail : eminozkul21@hotmail.com

© 2013, Acta Orthopædica Belgica.

extremity is limited (11,12,16,18). Due to the higher rate of major complications including infection, delayed union, compartment syndrome, vein and nerve injury in open fractures compared to closed fractures, there is a need to investigate the frequency and diversity of complications that might be observed prior to and following open supracondylar humerus fracture treatment.

In this study, the early and late phase outcome of patients with open supracondylar humerus fractures who underwent surgical treatment were evaluated.

### MATERIALS AND METHODS

Five hundred and eighty patients were surgically treated for supracondylar humerus fracture at our institutions between 2004 and 2011. Twenty-six (19 male, 7 female) presented an open fracture and were included in the study. Patient records, injury type, pre-operative and post-operative examination findings, surgical notes, accompanying injuries, infection follow-up, duration of hospitalization, mean union time and time to pin removal were recorded for all patients.

Fracture of the right humerus was observed in 14 patients, of the left humerus in 12 patients. The fractures were the result of a simple fall in 14 patients, a fall from a bicycle in five, a fall from a height in four, and due to a motor vehicle accident in three patients. According to the Gartland classification system, all patients had a Type 3 extension injury. According to the Gustilo-Anderson classification, 18 patients (69%) had Type 1 open fractures and eight patients (31%) Type 2A.

The initial clinical examination was performed in the emergency room by the resident specialist and double-checked by the senior surgeon prior to reduction of the fracture. The examination was repeated during the hours following treatment, then performed daily in order to detect possible motor/sensory deficit in the three nerve territories. A total of nine patients (34%) presented with a nerve injury: the anterior interosseous nerve in four patients, the ulnar nerve in two, the radial nerve in two and the median nerve in one.

Distal pulses could not be detected in four patients (15%), in three having a Type 1 and in one having a Type 2 open fracture. In these patients, distal pulses were checked with palpation and doppler ultrasound.

Tetanus prophylaxis and antibiotic treatment were administered in the emergency ward. Radiographs were taken. The patients were taken to surgery depending on their duration of fasting and completion of their diagnos-

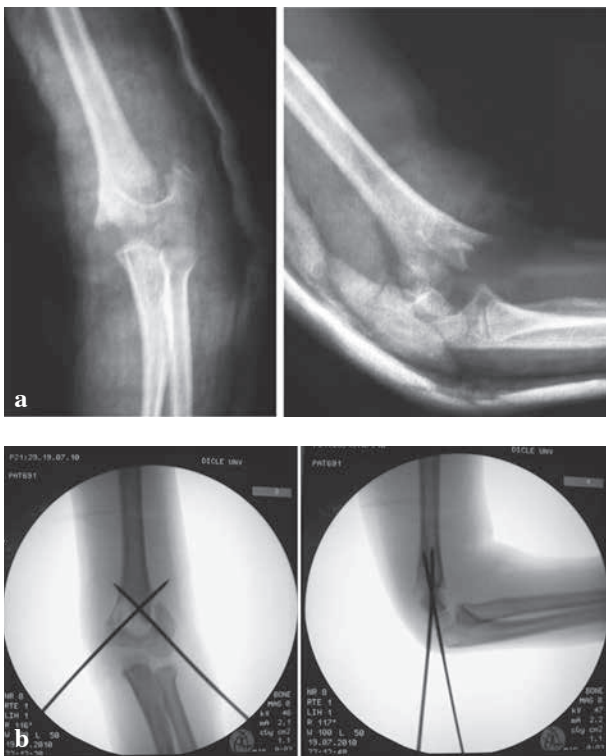
tic work-up. The average time from admission to operative treatment was 5 hours (range: 45 min.-8 hours). Wound cleaning and debridement was performed under general anaesthesia. Reduction was performed under fluoroscopy control, and the fractures were fixed with two crossed K-wires. Open reduction was performed in one case with vascular injury and in five cases in which closed reduction could not be performed. For open reduction, the medial or lateral approach was used depending on the displacement of the distal fragment. Intra-operative wound cultures were not taken. Among the four patients whose distal pulses could initially not be detected, pulses returned in three following reduction. Post-operative circulatory impairment symptoms (coldness, pale discoloration and delayed capillary refill) persisted in one patient. Exploration of the brachial artery was performed through an anterior approach and primary vascular repair was performed in this patient. A long arm cast with 80°-90° flexion of the elbow was applied in all patients following surgery. The wounds were checked on alternating days, and wound dressing was performed. No secondary wound cleaning and debridement was necessary in any of the patients. Post-operative antibiotic therapy was continued for three days. Casts were held until radiological union was achieved, and were discontinued and removed simultaneously with the K-wires.

Two of our patients had an accompanying femur fracture, while two had double forearm fractures on the same side. These fractures were treated in the same session as the supracondylar humerus fractures.

The patients were requested to attend control visits on post-operative day 15, day 30 and at one month intervals for the first three months; later follow-up was performed at six month intervals. Reduction accuracy, elbow carrying angle, humeral capitellar angle and lateral rotational angle (consistency between the axis of the fracture and articular surface) were measured in post-operative radiographs. Range of motion was evaluated and neurological examination was performed. Outcome was evaluated according to the scoring criteria of Flynn *et al* (8).

### RESULTS

The mean age of the patients was 7.3 years (range: 4-14) and the mean follow-up period was 4.3 years (min. 2, max. 8). The mean duration of hospitalization was 5.4 days (3 to 8 days). Pin tract infection was observed in one patient, who was treated with antibiotic therapy and pin tract care. None of the patients developed a deep infection or



**Fig. 1.** — 8-year-old male patient. Type 2, open supracondylar fracture of the left humerus. a) AP and lateral radiographs on admission ; b) fluoroscopy images after reduction.

osteomyelitis. Union was achieved in an average of 6 weeks (5 to 8 weeks) in all patients.

In three of the four patients considered as having a vascular injury, distal pulses became detectable following reduction, and no subsequent problems were encountered during the ensuing follow-up of these patient. The clinical parameters of the patient treated with brachial artery repair were restored, and circulation was observed during post-operative control with Doppler ultrasonography. No post-operative complications occurred, and the patient was discharged on post-operative day 8. Cold intolerance, limb length discrepancy or restrictions of joint movement were not observed during the late-phase examination of the same patient (Fig. 1).

The functions in nine patients with a nerve injury were restored within an average of 3.7 months (3-6 months) without any further intervention being necessary. Iatrogenic nerve injury was not observed in any of the patients.

Table I. — Scoring criteria by Flynn *et al* (8)

	<i>Functional</i> Loss of movement (°)	<i>Cosmetic</i> Carrying angle (°)
Excellent	0-6	0-6
Successful	6-10	6-10
Fair	11-15	11-15
Poor	> 15	> 15

According to the scoring criteria by Flynn *et al* (8) (Table I), the outcome was excellent in 23 patients (restricted mobility of < 5°) ; 3 patients showed a good outcome with 10° flexion deficit in 2 patients and 10° varus deformity in the third.

Overall, the mean elbow carrying angle was 65°, and the mean humeral capitellar angle was 40°. Compartment syndrome or limb length inequalities were not observed in any of the patients.

Statistical analysis (average, standard deviation, frequency) was carried out using SPSS 15.0 for Windows 7.

## DISCUSSION

Supracondylar humerus fractures in children require immediate treatment. These fractures are often observed following low-energy trauma, and therefore are generally Type 1 and Type 2 open fractures. Type 1 open fractures are observed 5 times more frequently than Type 2 open fractures. Unlike in Type 3, accompanying injuries are generally absent in Type 1 and 2 open fractures (11). In 7 of our patients (26%) open fractures were due to high-energy trauma ; femur fractures were also present in 2 patients, and forearm fractures in 2 more patients.

The most feared complication following open fractures is infection. It has been suggested that the incidence of infection after open fractures in children is higher among children older than 12 years of age (1,2). The incidence of infection after upper extremity open fractures is reported to be 0-2.5%, whereas the incidence of infection after Type 1 open fractures in children is reported as being 1.9% (11,12,14). The lower incidence of infection

compared to other fractures may be due to the choice of less invasive surgeries after supracondylar fractures, the use of K-wires alone as implants, and the fact that they generally consist of Type 1 open fractures. The need for a secondary debridement after open forearm fractures is reported as being 11% (10). Deep infection and osteomyelitis were not detected in any of our patients. This may be due to the higher frequency of Type 1 fractures, to the young mean age of the children (7.3 years) or to the short time interval before surgery (on average, under five hours).

Loss of distal pulses is a common complication after supracondylar humerus fractures (5). In case of supracondylar fractures where distal pulses cannot be detected, there is a need for emergency reduction, stabilization and intensive care. In cases with poor circulation after reduction of the extremity, vascular exploration and repair is suggested (15). Distal pulses were not detected in 4 of our patients (15%). The pulses returned in three of the four patients after reduction. Vascular exploration and repair was performed in the fourth patient due to poor circulation in the distal extremity both pre- and post-reduction.

Nerve injuries are observed in 12-20% of cases after supracondylar fractures (5). These injuries, which generally result from pressure or tension between fracture ends, are reported to recover spontaneously in 86-100% of cases (3,5,19). Therefore, explorations for these injuries are performed only in selected cases, namely in case of simultaneous nerve injury and ischaemia, in case of worsening of neurological examination and in complete nerve lesions (19). In our study, nerve injuries were present in nine patients (34%), all of which resolved spontaneously between three to six months.

While the incidence of compartment syndrome secondary to open forearm fractures is 20%, compartment syndrome or Volkmann's ischaemic contracture after supracondylar humerus fractures in children is rarely reported (11,12,16). We did not observe this condition in any of our patients.

In closed supracondylar humerus fractures, the mean duration of hospitalization is generally two days (17). The mean duration of hospitalization was 5.4 days (range: 3-8). The increased duration of

hospitalization in open fractures is due to differences in antibiotic treatment and wound care, and additional injuries which require close monitoring.

Delayed union in forearm fractures in children is defined as union after 10 weeks in patients younger than 9 years of age and after 12 weeks in older patients (9). Delayed union and nonunion reportedly occur in 4.5-4.8% of cases with open forearm fractures, while there were no reports on delayed union or nonunion after open supracondylar fractures (9, 11,13). Union was achieved on average in six weeks (range: 5-8).

The duration of antibiotic therapy after open fractures in children is subject to debate. Many authors have published their own treatment protocol. The duration of intravenous antibiotic therapy ranges between one to five days (10,12). In our study antibiotic therapy was administered to all patients for a mean of 3.8 days (range: 3-8) according to the Gustilo-Anderson classification.

According to the scoring criteria by Flynn *et al*, excellent outcomes were obtained in 23 patients who regained restricted mobility of < 5° and did not have any cosmetic problem, successful outcomes in 3 patients; 2 patients had a 10° loss of elbow motion, and one patient had 10° varus deformity. Compartment syndrome or extremity length inequalities were not observed in any of the patients. In this series, results of open supracondylar humerus fractures are similar to those reported for closed humerus supracondylar fractures in children (17).

Neurovascular injury after open supracondylar humerus fractures in children is frequent. However, most of these cases recover without any need for intervention. Contrary to other fractures, the frequency of wound infection, osteomyelitis, compartment syndrome or Volkman's ischaemic contracture is considerably lower.

In conclusion, open supracondylar humerus fractures differ from closed fractures regarding the need to assume a different treatment approach (e.g. increased frequency of accompanying neurovascular injury, wound debridement and antibiotic treatment) and the duration of hospitalization. However, the functional outcome in our cases was similar to those of closed supracondylar humerus fractures, and was also successful.

## REFERENCES

1. **Arslan H, Necmioğlu S, Kesemenli C, Subaşı M, Ersuz H.** [The treatment outcomes of children with Gustilo-Anderson grade II and grade III open fractures of the long bones.] (in Turkish). *Ulus Travma Derg* 2002 ; 8 : 86-89.
2. **Blasier RD, Barnes CL.** Age as a prognostic factor in open tibial fractures in children. *Clin Orthop Relat Res* 1996 ; 331 : 261-264.
3. **Brown IC, Zinar DM.** Traumatic and iatrogenic neurological complications after supracondylar humerus fractures in children. *J Pediatr Orthop* 1995 ; 15 : 440-443.
4. **Buckley SL, Smith GR, Sponseller PD et al.** Severe (type III) open fractures of the tibia in children. *J Pediatr Orthop* 1996 ; 16 : 627-634.
5. **Campbell CC, Waters PM, Emans JB, Kasser JR, Millis MB.** Neurovascular injury and displacement in type III supracondylar humerus fractures. *J Pediatr Orthop* 1995 ; 15 : 47-52.
6. **Cheng JC, Ng BK, Ying SY, Lam PK.** A 10-year study of the changes in the pattern and treatment of 6,493 fractures. *J Pediatr Orthop* 1999 ; 19 : 344-350.
7. **Farnsworth CL, Silva PD, Mubarak SJ.** Etiology of supracondylar humerus fractures. *J Pediatr Orthop* 1998 ; 18 : 38-42.
8. **Flynn JC, Matthews JG, Benoit RL.** Blind pinning of displaced supracondylar fractures of the humerus in children. Sixteen years' experience with long-term follow-up. *J Bone Joint Surg* 1974 ; 56-A : 263-272.
9. **Greenbaum B, Zions LE, Ebramzadeh E.** Open fractures of the forearm in children. *J Orthop Trauma* 2001 ; 15 : 111-118.
10. **Gustilo RB, Anderson JT.** Prevention of infection in the treatment of one thousand and twenty-five open fractures of long bones. Retrospective and prospective analyses. *J Bone Joint Surg* 1976 ; 58-A : 453-458.
11. **Haasbek JF, Cole WG.** Open fractures of the arm in children. *J Bone Joint Surg* 1995 ; 77-B : 576-581.
12. **Iobst CA, Tidwell MA, King WF.** Nonoperative management of pediatric type 1 open fractures. *J Pediatr Orthop* 2005 ; 25 : 513-517.
13. **Klasson SC, Blasier RD.** Open pediatric fractures of the forearm in children : Ten years experience. *Orthop Trans* 1995 ; 19 : 235.
14. **Lim YJ, Lam KS, Lee EH.** Open Gustilo 1 and 2 midshaft fractures of the radius and ulna in children : is there a role for cast immobilization after wound debridement ? *J Pediatr Orthop* 2007 ; 27 : 540-546.
15. **Louahem DM, Nebunescu A, Canavese F, Dimeglio A.** Neurovascular complications and severe displacement in supracondylar humerus fractures in children : defensive or offensive strategy ? *J Pediatr Orthop* 2006 ; 15 : 51-57.
16. **Luhmann SJ, Schootman M, Schoenecker PL, Dobbs MB, Gordon JE.** Complications and outcomes of open pediatric forearm fractures. *J Pediatr Orthop* 2004 ; 24 : 1-6
17. **Ozturkmen Y, Karamehmetoglu M, Azboy I.** [Closed reduction and percutaneous lateral pinfixation in the treatment of displaced supracondylar fractures of the humerus in children.] (in Turkish). *Acta Orthop Traumatol Turc* 2005 ; 39 : 396-403.
18. **Pirone AM, Graham HK, Krajchich JI.** Management of displaced extension-type supracondylar fractures of the humerus in children. *J Bone Joint Surg* 1988 ; 70-A : 641-650.
19. **Ramachandran M, Birch R, Eastwood DM.** Clinical outcome of nerve injury associated with supracondylar fractures of the humerus in children : the experience of a specialist referral centre. *J Bone Joint Surg* 2006 ; 88-B : 90-94.