



Multistrand titanium cable for the coracoclavicular stabilization of acute acromioclavicular joint dislocation

Tianwen YE, Yueping OUYANG, Aimin CHEN

From Shanghai Changzheng Hospital, Second Military Medical University, Shanghai, China.

The aim of this retrospective study was to evaluate the outcome of the surgical treatment of acute complete acromioclavicular (AC) joint dislocation with multistrand titanium cable for coracoclavicular (CC) stabilization. Forty-two patients with acute complete AC joint dislocation, Rockwood III, IV, V, were treated with CC stabilization using multistrand titanium cable. Thirty-nine patients could be evaluated after a mean follow-up period of 42 months (range, 34-60). The mean VAS score improved from 5.6 ± 1.5 to 0.4 ± 1.2 ($p < 0.05$). The mean Constant score from 64.8 ± 8.9 preoperatively to 95.3 ± 9.3 ($p < 0.05$). Radiographs showed anatomical reduction in 32 out of 39 patients. Cable breakage occurred in 2 patients. CC stabilization with multistrand titanium cables is an effective and safe alternative to other procedures. This procedure provides immediate joint stabilization and allows early mobilization with satisfying functional recovery.

Keywords : acromioclavicular dislocation ; coracoclavicular stabilization ; multistrand titanium cable.

INTRODUCTION

Acromioclavicular (AC) joint dislocation is a common injury caused by a high-energy impact. Loss of elevation and abduction due to shoulder pain is the most frequent complaint. AC joint injuries are classified into 6 types by Rockwood (22). Rockwood type IV, type V and type VI are unstable and mostly considered as an indication for operative treatment. Rockwood type III dislocation, involving the dominant shoulder of overhead

athletes or heavy laborers, is also seen as an indication for surgery (16).

Various surgical treatment options are proposed, such as transarticular AC fixation, extra-articular coracoclavicular (CC) stabilization, and dynamic muscle transfers (10). Several complications have been described for each of these techniques. Today no standard technique has been accepted, but CC stabilization has become more popular. Implants for CC stabilization are very important to maintain the reduction of the AC joint : steel wire, polydioxanonesulphate sutures (PDS), dacron slings, bioabsorbable screws, and TightRope devices have been proposed (6,13,14,19,25,28). However, no implant is perfect, and the search for new materials goes on. Multistrand titanium cables, introduced in 1992 (9), have in recent years largely replaced the monofilament stainless steel wires (26,32), because they are stronger and more fatigue-resistant (7,31).

- Tianwen Ye, MD, Orthopaedic Surgeon.
- Yueping Ouyang, MD, Orthopaedic Surgeon.
- Aimin Chen, MD, Orthopaedic Surgeon.

Department of Orthopaedic Surgery, Shanghai Changzheng Hospital, Second Military Medical University, Shanghai, China.

Correspondence : Aimin CHEN, Department of Orthopaedic Surgery, Shanghai Changzheng Hospital, Second Military Medical University, 415 Fengyang Road, Shanghai, 200003, China.

E-mail : yesonman@hotmail.com

© 2014, Acta Orthopædica Belgica.

MATERIALS AND METHODS

Forty-two consecutive AC joint dislocations Rockwood (22) grade III to VI, admitted between January 2004 and December 2009, were retrospectively evaluated. Inclusion criteria : (1) Rockwood type III to VI AC dislocation ; (2) seen within 6 weeks after trauma ; (3) no previous surgery. Exclusion criteria : craniocerebral injury, fracture of humerus or scapula, brachial plexus injury. The local ethics committee authorized the study. All patients signed an informed consent prior to being included in the study. All operations were performed by the same surgeon with experience in shoulder surgery.

There were 42 patients : 34 males and 8 females. Three patients were lost to follow-up. The 39 remaining patients had an average follow-up period of 42 months (range, 34-60 months). Their average age was 36 years (range, 23-53). The right shoulder was involved in 26 patients and the left in 16. There were 14 type-III cases, 2 type-IV cases and 26 type-V cases according to Rockwood's classification. Etiology : sports injuries (24), fall from a height (12), and road traffic accidents (6). The average lapse of time from injury to operation was 5.3 days (range, 1-13).

Surgical technique

General anaesthesia. The patient was placed in the beach-chair position with the head slightly turned to the unaffected side. A 3-4 cm longitudinal skin incision was made over the clavicle toward the coracoid process. The lateral third of the clavicle, the coracoid process and the CC ligament were exposed without violating the AC joint. The ruptured ligament was examined. Sutures were inserted into the ruptured CC ligament and kept untied. Two longitudinal 3.2 mm tunnels were drilled through the anterior third of the clavicle (1), approximately 25 mm and 45 mm medial to the lateral edge of the clavicle (21). Two multistrand titanium loops (Atlas cable system, Medtronic Sofamor Danek, Memphis, TN, USA) were passed through the tunnels in the clavicle and around the base of the coracoid process (Fig. 1). The clavicle was reduced under fluoroscopic control. Subsequently the loops were tightened with a tensioner device. This tensioner device proved more practical than the wire twister classically used to tighten steel wire. Finally the loops were secured by squeezing two cylindrical crimps. The redundant cables were cut off. The previously placed sutures were tied up. The AC capsule and the ligament were also repaired. The detached deltoid-trapezoid fascia was sutured to protect the reduction.

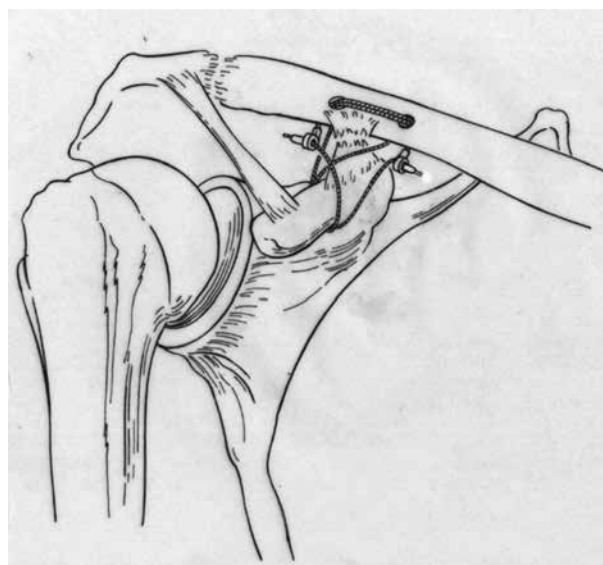


Fig. 1. — Coracoclavicular fixation with two multistrand titanium cables.

Postoperative care

All patients wore a sling for 3 weeks. Progressive passive exercises were started 1 to 2 days after surgery. Active mobilization was allowed after 2 weeks. Exercises against resistance were added 4 weeks post-operatively. Activities of daily living became possible after 6 weeks. Sports and heavy labor were allowed after 12 weeks. The cables were removed after 6 months on an average (range, 3-12), according to the recommendations of the manufacturer.

Evaluation

The patients were evaluated by an external orthopaedic surgeon. The Visual Analog Score (VAS) and the Constant score (5) were used. Radiographs (Fig. 2) were obtained immediately after surgery and at final follow-up. Vertical reduction of the AC joint was evaluated on an AP view. Anterior horizontal displacement of the lateral clavicle was checked on an axillary view. AC arthritis and calcification of the CC ligament were also recorded.

Statistical analysis

VAS and Constant scores were analyzed with the Wilcoxon signed-rank test. Computerized statistical analysis was performed using SPSS software (version

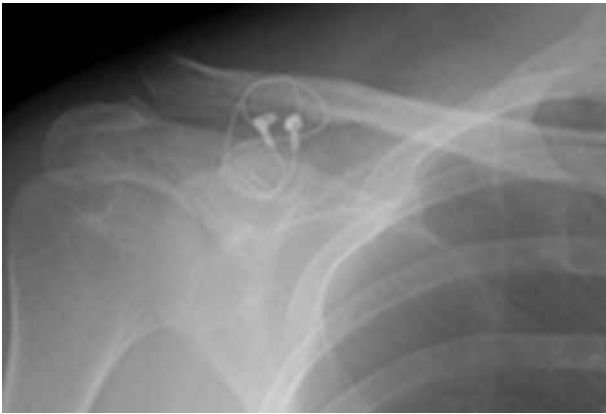

Fig 2. — AP views : coracoclavicular fixation with two multi-strand titanium cables. AC joints symmetrical.

11.0 ; SPSS Inc., Chicago, IL). A $p < 0.05$ was considered statistically significant.

RESULTS

The mean VAS score improved from 5.6 ± 1.5 to 0.4 ± 1.2 at follow-up ($p < 0.05$). The mean Constant score from 64.8 ± 8.9 to 95.3 ± 9.3 ($p < 0.05$). The AP view showed anatomical reduction in 32 patients (82%), slight loss of reduction in 5 patients (12.8%) and partial loss of reduction in 2 patients (5.1%). The axillary view showed no significant anterior displacement of the distal clavicle. Calcification of the CC ligament was noted in 12 patients (30.8%), and arthritis of the AC joint in 9 patients (23.1%). Clavicular osteolysis around the cable was present in 3 patients (7.7%). Cable breakage occurred in 2 patients (5%), respectively after 9 and 11 months ; the cables were immediately removed. Fracture of the clavicle or the coracoid did not occur. Wound infection and vascular or neurological complications were not recorded.

DISCUSSION

The goal of the operation is to restore normal anatomy of the AC joint by reduction and stabilization, and to provide optimal conditions for regaining a normal shoulder function. There are many surgical methods for the treatment of AC joint dislocation. Disadvantages and advantages of these methods remain open for discussion.

Classical intra-articular fixation

The intra-articular fixation method with a Kirschner wire and/or a tension-band has been popular, because it was simple. Unfortunately, complications were numerous : AC arthritis, pin break-away and breakage, migration of the pins to the lungs, heart, spinal cord and even major vessels (2,18).

Clavicular hook plate

The clavicular hook plate can maintain reduction and stability (17,23). It consists of a plate, screwed on the clavicle, and a lateral extra-articular hook which is in contact with the underside of the acromion. However, it includes a serious risk of damage to the subacromial region, such as rotator cuff tear and erosion of the acromion (4), so leading to continued pain, restriction of movement and poor functional outcome.

Coracoclavicular fixation

Coracoclavicular fixation is an indirect stabilization method without the risk of causing additional iatrogenic injury to the AC joint. It has the advantage of early and unrestricted motion (11). Theoretically, placement of the stabilization device in the direction of the CC ligament should be most ideal. In recent years, much progress has been made in this field with respect to implant materials, stabilization technique and limited incision (15,29).

Stabilization with a monocerclage steel wire passed around the coracoid process and the clavicle has a good clinical outcome (13). However, this CC wire loop method is technically complex because the steel wire is rigid and therefore difficult to manipulate. For example, the steel wire is difficult to pass through drill holes, and likely to sustain kinking and notching, resulting in failure. Therefore, monocerclage steel wire is rarely used today for CC stabilization.

The biocompatibility of multistrand titanium cables makes them ideal for surgical implantation. Multistrand titanium cables are soft and flexible, and do not interfere with postoperative magnetic reso-

nance imaging (9). The Atlas cable has seven strands braided together, and each strand is made of seven titanium wires. In other words, a multistrand titanium cable usually consists of 49 wires, and measures only about 1 mm in diameter, which makes it more flexible and easier to manipulate. Multistrand titanium cables do not exhibit appreciable creep, whereas the monofilament wires continue to stretch during 24 hours when subjected to a constant load (31). Moreover, multistrand titanium cables have a wonderful fatigue-resistance and strength (7,31).

Therefore, multistrand titanium cables can maintain the reduction of the AC joint, even when the construct is submitted to postoperative exercises.

The original CC cerclage technique consisted of passing a loop around the entire clavicle and the crook of the coracoid. This method may lead to anterior displacement of the lateral clavicle, with malreduction of the AC joint (11,19). It is recommendable, to avoid this anterior displacement, to pass the loop or loops through tunnels in the anterior third of the clavicle (1,19). This technique will yield a near restoration of AC joint congruity. Cadaveric studies recommend two tunnels, drilled in the anterior third of the clavicle, approximately 25 mm and 45 mm medial to the lateral edge of the clavicle (1,21). The current study confirmed the value of this technique.

A synthetic biomaterial like LARS (20) does not need to be removed postoperatively, but it is relatively expensive as compared with other materials.

Recently, arthroscopic surgery has been proposed to replace the CC ligament (24,30): the TightRope technique replaces the CC ligament with a rope. This method is minimally invasive, but it is skill-dependent. Therefore it is only suitable for experienced arthroscopists (8). In addition, arthroscopic surgery needs special equipment, which is too expensive for developing countries. So this technique is not applied extensively to date.

Complications

Ossification of the CC ligament and arthritis of the AC joint are always a concern in CC joint stabilization (3). The current study demonstrated a high incidence of CC ossification (30.8% of the patients) and AC osteoarthritis (23.1%). The formation of a

bony bridge may be due to a combination of factors, such as a bone morphogenetic protein process and/or the transportation of bone fragments by the drill, which favors calcium deposition in the soft tissues (20). Nevertheless, the authors found good to excellent scores in the cases with calcification of the CC ligament. The CC fixation may modify force transmissions at the AC joint level, leading to osteoarthritis. However, pain complaints were not noted, in agreement with other studies (12,20).

Although the fatigue resistance of multistrand titanium cables is significantly superior to that of stainless steel monofilament wire, repeated activity may still lead to fatigue breakage. It is therefore suggested to remove multistrand titanium cables after 6 months, as a routine. Of course, this increases the financial and psychological burden.

Weaknesses

The small number of patients, the short follow-up period, the retrospective character of this study and the absence of a control group constitute weaknesses.

Acknowledgments

We would like to thank Xianren Wu, MD, Geisinger Medical Center, Danville, Pennsylvania, USA, for his extensive editing. Tianwen Ye and Yueping Ouyang contributed equally to this work.

REFERENCES

1. Baker JE, Nicandri GT, Young DC *et al.* A cadaveric study examining acromioclavicular joint congruity after different methods of coracoclavicular loop repair. *J Shoulder Elbow Surg* 2003 ; 12 : 595-598.
2. Biddau F, Fioriti M, Benelli G. Migration of a broken cerclage wire from the patella into the heart. A case report. *J Bone Joint Surg* 2006 ; 88-A : 2057-2059.
3. Calvo E, López-Franco M, Arribas IM. Clinical and radiologic outcomes of surgical and conservative treatment of type III acromioclavicular joint injury. *J Shoulder Elbow Surg* 2006 ; 15 : 300-305.
4. Chandrasenan J, Badhe S, Cresswell T, Beer J. The clavicular hook plate : consequences in three cases. *Eur J Trauma Emerg Surg* 2007 ; 33 : 557-559.

5. **Constant CR, Murly AH.** A clinical method of functional assessment of the shoulder. *Clin Orthop Relat Res* 1987 ; 214 : 160-164.
6. **Defoort S, Verborgt O.** Functional and radiological outcome after arthroscopic and open acromioclavicular stabilization using a double-button fixation system. *Acta Orthop Belg* 2010 ; 76 : 585-591.
7. **Dickman CA, Papadopoulos SM, Crawford NR, Brantley AG, Gealer RL.** Comparative mechanical properties of spinal cable and wire fixation system. *Spine* 1997 ; 22 : 596-604.
8. **Dimakopoulos P, Panagopoulos A.** Functional coracoclavicular stabilization for acute acromioclavicular joint disruption. *Orthopedics* 2007 ; 30 : 103-108.
9. **Doran SE, Papadopoulos SM, Miller LD.** Internal fixation of the spine using a braided titanium cable : clinical results and postoperative magnetic resonance imaging. *Neurosurgery* 1996 ; 38 : 493-496.
10. **Epstein D, Day M, Rokito A.** Current concepts in the surgical management of acromioclavicular joint injuries. *Bull NYU Hosp Jt Dis* 2012 ; 70 : 11-24.
11. **Fialka C, Stampfl P, Oberleitner G, Vécsei V.** Traumatic acromioclavicular joint separation : Current concepts. *Eur Surg* 2004 ; 36 : 20-24.
12. **Greiner S, Braunsdorf J, Perka C, Herrmann S, Scheffler S.** Mid to long-term result of open acromioclavicular-joint reconstruction using polydioxansulfate cerclage augmentation. *Arch Orthop Trauma Surg* 2009 ; 129 : 735-740.
13. **Heitemeyer U, Hierholzer G, Schneppendahl G, Haines J.** The operative treatment of fresh ruptures of the acromioclavicular joint (Tossy III). *Arch Orthop Trauma Surg* 1986 ; 104 : 371-373.
14. **Hessmann M, Gotzen L, Gehling H.** Acromioclavicular reconstruction augmented with polydioxanonesulphate bands. Surgical technique and results. *Am J Sports Med* 1995 ; 23 : 552-556.
15. **Jerosch J, Filler T, Peuker E, Greig M, Siewering U.** Which stabilization technique corrects anatomy best in patients with AC separation ? An experimental study. *Knee Surg Sports Traumatol Arthrosc* 1999 ; 7 : 365-372.
16. **Johansen JA, Grutter PW, McFarland EG, Petersen SA.** Acromioclavicular joint injuries : indications for treatment and treatment options. *J Shoulder Elbow Surg* 2011 ; 20 (2 Suppl) : S70-82.
17. **Kienast B, Thietje R, Queitsch C et al.** Mid-term results after operative treatment of rockwood grade III-V acromioclavicular joint dislocations with an AC-hook-plate. *Eur J Med Res* 2011 ; 16 : 52-56.
18. **Loncán LI, Sempere DF, Ajuria JE.** Brown-Sequard syndrome caused by a Kirschner wire as a complication of clavicular osteosynthesis. *Spinal Cord* 1998 ; 36 : 797-799.
19. **Morrison DS, Lemos MJ.** Acromioclavicular separation. Reconstruction using synthetic loop augmentation. *Am J Sports Med* 1995 ; 23 : 105-110.
20. **Motta P, Bruno L, Maderni A, Tosco P, Mariotti U.** Acromioclavicular motion after surgical reconstruction. *Knee Surg Sports Traumatol Arthrosc* 2012 ; 20 : 1012-1018.
21. **Rios CG, Arciero RA, Mazzocca AD.** Anatomy of the clavicle and coracoid process for reconstruction of the coracoclavicular ligaments. *Am J Sports Med* 2007 ; 35 : 811-817.
22. **Rockwood CA Jr, Williams GR, Young DC.** Disorders of the acromioclavicular joint. In : Rockwood CA, Matsen FA (eds). *The Shoulder*. 2nd edition. Vol 1. WB Saunders, Philadelphia, 1998, pp. 483-553.
23. **Salem KH, Schmelz A.** Treatment of Tossy III acromioclavicular joint injuries using hook plates and ligament suture. *J Orthop Trauma* 2009 ; 23 : 565-569.
24. **Sallakh El SA.** Evaluation of arthroscopic stabilization of acute acromioclavicular joint dislocation using the TightRope system. *Orthopedics* 2012 ; 35 : e18-22.
25. **Stam L, Dawson I.** Complete acromioclavicular dislocations : treatment with a Dacron ligament. *Injury* 1991 ; 22 : 173-176.
26. **Sudo H, Abumi K, Ito M, Kotani Y, Minami A.** Spinal cord compression by multistrand cables after solid posterior atlantoaxial fusion. Report of three cases. *J Neurosurg* 2002 ; 97 (3 Suppl) : 359-361.
27. **Taft TN, Wilson FC, Oglesby JW.** Dislocation of the acromioclavicular joint. An end-result study. *J Bone Joint Surg* 1987 ; 69-A : 1045-1051.
28. **Talbert TW, Green JR 3rd, Mukherjee DP, Ogden AL, Mayeux RH.** Bioabsorbable screw fixation in coracoclavicular ligament reconstruction. *J Long Term Eff Med Implants* 2003 ; 13 : 319-323.
29. **Tauber M.** Management of acute acromioclavicular joint dislocations : current concepts. *Arch Orthop Trauma Surg* 2013 ; 133 : 985-995.
30. **Thiel E, Mutnal A, Gilot GJ.** Surgical outcome following arthroscopic fixation of acromioclavicular joint disruption with the tightrope device. *Orthopedics* 2011 ; 34 : e267-274.
31. **Weis JC, Cunningham BW, Kanayama M, Parker L, McAfee PC.** In vitro biomechanical comparison of multi-strand cables with conventional cervical stabilization. *Spine* 1996 ; 21 : 2108-2114.
32. **Xiao ZM, Zhan XL, Gong de F et al.** C2 pedicle screw and plate combined with C1 titanium cable fixation for the treatment of atlantoaxial instability not suitable for placement of C1 screw. *J Spinal Disord Tech* 2008 ; 21 : 514-517.