



Late Onset Tibia Vara. Acute Correction Strategy : Proper Case Selection and a Simple External Fixation Technique

Ashraf A. KHANFOUR, Mahmoud EL-ROSASY

From the Departments of Orthopaedic Surgery, Damanhur National Medical Institute, Damanhur

Following proximal tibial osteotomy for cases of late onset tibia vara, both acute and gradual correction strategies were described, where each has its pros and cons.

The aim of this study was to verify the proper selection criteria of cases with late onset tibia vara amenable to successful acute correction strategy using a homogenous patient group with clear inclusion criteria ; all the cases were fixed by a low profile semicircular fixator module.

Thirty legs in 20 patients (11 boys, nine girls) with late onset tibia vara, treated in our department between January 2005 and February 2008, that complied well with the assigned inclusion criteria constituted the material of this prospective study. Their mean age was 10.4 years (range, 6-14 years). They were all managed using the same modality that was acute correction based on the osteotomy rule II concept and fixed by a low profile miniature Ilizarov fixator module.

After a mean follow up period of 5.9 years (range, 5-7) only (13%) of the cases showed recurrence.

Proper selection of cases with late onset tibia vara undergoing acute correction strategy is of utmost importance for the sake of a successful outcome. On the other hand, the low profile simplified fixator module used is a handy and a compliant osteotomy fixation tool.

Keywords : late onset tibia vara, acute correction, external fixation, ilizarov.

INTRODUCTION

Late-onset tibia vara or Blount's disease constitutes the most common cause of pathologic genu varum in late childhood and adolescence. Most authors consider it as a juvenile form if the onset of the disease is between 4-10 years and as an adolescent form if its onset is after 10 years of age (2,3,17,24,46). Several treatment modalities were described for these cases as proximal tibial osteotomy, growth modulation, and medial plateau elevation that are either carried out as an isolated procedure or in combination (2,4,7,18,31,50). However, proximal tibial osteotomy is still the standard surgical management for late onset cases where the researchers observed that the proximal tibial physis typically grew symmetrically following this osteotomy (1,3,7,16,18). After osteotomy, either acute (6,11,13,14,19,26,29,34,45,49,52,56) or gradual correction strategies

■ Ashraf A Khanfour FRCS Ireland ; M. D Orth., Assistant Professor of Orthopaedics and traumatology.

Department of Orthopaedic Surgery, Damanhur National Medical Institute, Damanhur Egypt.

■ Mahmoud El-Rosasy M. D Orth., Professor of Orthopaedics and traumatology.

Department of Orthopaedic Surgery, Tanta University, Tanta, Egypt.

Correspondence : Ashraf A. Khanfour, 25 Garden city Somoha. Alexandria ; Egypt. Postal Code : 21615.

E-Mail : Dr_ashrafkhanfour@hotmail.com

© 2014, Acta Orthopædica Belgica.

were described. While the gradual (1,2,7,8,10,15,18, 44,48,51,54) correction strategy using distraction osteogenesis has its crucial indication in certain situations like addressing severe deformity or a coincident significant anatomical limb length discrepancy, it requires a high degree of patient compliance and still has its recorded complications (16,17,37,44, 51,54). Conversely, acute correction strategy has its merits as being more compliant to the patient and requires less regular follow up visits, but it needs proper case selection to get a successful outcome. These selection criteria were not clearly reported in the literature published on this topic.

The aim of this study was to verify the proper selection criteria of cases with late onset tibia vara amenable to successful acute correction strategy using a standardized external low profile Ilizarov fixator module.

PATIENTS AND METHODS

Thirty legs in 20 patients (11 boys, nine girls) with late onset tibia vara who presented to the orthopedic department between January 2005 and February 2008 were included in this prospective study. The inclusion criteria were: (1) maximal angular deformity of -40° , (2) in unilateral cases, the calculated expected post-correction limb length discrepancy is not more than 1.5 cm and (3) belonging to a low grade group Langenskiöld classification (Stage I-IV). The exclusion criteria were: (1) high grade group Langenskiöld classification (Stage V-VI) necessitating more than a single procedure, (2) presence of overgrowth of the fibula in relation to the tibia that may even protrude up to the knee joint line, (3) the calculated expected post-correction limb length discrepancy is more than 1.5 cm, and (4) deformity more than -40° . The mean age of the patients at the time of operation was 10.4 years (range, 6-14 years). Three cases were right sided, six were left sided, and 11 were bilateral. Fourteen cases were in stage II, nine in stage III, and seven in stage IV according to Langenskiöld's classification (23,25). The mean preoperative anatomical frontal tibiofemoral angle was -24.66° (range, -15 - 35° , SD 5.07°). The mean tibial internal torsion was 15.33° (range, 0° - 40° , SD 10.41°) (Table 1). All the cases were treated using the same strategy which was acute correction based on the osteotomy rule II concept and fixation using a low profile miniature Ilizarov fixator module. This osteotomy rule would be attained by designing the

axis of correction of angulation (ACA) to pass through the level of the center of rotation of angulation (CORA) which is located here juxta-articularly; while the osteotomy was done at another level, just distal to the tibial tuberosity. So lateral translation will accompany angulation correction and this will consequently align the mechanical axis of the limb.

One child (case no. 19) had an associated distal femoral valgus (mLDFA = 75°). Another child with bilateral disease (case no. 13), presented with -45° angulation on the left side that necessitated gradual correction and so this limb was excluded from this study.

Preoperative planning

(1) Determination of the knee joint malalignment and malorientation radiologically using the malalignment test. The magnitude of the varus deformity was measured using the anatomical tibiofemoral angle (40,41). (2) Defining the Langenskiöld stage (23,25). (3) Assessment of the tibial internal torsion clinically by the thigh-foot angle (53). (4) Assessment of the limb length inequality by the block method (47). (5) In unilateral cases, calculation of the expected post-correction limb length discrepancy (LLD): in these cases as the CORA lies juxta-articular or even inside the knee joint line itself, the expected limb length after correction will be the result of the summation of the ipsilateral anatomical lengths of the femur and the tibia. So, the expected LLD was evaluated by comparing the anatomical limb length of the affected and the sound limb (22).

Operative technique

In all cases, the Ilizarov external fixator module was preoperatively constructed. The frame consisted of two symmetrical femoral arches connected together by two or three connecting rods. Rancho cubes and Schanz clamps were then mounted to it. Two symmetrical straight plates substituted the arches in cases with short legs (Fig. 1). Bilateral deformities were corrected on two successive sessions. The procedure was performed under general anesthesia without tourniquet application. Fibulotomy was done at the level of the mid leg. Under the C-arm control, while the patella was facing directly forward and the limb was halted in this position by the assistant, a 6 mm bicortically fixed Schanz screw was inserted from the medial aspect, parallel to the ground, just distal to the proximal tibial epiphyseal plate and parallel to the proximal knee joint orientation line (Fig. 2). A parallel second distal Schanz screw was then inserted

Table 1. — Patient demography.

No.	Age	Sex	Side		Lang. Stage	Deformity Components				Degree of Angular Corr. (Degrees)	Time spent in the fixator (M)	Follow up (Y) Angular	Recurrence of the deformity	Remarks
						Varus (Anatomic TF Angle)	Intorsion (Degrees)	procurvatum	Associated distal femoral deformity					
1	13	m	Bil	R	III	-35	40	-	-	45	4	5	-	
				L	II	-30	40	-	-	40	3.5	5.5	-	
2	11	f	Bil	R	III	-20	30	-	-	40	3	6	-5	
				L	III	-25	25	-	-	35	3	6.5	-	
3	6	f	Bil	R	III	-20	20	-	-	30	3	6	-	
				L	II	-15	20	-	-	25	3	6	-	
4	11	f	R		II	-20	-	-	-	30	4	6	-	
5	12	f	R		II	-25	-	-	-	35	4	6.5	-	
6	7	f	Bil	R	II	-20	20	-	-	30	3	5	-	
				L	III	-20	15	-	-	30	3	5.5	-	
7	11	m	Bil	R	II	-30	15	-	-	40	3	5	-	Transient common peroneal nerve palsy
				L	IV	-35	25	-	-	45	4	5.5	-10	
8	7	m	Bil	R	III	-25	15	-	-	35	3	5	-5	
				L	II	-25	15	-	-	35	4	5.5	-	
9	8	f	L		IV	-25	20	-	-	35	3	6	-	
10	13	m	L		II	-25	25	-	-	35	4	5	-	
11	11	m	L		II	-20	15	-	-	30	4	5	-	
12	11	m	Bil	R	II	-20	10	-	-	30	4	6	-	
				L	II	-25	10	-	-	35	4	6.5	-	
13	12	m	Bil	R	III	-30	10	-	-	40	3	6.5	-	
				L	IV	-45	15	25	-	55	5	7	-	Excluded (Corrected by Gradual Strategy)
14	13	m	L		III	-25	-	-	-	35	3	7	-	
15	14	m	Bil	R	IV	-30	15	-	-	40	4	6	-	
				L	IV	-35	15	-	-	45	4	7	-	
16	10	f	L		IV	-25	10	-	-	35	3.5	6	-	
17	14	m	Bil	R	III	-20	-	-	-	30	4	6	-5	
				L	II	-25	-	-	-	35	4	5.5	-	
18	6	m	Bil	R	II	-20	10	-	-	30	3	6	-	
				L	II	-20	15	-	-	30	3	6.5	-	
19	9	f	R		IV	-25	10	-	mLDFA=75	35	4	7	-	Transient common peroneal nerve palsy
20	9	f	L		IV	-25	15	-	-	35	3	7	-	




Fig. 1. — The construct modules used ; A : built by 2 symmetrical femoral arches. B : built by 2 symmetrical plates

using a Rancho cube as a guide. A percutaneous straight cut corticotomy was then done through a 2-3 cm anterior incision just distal to both the tibial tuberosity and the distal pin using multiple drill holes with a 4.5 mm drill pit. Prophylactic percutaneous anterior compartment fasciotomy was performed using a long blunt-nose scissor through the same corticotomy incision. Acute correction was performed in this sequence : *derotation, translation, angulation*, and lastly *extension* if procurvatum was present. Derotation was done until the second toe of the plantigrade foot aligned with the patella. As a rule of thumb, for each degree of angular correction, 1% lateral translation of the distal bone end on the proximal one at the osteotomy site was done and monitored under the C-arm (Fig. 2). After obtaining the required angular correction, the resultant increase in the surrounding soft tissue tension would aid the bone ends to jam and lock at the osteotomy site. Now, this corrected position was firmly halted by the assistant. The pre-assembled construct was then fixed to the previously inserted proximal two Schanz screws in the metaphyseal area. Consequently, the distal segment was fixed to the construct by similar two Schanz Screws. The mechanical axis alignment was then checked under the C-arm using the electrocautery cable stretched between the centers of the hip and the

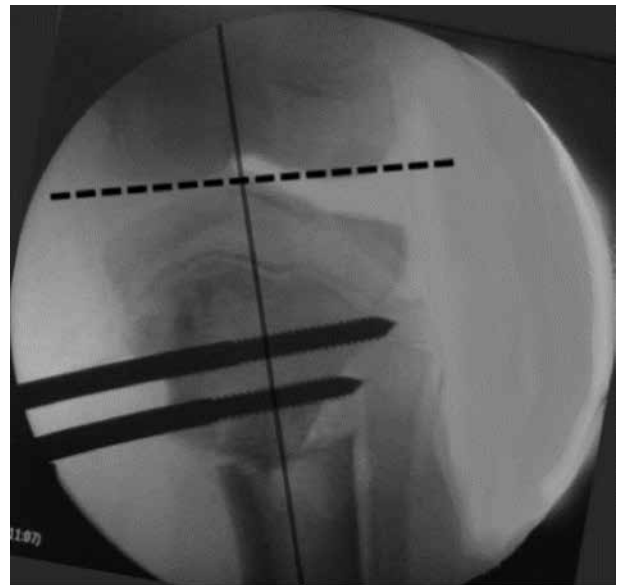

Fig. 2. — Intra-operative C-arm view after achieving the required correction demonstrating (1) The metaphyseal Schanz screws are parallel to the proximal knee joint orientation line and distal to the proximal tibial epiphyseal plate. (2) The mechanical axis highlighted by the shadow of the electrocautery cable passes through the centre of the knee. (3) lateral translation of the distal bone end on the proximal one.




Fig. 3. — Intraoperative completion of the correction and full application of the fixator

ankle joints, the shadow of this cable crossing the center of the knee joint. Fine tuning of correction was feasible at this stage (Fig. 2). 5° Valgus overcorrection to an anatomical tibio-femoral angle of 10° was intentionally attained in all cases (normally 5° valgus). At the end, the fixation was augmented by the addition of another one or two pins to each segment in a different divergent plane (Fig. 3). The case which presented with the associated distal femoral valgus (case no. 19), was corrected on the femoral side firstly using the same technique and a similar construct; then the tibial deformity was synchronously corrected (Fig. 4). In no cases we performed peroneal nerve release.

Patients were encouraged to do active knee exercises once the postoperative pain was relieved. Weight bearing as tolerated was allowed after 3-7 days using crutches. Follow up after 2 weeks for removal of stitches and dressing. Then follow up radiography every 1 ½ months. Complete union was verified both radiologically and clinically when the patient could bear weight comfortably after disconnecting the two arches. Removal of the fixator was done under anesthesia for good toilet and cleaning of the pin tracts.

RESULT

The mean time spent in the fixator was 3.5 months (range, 3-4 months, SD = .65). The mean degree of angular correction was 33.33° (range, 25°-45°, SD 4.0°). All deformities were corrected as planned. There was no postoperative loss of correction during consolidation. All cases attended the final follow-up (mean, 5.9 years; range, 5-7) (Fig. 5). All cases suffered one or more attacks of superficial pin tract infection especially in the metaphyseal pins that resolved successfully on local toilet and oral antibiotic therapy. Transient common peroneal nerve palsy occurred in two cases that was recovered spontaneously on the 8th and 12th week respectively. This may be due to a stretch on the nerve especially in case no. 19 where both the distal femoral and proximal tibial corrections were carried out synchronously. Recurrence was defined when the anatomical tibiofemoral angle became less than 0° in the varus direction (negative values)

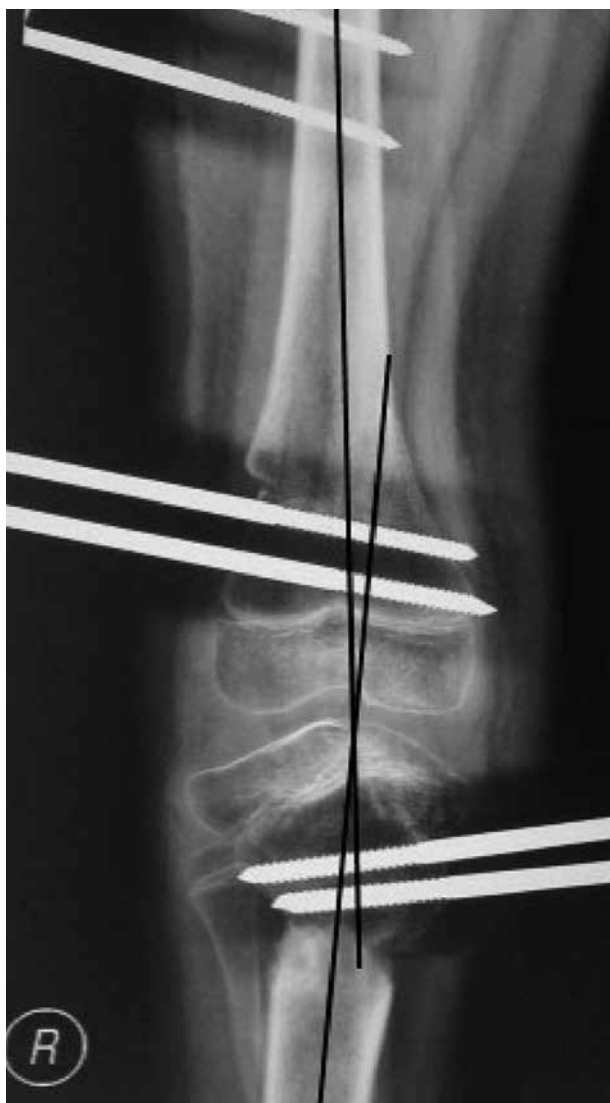

Fig. 4. — X-ray near full consolidation of a juvenile female child 9 years old in which synchronous distal femoral and proximal tibial correction were carried out. It shows 10° valgus (5° overcorrection).

and it occurred in four out of 30 legs (13%). Three of them were classified as Langenskiöld stage III and showed minimal recurrence (-5°). The fourth case was Langenskiöld stage IV and showed significant recurrence (-10°). These cases were counselled for regular close follow up for a possibility of the need of another interference. No significant LLD (> 1.5 cm) was recorded at the end of the follow up.

DISCUSSION

As Blount's disease includes different types and in addition each type has a broad array of deformity components, determining an explicit selection criteria for a given modality of treatment became a necessity for the sake of a successful outcome. Either acute or gradual correction after proximal tibial osteotomy are both a well-established treatment strategy for the late onset tibia vara, with each its pros and cons (2,5,12,13,17,36,52,54,56). While the gradual deformity correction strategy is considered to be more accurate by some authors (16,32,42), others stated that evidence for this was lacking, although a higher incidence of peroneal nerve palsy was recorded after acute correction which was fortunately transient. In a great systematic review by Gilbody *J et al* in 2009, they failed to find proper case selection criteria for each correction strategy, as most of the articles included in their work were retrospective, of small sample size, often including quite different etiologies of genu varus and also including patients with early and late-onset Blount's disease together, and lastly there was no standardization for deformity description or defining recurrence (17).

In this present study the material was composed of a homogeneous patient group with clear inclusion and exclusion criteria whom were subjected to a standardized modality of correction and fixation. Cases with significant limb length discrepancy (LLD), high Langenskiöld grade, or overgrowth of the proximal fibula were excluded from this study. For cases with expected post-correction significant residual LLD (> 1.5 cm), many authors described the use of a combined strategy of both acute correction of the angular component of the deformity, followed by gradual continuing lengthening but they found that these cases significantly had a poorer bone healing. They assumed this to both, the great insult that occurs to the periosteum together with the decrease in the contact cross sectional area between the divided bone ends that results after carrying out a high degrees of acute correction (12,16, 21,30,35,36,56). And accordingly, these cases are better corrected gradually from the start.

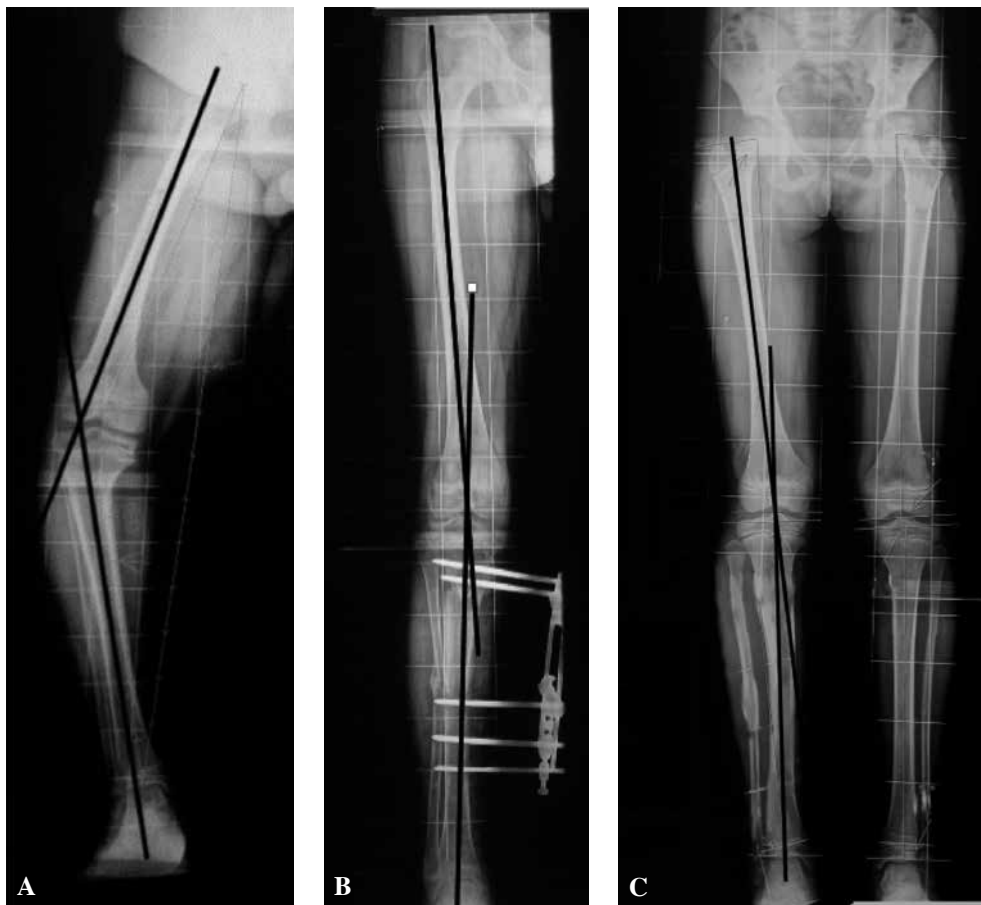

Fig. 5. — A : Preoperative full leg length scanogram of a nine years old female with a right sided juvenile onset Blount's disease showing varus (anatomic Tibiofemoral angle (aTF) was -35°). B : Postoperative scanogram showing 5° overcorrection (aTF angle became 10°). C : End of follow up scanogram showing no recurrence.

On the other hand, in cases with a high grade Langenskiöld stage (stage V, VI), a consensus exists that a single procedure is generally not enough and either adjunctive growth modulation procedures or medial tibial plateau elevation are required (4,20,31,50,57). Lastly, cases with overgrowth of the proximal fibula in relation to the tibia, unipolar lengthening of the tibia in relation to the fibula is needed to level the proximal tibio-fibular joint (5). So, in the three above conditions either gradual correction or multiple procedures are required.

Considering limb length inequality in general, there are two types of shortening, geometrical or true. A *geometrical* (mechanical) shortening is pres-

ent in case of angular deformity of the limb where the mechanical limb length (a straight line from the most proximal subarticular bone of the femoral head to the subarticular bone at the center of the ankle mortise on the long both lower limb scanogram) is shorter than that of the sound limb due to the loss of co-linearity of its hip, knee, and ankle. A *true* (anatomical) shortening is present when the summation of the individual anatomical bony segments forming the limb – tibia and femur – are shorter than that of the sound limb (2,22,28,38). Both Kessler AC *et al* and Magnussen RA *et al* concluded that the resulted actual limb length after angular deformity correction was within a 0.7 cm

error less than the calculated value in the pre-operative planning and they attributed this to the bone void occurring at the osteotomy site (22, 28).

In the pediatric age group, the ideal form of fixation after corticotomy remains controversial, (13, 40, 41-49). Although internal fixation of the proximal tibial osteotomy is more compliant to the patient, they hardly align the mechanical axis (49). This is because the CORA in these patients lies juxta-articularly while the osteotomy cut is forcefully located away from it to avoid physal injury in these patients. This will lead to the occurrence of a secondary translational iatrogenic malalignment of the mechanical axis of the limb if varus angulation correction was carried out without lateral translation. This translation is difficult to be achieved or maintained using internal fixation. Consequently, the external fixator continues to be a more attractive fixation tool as it easily fixes the bone after both angulation and translation (2, 27, 39-41, 48). Other advantages of external fixators are : secure fixation to the small proximal tibial segment, the ability for dynamic compression, the possibility for minimal postoperative adjustments, and enabling the patients for early postoperative weight bearing (2, 6, 13, 16, 52, 56).

Regarding the available types of the external fixators used, it was found that while the unilateral fixators are weak and less modular, the circular fixators on the contrary are ideal for both correction and limb length equalization. But the latter are unfortunately bulky and noncompliant for the patients, require complex planning, laborious pre-construction of the frame and a protracted learning curve of the surgeons (2, 5, 8, 15, 37, 42, 54). So, it is better reserved for cases with severe deformities necessitating gradual correction or lengthening. In recent years, new generations of multi-axial correcting unilateral fixators with improved versatility emerged but unfortunately they are not handy (9, 33, 42, 43, 55). In this study, we used a low profile miniature module built up from Ilizarov fixator accessories which is easily accessible.

Although there is a consensus on the necessity of attaining overcorrection, there was no agreement on its amount in the literature (3, 46). In this study, 5° overcorrection was assigned to offload the sick

upper medial tibial physis encouraging its recovery.

Generally, the recorded rate of recurrence of varus deformity in Blount's disease has been found to be in the range of 30% to 100% (6). In this study, at the end of the follow up, a good result was obtained with only 13% of cases showing recurrence. This could be attributed to the proper case selection for the given strategy of treatment, comprehensively addressing all the components of the deformity, and achieving acceptable overcorrection offloading the sick medial epiphysis encouraging its articular/epiphyseal recovery.

A shortcoming of this study is the relatively small number of cases and the lack of a randomized control group for comparative study but this was due to both the uncommon nature of these category of patients as well as the restriction for the inclusion criteria used.

We believe that proper selection of cases with late onset tibia vara undergoing acute correction is of utmost importance for the sake of a successful outcome. On the other hand, the low profile simplified fixator module used is a handy and a compliant osteotomy fixation tool.

REFERENCES

1. **Alekberov C, Shevtsov VI, Karatosun V, Gunal I, Alici E.** Treatment of tibia vara by the Ilizarov method. *Clin Orthop Relat Res* 2003 (409) : 199-208.
2. **Amer AR, Khanfour AA.** Evaluation of treatment of late-onset tibia vara using gradual angulation translation high tibial osteotomy. *Acta Orthop Belg* 2010 ; 76 (3) : 360-366.
3. **Birch JG.** Blount disease. *J Am Acad Orthop Surg* 2013 ; 21 (7) : 408-418.
4. **Bushnell BD, May R, Campion ER, Schmale GA, Henderson RC.** Hemiepiphysodesis for late-onset tibia vara. *J Pediatr Orthop* 2009 ; 29 (3) : 285-289.
5. **Catagni MA, Meyers LL, Dellacqua D, Guerreschi F.** The role of external fixation in antivarus tibial osteotomy. *Operative Techniques in Sports Medicine* 2000 ; 8 (1) : 39-43.
6. **Chotigavanichaya C, Salinas G, Green T, Moseley CF, Otsuka NY.** Recurrence of varus deformity after proximal tibial osteotomy in Blount disease : long-term follow-up. *J Pediatr Orthop* 2002 ; 22 (5) : 638-641.
7. **Clarke SE, McCarthy JJ, Davidson RS.** Treatment of Blount disease : a comparison between the multi-axial correction system and other external fixators. *J Pediatr Orthop* 2009 ; 29 (2) : 103-109.

8. **Coogan PG, Fox JA, Fitch RD.** Treatment of adolescent Blount disease with the circular external fixation device and distraction osteogenesis. *J Pediatr Orthop.* 1996 ; 16 (4) : 450-454.
9. **Davidson RS.** The MAC (Multi-Axial Correcting) Monolateral External Fixation System (Biomet/EBI) Technique : An Easier Way to Correct Deformity. *Oper Tech in Orthop* 2011 ; 21 : 113-124.
10. **de Pablos J, Azcarate J, Barrios C.** Progressive opening-wedge osteotomy for angular long-bone deformities in adolescents. *J Bone Joint Surg Br.* 1995 ; 77 (3) : 387-391.
11. **Dietz FR, Weinstein SL.** Spike osteotomy for angular deformities of the long bones in children. *J Bone Joint Surg Am* 1988 ; 70 (6) : 848-852.
12. **Donnan LT, Saleh M, Rigby AS.** Acute correction of lower limb deformity and simultaneous lengthening with a monolateral fixator. *J Bone Joint Surg Br* 2003 ; 85 (2) : 254-260.
13. **El-Rosasy M, Ayoub M.** Acute correction of proximal tibial deformities in adolescents using Ilizarov external fixator : focal-dome versus straight-cut osteotomy. *J Pediatr Orthop B* 2007 ; 16 (2) : 113-119.
14. **Elzohairy MM.** Modified Oblique Proximal Tibial Osteotomy for Deformity Correction of Tibia Vara (Blount Disease). *Orthopedic & Muscular System* 2012 ; 1 (4) : 1-4.
15. **Feldman DS, Madan SS, Koval KJ, van Bosse HJ, Bazzi J, Lehman WB.** Correction of tibia vara with six-axis deformity analysis and the Taylor Spatial Frame. *J Pediatr Orthop* 2003 ; 23 (3) : 387-391.
16. **Feldman DS, Madan SS, Ruchelsman DE, Sala DA, Lehman WB.** Accuracy of correction of tibia vara : acute versus gradual correction. *J Pediatr Orthop* 2006 ; 26 (6) : 794-798.
17. **Gilbody J, Thomas G, Ho K.** Acute versus gradual correction of idiopathic tibia vara in children : a systematic review. *J Pediatr Orthop* 2009 ; 29 (2) : 110-114.
18. **Gordon JE, Heidenreich FP, Carpenter CJ, Kelly-Hahn J, Schoenecker PL.** Comprehensive treatment of late-onset tibia vara. *J Bone Joint Surg Am* 2005 ; 87 (7) : 1561-1570.
19. **Hayek S, Segev E, Ezra E, Lokiec F, Wientroub S.** Serrated W/M osteotomy. Results using a new technique for the correction of infantile tibia vara. *J Bone Joint Surg Br* 2000 ; 82 (7) : 1026-1029.
20. **Hefny H, Shalaby H.** A safer technique for the double elevation osteotomy in severe infantile tibia vara. *Strategies Trauma Limb Reconstr* 2010 ; 5 (2) : 79-85.
21. **Kamegaya M, Shinohara Y, Shinada Y.** Limb lengthening and correction of angulation deformity : immediate correction by using a unilateral fixator. *J Pediatr Orthop* 1996 ; 16 (4) : 477-479.
22. **Kessler AC, Pugh LI, Stasikelis PJ.** Length changes in tibial osteotomy with angular correction. *J Pediatr Orthop B* 2005 ; 14 (5) : 337-339.
23. **Khanfour AA.** Does Langenskiold staging have a good prognostic value in late onset tibia vara ? *J Orthop Surg Res* 2012 ; 7 : 23.
24. **Kling TF, Jr.** Angular deformities of the lower limbs in children. *Orthop Clin North Am* 1987 ; 18 (4) : 513-527.
25. **Langenskiold A, Riska EB.** Tibia Vara (Osteochondrosis Deformans Tibiae) : A Survey of Seventy-One Cases. *J Bone Joint Surg Am* 1964 ; 46 : 1405-1420.
26. **Laurencin CT, Ferriter PJ, Millis MB.** Oblique proximal tibial osteotomy for the correction of tibia vara in the young. *Clin Orthop Relat Res* 1996 (327) : 218-224.
27. **Loder RT, Schaffer JJ, Bardenstein MB.** Late-onset tibia vara. *J Pediatr Orthop* 1991 ; 11 (2) : 162-167.
28. **Magnussen RA, Lustig S, Demey G, Neyret P, Servien E.** The effect of medial opening and lateral closing high tibial osteotomy on leg length. *Am J Sports Med* 2011 ; 39 (9) : 1900-1905.
29. **Martin SD, Moran MC, Martin TL, Burke SW.** Proximal tibial osteotomy with compression plate fixation for tibia vara. *J Pediatr Orthop* 1994 ; 14 (5) : 619-622.
30. **Matsubara H, Tsuchiya H, Sakurakichi K, Watanabe K, Tomita K.** Deformity correction and lengthening of lower legs with an external fixator. *Int Orthop* 2006 ; 30 (6) : 550-554.
31. **McCarthy JJ, MacIntyre NR, 3rd, Hooks B, Davidson RS.** Double osteotomy for the treatment of severe Blount disease. *J Pediatr Orthop* 2009 ; 29 (2) : 115-119.
32. **McCarthy JJ, Mark AK, Davidson RS.** Treatment of angular deformities of the tibia in children : acute versus gradual correction. *J Surg Orthop Adv* 2007 ; 16 (3) : 118-122.
33. **McCarthy JJ, Ranade A, Davidson RS.** Pediatric deformity correction using a multiaxial correction fixator. *Clin Orthop Relat Res* 2008 ; 466 (12) : 3011-3017.
34. **Miller S, Radomisli T, Ulin R.** Inverted arcuate osteotomy and external fixation for adolescent tibia vara. *J Pediatr Orthop* 2000 ; 20 (4) : 450-454.
35. **Noonan KJ, Leyes M, Forriol F, Canadell J.** Distraction osteogenesis of the lower extremity with use of monolateral external fixation. A study of two hundred and sixty-one femora and tibiae. *J Bone Joint Surg Am* 1998 ; 80 (6) : 793-806.
36. **Noonan KJ, Price CT, Sproul JT, Bright RW.** Acute correction and distraction osteogenesis for the malaligned and shortened lower extremity. *J Pediatr Orthop* 1998 ; 18 (2) : 178-186.
37. **Paley D.** Problems, obstacles, and complications of limb lengthening by the Ilizarov technique. *Clin Orthop Relat Res* 1990 (250) : 81-104.
38. **Paley D, Herzenberg JE.** *Principles of deformity correction.* Berlin, Heidelberg, New York : Springer-Verlag ; 2002. 269-288 p.
39. **Paley D, Herzenberg JE.** *Principles of deformity correction.* Berlin, Heidelberg, New York : Springer-Verlag ; 2002.

40. **Paley D, Tetsworth K.** Mechanical axis deviation of the lower limbs. Preoperative planning of multiapical frontal plane angular and bowing deformities of the femur and tibia. *Clin Orthop Relat Res* 1992 (280) : 65-71.
41. **Paley D, Tetsworth K.** Mechanical axis deviation of the lower limbs. Preoperative planning of uniapical angular deformities of the tibia or femur. *Clin Orthop Relat Res* 1992 (280) : 48-64.
42. **Park H, Kim HW, Park HW, Lee KS.** Limb angular deformity correction using Dyna-ATC : surgical technique, calculation method, and clinical outcome. *Yonsei Med J* 2011 ; 52 (5) : 818-830.
43. **Price CT, Scott DS, Greenberg DA.** Dynamic axial external fixation in the surgical treatment of tibia vara. *J Pediatr Orthop* 1995 ; 15 (2) : 236-243.
44. **Probe RA.** Lower extremity angular malunion : evaluation and surgical correction. *J Am Acad Orthop Surg* 2003 ; 11 (5) : 302-311.
45. **Rab GT.** Oblique tibial osteotomy revisited. *J Child Orthop* 2010 ; 4 (2) : 169-172.
46. **Sabharwal S.** Blount disease. *J Bone Joint Surg Am* 2009 ; 91 (7) : 1758-1776.
47. **Sabharwal S, Kumar A.** Methods for assessing leg length discrepancy. *Clin Orthop Relat Res* 2008 ; 466 (12) : 2910-2922.
48. **Sakurakichi K, Tsuchiya H, Kabata T, Yamashiro T, Watanabe K, Tomita K.** Correction of juxtaarticular deformities in children using the Ilizarov apparatus. *J Orthop Sci* 2005 ; 10 : 360-366.
49. **Schaaf AC, Morscher MA, Weiner DS.** The use of the reconstruction plate in multiplanar tibial osteotomies in children. *J Child Orthop* 2011 ; 5 (2) : 127-133.
50. **Schoenecker PL, Johnston R, Rich MM, Capelli AM.** Elevation of the medial plateau of the tibia in the treatment of Blount disease. *J Bone Joint Surg Am* 1992 ; 74 (3) : 351-358.
51. **Sen C, Kocaoglu M, Eralp L.** The advantages of circular external fixation used in high tibial osteotomy (average 6 years follow-up). *Knee Surg Sports Traumatol Arthrosc* 2003 ; 11 (3) : 139-144.
52. **Smith SL, Beckish ML, Winters SC, Pugh LI, Bray EW.** Treatment of late-onset tibia vara using afghan percutaneous osteotomy and orthofix external fixation. *J Pediatr Orthop* 2000 ; 20 (5) : 606-610.
53. **Staheli LT, Corbett M, Wyss C, King H.** Lower-extremity rotational problems in children. Normal values to guide management. *J Bone Joint Surg Am* 1985 ; 67 (1) : 39-47.
54. **Stanitski DF, Dahl M, Louie K, Grayhack J.** Management of late-onset tibia vara in the obese patient by using circular external fixation. *J Pediatr Orthop* 1997 ; 17 (5) : 691-694.
55. **Stanitski DF, Srivastava P, Stanitski CL.** Correction of proximal tibial deformities in adolescents with the T-Garches external fixator. *J Pediatr Orthop* 1998 ; 18 (4) : 512-517.
56. **Watanabe K, Tsuchiya H, Sakurakichi K, Matsubara H, Tomita K.** Acute correction using focal dome osteotomy for deformity about knee joint. *Arch Orthop Trauma Surg* 2008 ; 128 (12) : 1373-1378.
57. **Westberry DE, Davids JR, Pugh LI, Blackhurst D.** Tibia vara : results of hemiepiphyseodesis. *J Pediatr Orthop B* 2004 ; 13 (6) : 374-378.