



## Shape memory embracing fixator for Vancouver type B and type C periprosthetic femoral fractures

Yan XIONG, Quanyin DU, Ziming WANG, Aimin WANG

*From the Department of Orthopedics, Daping Hospital, The Third Military Medical University, Chongqing, China*

**The purpose of this study was to analyze clinical and radiographical results of a group of patients with periprosthetic femoral fractures treated with the shape memory embracing fixator.**

**We retrospectively reviewed twelve patients in whom a total of twelve periprosthetic femoral fractures were treated with the shape memory embracing fixator between August 2004 and February 2013. The patients were 3 men and 9 women (mean age, 69.9 years ; range 42-92 years). The average duration of follow-up was 39.3 months (range 4-103 months). In one case, bone grafting was used. Postoperative evaluation was based on radiographs and Harris hip scores.**

**All fractures healed at on average 4.4 months (range : 3 to 6 months) after surgery. None of the patients developed nonunion or malunion during the follow up. And there was no implant failure and no infection during follow up. The average Harris hip score at the final follow-up examination was 84.8 points.**

**Results show that the shape memory embracing fixator is a safe and effective means for Vancouver type B and type C periprosthetic femoral fractures following hip arthroplasty.**

**Keywords :** Shape memory ; periprosthetic femoral fractures ; total hip arthroplasty.

### INTRODUCTION

The treatment of periprosthetic femoral fractures following hip arthroplasty is complex and challenging. With increasing numbers of total hip arthro-

plasty and increasing average life expectancy, the worldwide incidence of postoperative periprosthetic femoral fracture is on the rise (1,18,19). According to the data from the Swedish National Hip Arthroplasty Registry (21), an annual incidence of postoperative periprosthetic femoral fracture following hip arthroplasty from 1979 to 2000 ranged between 0.045% and 0.13%.

In nondisplaced fractures with a well-fixed prosthesis, nonoperative treatment is usually successful. Cylinder casts, long leg casts, and cast braces have all been used in this condition. In displaced fractures, however, there are major controversies and many difficulties including implant loosening, bone loss and the selection of internal fixation devices (14). And many treatments with internal fixation devices are associated with high rates of complications including malunion, nonunion and fixation device failure (3).

- 
- Yan Xiong, MD.
  - Quanyin Du, MD.
  - Ziming Wang, MD.
  - Aimin Wang, MD.

*Department of Orthopedics, Daping Hospital, The Third Military Medical University, Chongqing, P.R. China. (400042).*

Correspondence : Prof Aimin Wang or Yan Xiong, Department of Orthopedics, Daping Hospital, The Third Military Medical University, Chongqing, P.R. China. (400042).

E-mail : xiongyan815@163.com

© 2014, Acta Orthopædica Belgica.

---



*Fig. 1.* — Photograph showing the shape memory embracing fixator

Shape memory alloys (SMA) constitute a group of metallic materials with the ability to recover a previously defined length or a shape when subjected to an appropriate thermomechanical load. In 1975, Andreasen made the first implant of a superelastic orthodontic device. Subsequently, various shape memory devices were developed and applied clinically in the cardiovascular and orthopedic fields (8,22).

A nickel-titanium (Ni-Ti) shape memory embracing fixator was originally designed to stabilize long bone shaft fractures. The shape memory embracing fixator consists of a body, pairs of arms and sawteeth (Fig. 1). Pairs of arms can symmetrically hold the bone and fix the fracture. Because it has many advantages, such as easy implantation, stable fixation and lower incidence of complication, we used it to treat the periprosthetic femoral fractures following hip arthroplasty and obtained excellent results. In this study, we describe 12 patients with postoperative periprosthetic femoral fractures following hip arthroplasty who were treated with the shape memory embracing fixator.

#### PATIENTS AND METHODS

We retrospectively analyzed the cases of patients with a periprosthetic femoral fracture following hip arthroplasty. Between August 2004 and February 2013, 12 patients with 12 periprosthetic femoral fractures were treat-

ed with the shape memory embracing fixator (Lanzhou Seemine shape memory alloy Co. Ltd., Gansu, China) (Fig. 1). The shape memory embracing fixator has six pairs of arms and can tightly hold the bone. The study was approved by our institutional review board. There were 3 men and 9 women (mean age, 69.9 years; range 42-92 years). One of these patients had evidence of radiological fracture of the prosthesis stem and accepted revision operation. 9 patients suffered their fracture following falls from a standing height, one falls from the wheelchair, one suffered the fracture during the operative course and one suffered their fracture following traffic accident. One fracture occurred in one proximal femoral fibroma operation procedure. According to the Vancouver classification system, there were nine type B1, one type B2 and two type C periprosthetic femoral fractures following hip arthroplasty (Table I).

The operations were performed when the patients' vital signs were stable. Under the spinal anesthetic, a lateral femoral approach was used to expose the fracture. After soft tissue was dissected, the fracture was reduced and extensive periosteal stripping was avoided. The selected fixator was about 10% smaller in the diameter than the femur and more than two pairs of arms on each side of the fracture line. So we can get a greater embracing force to fix the fracture. If the prosthesis was loosening, we changed one new prosthesis and selected the revision operation. And morselized cancellous bone allograft was used in one of the fractures. The shape memory embracing fixator was firstly immersed in ice-cold saline at about 0 °C for five minutes. Then the embracing fixator was distracted by a forceps and placed on the fracture. By

Table I. — Patient demographics

Case	Gender, Age (yr)	Primary Diagnose	Previous operation	Injury	Fracture Type
1	F/67	Femoral neck fracture	THA 2 months	Standing fall	B1 long oblique displaced
2	F/69	Femoral neck fracture	Screw fixation 5 years, HA 5 years, Revision THA 6 years	Standing fall	C transverse displaced
3	M/84	Femoral neck fracture	THA 1.5 years	Standing fall	B1 short oblique undisplaced
4	F/46	Femoral neck fracture	Screw fixation 5 years, THA 8 years	Standing fall	B1 comminuted and displaced
5	M/87	Femoral neck fracture	THA 1 year	Standing fall	C long oblique displaced
6	F/83	Femoral neck fracture and hemiparalysis	THA 2 months	Falling down chair	B1 short oblique displaced
7	F/61	Femoral neck fracture	THA 4 years	Standing fall	B1 long oblique displaced
8	F/42	Proximal femoral fibroma	No	Intraoperative fracture	B1 long oblique displaced in the operation
9	F/77	Femoral neck fracture	THA 1 month	Standing fall	B1 long oblique displaced
10	F/73	Femoral head necrosis	THA 1 year	Standing fall	B1 short oblique displaced
11	F/92	Femoral neck fracture	HA 6 years	Standing fall	B2 long oblique displaced and prothesis stem fracture
12	M/58	Femoral head necrosis	THA 2 years	Traffic accident	B1 long oblique displaced

THA = total hip arthroplasty, HA = hemiarthroplasty.

heating the saline to about 40 °C, the shape memory embracing fixator tended to close, fixed the separated part of bones and maintained the original alignment of the femur. The fixation of the fracture was examined by moving the hip and knee joint. Intra-operatively, the C-arm X-ray machine was used to assess the effect of reduction and fixation. The wound was closed with coated Vicryl Plus antibacterial suture. For one fracture, an embracing fixator and bone grafting were used. In one patient with prothesis stem fracture, the revision THA procedure and the shape memory embracing fixator were used. In ten fractures, the shape memory embracing fixator was used alone. The average operative time was 78 minutes (range : 60 to 90 minutes). The average blood loss was 367 ml (range 200-800 ml).

After the operation, all patients were given antibiotics by intravenous drip for three days. And low-molecular-weight-heparin was used for preventing thrombosis. The patients were managed non-weight-bearing on the involved limb. Early passive exercise of the ankle, knee and hip joint were applied. The postoperative rehabilitation project was designed individually. The patients were instructed to limit weight bearing by using a crutches for the first three weeks. Then patients can be encouraged to partial weight bearing. Anteroposterior plain radiographs

were taken postoperatively and at 4-weekly intervals. According to the plain radiography, the results of fixation, the time to union, and the presence of complications such as nonunion, malunion and loosening of the implant were assessed. When there were radiographic signs of union and mature bridging callus across at the fracture, full weight bearing was allowed. The fracture was considered healed clinically when the patient had no pain on full weight bearing and there was radiographic evidence of a callus bridging the fracture. Final clinical results were evaluated using Harris hip scores.

## RESULTS

The results of surgery are shown in Table II. The average duration of follow-up was 39.3 months (range 4-103 months). The average time from the primary hip arthroplasty to fracture was 31.9 months (range : 0 months to 96 months). One patient underwent the shape memory fixation in the procedure of the first total hip arthroplasty because of the proximal femoral fibroma. One patient underwent fixation after the primary hemiarthroplasty and underwent revision total hip arthroplasty because of

Table II. — Results of surgery

Case	Implant type	Follow up (mo)	Preoperative mobility	Postoperative mobility at 6 month	Radiographic Union (mo)	Harris hip score at final examination
1	EF	103	Independent	Independent	3	95
2	EF+grafting	74	Single cane	Single cane	4	80
3	EF	62	Single cane	Single cane	5	80
4	EF	52	Independent	Independent	4	90
5	EF	52	Single cane	Single cane	6	82
6	EF	48	Crutches	Crutches	6	75
7	EF	28	Independent	Independent	3	90
8	EF	23	Independent	Independent	6	90
9	EF	4	Independent	Independent	4	80
10	EF	4	Independent	Independent	3	85
11	EF+THA	8	Single cane	Single cane	6	80
12	EF	14	Independent	Independent	3	90

EF = embracing fixator, THA = total hip arthroplasty, HA = hemiarthroplasty.

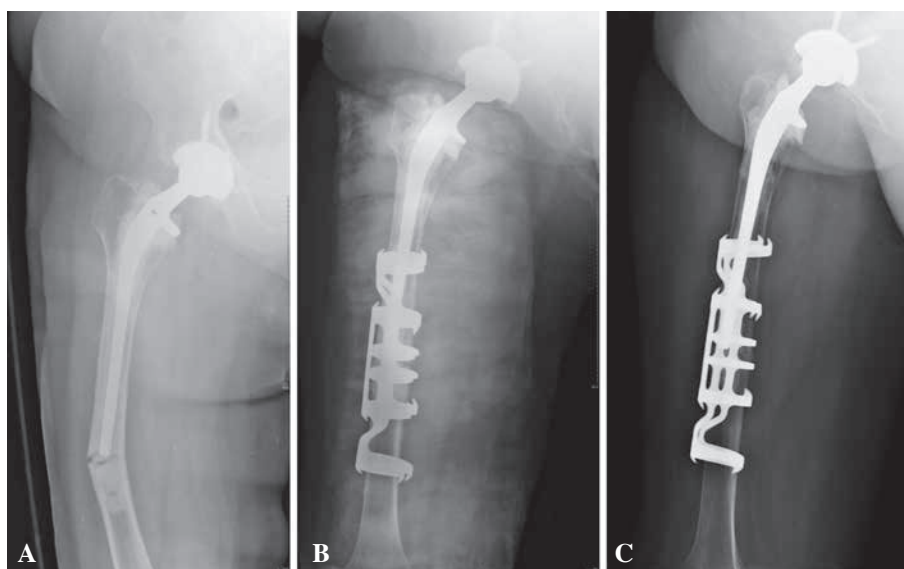
the broken stem. Ten patients had total hip replacement before fractures. The average time from the fracture to the operation was 1.9 days (range : 0 to 4 days). There were no wound infections. Postoperatively, the patients were kept non-weight-bearing for at least 4 weeks. Fractures healed in all patients and there was no nonunion and malunion (Fig. 2). According to radiography, all fractures healed at on average 4.4 months (range : 3 to 6 months) after surgery. There were no implant failures. Varus bending of the embracing fixator did not occur. All patients returned to their previous level of mobility. One patient was able to walk with the assistance of crutches. The average Harris hip score at the final follow-up examination was 84.8 points.

## DISCUSSION

With the rapid increase of the elderly population and rising numbers of total hip arthroplasties, the number of periprosthetic femoral fractures has been proportionally increasing worldwide and the overall incidence has been reported to range between 0.1% and 6% (4). According to the data of the Mayo Clinic Joint Registry, the incidence of periprosthetic femoral fracture after 23,980 primary total hip arthroplasties was 1.1% and the incidence after 6349 revision total hip arthroplasties reached

4% (4,21). According to the data of the Swedish National Hip Arthroplasty Registry, the annual incidence varied between 0.045% and 0.13% (21). And there is an increasing tendency for the occurrence of periprosthetic femoral fractures.

There are many risk factors leading to the periprosthetic femoral fracture. Firstly, the low energy fall is the major injury mechanism. In the Swedish Registry database, approximately 75% of periprosthetic femoral fractures were caused by falls at sitting or standing height (20). In the present study, nine periprosthetic femoral fractures were caused by falls at the standing height. Secondly, several studies indicated that the proportion of periprosthetic femoral fractures in females ranged from 52% to 70% (12,28). Therefore, gender is considered a risk factor for periprosthetic femoral fractures. In the present study, 62.5% of patients are females. Thirdly, many studies provide evidence that age and osteoporosis are risk factors for periprosthetic femoral fracture (20). Wu *et al* studied 16 periprosthetic femoral fractures following 454 cementless total hip arthroplasties (31). They found that the average age of the postoperative fracture group was 65.6 years of age and significantly higher than the non-fracture group. Age and preoperative osteoporosis were found to be significantly associated with the fracture risk. In our study, the average age of periprosthetic



**Fig. 2.** — Case 1, Anteroposterior radiographs of a patient. **A.** the radiograph showing a type B1 periprosthetic femoral fracture, according to the Vancouver classification system which occurred after a total hip arthroplasty. **B.** the fracture was fixed with a shape memory embracing fixator. **C.** the fracture healed at 3 months after the operation.

femoral fractures was 69.9 years of age and six patients had significant evidence of osteoporosis. On the other hand, the most important cause of periprosthetic femoral fractures is osteolysis and resultant aseptic loosening (17). Osteolysis can lead to aseptic loosening and loosening of the stem can increase cement-bone interface motion, resulting in further bone resorption. Thus, in many studies both osteolysis and aseptic loosening have been demonstrated to be risk factors for periprosthetic femoral fractures (5,17). According to 1049 cases from the Swedish Registry, 70% of the implants in periprosthetic femoral fractures after primary hip arthroplasty were loose (20). In the present study, there was one case which showed evidences of loosening of the prosthesis and the broken stem.

There are many classification schemes including that of Johansson *et al*, Bethea *et al*, Cooke and Newman, and Roffman and Mendes. In the present study, we chose the Vancouver classification which has been proved reliable and predictable for the treatment plan. The management of periprosthetic femoral fractures following total hip arthroplasty is complex, challenging and controversial. It is influenced by various factors including the site of the

fracture, bone quality, the stability of the implant, and the condition of the patient (5,26,30,31). The treatment objective includes gaining the best reduction, maintaining implant stability, accelerating fracture healing and allowing mobility of the patient at the earliest. The non-operative method is no longer recommended because of the risk of prolonged bed rest and the high rates of nonunion and malunion (5,26,30,23). In case of loosening of the prosthesis, revision surgery is usually recommended. In our case, there is one case that accepted the revision surgery for the prosthesis loosening. If there is no loosening of the implant, open reduction and internal fixation has been described.

However, the internal fixation encounters many difficulties such as a decreased space for screw insertion next to a stem, possible cracking of the cement mantle, and the creation of stress raisers at the screw path (14). Firstly, cerclage techniques with steel wires, nylon straps and cables were used to treat periprosthetic femoral fractures (11,24,25). But biomechanical studies showed that cerclage techniques had high failure rates with minimal rotational stability. Consequently, the cable-plate systems such as the Mennen, Dall-Miles plate, and

Cable-Ready systems (11,25,29) were developed in order to overcome these problems. But each system was associated with some complications such as failure of fixation, and high rates of nonunion and malunion. Recently, carbon fiber plates and locking plates were used for the treatment of periprosthetic femoral fractures and achieved encouraging results (2,6,7,13). But the majority of periprosthetic fractures are osteoporotic fractures. Some studies have suggested using a minimum of four bicortical locking screws on each side of the fracture (15,16). In most situations, there is limited space for bicortical locking screws around the prosthetic stem and implant failures are often observed.

In the present study, the shape memory embracing fixator was used for the treatment of periprosthetic femoral fracture. Shape memory alloys can return to a former shape when subjected to an appropriate thermomechanical procedure. Many studies reported that the biocompatibility of the shape memory nickel-titanium alloy is better than that of stainless steel (30). Thus, the shape memory nickel-titanium alloy is suitable for long-term implants and has been widely used in the orthopedic field. The triangle sawteeth on the shape memory fixator arms can hold the bone and produce compression axially. In the biomechanically studies shown that compared to the common plates the shape memory embracing fixator has stonger antibending and antitorsional effects and lower antiloading stress. So the bone healing with the shape memory fixator was indirect bone healing (9,10).

In our case study, we did not encounter any technical problems and the shape memory embracing fixator was used with good results. All periprosthetic femoral fractures achieved good unions at a mean of 4.4 months without any infection, malunion and failure of implants. These low rates of complications are better than those achieved using other fixation techniques. Weight bearing was allowed when there were radiographic signs of union. All patients were able to walk with or without crutches. The limitaion of our study was that the sample size was small and was no control group.

In summary, the shape memory embracing fixator is a safe and effective mean for the treatment of periprosthetic femoral fractures following hip ar-

throplasty. Our results indicate that the shape memory embracing fixator can promote fracture union and decrease the rates of complications such as malunion and implant failure.

## REFERENCES

1. **Abendschein W.** Periprosthetic femur fractures a growing epidemic. *Am J Orthop* 2003 ; 32 : 34-36.
2. **Baker D, Kadambande SS, Alderman PM.** Carbon fibre plates in the treatment of femoral periprosthetic fractures. *Injury* 2004 ; 35 : 596-598.
3. **Beals RK, Tower SS.** Periprosthetic fractures of the femur. An analysis of 93 fractures. *Clin Orthop* 1996 ; 327 : 238-246.
4. **Berry DJ.** Epidemiology : hip and knee. *Orthop Clin North Am* 1999 ; 30 : 183-190.
5. **Berry DJ.** Management of periprosthetic fractures : the hip. *J Arthroplasty* 2002 ; 17 (4 Suppl 1) : 11-13.
6. **Buttaro MA, Farfalli G, Paredes Núñez M, Comba F, Piccaluga F.** Locking compression plate fixation of Vancouver type-B1 periprosthetic femoral fractures. *J Bone Joint Surg Am* 2007 ; 89 (9) : 1964-1969.
7. **Chakravarthy J, Bansal R, Cooper J.** Locking plate osteosynthesis for Vancouver Type B1 and Type C periprosthetic fractures of femur : A report on 12 patients. *Injury* 2007 ; 38 : 725-33.
8. **Dai K, Chu Y.** Studies and applications of NiTi shape memory alloys in the medical field in China. *Biomed Mater Eng* 1996 ; 6 (4) : 233-240.
9. **Dai Kerong, Ni Cheng, Wu Xiaotao.** An experimental study and preliminary clinical report of shape-memory sawtooth-arm embracing internal fixator. *Zhonghua Wai Ke Za Zhi* 1994 ; 32 : 629 (in Chinese).
10. **Dai K, Wu X, Zu X.** An investigation of the selective stress-shielding effect of shape-memory sawtooth-arm embracing fixator. In Chu YY, Zhao LC (ed). *Shape memory materials and its applications*. Trans Tech Publication, 2002 ; Switzerland.
11. **de Ridder VA, de Lange S, Koomen AR, Heatley FW.** Partridge osteosynthesis : a prospective clinical study on the use of nylon cerclage bands and plates in the treatment of periprosthetic femoral shaft fractures. *J Orthop Trauma* 2001 ; 15 : 61-65.
12. **Franklin J, Malchau H.** Risk factors for periprosthetic femoral fracture. *Injury* 2007 ; 38 (6) : 655-660.
13. **Fulkerson E, Koval K, Preston CF, Iesaka K, Kummer FJ, Egol KA.** Fixation of periprosthetic femoral shaft fractures associated with cemented femoral stems : a biomechanical comparison of locked plating and conventional cable plates. *J Orthop Trauma* 2006 ; 20 : 89-93.
14. **Giannoudis PV, Kanakaris NK, Tsiridis E.** Principles of internal fixation and selection of implants for periprosthetic femoral fractures. *Injury* 2007 ; 38 (6) : 669-687.

15. **Kääb MJ, Stöckle U, Schütz M, Stefansky J, Perka C, Haas NP.** Stabilisation of periprosthetic fractures with angular stable internal fixation : a report of 13 cases. *Arch Orthop Trauma Surg* 2006 ; 126 (2) : 105-10.
16. **Kumar V, Kanabar P, Owen PJ, Rushton N.** Less invasive stabilization system for the management of periprosthetic femoral fractures around hip arthroplasty. *J Arthroplasty* 2008 ; 23 (3) : 446-50.
17. **Learmonth ID.** The management of periprosthetic fractures around the femoral stem. *J Bone Joint Surg Br* 2004 ; 8 : 613-619.
18. **Lindahl H, Garellick G, Regnér H, Herberts P, Malchau H.** Three hundred and twenty-one periprosthetic femoral fractures. *J Bone Joint Surg Am* 2006 ; 88 (6) : 1215-22.
19. **Lindahl H.** Epidemiology of periprosthetic femur fracture around a total hip arthroplasty. *Injury* 2007 ; 38 (6) : 651-654.
20. **Lindahl H, Malchau H, Herberts P, Garellick G.** Periprosthetic femoral fractures : classification and demographics of 1049 periprosthetic femoral fractures from the Swedish National Hip Arthroplasty Register. *J Arthroplasty* 2005 ; 20 : 857-865.
21. **Malchau H, Herberts P, Eisler T, Garellick G, Soderman P.** The Swedish Total Hip Replacement Register. *J Bone Joint Surg Am* 2002 ; 84 (Suppl 2) : 2-20.
22. **Machado LG, Savi MA.** Medical applications of shape memory alloys. *Braz J Med Biol Res* 2003 ; 36 (6) : 683-691.
23. **Masri BA, Meek RM, Duncan CP.** Periprosthetic fractures evaluation and treatment. *Clin Orthop Relat Res* 2004 ; 420 : 80-95.
24. **Mont MA, Maar DC.** Fractures of the ipsilateral femur after hip arthroplasty. A statistical analysis of outcome based on 487 patients. *J Arthroplasty* 1994 ; 9 : 511-519.
25. **Noorda RJ, Wuisman PI.** Mennen plate fixation for the treatment of periprosthetic femoral fractures : a multicenter study of thirty-six fractures. *J Bone Joint Surg Am* 2002 ; 84A : 2211-2215.
26. **Rosenberg AG.** Managing periprosthetic femoral stem fractures. *J Arthroplasty* 2006 ; 21 (4 Suppl 1) : 101-104.
27. **Ryhänen J, Niemi E, Serlo W, Niemelä E, Sandvik P, Pernu H, Salo T.** Biocompatibility of nickel-titanium shape memory metal and its corrosion behavior in human cell cultures. *J Biomed Mater Res* 1997 ; 35 : 451-457.
28. **Tsiridis E, Haddad FS, Gie GA.** The management of periprosthetic femoral fractures around hip replacements. *Injury* 2003 ; 34 : 95-105.
29. **Tsiridis E, Haddad FS, Gie GA.** Dall-Miles plates for periprosthetic femoral fractures. A critical review of 16 cases. *Injury* 2003 ; 34 : 107-110.
30. **Tsiridis E, Krikler S, Giannoudis PV.** Periprosthetic femoral fractures : current aspects of management. *Injury* 2007 ; 38 (6) : 649-650.
31. **Wu CC, Au MK, Wu SS, Lin LC.** Risk factors for postoperative femoral fracture in cementless hip arthroplasty. *J Formos Med Assoc* 1999 ; 98 : 190-194.