

CASE REPORT

CHONDROBLASTOMA OF THE PATELLA ASSOCIATED WITH AN ANEURYSMAL BONE CYST

R. TREBŠE¹, A. ROTTER², V. PIŠOT¹

Chondroblastoma is a rare, benign tumor of bone, accounting for about 1% of all bone tumor cases. It tends to affect the epiphyseal ends of long bones, most often in males during the first and second decades of life. It has well-characterized radiographic and histologic features but despite its histologically benign appearance a few cases of metastases have been reported. Local recurrences after curettage and bone grafting occur in 11% to 25% of cases. The features of a patellar chondroblastoma are the same as for other locations. In reviewing the literature we found an unusually high male-to-female ratio. It is interesting that the usual treatment of the patellar chondroblastoma has been patellectomy, whereas curettage and bone grafting has predominated in the other locations.

We present a computer tomography and magnetic resonance imaging study of a case of chondroblastoma of the patella associated with an aneurysmal bone cyst. To our knowledge, it is the seventh case reported and the second with computer tomography and magnetic resonance imaging studies. We also review and discuss in detail all the cases of patellar chondroblastoma that we found in the literature.

Keywords : chondroblastoma ; patella.

Mots-clés : chondroblastome ; rotule

cartilage germ cells, and they redefined the tumor as “benign chondroblastoma”.

Chondroblastoma is rare, representing about 1% of all primary bone tumors (1, 5, 9). It is typically centered in an epiphysis. Although it occurs most often in the end of a long tubular bone, it can appear in any secondary center of ossification. It is most probably a tumor of cartilaginous origin and is more common in males by a ratio of about 2-to-1 (1, 5, 9). Seventy percent of chondroblastomas occur during active epiphyseal plate growth, and about two-thirds of the patients are in the second decade of life (5).

Local pain of several months' duration and swelling are the most important symptoms of benign chondroblastoma and affect most patients. Radiographic features include a lytic lesion involving the epiphysis with a thin border of sclerosis. About half of all cases demonstrate central punctate calcification (1). Treatment has usually consisted of curettage with or without bone grafts, but other modalities such as radiotherapy, wide resection, excision, amputation, chemical cauterization, cryosurgery or combinations of these have been used (5, 9).

INTRODUCTION

In 1928 Ewing first described the “calcifying giant cell tumor” subsequently designated “epiphyseal chondromatous giant cell tumor” by Codman in 1931. Jaffe and Lichtenstein considered the histogenesis of Codman's tumor to be derived from

¹ Orthopedic Hospital Valdoltra, Ankaran, Slovenia.

² Department of Pathology, Faculty of Medicine, University of Ljubljana, Slovenia.

Correspondence and reprints : R. Trebše
Ortopedska bolnišnica Valdoltra, Jadranska cesta
31, 6280 Ankaran, Slovenia.

E-mail : info@ob-valdoltra.si.

In patients in whom the chondroblastoma was treated with curettage and bone grafting the reported recurrence rate ranged from 11% to 25%, and when treated with curettage alone from 17% to 60% (1, 5, 9). The recurrence rate after radiotherapy alone is not well documented (1, 9). There is some evidence that lesions in the nonepiphyseal sites and lesions larger than 8 cm have a somewhat higher recurrence rate. Findings that chondroblastomas located in flat bones demonstrate more aggressive patterns of bone destruction compared to the lesions affecting long bones support that possibility. Huvos (5) reported a 100% recurrence rate for lesions associated with an aneurysmal bone cyst (ABC), but others did not confirm this (1, 9).

Malignant potential or a malignant variant has been suggested by many authors (1, 5). A significant percentage of the reported malignant chondroblastomas were diagnosed after radiotherapy and may have been postradiation sarcomas. Some cases of malignant chondroblastomas were subsequently reclassified to other types of neoplasm. In spite of a few reliable reports of a malignant change and metastatic spread there is still some doubt whether so-called "malignant chondroblastomas" exist (9).

CASE REPORT

A 24-year-old athlete was seen because of pain in the right knee which he had had for approximately five years and which had worsened during the preceding half year. Pain started after minor blunt trauma to the knee; it was aggravated after exercise, especially during squatting or running, and disappeared at rest. An xray that was made about one month before we saw him was interpreted as normal, although the presence of some cystic anomaly had been noted. The patient was treated with rest and an ointment with no success.

When we saw the patient he appeared healthy and was afebrile. Physical examination revealed no effusion, erythema or warmth of the knee. The right patella was larger, more prominent, and tender to palpation at the proximal pole. The knee was stable and had a full range of active and passive motion with no crepitation of the patella. The circum-

ference of the right thigh was one centimeter smaller than that of the left thigh. Results of laboratory studies including a hemogram, erythrocyte sedimentation rate, ionogram, urinalysis and coagulation tests were all within normal ranges.

Right knee xrays showed a radiolucent lesion of the right patella with a well-defined lobulated contour, sclerotic rim and some calcifications in the matrix. There were also signs of effusion with a loose body (fig. 1). CT scan revealed a multiloculated osteolytic structure of the patella with sclerotic margins of the lesion, mineral densities in the matrix and a horizontal fluid-fluid level (fig. 2a, b). MR-imaging showed a focal lobulated lesion in the patella with T1-hypo and T2-hyperintense signals.

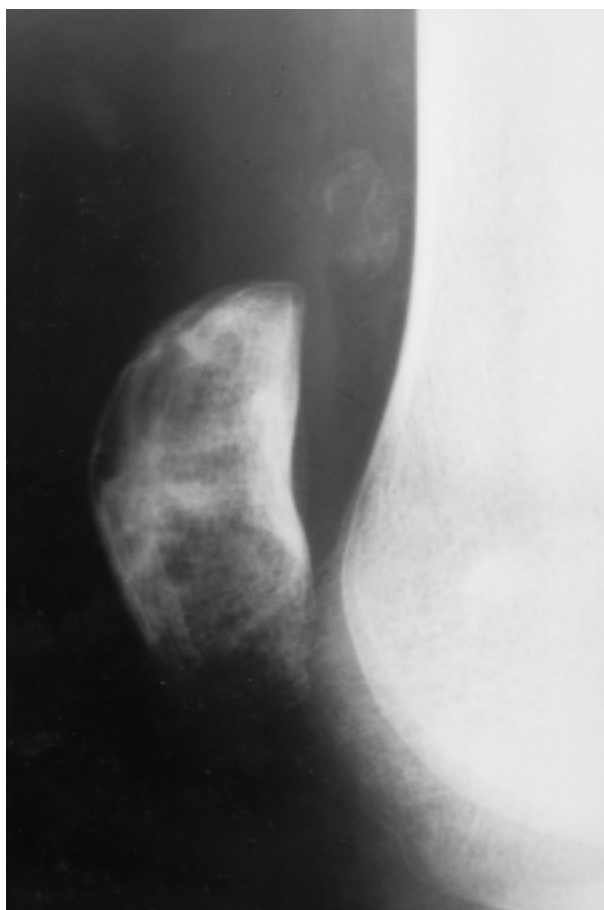


Fig. 1. — Plain lateral radiograph of the patella showing an osteolytic lesion with osteosclerotic regions. There are also signs of effusion and a loose body in the recess.

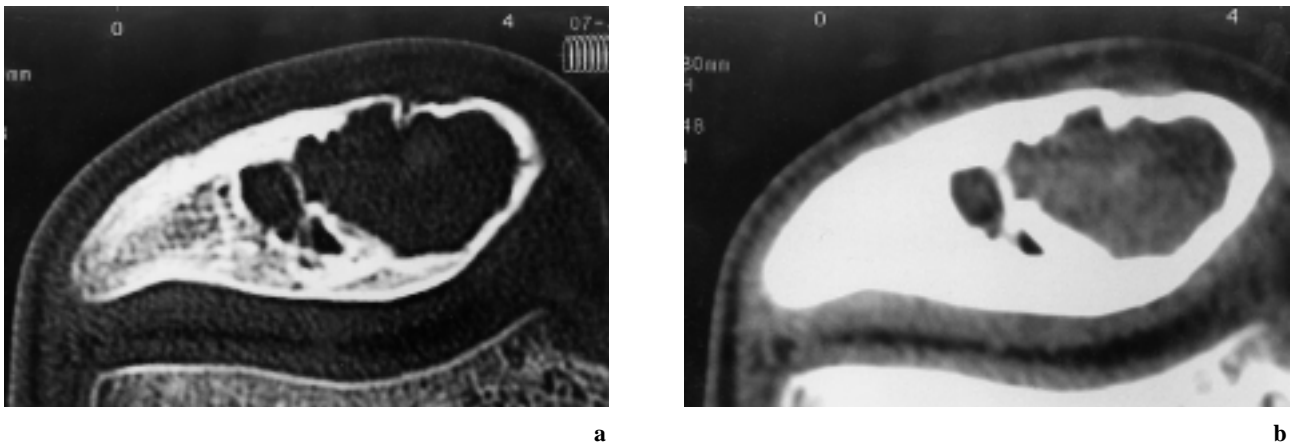


Fig. 2. — *a.* Axial CT-section reconstructed with a bone algorithm revealing a central lytic lesion of the patella with a sclerotic rim. *b.* Axial CT-section reconstructed with an algorithm for the soft tissues revealing a horizontal fluid-fluid level with a more dense liquid in the inferior part.

There were also some T1- and T2-hypointensities within the focal lesion (calcifications on the CT study). The margins of the lesion were well defined (fig. 3a, b).

At surgery no abnormality was found in the soft tissue around the patella. An anterior window was made in the patella, and the osteolytic lesion was thoroughly curetted and rinsed with large amounts of saline. A few milliliters of brownish tissue and serosanguineous fluid was removed from the cavity and sent for histology. The cavity was then packed with an iliac crest cancellous autograft. After the operation the patient was managed with dorsal cast immobilization for two weeks and started with static quadriceps exercises.

After two months the patient resumed normal activities. He had a normal, pain-free range of motion. Radiographically there was no radiolucency in the patella. Seven months after the operation the patient was asymptomatic. There were no radiographic abnormalities on the xrays of the knee. Two and a half years after the surgery the patient was still asymptomatic, and there were no clinical or radiographic signs of a recurrence. He resumed competitive sports.

PATHOLOGIC RESULTS

Light microscopy of the tumor revealed two distinct parts : one was sharply demarcated hypocellu-

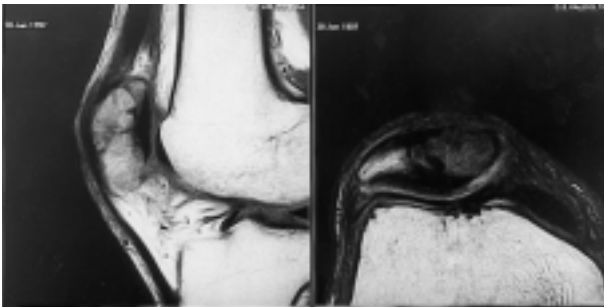
lar chondroid matrix with dispersed chondroblast-like cells lying singly in lacunae combined with the regions of myxoid fibrous stroma with stellate and spindle cells, and the other part was highly cellular sheets of tumor cells (fig. 4).

On high-power view polyhedral chondroblasts with distinct cytoplasmic borders, pale pink cytoplasm, and hyperlobulated nuclei intermingled with an osteoclastic type of nonneoplastic multinucleated giant cells, surrounding poorly formed chondroid matrix, were seen. In the matrix there were some calcifications in combination with the cells, arranged in a pattern, slightly resembling “chicken-wire”. There were varying but slight degrees of cellular atypia with some large hyperchromatic nuclei, and few regular mitotic figures. There were numerous irregular vascular spaces, extravasation of erythrocytes and deposition of hemosiderin pigment mostly within macrophages.

DISCUSSION

The location of a chondroblastoma in the patella was formerly considered highly unusual, but since Ogden has emphasized the similarity between the patella and the epiphysis, it is not surprising that a chondroblastoma can also arise in the patella which is formed from a cartilage focus.

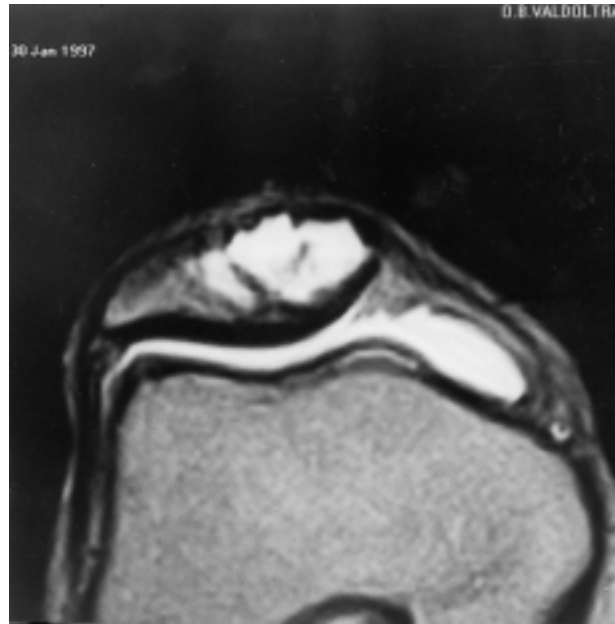
A review of the literature identified a total of 45 cases of chondroblastoma of the patella,



a

Fig. 3. — *a.* Axial and sagittal FE T1-weighted MR-scan showing a focal patellar lesion with a hypointense T1-signal from the lesion (relative to the signal from the muscle) and a hypointense signal in the recess. There are also some T1-hypointensities within the focal lesion (mineral densities on the CT-study).

b. Axial SE T2-weighted MR-scan showing a hyperintense T2-signal from the lesion (relative to the signal from the muscle) and a hyperintense signal in the recess. There are also some T2-hypointensities within the focal lesion (mineral densities on the CT-study).



b

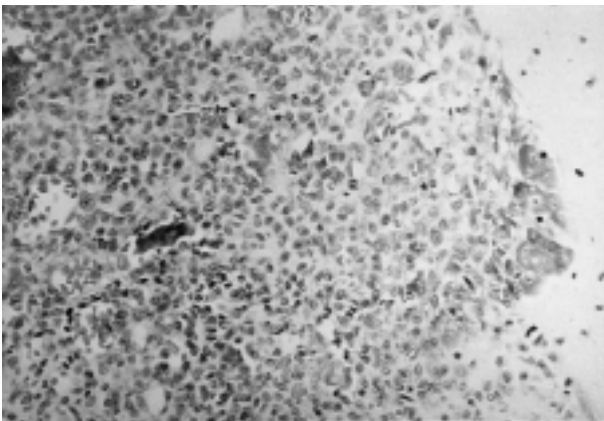


Fig. 4. — Photomicrograph of a specimen from the lesion shows a hypercellular region of polyhedral chondroblast-like cells with distinct cytoplasmic borders, pale cytoplasm, and hyperlobulated nuclei intermingled with an osteoclastic type of nonneoplastic multinucleated giant cells, sharply demarcated (fat arrow) from a poorly formed chondroid matrix (CM). In the interstitium of the cellular part of the tumor there are some focal calcifications. Tumor cells show varying but slight degrees of atypia with some large hyperchromatic nuclei. There are also numerous, irregular proliferated vascular spaces (empty arrows) with extravasation of erythrocytes and deposition of hemosiderin pigment, mostly within macrophages. (Giemsa stain, magnification 108 ×).

but clinicopathological data is available only for 30.

The patient's age was known in 29 of 30 cases. The mean age was 21.1 years, with a range from 11 to 35. The patients' gender was known in 28 of 30 cases revealing a striking 4-to-1 male-to-female ratio (22 males / 6 females). There was no predilection for either the right or left patella. Pain was the dominant clinical feature in all these patients. It lasted from 5 weeks to 6 years. It was intermittent in 5 patients and sometimes related to strenuous activities. In 5 cases there was a pathological fracture (10).

Seven lesions, including ours, were associated with an aneurysmal bone cyst (ABC) (3, 4, 10), and five of them presented with an enlarged and distorted patella. At least four of these presented with signs of knee joint irritation. In the 23 patients without coexistent ABC, no patellar enlargement or signs of joint irritation were noted (7). The exception is the first published report (2) in which the patient presented with signs of joint irritation and a fracture. A coexistent ABC was not explicitly mentioned, but according to the pathologic report and the xrays published it was most probably present.

Radiographically patellar chondroblastoma appears as a well-defined lucency, 1 to 3.5 cm in

size with well-defined and usually sclerotic margins suggesting benign histology (7). The smallest lesions demonstrated round contours, indicating that the lobulated contour seen in the remaining cases may be a function of the larger size of the lesion or an association with an ABC, which is commonly present secondarily to extrapatellar chondroblastoma (1). ABC-associated cases also demonstrated an enlarged patellar contour compared to the healthy side (1).

Bone expansion, which was found in 63% of extrapatellar chondroblastomas of flat bones, was present in four cases of patellar chondroblastoma associated with an ABC, and in no case out of the 23 chondroblastomas without an ABC. Bone expansion thus appears as a probable feature of the ABC.

Technetium bone scan was made in four cases, and it always showed hyperfixation (3, 7).

Both CT and MRI studies were done only once before, and the characteristics of the patellar chondroblastoma were not different from the extrapatellar ones. CT demonstrated a regular multilocular, hypodense lytic-sclerotic tumor with septations, calcifications and fluid-fluid levels within the lesion. MRI revealed low-to-intermediate, heterogeneous signal intensity, lobular internal architecture and fine lobulated margins.

Treatment consisted of curettage and bone grafting without additional cryosurgery or phenolization in five cases (3, 6, 8, 10) and patellectomy in 23 cases (2, 7, 9). In one case (4) biopsy and bone grafting of the defect was followed by patellectomy one year later.

Follow-up data were available in eight cases (2, 3, 6, 8, 9, 10). After a mean time of 3.5 years (range 1 to 8 years) there was only one recurrence after five years, which was subsequently retreated with curettage and bone grafting. In this particular case the diagnosis at the first attempt of curettage with bone grafting was ABC without a chondroblastoma. The histology at the second operation revealed ABC and chondroblastoma instead. The authors concluded that even at the first surgery there was probably a missed chondroblastoma because no case has yet been documented of a chondroblastoma developing from an ABC.

From the reports about patellar osteolytic lesions (10) we found that 50% consisted of non-neoplastic conditions including; dorsal defects, brown tumors of hyperparathyroidism, osteomyelitis, osteochondritis dissecans, rheumatoid cysts and Paget's disease of bone. The remaining were neoplasms. From these 70 to 90% proved to be primary and benign. Although very rare, chondroblastoma seems to be the most probable neoplasm. Other benign lesions found in the patella were (in decreasing order of frequency): giant cell tumors, simple bone cysts, hemangiomas, lipomas, chondromas and osteoblastomas. Malignant lesions were mostly metastases but also lymphomas and hemangioendotheliomas.

ABC is present secondary to chondroblastoma in 6 to 31% of cases. In the patella it was present, according to our investigation, in 23.3% (7 out of 30 well-documented cases). ABC is secondary to a neoplasm in 28%. Even primary ABC's mostly emerge during a reactive bone process such as fracture healing, periosteal trauma and heterotopic ossification. It is possible that a vascular anomaly in a primary bone lesion or in the reactive bone growth causes a hemodynamic change, which develops into an ABC.

In one case (4) the reason for a patellectomy in a young healthy person was purely cosmetic which is unacceptable. For the others one may only speculate on the reasons for such a high rate of patellectomy. It is possible that the diagnosis was not considered preoperatively, which is in contrast with Bloemi and Mulder's report (1) in which it is stated that the radiological diagnosis of chondroblastoma in general has a sensitivity of 75% and a specificity of 99%. Their report is based on features seen on plain xrays from 1953 to 1982, which excludes the possibility of a less accurate preoperative diagnosis in the pre-CT era. We think that preoperative suspicion of chondroblastoma is possible since it appears to be the most probable benign neoplasm in the patella. This would permit using a more conservative procedure such as curettage and bone grafting instead of patellectomy. The fact that the recurrence was reported in only one case and there are no case reports of malignant change of patellar chondroblastoma

supports more conservative treatment modalities, too.

Another unexpected finding that resulted from reviewing reports of patellar chondroblastoma is the male-to-female ratio. It could be a chance finding, but we can also speculate that it is the result of a higher rate of repetitive micro-and macrotrauma in males. The possibility arises, that traumatic events or repetitive strain does have a role in the development of chondroblastoma in the patella. Supporting this possibility we found that out of 13 patients with a reported trauma history, six had definite trauma to the patella and a few more were involved in strenuous athletic or work activities. The time interval between the traumatic event and the occurrence of the chondroblastoma ranged from a few months up to seven years. The incidence of trauma and strenuous activities seems too high to be accidental, but strong evidence is missing.

We think that when xrays, CT and MRI all point to the diagnosis of a chondroblastoma of the patella, the treatment of choice should be curettage and bone grafting. If however any suspicion has arisen in the diagnostic workout, a biopsy to determine the need for further radical surgery should be performed first.

Acknowledgements

We would like to thank Mr. Fonda Silvester, M.D. for helping to manage the case.

REFERENCES

1. Bloem J. L., Mulder J. D. Chondroblastoma. A clinical and radiological study of 104 cases. *Skeletal Radiol.*, 1985, 14, 1-9.
2. Cohen J., Cahen I. Benign chondroblastoma of the patella. *J. Bone. Joint. Surg.*, 1963, 45-A, 824-826.
3. Ghekiere J., Geusens E., Lateur L., Samson I., Sciote R., Baert A. L. Chondroblastoma of the patella with a secondary bone cyst. *Eur. Radiol.*, 1998, 8, 992-995.
4. Gottschalk A., Solomon L., Isaacson C., Schmaman A. Aneurysmal bone cyst of the patella secondary to chondroblastoma. *S. Afr. Med. J.*, 1985, 67, 105-106.
5. Huvos A. G., Marcove R. C. Chondroblastoma of bone. A critical review. *Clin. Orthop.*, 1973, 95, 300-302.
6. James R. L., Shelton M. L., Sachdev R. K. Chondroblastoma of the patella with a pathologic fracture. *Orthop. Rev.*, 1987, 16, 834-835.
7. Moser P. R., Brockmole D. M., Vinh T. N., Kransdorf M. J., Aoki J. Chondroblastoma of the patella. *Skeletal Radiol.*, 1988, 17, 413-419.
8. Remagen W., Schäfer., Roggatz J. Chondroblastoma of the patella. *Arch. Orthop. Trauma. Surg.*, 1980, 96, 157-158.
9. Schajowicz F., Gallardo H. Epiphysial chondroblastoma of bone. A clinico-pathological study of sixty-nine cases. *J. Bone. Joint. Surg.*, 1970, 52-B, 205-226.
10. Wolfe M. W., Halvorson T. L., Bennett J. T., Martin P. C. Chondroblastoma of the patella presenting as a knee pain in an adolescent. *Am. J. Orthop.*, 1995, 24, 61-64.

SAMENVATTING

R. TREBŠE, A. ROTTER, V. PIŠOT. Chondroblastome in associatie met een aneurysmale beenkyste van de patella.

Dit rapport beschrijft de ongewone associatie van een chondroblastoma met een aneurysmale beenkyste gelocaliseerd in de patella. Het gaat om het zevende geval in de literatuur en het tweede waarbij CT en NMR beelden beschikbaar zijn. Naar aanleiding van dit geval brengen we een overzicht van de literatuur omtrent chondroblastoma van de patella.

Chondroblastoma is een benigne zeldzame beentumor (1% van het totaal aantal beentumoren). De localisatie is het epiphysair uiteinde van een lang been, meestal bij mannen in hun eerste of tweede levensdecade. Het vertoont typische radiografische en histologische kenmerken, en niettegenstaande zijn benign histologisch aspect zijn er toch gevallen met metastasering beschreven. Lokaal herval na curettage en opvulling komt voor in 11% tot 25% van de gevallen. Bij patella aantasting zijn er geen afwijkende verschijnselen ten opzichte van andere localisaties. Ook daar is de man-vrouw verhouding sterk nadelig voor de man. Gewoonlijk wordt patellectomie uitgevoerd, waar elders een curettage en enting de regel is.

RÉSUMÉ

R. TREBŠE, A. ROTTER, V. PIŠOT. Chondroblastome de la rotule associé à un kyste osseux anévrysmal.

Le chondroblastome est une tumeur osseuse bénigne rare, représentant environ 1% des tumeurs osseuses. Ce sont les épiphyses des os longs qui sont le plus souvent touchées, surtout chez des sujets masculins dans leur deuxième décennie. Les aspects radiologiques et

histologiques sont typiques. L'évolution de la lésion et l'histologie sont généralement de type bénin ; quelques cas avec métastases sont cependant cités. Des récurrences ont été observées dans 11-25% des cas, après traitement par curetage et greffe.

La pathologie du chondroblastome de la rotule est la même que celle des chondroblastomes qui affectent les autres os, avec cette différence qu'il est quatre fois plus fréquent chez l'homme que chez la femme. Dans le

passé, le traitement le plus fréquent du chondroblastome de la rotule a été la patellectomie tandis que, pour les autres chondroblastomes, le traitement a été plus conservateur, associant curetage et greffe osseuse.

Nous présentons un cas de chondroblastome de la rotule associé à un kyste osseux anévrysmal. C'est le septième cas rapporté qui présentait cette association de lésions et c'est le deuxième étudié par CT et IRM. Nous discutons en détail les cas rapportés dans la littérature.