



Mid-term results for hip resurfacing in patients under 30 years old with childhood hip disorders

Simon MACLEAN, Scott EVANS, Paul PYNSENT, John O'HARA

From The Royal Orthopaedic Hospital, Birmingham, UK

The aim of our study was to assess survivorship and function in young patients with hip resurfacing for degenerative arthritis secondary to childhood hip diseases. Data was collected retrospectively using the institutional database and patient notes. Between 1999 and 2012, there were 156 hip resurfacings performed in 143 patients (82 females, 73 males). Mean age at the time of surgery was 21.4 years (12.3 to 30.0). The main indications for surgery included ; DDH, AVN, Perthes' and SUFE. Median follow-up was 4.1 years (1.0 to 13.2). Median Oxford scores improved from 54.2 pre-op to 18.8 post-op at a minimum of 2 years follow-up. There were 14 failures. Median head size was 46 mm (45 mm in the failures) For the failures, median cup inclination was 44.4 degrees and anteversion 7.6 degrees. We report the largest single surgeon series of resurfacing hip arthroplasty in the under 30's for childhood hip disorders. 90% 5-year survivorship and good functional outcome can be achieved.

Keywords : hip resurfacing ; hip dysplasia ; young adult hip ; survivorship ; Perthes' disease ; Developmental dysplasia of the hip.

ics. Arthroplasty in this population is reserved for where there is no useful joint-preserving option. The surgeon aims to reduce pain and optimise function yet needs to conserve bone. Surgical challenges arise from the patient age, previous surgery, soft tissue imbalance and aberrant femoral and acetabular anatomy. Arthrodesis is not acceptable anymore for reasons of function, cosmesis and self-esteem. It is undesirable because of adverse effects on spine and knee function and the development of degenerative changes in these parts. Total hip arthroplasty leads to stress shielding of the proximal femur. Stem failure leads to revision surgery, bone loss and functional limitations.

Hip resurfacing was popularised in the early 1990s as a way of preserving biomechanics, improving hip stability and consuming less bone on the femur than a total hip replacement. A total hip replacement then becomes instead the first revision operation. It is potentially the lowest rung on the

INTRODUCTION

The management of degenerative arthritis secondary to childhood hip disorders in young patients is a significant challenge. Many of these patients have already undergone surgery in order to optimise bony anatomy, joint congruity and hip biomechan-

■ Simon MacLean, FRCS (Tr&Orth).

■ Scott Evans, FRCS (Tr&Orth).

■ Paul Pynsent, PhD.

Department of Paediatric and Young Adult Hip Reconstruction, The Royal Orthopaedic Hospital, Birmingham, UK.

Correspondence : Simon MacLean, The Royal Orthopaedic Hospital, Bristol Rd South, Northfield, Birmingham, UK. B31 2AP. E-mail : simon.macleane@nhs.net

© 2015, Acta Orthopædica Belgica.

arthroplasty ladder. Medium to long-term data shows promising survivorship and functional results in males with “primary” osteoarthritis (4,15).

Previous studies have reported hip resurfacing in younger patients but study numbers have been limited and many have involved multiple surgeons in nature. Confusingly these have included hips with “primary osteoarthritis” (1-3,7,10,13,14,17), a diagnosis unacceptable in the age of modern imaging.

Resurfacing use has decreased in recent years due to reported concerns on patients with Adverse Reaction to Metal Debris (ARMD) (3), and higher than expected failure rates in females, and those with smaller implant sizes (4). We assessed the survivorship and function in young patients with hip resurfacing carried out exclusively by a single surgeon for degenerative arthritis due to childhood hip diseases.

SUBJECTS AND METHODS

All data was retrospectively extracted from our institution’s hip database or patient notes. Between 1999 and 2012 there were 156 hip resurfacings performed in patients below thirty years of age by a single surgeon in 143 patients. Eighty-two resurfacings were performed in females, 73 in males. Resurfacing was considered by the senior author as the preferred arthroplasty choice in young adults due to retention of femoral bone stock ; allowing the inevitable future revision operation to be a total hip replacement with a standard femoral stem. There were a number of patients in our cohort with neuromuscular diseases or ‘windswept’ lower limbs contractures from immobility. It was decided that a resurfacing with a large femoral component would minimise dislocation risk. Two patients died from unrelated causes during the follow-up period, and these was treated as censored data. Mean age at the time of surgery was 21.4 years (range 12.3 to 30.0). Indication for surgery is given in table I.

Pre-operative Oxford Hip Scores were collected using the method described by Pynsent *et al* (12) within 6 months of surgery. In this method a healthy joint scores 0% and the worst possible joint, 100%. Patients were excluded if suffering with significant disability where it was deemed the Oxford score an inappropriate tool to use in these cases. For patients with pre-operative scores, further scores were collected at regular intervals between their 6 weeks post-operative appointment and discharge.

Overall, the cohort included 88 Birmingham hips (Midland Medical Technologies Ltd, Birmingham, UK and Smith and Nephew, London, England) and 63 Adept hips (Finsbury Orthopaedics Ltd, later MATORTHO, Leatherhead, UK). Cup inclination and anteversion angles were then measured with ImageJ software using the 6-week post-operative x-ray (18). All patients were assessed in clinic by the senior author at 6 weeks, 3 months, 6 months, 12 months post-operatively and then at five yearly intervals.

Cobalt and Chromium levels of 7 parts per billion has been defined as a threshold level by the Medicines and Healthcare Products Regulator Agency (MHRA) (19) (119 nmol/L cobalt and 134.5 nmol/L chromium). Metal ion levels were collected when possible based on patient availability at various time intervals post-operatively.

Statistical Analysis

Kaplan-Meier analysis was used to determine the survivorship of the prosthesis with revision as the end point. Mood’s test was used for comparison of median values.

Surgical Technique

From 1999 to 2007, the posterior approach to the hip was used. The Hardinge approach was used from 2007 to 2008. It appealed because of the excellent view of the anterior head-neck junction it afforded. Acetabular exposure was comparable in both approaches. We reverted to the posterior approach because, so far, 15 of a total of 356 patients operated upon by the Hardinge approach for arthroplasty or hip debridement ruptured their abductors and required secondary repair. We have found that hip resurfacing and hip debridement patients are not really patient or tolerant of the restrictions obligatory for the first six weeks after the Hardinge approach.

In choosing the prosthesis size we were conscious of the need not to adversely affect the head-neck ratio as it would restrict the range of motion. We were particularly conscious that the functioning articulating diameter included the articular cartilage. Accordingly we determined component size by measuring the diameter of the *unreamed* acetabulum using an acetabular trial.

In terms of femoral component placement, we aimed to put the stem of the prosthesis parallel to the calcar in both planes. We used the isthmus of the neck as reference for the antero-posterior and medial-lateral location of the head component, regardless of the head shape. In dysplasia and patients who had neuromuscular disorders, we often found a flat eroded surface laterally. In Perthes’ dis-

Table I. — Pathology within the cohort

Indication for surgery	Number
Congenital dislocation and dysplasia of the hip	43
Secondary Osteoarthritis – bone dysplasias	30
Avascular necrosis	22
Secondary OA – Cerebral Palsy	18
Perthes' disease	18
Slipped upper femoral epiphysis (SUFE)	11
Previous infection	5
Inflammatory arthropathy	3
Secondary OA - Down's syndrome	2
Psoriatic arthritis	1
Ankylosing spondylitis	1
Secondary OA – Spina Bifida	1
No indication recorded	1
TOTAL	156

ease we often had to trim back the circumferential diameter of the short head to place the instruments accurately ; we also assessed the contra-lateral head-neck ratio and used this as a guide to help sizing in Perthes'.

If the bony head or neck were short we often found that restoring length fully resulted in a gap inside the head component which would be occupied with cement. If this occurred, we then judiciously lost some length to ensure that the apical weight-bearing bone had direct contact with the internal chamfer of the prosthesis and that the cement was fully contained and sealed by at least 5mm of the cylindrical section of the head. Individualised preparation and roughening of the small areas of bone not touched by the chamfer reamer was required. The head component was filled with chilled low-viscosity cement and seated on the femur. This technique did not allow more than 5-8 mm of leg-length on the femoral side. If greater length gain than this was required, we modified our acetabular preparation slightly.

On the acetabular side the most common problem encountered was dysplasia. Our aim was to fix the acetabular prosthesis in the normal hip centre. Initially we aimed for 15-20 degrees of anteversion and 45 degrees of lateral cover ; from 2007 we aimed for 40 degrees or better of acetabular cover. We usually reamed the bony socket to 4mm more than the original diameter and deepened it enough to allow the prosthesis to be medialised to gain adequate antero-posterior grip. We started by reaming medially and posteriorly into the acetabular

fossa with a reamer of less than the original acetabular diameter ; only then did we ream to the desired size in the direction of introduction of the prosthesis. It was often necessary to hammer a small punch medially onto the plastic mounting disc to seat the prosthesis medially before the introducer handle was impacted fully. When using the Dysplasia (Smith & Nephew) or the Extra Fixation Cup (MATORTHO), in addition to the above measures, we secured the cup temporarily with a 4-5 cm cortical screw through the first fixation hole, before fixing the cup definitively with the manufacturer's 6.5 mm neutralisation screws. Where we needed to gain some length on the acetabular side, we reamed medially enough to get the required grip and proximally only just enough to remove all articular cartilage. In achieving a sub-tension angle of less than 40 degrees, there often resulted in up to 5 mm of exposed acetabular component laterally, which we disregarded and found to be of no concern.

RESULTS

Mean follow-up was 4.1 years (range 0.1 to 13.2). In 53 patients it was deemed appropriate to use the Oxford score as a measure of functional improvement. These patients had pre-operative Oxford hip scores, and 198 scores were collected at various time intervals post-operatively (Fig. 1). There was no significant difference between the median scores

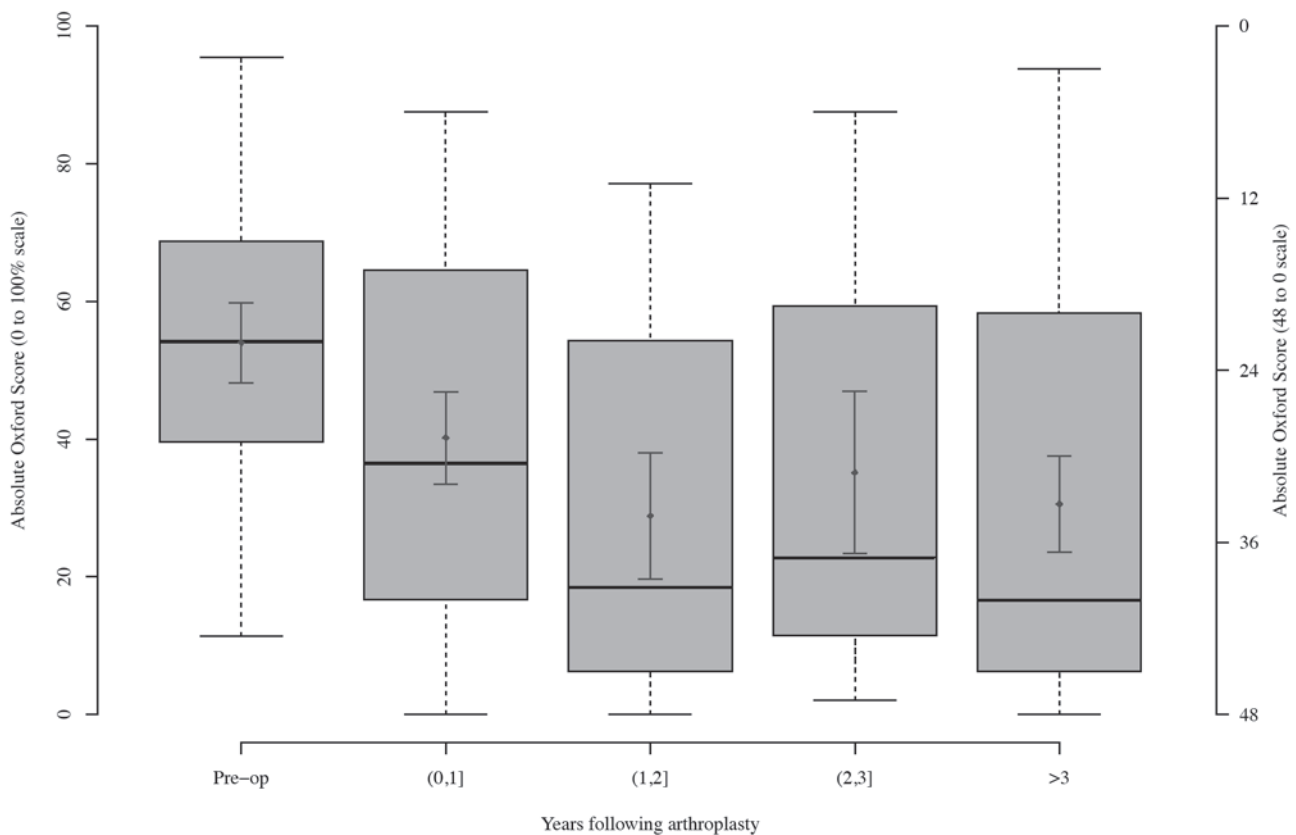


Fig 1. — Oxford hip Scores following surgery (time from surgery = time '0')

of males and females at 2 or more years following surgery ($p = 0.846$).

There were 14 revision operations in 13 patients (one bilateral). There were 8 males and 6 females in this group. The demographics of these patients and reasons for failure are shown in table II. Example of a failure is shown in figure 2. Survival analysis is shown in figure 3. 5 year survivorship was 90.0%, and 78.6% at 10 years.

For the failures, the median post-operative cup inclination angle following primary surgery was 44.4 degrees (IQ range : 32.0-51.0) and the anteversion angle was 7.6 degrees (IQ range : 7.6-8.2).

Cup sizes used in the cohort is shown in table III. In the overall cohort median head size was 46 mm (females median size 44 mm, males 50 mm). In the failures, median head size was 45 mm.

Cobalt and chromium levels were only available in 31 patients (32 hips). The median cobalt level was 1.24 (IQ range 0.71-8.54) and for chromium was 2.08 (1.30-6.71). The maximum levels for cobalt and chromium against time from the primary surgery are shown in figures 5a and 5b respectively.

DISCUSSION

This is believed to be the largest series of hip resurfacings in the young adult from a single surgeon. The patients in our series present unique technical challenges to the arthroplasty surgeon. The series includes some pathologies which have been included in other published papers, but this series has also reviewed resurfacings in a higher proportion of patients with neuromuscular disease and bone

Table II. — Demographics of patients undergoing revision operations

Patient	Age at operation	Head size	Cup size	Aetiology	Reason for failure	Months to revision	Previous surgery	Revision
1	24y7m	46	52	DDH	Undiagnosed pain	15	Valgus osteotomy, trochanteric bursectomy, arthroscopic labrectomy, shelf osteotomy	Uncemented THR
2	18y7m	38	44	Acquired dysplasia (spastic-type CP)	Dislocation (cup slipped)	1		Cup revised
3	26y1m	38	46	Perthes	Loose cup. Stem loosening	2, 36		Cup revised to Dysplasia cup, Uncemented THR
4	25y4m	46	52	DDH	Loose cup	76		Cup revised
5a	19y4m	42	50 (dysplasia cup)	Epiphyseal dysplasia	Stem loosening	28		Large metal-on-metal THR
5b	19y4m	42	48 (dysplasia cup)	Epiphyseal dysplasia	Stem loosening	37		Revision to uncemented Freeman Stem
6	14y3m	42	48	Acquired dysplasia (spina bifida)	Dislocation			?
7	25y4m	46	52	AVN	Loose cup	14	Fractured neck of femur – screw fixation	Cup revised
8	28y2m	50	56	Acquired dysplasia (spastic-type CP)	Loose cup	1 m		Cup revised (dysplasia cup)
9	19y5m	46	52	AVN	Stem loosening and loose cup	108		Exeter stem, Pinnacle cup
10	26y1m	52	58	Perthes	Loose cup	2		Cup revised (dysplasia cup)
11	25y4m	46	52	DDH	Loose cup	76		Cup revised
12	19y4m	44	50 (dysplasia cup)	Epiphyseal dysplasia	Loose cup and stem loosening	41		Large metal-on-metal THR
13	19y4m	42	48 (dysplasia cup)	Epiphyseal dysplasia	Stem loosening	37		Revised to uncemented Freeman stem

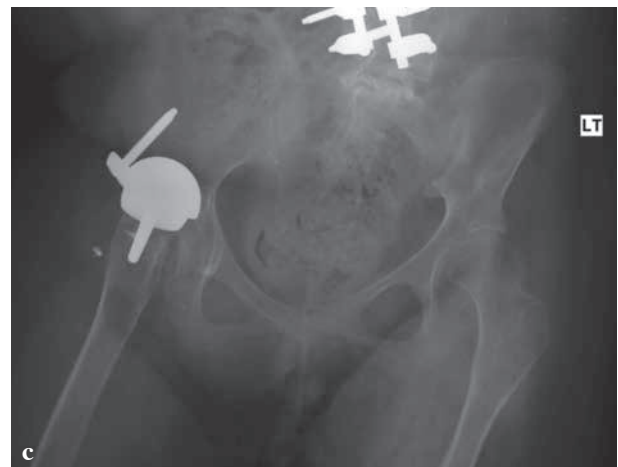
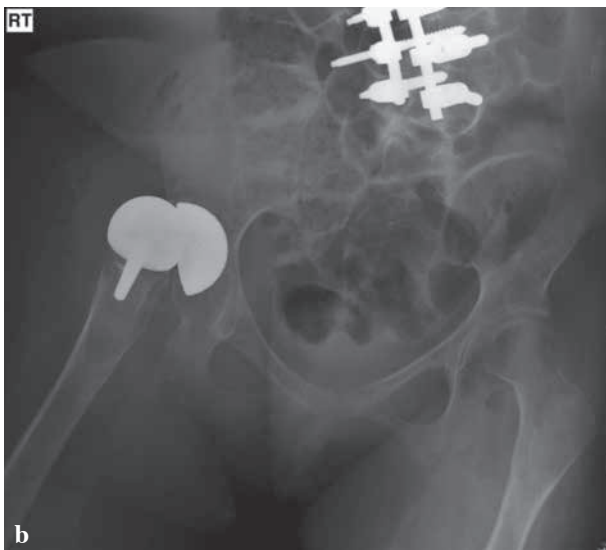
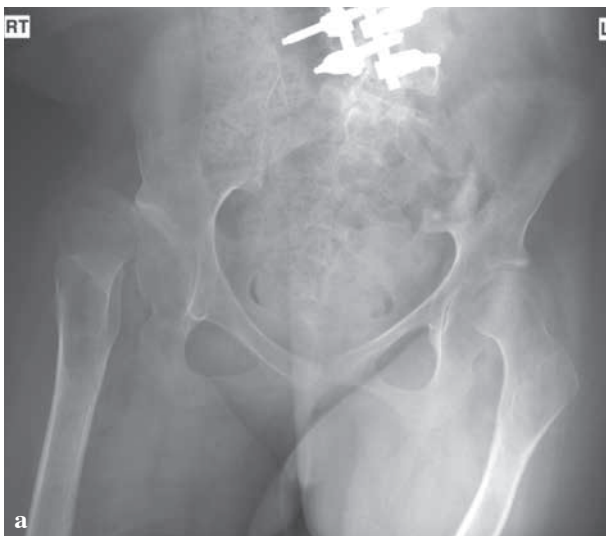Fig. 2. — a. Pre-operative 18 year old patient with spastic-type cerebral palsy. b. 1 month post-operative film showing cup has slipped. c. Cup revised with additional screw augmentation.

dysplasias. We also believe our series of resurfacing in this population has the youngest mean age yet published.

The 5-year survivorship of 90% has demonstrated that good survivorship can be achieved in this complex group of patients, and is comparable to current published literature. In other papers (10,14) early failures have usually been seen due to femoral neck fracture and late failures due to implant loosening. In our study, most failures occurred on the acetabular side. This does not appear to relate to inappropriate implant positioning (as our mean cup inclination in the series of failures neared 40 degrees), but may relate to poor acetabular bone stock,

soft tissue deficiencies around the hip joint and abnormal muscular forces. In cases where bone stock is particularly poor, caution should be taken when using a hip resurfacing, as relatively more acetabular bone is removed in contrast to a total hip replacement, where smaller socket sizes can be used. We therefore recommend a total hip replacement in these cases where acetabular bone stock is compromised. Previous osteotomy is usually a sign of significant hip dysplasia. In these patients, restoration of the hip centre of rotation is challenging, and incorrect placement of the cup may lead to dislocation. In addition, severe capsular laxity and muscle attenuation/dysfunction usually occurs, adding to the potential for instability.

Where there had been a deficient iliac wing due to bone harvesting for Salter's osteotomy or acetabuloplasty, we have therefore become particularly conscious of the potential to convert a stiff, painful hip into a mobile but potentially unstable one, with poor muscle control not easily overcome by rehabilitation.

Several studies have reported the use of total hip arthroplasty (THR) in the young adult. Daurka reported the ten-year results of THR in patients with an average age of 14.4, with a 62% survivorship of the acetabular component (94% of the femoral component), but found improved results in the ceramic-on-ceramic hips (5). Pruscynski *et al*

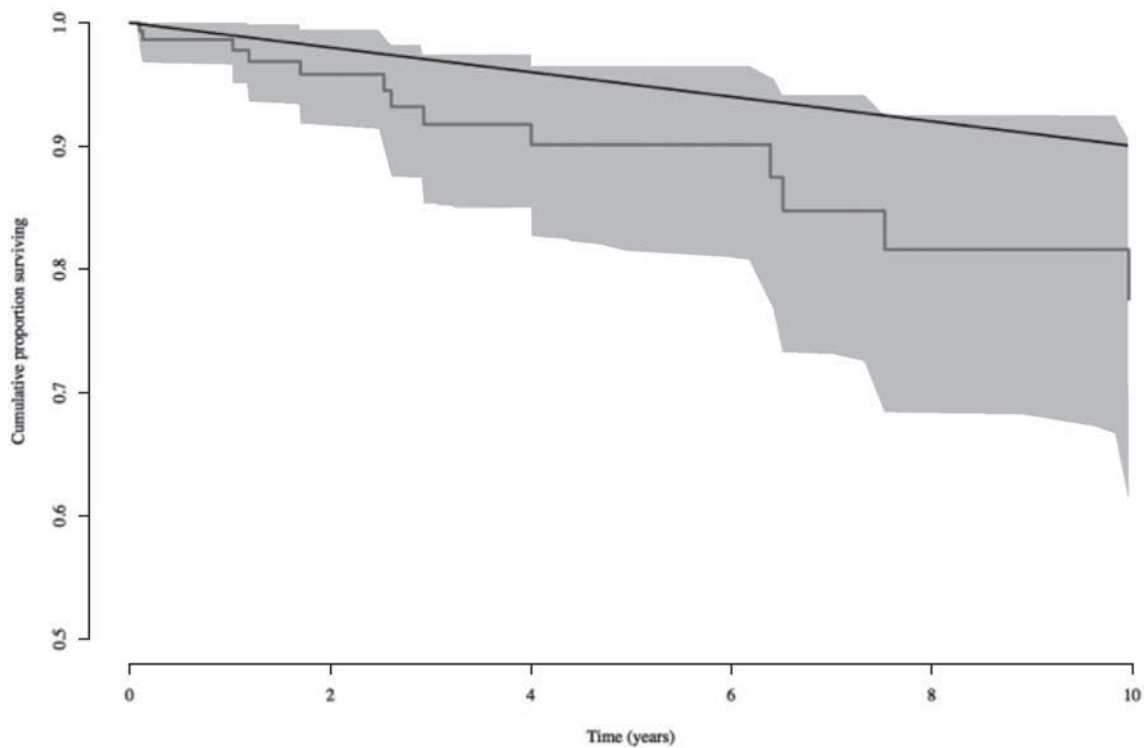


Fig. 3. — Kaplan – Meier analysis for resurfacings. The red line is the cumulative survival curve with the 95% confidence limits shaded in pink. The black line represents the NICE guidelines for hip arthroplasty survivorship.

reported 7 failures in 30 patients with THR under the age of 28 with a mean follow-up of 6.9 years (11). We found that hip resurfacing as well as having favourable survivorship in this age group, conferred the added benefit of a larger head size and reduced dislocation rate - important in those patients with neuromuscular disease.

Reito *et al* (13) reports a resurfacing survivorship of 90.5% in under 40's at 7 years, however most patients in this group had "primary" osteoarthritis or AVN as their primary pathologies and may pose less of a surgical challenge. Most revisions in their cohort were thought to relate to ARMD. Sayeed *et al* reported a small series of resurfacings in patients with AVN with no failures at 7.5 years (14). Amstutz *et al* published results of resurfacing in dysplastic patients, with around a 90% survival at 6 years. In his series, in contrast to our own, all failures were on the femoral side (1). Amstutz published a further small series of patients with resurfacing for childhood hip disorders. There was a 92% survivorship

at 4.7 years, with femoral component failure again being the cause. Woon *et al* (17) reported the results of 53 resurfacings for a range of pathologies in patients under 30 years, reporting an 8-year survivorship of 95%.

The primary indication for resurfacing in this cohort was pain relief. Functional improvement was a secondary objective, although our sub-cohort's Oxford hip score improved significantly. It was to be expected that these scores would significantly worse compared to our institution's median score following resurfacing. Our patients' functional status and expectations after surgery varied greatly depending on the patient's syndrome or primary disease process. For example, patients with cerebral palsy seek pain relief and hip resurfacing also allows their personal hygiene needs and modest mobility to be met a great deal more easily. This is in contrast to a patient who is otherwise well but suffering from primary childhood hip pathology (eg DDH, Perthes' or SUFE). These patients seek pain relief but after a

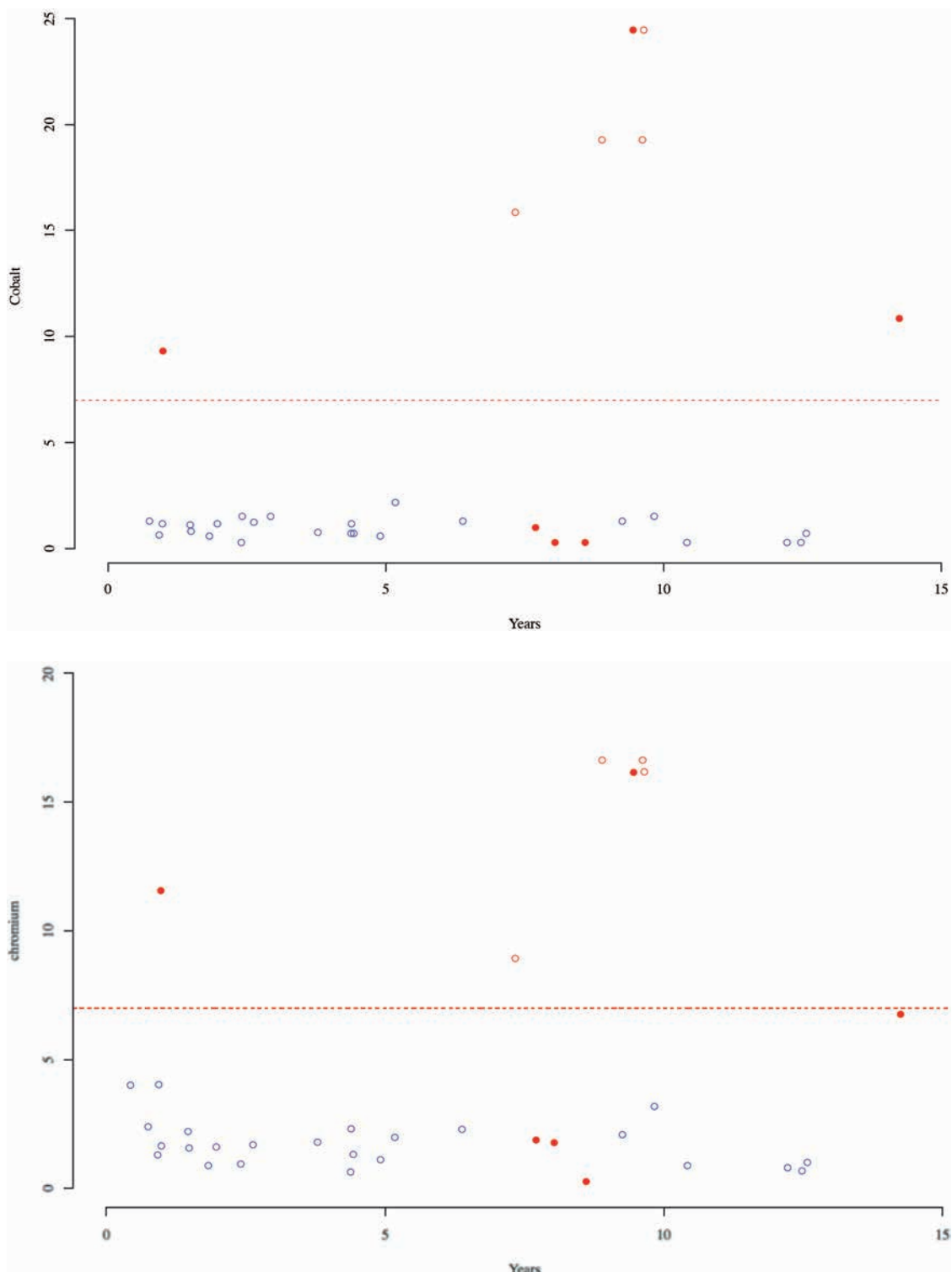


Fig. 4a & b — The time to maximum concentration of cobalt ions (Fig. 4a) and chromium ions (Fig. 4b) in whole blood from primary resurfacing. The blue symbols represent hips below the safe level and the red those above. The red filled symbols are revised hips. a. Cobalt ion levels post-operatively. b. Chromium ion levels post-operatively.

disabled childhood and adolescence, expect and deserve an entirely normal independent life in all its richness and variety.

The significance of raised metal ions remains a source of debate. Our senior author did not regard female sex as a contraindication for a resurfacing prosthesis. A transient rise following the 'run-in period' is usually followed by 'steady state' wear, and there may be a significant decrease at 10 years (16). There is debate as to the potential effects of raised metal ions on the developing foetus. A recent study reported that levels for cobalt and chromium in the umbilical cord were under a half and a quarter of those levels observed in maternal blood. All children in this study were born healthy (6).

In our cohort, 4 out of 8 patients with raised cobalt levels were revised. 2 out of 6 patients with raised chromium levels needed revision. We found no evidence of any macroscopic adverse reaction to metal debris however. In no cases did we find the revision operation significantly compromised by the primary surgery.

Femoral head sizes in our cohort were smaller than the 'optimum' for resurfacing as defined in previous studies. Cases of hip dislocation, dysplasia and cerebral palsy together made up 58% of our cases. All of these will necessarily have had smaller than average femoral heads. Although patients with cerebral palsy may not have high expectations, patients with dislocation or dysplasia do. We are not convinced that smaller femoral heads are as important a cause of failure as claimed. Inadvertent downsizing (a particularly easy mistake in females) resulting in a loss of motion and painful impingement in full flexion or abduction is a more likely explanation.

There are several limitations to our study. Follow-up cobalt and chromium levels were only measured on a small proportion of patients and we cannot speculate about the remaining cohort. Overall, our neuromuscular patient population would be expected to be less active. Despite reduced hip cycles however, abnormal wear patterns may have occurred as a result of abnormal force vectors and subclinical episodes of hip subluxation leading to increased wear. In the neuromuscular patients, functional limitations necessitated pain relief as being

the sole surgical goal. Oxford scores were not valid in neuromuscular patients and were only measured on a selected group of 53 patients, where it was deemed a valid measure of functional outcome.

For many surgeons, the indications for hip resurfacing have been narrowed due to literature reporting poor outcomes in certain patient groups and the presence of ARMD. We report the largest single surgeon series of resurfacing hip arthroplasty in the under 30's for childhood hip disorders. Despite a challenging cohort of patients, we have shown that hip resurfacing remains an effective treatment option with good survivorship and functional outcome in the medium-term. Resurfacing should form part of the armamentarium of the arthroplasty surgeon when faced with a degenerative hip in a young adult.

REFERENCES

1. **Amstutz HC, Su EP, Le Duff MJ.** Surface arthroplasty in young patients with hip arthritis secondary to childhood disorders. *Orthop Clin North Am* 2005 ; 36 (2) : 223-30.
2. **Amstutz HC, Ball ST, Le Duff MJ, Dorey FJ.** Resurfacing THA for patients younger than 50 year : results of 2- to 9-year followup. *Clin Orthop Relat Res* 2007 ; 460 : 159-64.
3. **Amstutz HC, Le Duff MJ, Harvey N.** Improved survivorship of hybrid metal-on-metal hip resurfacing with second-generation techniques for Crowe-I and II developmental dysplasia of the hip. *J Bone Joint Surg Am* 2008 ; 90 Suppl 3 : 12-20.
4. **Coulter G, Young DA, Dalziel RE Shimmin AJ.** Birmingham hip resurfacing at a mean of ten years : results from an independent centre. *J Bone Joint Surg Br* 2012 ; 94 (3) : 315-21.
5. **Daurka JS, Malik AK, Robin DA, Witt JD.** The results of uncemented total hip replacement in children with juvenile idiopathic arthritis at ten years. *J Bone Joint Surg Br* 2012 ; 94 (12) : 1618-24.
6. **DeSouza RM, Wallace D, Costa ML, Krikler SJ.** Transplacental passage of metal ions in women with hip resurfacing : no teratogenic effects observed. *Hip Int* 2012 ; 22 (1) : 96-9.
7. **Gross TP, Liu F.** Prevalence of dysplasia as the source of worse outcomes in young female patients after hip resurfacing arthroplasty. *Int Orthop* 2012 ; 36 (1) : 27-34.
8. **Malek IA, King A, Sharma H et al.** The sensitivity, specificity and predictive values of raised plasma metal ion levels in the diagnosis of adverse reaction to metal debris in symptomatic patients with a metal-on-metal arthroplasty of the hip. *J Bone Joint Surg Br* 2012 ; 94 (8) : 1045-50.

9. **McBryde CW, Thievendran K, Thomas AM et al.** The influence of head size and sex on the outcome of Birmingham hip resurfacing. *J Bone Joint Surg Am* 2010 ; 92 (1) : 105-12.
10. **Pattyn C, De Smet KA.** Primary ceramic-on-ceramic total hip replacement versus metal-on-metal hip resurfacing in young active patients. *Orthopaedics* 2008 ; 31 (11) : 1078.
11. **Pruszczynski B, Sibinski M, Synder M.** Outcomes of hip arthroplasty in patients younger than 28 years old. *Ortop Traumatol Rehabil* 2011 ; 13 (3) : 261-9.
12. **Pynsent PB, Adams DJ, Disney SP.** The Oxford hip and knee outcome questionnaires for arthroplasty. *J Bone Joint Surg Br* 2005 ; 87 (2) : 241-8.
13. **Reito A, Eskelinen A, Puolakka T, Pajamaki J.** Results of metal-on-metal hip resurfacing in patients 40 years old and younger. *Arch Orthop Trauma Surg* 2013 ; 133 (2) : 267-73.
14. **Sayed SA, Johnson AJ, Stroh DA et al.** Hip resurfacing in patients who have osteonecrosis and are 25 years or under. *Clin Orthop Relat Res* 2011 ; 469 (6) : 1582-8.
15. **Treacy RB, McBryde CW, Shears E, Pynsent PB.** Birmingham hip resurfacing : a minimum follow-up of ten years. *J Bone Joint Surg Br* 2011 ; 93 (1) : 27-33.
16. **Van Der Straten C, Van Quickenborne D, De Roest B et al.** Metal ion levels from well-functioning Birmingham Hip Resurfacings decline significantly at ten years. *Bone Joint J* 2013 ; 95-B (1) : 1332-812.
17. **Woon RP, Johnson AJ, Amstutz HC.** The Results of metal-on-metal hip resurfacing in patients under 30 years of age. *J Arthroplasty* 2013 ; 28 (6) : 1010-4.
18. **No authors listed.** Image J : Image Processing and Analysis in Java. <http://www.rsb.info.nih.gov>.
19. **No authors listed.** Medical Device Alert : Metal-on-metal (MoM) total hip replacements (MDA/2012/016). <http://www.mhra.gov.uk>. (Date last accessed 2nd April 2012).