



A novel freehand method for patellar resurfacing in total knee replacement

Angelos ASSIOTIS, Stephen NG MAN SUN, Simon MORDECAI, John HOLLINGDALE

From Trauma and Orthopaedics Department, Central Middlesex Hospital, London

Patellar resurfacing in the context of primary total knee replacement (TKR) and in the presence of patella-femoral osteoarthritis is common and widespread practice, as it reduces the rate of re-operation and anterior knee pain.

There are several measuring devices and cutting jigs available in the market, which aim to aid with accurately resecting the patellar articular surface. A common characteristic of these jigs is that the patella needs to be everted at some stage to apply them and use them. The senior author of this paper has developed a method of performing patellar resection with the use of simple instruments with no need to evert it and while it engages the trochlea in a physiological position. We propose that this method is reproducible and produces cuts that are parallel to the trochlea.

INTRODUCTION

Patellar resurfacing, in the context of total knee replacement (TKR), has been subject to controversy for several years (2-4,17) with some authors supporting routine resurfacing, others supporting routinely not resurfacing the patella and a third group being proponents of selective resurfacing as required. Although large studies have shown similar functional outcomes and pain levels between the resurfaced and non-resurfaced groups, critics of these studies suggest that they included older implants that are no longer in use (5,8). Evidence has emerged that resurfacing reduces anterior knee pain (15) and the rate of

re-operation after TKR (11,16). Manufacturers have developed several cutting jigs in order to ensure accurate resection of the patellar articular surface. At the same time, other freehand techniques have been described in the literature using various methods (7,14,18). We describe a reproducible freehand method of performing the patellar resection that allows for an accurate cut. Furthermore, the patella resection plane is parallel to the trochlea, something that may be difficult to achieve with various cutting jigs and something that may lead to post-operative lateral patellar tilt, especially when such a tilt was present pre-operatively (9). Lastly, our proposed method avoids eversion of the patella, which is considered to be a form of minimally invasive surgery (MIS) in TKR and has been clearly shown to reduce blood flow to the patella (12,13,19).

-
- Angelos Assiotis, MBBS, MRCS, MSc.
 - Stephen Ng Man Sun, MBBS, MRCS.
 - John Hollingdale, MBBS, FRCS (Orth).
Trauma and Orthopaedics SpR, Central Middlesex Hospital, London.
 - Simon Mordecai, MBBS, MRCS.
Trauma and Orthopaedics SpR, Hillingdon Hospital, London.
- Correspondence : Angelos Assiotis, Trauma and Orthopaedics SpR, Central Middlesex Hospital, London.
E-mail : aassiotis9@hotmail.com
© 2015, Acta Orthopædica Belgica.
-

No benefits or funds were received in support of this study. The authors report no conflict of interests. This study was carried out at Central Middlesex Hospital, London.

SURGICAL TECHNIQUE

Patients are usually given a general anaesthetic and are placed in the supine position with a tourniquet applied in the proximal thigh. A foot support that allows support of the lower limb in varying degrees of knee flexion is applied before preparing and draping the skin. The approach used is a medial para-patellar approach through a midline skin incision. The infra-patellar fat pad is preserved as much as possible, in order to preserve blood flow to the patella.

The tibial and femoral cuts are performed as usual and the same applies for any soft tissue releases in order to correct possible fixed deformities. During these steps, the patella is retracted laterally with the use of a small Hohmann retractor with avoidance of extensive tension, in order to preserve blood flow and avoid injuring the extensor mechanism.

After the femoral and tibial cuts have been performed and the appropriate size has been selected for all implants, the femoral trial implant is inserted and the knee flexed at 30°, which is the angle in which the patella starts engaging the trochlea. Patellar thickness is measured as usual with flat-tipped calipers and the level of resection marked along the long axis of the bone with diathermy. Resection is no more than one third of the maximum thickness (*l*) of the patella in order to avoid post-operative complications such as patella fracture. This usually means that at least 14-15 mm of patella is present after completion of the resection. A metal ruler is inserted between the distal femur and femoral trial and this will be parallel to the newly resurfaced patello-femoral joint. The patella is not everted; instead, it's stabilised in the trochlea with two towel clips by the assistant and the resection carefully performed with an oscillating saw at the marked level, with the blade always kept parallel to the ruler (Fig. 1). The patella is prepared as normal thereafter with minimal eversion in order to insert the actual implant and tracking is checked both with the trial implant and after the actual implant has been inserted.

The superficial and deep tissues, including the capsule, are then infiltrated with a mixture of normal saline, ropivacaine, adrenaline and ketorolac, as

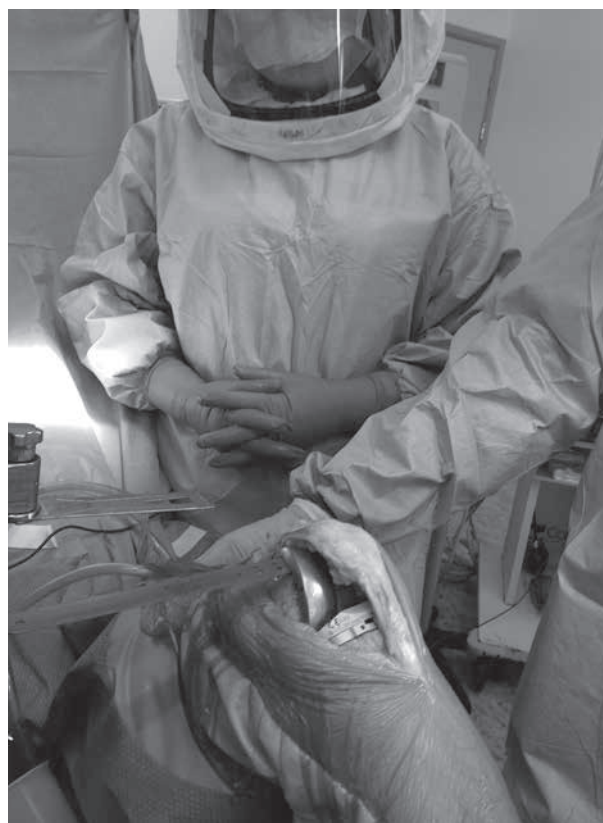

Fig. 1. — Patellar thickness has been marked with diathermy and the ruler is placed on the anterior chamfer cut. The saw is lined up parallel to the ruler in order for the resection plane to be parallel to that of the trochlea.

part of the local enhanced recovery protocol. This is followed by closure of the capsule and medial parapatellar retinaculæ with the use of a heavy suture, followed by layered closure of the superficial tissues and the knee. A compression bandage is finally applied and maintained for the first 24 hours after surgery.

Patients are mobilised on the day of surgery and radiographs taken on day 1 after surgery (Fig. 2).

DISCUSSION

Patello-femoral complications post-TKR form a large percentage all post-TKR problems and these include anterior knee pain, extensor mechanism injuries and patella fractures (6). Although the debate between routine resurfacing and non-resurfacing of

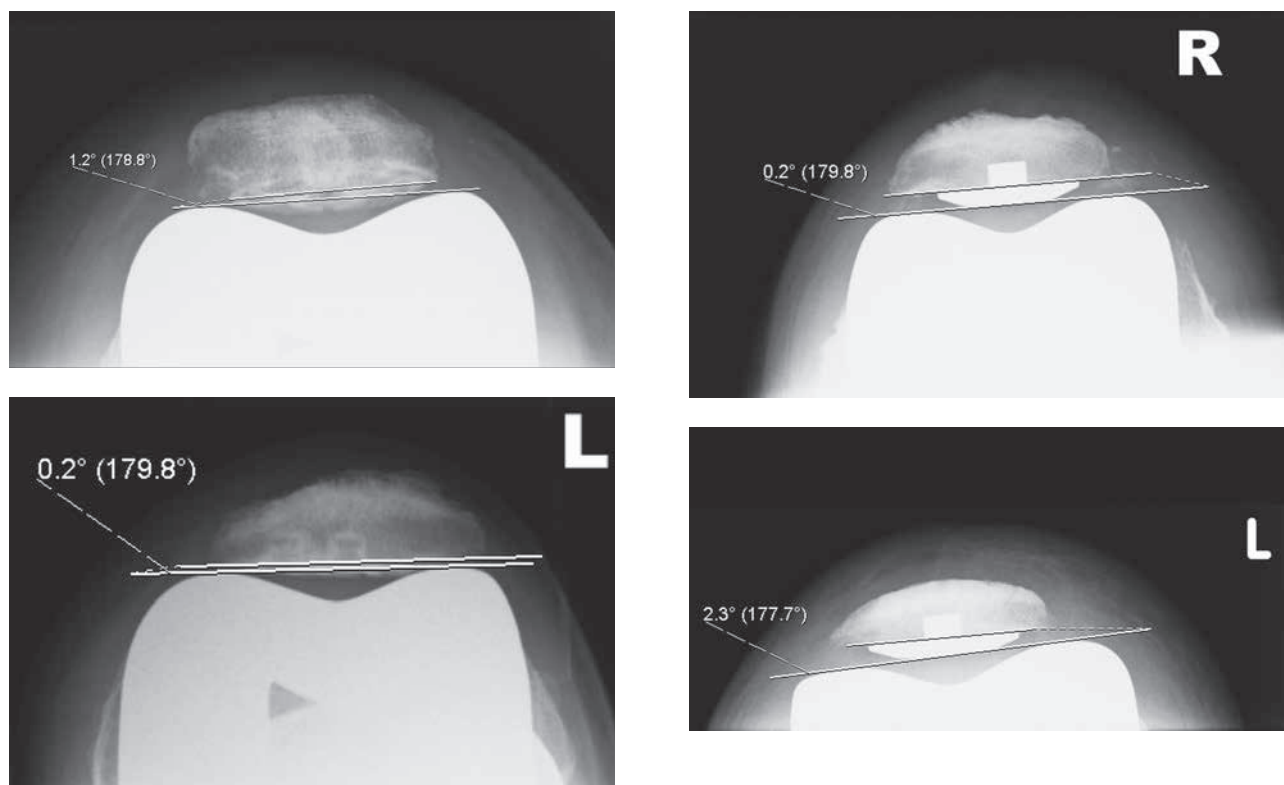


Fig. 2. — Series of radiographs demonstrating almost parallel patellar resection planes to the trochlea, with the use of the proposed method.

the patella in TKR is still ongoing, it seems that resurfacing conveys certain benefits in terms of reduced anterior knee pain and rate of re-operations. In our centre, knee surgeons routinely resurface the patella. Manufacturers offer a wide selection of implants and jigs that help resect and resurface the patella, but they share the characteristic that in order to apply these jigs, the patella needs to be everted and almost invariably, the cut is made in an arbitrary position of the patella.

Evidence shows that everting the patella almost invariably causes some degree of ischaemia to the bone, which in turn may lead to avascular necrosis and stress fractures of the patella (6). The degree of ischaemia has been quantified by authors such as Stoffel *et al* (19), who used in vivo Laser Doppler flowmetry and found that eversion reduced blood flow to the patella to 13% of baseline whereas lateral retraction reduced the flow to 53% of baseline

and this difference was significant. Similar findings were reported by Hempfing *et al* (13) and Hasegawa *et al* (12), who proposed a MIS approach of laterally retracting the patella as an alternative to the traditional practice of everting it.

With that in mind, several authors suggested a different approach to the matter, with gentle lateral retraction during TKR, in order to minimise ischaemia (10,19). In our centre, the standard practice is that of controlled lateral retraction of the patella during the preparation of the femur and tibia and insertion of implants, followed by the described method of patellar resurfacing. Other authors have described methods of resurfacing the patella, using a freehand technique. Camp *et al* (7) use calipers to measure the thickness, followed by an initial cut in eversion. They then divide the patella in four quadrants and finely adjust the resection thickness to the desirable level. Lombardi *et al* (14) described

a freehand method of resecting the patella in eversion by using the insertions of the quadriceps and patellar tendons as reference landmarks. Shakespeare and Dikko (18) utilised an extra-medullary tibial cutting jig to make the patellar resection, reporting good results. We describe a new reproducible technique for patellar resection that does not depend on jigs and may be performed simply with the use of calipers, a ruler and a saw, regardless of the set used for the TKR. Avoiding patellar eversion reduces ischaemia significantly the resection is made in the plane of the resurfaced patella-femoral joint with the patella engaging the trochlea.

REFERENCES

1. **Baldwin JL, House CK.** Anatomic dimensions of the patella measured during total knee arthroplasty. *J Arthroplasty* 2005 ; 20 : 250-257.
2. **Barrack RL, Bertot AJ, Wolfe MW et al.** Patellar resurfacing in total knee arthroplasty. A prospective, randomized, double-blind study with five to seven years of follow-up. *J Bone Joint Surg* 2001 ; 83-A : 1376-1381.
3. **Beaupre L, Secretan C, Johnston DW, Lavoie G.** A randomized controlled trial comparing patellar retention versus patellar resurfacing in primary total knee arthroplasty : 5-10 year follow-up. *BMC Res Notes* 2012 ; 5 : 273.
4. **Bourne RB, Burnett RS.** The consequences of not resurfacing the patella. *Clin Orthop Relat Res* 2004 ; 428 : 166-169.
5. **Bourne RB.** To resurface the patella or not ? Better assessments needed to address the benefits for total knee replacement : commentary on an article by George Pavlou et al. : "Patellar resurfacing in total knee arthroplasty : does design matter ? A meta-analysis of 7075 cases". *J Bone Joint Surg* 2011 ; 93-A : e82.
6. **Brick GW, Scott RD.** Blood supply to the patella. Significance in total knee arthroplasty. *J Arthroplasty* 1989 ; 4 Suppl : S75-79.
7. **Camp CL, Bryan AJ, Walker JA, Trousdale RT.** Surgical technique for symmetric patellar resurfacing during total knee arthroplasty. *J Knee Surg* 2013 ; 26 : 281-284.
8. **Campbell DG, Duncan WW, Ashworth M et al.** Patellar resurfacing in total knee replacement : a ten-year randomised prospective trial. *J Bone Joint Surg* 2006 ; 88-B : 734-739.
9. **Chan KC, Gill GS.** Postoperative patellar tilt in total knee arthroplasty. *J Arthroplasty* 1999 ; 14 : 300-304.
10. **Dalury DF, Dennis DA.** Extensor mechanism problems following total knee replacement. *J Knee Surg* 2003 ; 16 : 118-122.
11. **Garneti N, Mahadeva D, Khalil A, McLaren CA.** Patellar resurfacing versus no resurfacing in Scorpio total knee arthroplasty. *J Knee Surg* 2008 ; 21 : 97-100.
12. **Hasegawa M, Kawamura G, Wakabayashi H, Sudo A, Uchida A.** Changes to patellar blood flow after minimally invasive total knee arthroplasty. *Knee Surg Sports Traumatol Arthrosc* 2009 ; 17 : 1195-1198.
13. **Hempfling A, Schoeniger R, Koch PP, Bischel O, Thomsen M.** Patellar blood flow during knee arthroplasty surgical exposure : Intraoperative monitoring by laser doppler flowmetry. *J Orthop Res* 2007 ; 25 : 1389-1394.
14. **Lombardi AV, Jr., Mallory TH, Maitino PD, Herrington SM, Kefauver CA.** Freehand resection of the patella in total knee arthroplasty referencing the attachments of the quadriceps tendon and patellar tendon. *J Arthroplasty* 1998 ; 13 : 788-792.
15. **Mayman D, Bourne RB, Rorabeck CH, Vaz M, Kramer J.** Resurfacing versus not resurfacing the patella in total knee arthroplasty : 8- to 10-year results. *J Arthroplasty* 2003 ; 18 : 541-545.
16. **Pakos EE, Ntzani EE, Trikalinos TA.** Patellar resurfacing in total knee arthroplasty. A meta-analysis. *J Bone Joint Surg* 2005 ; 87-A : 1438-1445.
17. **Pavlou G, Meyer C, Leonidou A, As-Sultany M, West R, Tsiridis E.** Patellar resurfacing in total knee arthroplasty : does design matter ? A meta-analysis of 7075 cases. *J Bone Joint Surg* 2011 ; 93-A : 1301-1309.
18. **Shakespeare D, Dikko B.** A simple precise technique for making the anterior cut in patellofemoral resurfacing. *Knee* 2005 ; 12 : 454-455.