

POPLITEAL ARTERY INJURIES ASSOCIATED WITH FRACTURES AND DISLOCATIONS ABOUT THE KNEE

M. SUBASI¹, O. CAKIR², C. KESEMENLI¹, H. ARSLAN¹, S. NECMIOGLU¹, N. EREN²

The authors present the results of a retrospective review of popliteal artery injuries associated with fractures and dislocations about the knee.

They treated 41 patients with popliteal artery injuries associated with either fractures about the knee or knee dislocations. Thirty-five of the patients were males, 6 females ; the mean age was 23 years. The delay before accessing the hospital was 17 hours (range : 3 hours to 10 days). Thirty-two fractures were open. Together with the vascular injury, 12 femoral fractures, 20 tibial and fibular fractures, 5 knee dislocations, 4 femoral + tibial fractures were identified. Twenty-three patients underwent external fixation, 8 internal fixation, 6 plaster cast immobilization, 4 minimal osteosynthesis and plaster cast immobilization. The arterial injury was treated by end-to-end anastomosis in 5 cases, saphenous vein anastomosis in 29 cases and thrombectomy in 7 cases. Nine patients were amputated.

Delay in surgery, blunt trauma, extensive soft tissue defect and bone fracture or dislocation, are associated with high amputation rate following popliteal artery injury. The influence of each of these factors alone on the amputation rate could not be evaluated in this study, as no statistically significant correlation could be demonstrated.

Keywords : popliteal artery trauma ; fracture ; dislocation.

Mots-clés : artère poplitée ; traumatisme ; fracture ; luxation.

INTRODUCTION

Popliteal artery injuries associated with bone injury result in high amputation rates. The amputa-

tion rate among patients treated with ligation was 72% in World War II. The amputation rate went down to 32% in the Korean War thanks to the development of vascular surgery techniques. A similar amputation rate was reported from the Vietnam War (17, 18). The amputation rate has decreased in cases of penetrating trauma, whereas it is still high following blunt trauma. Delayed treatment of the vascular lesion, extensive soft tissue damage associated with fractures and additional infection have been pinpointed as the factors contributing to the extremity loss (2, 9, 16). McCabe *et al.* (12), in a review of the literature, reported amputation rates of 8% for injuries caused by penetrating trauma and 38% for those caused by blunt trauma.

In this study, we have retrospectively reviewed the popliteal artery injuries associated with fractures and dislocations about the knee. The purpose was to evaluate the treatment outcomes and to identify the factors affecting success.

MATERIALS AND METHOD

Forty-one patients with popliteal artery injuries associated with bone injuries about the knee that were

¹ Department of Orthopaedic Surgery, University of Dicle, Diyarbakir, Turkey.

² Department of Thoracic and Cardiovascular Surgery, University of Dicle, Diyarbakir, Turkey.

Correspondence and reprints : Mehmet Subasi, Dicle University, Department of Orthopedic Surgery, Diyarbakir / Turkey. E-mail : msubasi@dicle.edu.tr.

treated between January 1985 and July 2000 were evaluated retrospectively in the department of orthopedics and trauma and the department of thoracic and cardiovascular surgery of Dicle University School of Medicine. Cases with popliteal artery injuries but without fracture or dislocation about the knee and cases that underwent primary amputation were excluded from the study. Thirty-five of the patients (85%) were males, six females (15%); the mean age was 23 years (3-65 years). The injury mechanism was a gunshot in 22 (54%) cases, a traffic accident in 12 (29%) cases and a fall from a height in seven (17%) cases (table I).

Table I. — Causes of injuries and number of amputations

Etiology	Number of Cases	Amputation (n = 9)	Rate (%)
Gunshot	22	3	13.6
Traffic accident	12	4	33.3
Fall from a height	7	2	28.6

The delay before reaching the hospital was 0 to 8 hours for 32 patients, 9 to 12 hours for three, 13 to 24 hours for two and over 24 hours for four patients. The overall delay before reaching the hospital was 17 hours (3 hours to 10 days). Nine patients were referred to the hospital after 8 hours or more. Thirty-two fractures (78%) were open (1 type I, 9 type II, 16 type IIIA, 4 type IIIB, 2 type IIIC). Bleeding, pulselessness, expandable and pulsatile hematoma or distal ischemia were considered to be indications for vascular surgery. In addition to physical examination, Doppler ultrasonography was used routinely for diagnosis. Single-shot preoperative angiography was performed in six cases in whom the vascular injury site could not be definitely localized. The fracture site was identified by xray. The anticoagulant treatment was initiated in the emergency room for cases in which systemic anticoagulation was not contraindicated (active hemorrhage, coagulopathy, and craniocerebral injury). Concomitant to the vascular injury, 12 femoral fractures (29%), 20 tibial and fibular fractures (49%), 5 knee dislocations (12%), 4 femoral plus tibial fractures (10%), 1 peroneal nerve neurapraxia type injury (2%) and 4 tibial nerve injuries (10%) were identified. Twenty-two of the patients (54%) had only arterial injury, 19 (46%) had the arterial injury associated with popliteal vein injury. Three patients (7%) had intraabdominal injuries which required laparotomy, four patients (10%) had head trauma, and two (5%) had hemopneumothorax.

The patients underwent surgery under general anesthesia. After hemodynamic stabilization, irrigation and debridement were performed on cases with open fractures. The injured artery was found and an umbilical or silicone rubber tape was passed around it. A Fogarty catheter was passed gently, both proximal and distal to the arterial injury, to remove any intraluminal thrombus. Both proximal and distal arterial lumens were flushed with heparinized saline solution. All the cases received 100 U/kg heparin intravenously during operation. Tetanus prophylaxis and antibiotics were administered in all the cases. Low molecular weight dextran (500 ml/day) and systemic anticoagulant treatment (heparin 25,000 U/day) were administered to all patients for one day postoperatively and for 3 days in cases with delayed treatment. Rates of risk were evaluated using a software program called Statistical Package for Social Science 9.0 (SPSS for Windows. SPSS Inc., Chicago).

RESULTS

Treatment of the skeletal lesion was performed first in seven patients who did not have severe ischemia and in whom it was thought that the vascular repair could be damaged during bone fixation (fig. 1) and also in 5 cases with knee dislocation; vascular repair was done after stabilization of the skeleton (fig. 2). Twenty-three patients (56%) underwent external fixation, 8 (19%) open reduction and plate internal fixation, 6 (15%) plaster, cast immobilization and following minimal osteosynthesis in another 4 (10%) (table II).

The most commonly used surgical technique for arterial reconstruction was saphenous vein graft interpositioning. Primary arterial repair was used in 5 cases (12%), in which both ends of the vessel could be easily mobilized and primarily sutured without tension. Twenty-nine arteries (71%) were not suitable for primary repair and were treated by graft interpositioning. The saphenous vein was used as an interpositioning graft in all these 29 arteries. A PTFE (Polytetrafluoroethylene, Gore-Tex) synthetic graft was used instead of a saphenous vein for only one (2%) in a reoperation owing to thrombosis of the saphenous vein graft used initially. The injury was located at the popliteal artery trifurcation site in 8 (20%) cases that underwent saphenous vein interpositioning.

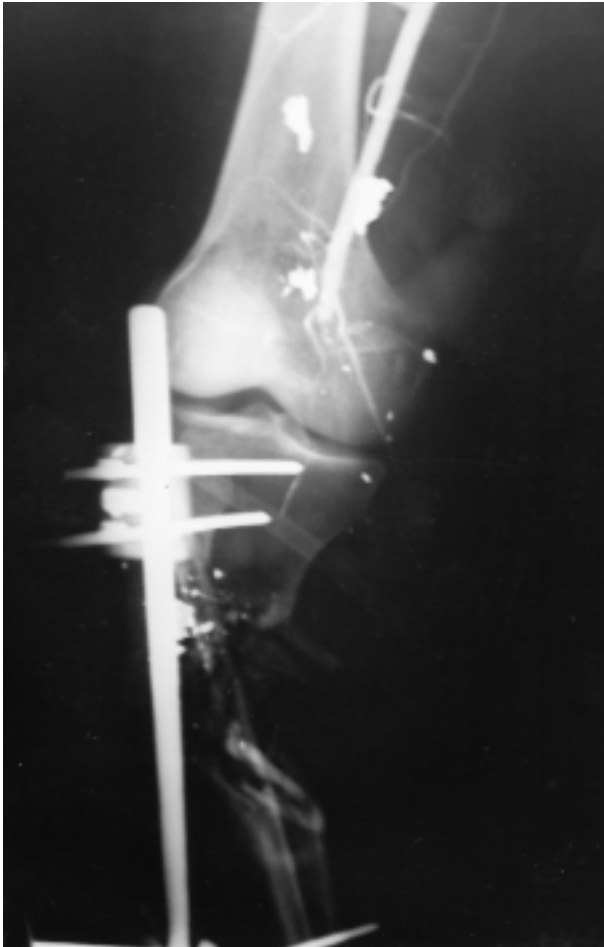


Fig. 1. — Gunshot injury of popliteal artery with tibial fracture.

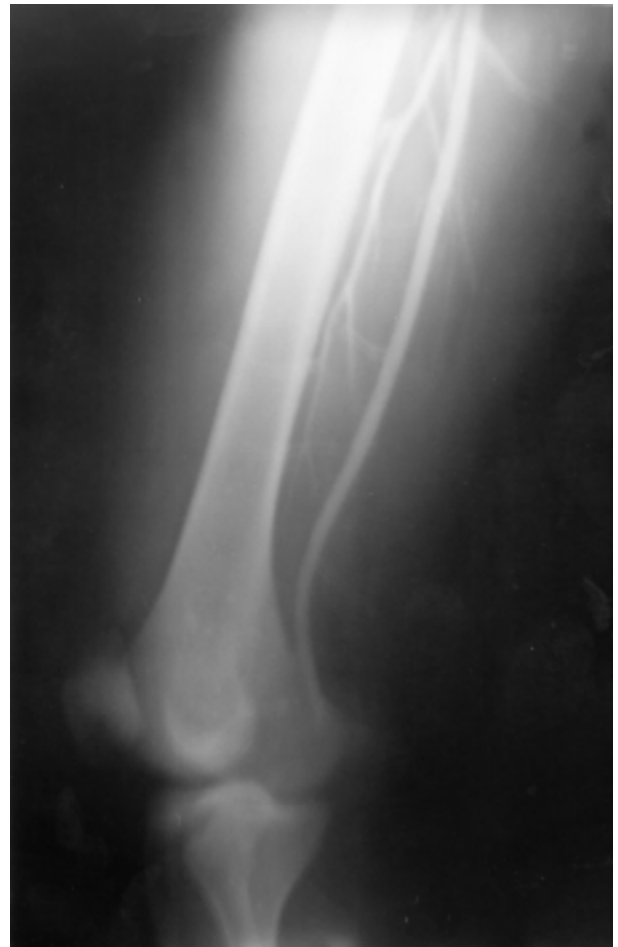

Fig. 2. — Popliteal artery injury after a knee dislocation (xray after closed reduction).

Table II. — Skeletal injuries and treatment methods

Localization	n	External Fix.	ORIF	Plaster + Min.O.	Plaster cast	Amputation
Femur fracture	12	8	0	3	1	3
Tibia fracture	20	13	6	1	0	4
Femur and tibia fractures	4	2	2	0	0	2
Knee dislocation	5	0	0	0	5	0
Total	41	23	8	4	6	9

Min. O. : Minimal osteosynthesis.

Fix. : Fixation.

ORIF : Open reduction and internal fixation.

These cases were treated by saphenous vein interpositioning between the popliteal artery and the posterior tibial artery ; the anterior tibial artery was ligated. Arterial repair was performed by thrombectomy in 7 patients (17%) (table III) ; arterial thrombosis recurred in two of these patients. During reoperation, intimal damage, which had not been seen at in the first operation, was identified in one of these cases. This site was resected and saphenous vein interpositioning was performed. The other case was a late referral (48 hours) ; amputation was performed as a result of recurring thrombosis (table III).

Table III. — Treatment of arterial injury methods and amputation

Treatment method	N	Amputation	Rate(%)
Saphenous vein interposition	29	8	27.5
End-to-end anastomosis	5	0	0.0
Thrombectomy	7	1	14.3
Total	132	9	

All of the popliteal vein injuries accompanying the arterial injury were repaired. Ligation was not performed in any of the cases. The surgical techniques for vein repair were saphenous vein graft interpositioning in 11 cases (58%), end-to-end anastomosis in 6 cases (32%) and lateral suture in 2 cases (10%). None of the cases underwent primary nerve repair. Fasciotomy of the four compartments of the leg, using two skin incisions, was performed intraoperatively (immediately after arterial repair) in 4 patients and postoperatively in 6 patients because of suspected compartment syndrome based on clinical findings or elevated compartment pressures. The amputation rate for the cases that underwent fasciotomy was 33%. Such cases were kept under systemic anticoagulation with heparin until the signs of ischemia improved, and at the same time they were administered 20% mannitol (400 cc/day) to decrease tissue edema. Six patients with extensive soft tissue injury were treated in cooperation with the plastic surgeon.

The mean hospitalization period was 9 (8-20) days. Four cases (10%) had early postoperative wound infection. They were treated with the appropriate antibiotherapy and wound debridement.

Nine patients (22%), one female and eight males, underwent amputation. The amputation level was above the knee in five cases, below the knee in three cases and through the Lisfranc joint in one case. Five (56%) of these cases were late referrals, three with 9 to 12 hours of delay and two more than 24 hours. The mean referral period was 34 hours (9 hours to 96 hours). The lesion resulted from traffic accidents in four patients (45%), gunshot wounds in three (33%), and from a fall from a height in two (22%). The mean age was 23 years (7 to 44 years). The other injuries associated with the arterial injury were : popliteal vein injury in 6 cases (67%), extensive soft tissue defect in one case and nerve injury in one case. The surgical technique used for the vascular lesion in these cases that were subsequently amputated were : saphenous vein interpositioning in 8 cases (89%) and thrombectomy in one case (11%). One case that was treated by saphenous vein graft interpositioning underwent PTFE (Gore-Tex) graft interpositioning during a reoperation which was made necessary by graft thrombosis. This patient underwent amputation as a result of necrosis caused by recurrent graft thrombosis. The associated fractures in amputated cases were femoral fractures in 3 cases, tibial and fibular fractures in 4 and combined femoral and tibial fractures in 2 cases. For the treatment of fractures, minimal osteosynthesis followed by plaster cast immobilization had been applied to 2 cases, internal fixation to 3 cases and external fixation to 4 cases (table I, II, III). The type of treatment of the fracture, late referral or type of trauma did not each alone have a statistically significant effect on the amputation rate.

A 3-year-old boy who was referred 24 hours after the trauma had associated head trauma. He died because of the head trauma. The mortality rate for the whole group was 2%.

The majority of the limb-salvage group had a good outcome : 25 patients (78%) had a useful and functional limb following repair and were generally pleased with the result. Complications also in-

cluded peroneal nerve palsy in one patient who recovered completely, and tibial nerve injury in four patients. One of these four patients also had femur and tibia fractures and was amputated. Disrupted nerves were sutured in another three patients. One of these three patients recovered partially and benefited from muscle tendon transfer surgery, allowing sufficient ankle strength and mobility to ambulate without a brace. In the remaining two patients peripheral nerve deficit has remained unchanged at 14 and 25 months. Among overall patients one had an infected femoral nonunion and another had tibial osteomyelitis. These two patients required multiple local procedures that resulted in a weakened leg. Another two patients had knee dislocations, and still another one had a comminuted femoral fracture, all leading to a stiff knee joint. Limited flexion of the knee was noted in all the patients with femoral fractures treated with external fixations, however these patients had at least 110° of knee flexion. Limb shortening of 2 cm occurred in two patients with femoral fractures due to gunshot injuries, who were ambulated without a brace.

DISCUSSION

The most common cause of vascular injuries in the extremities is penetrating trauma. Warfare, suicide attempts, attacks and alcohol and drug addiction are risk factors for penetrating vascular injuries. The second most common cause is blunt trauma including traffic accidents, falls from a height and crush injuries (23). The causes of vascular injuries differ in different parts of the world. In developed countries, especially in Northern European countries where violence is not common, the primary cause is blunt trauma. In the US, penetrating trauma is primarily caused by gunshots (2, 3, 11). Twenty-two of our cases (53%) had vascular injury associated with fracture as a result of gun-shot injuries. The most common cause of such injuries is terrorist activities in our region. Penetrating trauma is frequently observed among young and middle-aged males. The low age of our cases (mean age is 23) and the male predominance support this thesis. The demographic data of our cases are in line with the literature (2, 3, 4, 11).

It is necessary to stabilize the vital functions of a patient with a vascular injury. To this end, the airway must be protected, any bleeding should be stopped and blood and fluid deficits should be compensated. For a successful result in vascular injuries associated with fracture, it is of great importance to pursue the principles of early and accurate diagnosis, resuscitation, revascularization, and soft tissue preservation and fracture stabilization. Controlling bleeding in such patients is life-saving. Bleeding can generally be controlled by direct pressure on the bleeding site (digital pressure, compression dressing). It is of no use to place a clamp on the bleeding site in a blind fashion, as it may even damage the adjacent tissues. A tourniquet should be avoided, since it may decrease the collateral circulation (23).

Popliteal arterial injuries associated with bony injuries have a high amputation rate. Such injuries usually involve venous and soft tissue components. The rate of amputation decreased thanks to the developments in shock therapy, use of antibiotics, better bone stabilization by external fixators, treatment of bone defects by internal bone transport, soft tissue reconstruction such as local and free flap and rapid transportation. The amputation rate seems to be higher in blunt trauma than in penetrating trauma due to the fact that the former involves greater damage to the bone and soft tissue. In many series reporting open fracture, knee dislocation and prolonged ischemia, blunt trauma is associated with a high amputation rate (4, 9, 11, 13). Flint *et al.* (8) emphasized the importance of soft tissue loss in their series. Odland *et al.* (14) reported that shock and crush injuries are associated with a significant rate of amputation. In our patients 67% of those undergoing amputation were injured as a result of blunt trauma. High-energy gunshot injuries are associated with severe bone and soft tissue defects. The amputation rate is also high in such cases : it is 33% in our series.

Our patient who died had prolonged ischemia, a contaminated soft tissue injury and head trauma as a result of a mine explosion.

The success rate in delayed cases is low. Rapid diagnosis and surgery decrease the ischemia period and thus, the amputation rate. Physical examination

findings such as bleeding from a penetrating wound, pulsatile hematoma and absence of distal pulses are sufficient for the diagnosis of an arterial injury. In case of uncertain presence of distal pulses, especially in case of blunt trauma, angiography is necessary. Classical angiography leads to 1-2 hours of wasted time and may aggravate the severity of ischemia. Single-shot angiography in the operating room prevents such a waste of time (13, 16, 21). However, Bryan *et al.* (1) reported that the amputation rate was low in their patients who were referred in the first 24 hours, and that there was no correlation between delayed surgery and amputation rate in the first 24 hours. They underlined in their series that the most important determinant for amputation was the extent of soft tissue injury. We have determined the diagnosis in 6 of our cases by single-shot angiography. Fifty-six percent (5 cases) of the amputated cases had been referred late (mean delay : 34 hours). In 5 out of 9 patients, who were referred after more than eight hours, the treatment failed and amputation was required. However, a 35-year-old patient referred as a result of a gunshot injury underwent saphenous vein graft and arterial repair and fasciotomy after 10 days, and the result was successful.

It has been suggested that vascular repair should be performed before bone stabilization to decrease the period of ischemia (10, 11, 13, 16). However, since there is a risk of damaging the vascular structure during bone fixation, giving precedence to skeletal fixation in cases that have no severe ischemia and that are not delayed facilitates the vascular repair (11, 13, 16). Seven cases without severe ischemia but in whom the vascular repair might have been damaged during bone fixation and 5 cases with knee dislocation, that is, a total of 12 cases (29%), first underwent treatment of the bony lesion and then vascular repair. Bone fixation is provided by means of external fixation in order to decrease the infection rate and facilitate wound care in open fractures. In closed and stable fractures, internal fixation and in closed pediatric fractures, minimal osteosynthesis and plaster cast immobilization or casting alone suffices for treatment (1). External fixation was applied to 23 of our patients (56%), internal fixation to 8 (19%), plaster

casts to 6 (15%) and minimal osteosynthesis and plaster casts to 4 (10%) cases. Of the amputated patients, 4 were stabilized by external fixation, 3 by internal fixation and by 2 minimal osteosynthesis and plaster casting. The distribution of fractures in amputated patients is femoral fractures in 3 cases, tibial and fibular fractures in 4 cases and combined femoral and tibial fractures in 2 cases.

It is reported that primary repair, lateral suture, and end-to-end anastomosis yield the best results in popliteal arterial injuries and that the amputation rate in such patients is between 2 and 5% (5, 6, 11, 13, 15, 19). However, gunshot injuries and blunt trauma frequently require graft interpositioning. The amputation rate is about 20-25%. The high amputation rate following complex repair is probably related with the severity of trauma. Saphenous vein is preferable as the interpositioning graft. It is not common to use synthetic grafts for repairing the popliteal artery. However, in cases where the saphenous vein is not appropriate, PTFE grafts can be used, the long-term results of PTFE grafts are poorer than the results of saphenous vein in the popliteal position (5, 6, 11, 13, 15, 19). In our clinic, we used the saphenous vein (71%) for cases where end-to-end anastomosis was not possible for popliteal arterial repair. We used a synthetic graft for one case (2%) in a reoperation owing to the inefficacy of the previous saphenous graft. This case was amputated as a result of necrosis caused by repetitive thrombosis. In spite of a reoperation, one (14%) out of seven cases who underwent thrombectomy had to be amputated. The surgery failed in eight out of 29 cases who underwent saphenous vein grafting, and those were amputated. Five cases in whom end-to-end anastomosis was performed did not require amputation.

It is reported that arterial injury associated with venous injury increases amputation rate and that venous repair decreases the pressure in the compartment together with the venous pressure (20). However, some authors believe that venous repair is not important for extremity salvage and that there is no difference in results between vein ligation and repair (15, 22). All the popliteal vein injuries in our patients were repaired. Six (67%) out of nine

amputated patients had venous injury accompanying the arterial injury.

The edema developing after the reperfusion of the ischemic extremity may lead to compartment syndrome, resulting in microvascular thrombosis and muscular necrosis. Fasciotomy of all four compartments prevents such complications when performed early. Field *et al.* (7) reported that prophylactic fasciotomy performed on patients with ischemia for more than six hours or with arterial injury associated with venous injury was efficient for limb salvage. However, it is debatable whether to perform prophylactic fasciotomy before the compartment syndrome develops, because fasciotomy increases the infection rate and duration of hospitalization. If compartment syndrome develops in delayed cases, fasciotomy should be performed before vascular repair. It is claimed that this improves the collateral circulation and decreases ischemia during vascular repair. However, this operation was undertaken immediately after vascular repair in the reported series (11, 13). Fasciotomy was performed on four of our cases in the early period immediately after vascular repair and on six in the late postoperative period; that is, a total of 10 (24%) fasciotomies were performed. Systemic anticoagulant treatment with heparin was maintained in these cases until ischemic findings improved, and mannitol was administered to decrease edema.

Finally, delay in surgery, blunt trauma, extensive soft tissue defect and bone fracture or dislocation in popliteal arterial injuries are associated with a high amputation rate. The effect of each of these factors alone on increasing the amputation rate could not be determined in this study. Statistically significant correlations could not be found ($p > 0.05$). Upon evaluating the literature data and the results obtained from our cases, it has been concluded that the use of systemic anticoagulants, decreasing the severity of ischemia by fasciotomy, not wasting time with preoperative diagnostic tests, performing vascular repair before orthopedic repair in delayed cases and preoperative and postoperative debridement of necrotic tissue decrease the amputation risk.

REFERENCES

1. Bryan T., Merritt P., Hack B. Popliteal arterial injuries associated with fractures or dislocations about the knee as a result of blunt trauma. *Orthop. Rev.*, 1991, 20, 525-530.
2. Cargile J. S., Hunt J. L., Purdue G. F. Acute trauma of the femoral artery and vein. *J. Trauma.*, 1992, 32, 364-371.
3. Dolores F. C., Michael C. D., Benjamin J. B., Lalka S. G., Sawchuk A. P., Schulz J. E. An experience with upper-extremity vascular trauma. *Am. J. Surg.*, 1990, 160, 229-233.
4. Eren N., Özgen G., Gürel A., Ener B. K., Furtun K. Vascular injuries and amputation following limb fractures. *Thorac. Cardiovasc. Surg.*, 1990, 38, 48-50.
5. Feliciano D. V., Herskowitz K., O'Gorman R. B. Management of vascular injuries in the lower extremities. *J. Trauma.*, 1998, 28, 319-326.
6. Feliciano D. V., Mattox K. L., Graham J. M., Bitanto C. G. Five-year experience with PTFE grafts in vascular wounds. *J. Trauma.*, 1985, 25, 71-75.
7. Field C. K., Senkowsky J., Hollier L. H., Kwamme P., Saroyan R. M., Ri.Ce J. C., Rush D. S., Kerstein M. D. Fasciotomy in vascular trauma: Is it too much, too often? *Am. Surg.*, 1994, 60, 409-411.
8. Flint L. M., Richardson J. D. Arterial injuries with lower extremity fracture. *Surgery*, 1983, 93, 5-8.
9. Harrel D. J., Spain D. A., Bergamini T. M., Miller F. B., Richardson J. D. Blunt popliteal artery trauma: A challenging injury. *Am. Surg.*, 1997, 63, 228-232.
10. Lemaire R. Traitement des lésions ostéo-articulaires associées à des lésions vasculaires traumatiques. *Acta Chir. Belg.*, 1982, 82, 449-456.
11. Martin L. C., McKenney M. G., Sosa J. L., Ginzburg E., Puente I., Seeman D, Zeppa R. Management of lower extremity arterial trauma. *J. Trauma.*, 1994, 37, 591-599.
12. McCabe C. J., Ferguson C. M., Ottinger L. W. Improved limb salvage in popliteal artery injuries. *J. Trauma.*, 1983, 23, 982-985.
13. Melton S. M., Croce M. A., Patton J. H., Pritchard F. E., Minard G., Kudsk K. A., Fabrian T. C. Popliteal artery trauma systemic anticoagulation and intraoperative thrombolysis improves limb salvage. *Ann. Surg.*, 1997, 225, 518-529.
14. Odland M. D., Gisbert V. L., Gustilo R. B., Ney A. C., Blake D. P., Bubrick M. P. Combined orthopaedic and vascular injury in the lower extremities: Indications for amputation. *Surgery*, 1990, 108, 660-666.
15. Peck J. L., Eastman A. B., Bergan J. J., Sedwitz M. M., Hoyt D. B., McReynolds D. G. Popliteal vascular trauma: A community experience. *Arch. Surg.*, 1990, 125, 1339-1344.
16. Pretre R., Bruschweiler I., Rossier J., Chilcott M., Bednarkiewicz M., Kürsteiner K., Kalangos A., Hoffmeyer P., Faidutti B. Lower limb trauma with injury to the popliteal vessels. *J. Trauma.*, 1996, 40, 595-601.

17. Rich N. M., Spencer F. C. Vascular Trauma. W.B. Saunders, Philadelphia, 1978.
18. Rich N. M., Methz C. W., Hutton J. E., Baugh H. H., Hugues C. W. Internal versus external fixation of fractures with concomitant vascular injuries in Vietnam. J. Trauma., 1971, 11, 463-472.
19. Shah D. M., Leather R. P., Corson J. D., Karmody A. M. Polytetrafluoroethylene grafts in the rapid reconstruction of acute contaminated peripheral vascular injuries. Am. J. Surg., 1984, 148, 229-235.
20. Shah P. M., Wapnir I., Babu S., Shahl W. M., Clauss R. H. Compartment syndrome in combined arterial and venous injuries of the lower extremity. Am. J. Surg., 1989, 158, 136-141.
21. Solak H., Yeniterzi M., Yüksek T., Eren N., Ceran S., Goktogan T. Injuries of the peripheral arteries and their surgical treatment. Thorac. Cardiovasc. Surg., 1990, 38, 96-98.
22. Timberlake G. A., Kerstein M. D. Venous injury : To repair or ligate, the dilemma revisited. Am. Surg., 1995, 61, 139-145.
23. Weaver F. A., Hood D. B., Yelhin A. E. Vascular injuries of the extremities. In : Rutherford R. B. Vascular Surgery. Saunders, Philadelphia, 2000, pp. 862-871.

SAMENVATTING

M. SUBASI, O. CAKIR, C. KESEMENLI, H. ARSLAN, S. NECMIOGLU, N. EREN. Traumatische letsels van de arteria poplitea gepaard met fracturen en luxaties in de kniestreek.

Deze retrospectieve studie slaat op 41 patiënten, 35 mannen en 6 vrouwen, gemiddeld 23 jaar oud. Ze werden gemiddeld 17 uren na het ongeval opgenomen (uiterste waarden : 3 uren en 10 dagen). In 32 gevallen ging het om een open fractuur. Buiten het vaatletsel waren er 12 femurfracturen, 20 tibia- en fibulafracturen, 5 knieluxaties en 4 fracturen van zowel femur als tibia. Drieëntwintig patiënten werden behandeld met een uitwendige fixator, 8 met een osteosynthese, 6 met een gipsverband, en 4 met een minima osteosynthese plus gips. Het vaatletsel werd behandeld met een terminotenninale sutuur in 5 gevallen, met een greffe (v. saphena) in 29 gevallen, en met thrombectomie in 7 gevallen.

Negen maal bleek een amputatie nodig. Factoren die gepaard gaan met een hoog amputatiepercentage, na letsel van a. poplitea, zijn : laattijdige ingreep, contusies, uitgebreide weke delen letsels, en fracturen of luxaties. Het was onmogelijk de invloed van ieder van deze factoren na te gaan, aangezien een significante correlatie niet kon worden aangetoond.

RÉSUMÉ

M. SUBASI, O. CAKIR, C. KESEMENLI, H. ARSLAN, S. NECMIOGLU, N. EREN. Lésions traumatiques de l'artère poplitée associées à des fractures et luxations du genou.

Les auteurs présentent les résultats d'une étude rétrospective qui a porté sur les lésions traumatiques de l'artère poplitée associées à des fractures et luxations dans la région du genou. Ils ont traité 41 patients qui présentaient de telles lésions : 35 hommes et 6 femmes dont l'âge moyen était de 23 ans. Les patients ont été reçus à l'hôpital en moyenne 17 heures après le traumatisme (extrêmes : 3 heures et 10 jours). Trente-deux fractures étaient ouvertes. Outre la lésion vasculaire, on relevait 12 fractures du fémur, 20 fractures du tibia et du péroné, 5 luxations du genou et 4 fractures associées du fémur et du tibia. Vingt-trois patients ont été traités par fixateur externe, 8 par ostéosynthèse interne, 6 par immobilisation plâtrée et 4 par ostéosynthèse à minima suivie de plâtre. La lésion artérielle a été traitée par suture termino-terminale dans 5 cas, par interposition d'un greffon de veine saphène dans 29 cas et par thrombectomie simple dans 7 cas. Neuf patients ont été amputés.

Après lésion traumatique de l'artère poplitée, les facteurs qui sont associés à un taux d'amputation élevé sont la réalisation retardée du traitement chirurgical, les traumatismes par écrasement, les dégâts étendus des tissus mous, et l'existence de fractures ou luxations associées. Les auteurs n'ont pas pu évaluer dans cette étude l'influence de chacun de ces facteurs sur le taux d'amputation, car ils n'ont pas pu mettre en évidence de corrélation significative.