



## Analysis of sagittal balance using spinopelvic parameters in ankylosing spondylitis patients treated with vertebral column decancellation surgery

Bin LIN, Wen-Bin ZHANG, Tao-yi CAI, Cheng-Wu LU, Qin ZHOU, Zhuanzhi HUANG, Hui YU

*From the Department of Orthopaedics, 175th Hospital of PLA, Orthopaedics Center of PLA, Southeast Hospital of Xiamen University, Zhangzhou, Fujian Province, People's Republic of China*

This study was designed to explore the change of spinopelvic parameters after vertebral column decancellation (VCD) for the management of thoracolumbar kyphosis secondary to ankylosing spondylitis (AS). Forty-two AS patients including thirty-six males and six females with thoracolumbar kyphosis, who underwent VCD from April 2005 to June 2012 in our hospital, were retrospectively reviewed. A series of spinopelvic parameters including thoracic kyphosis (TK), lumbar lordosis (LL), sacral slope (SS), pelvic incidence (PI), pelvic tilt (PT) and sagittal vertical axis (SVA) measured on preoperative and postoperative free-standing radiographs were obtained and analyzed. Also clinical assessments were performed with the Oswestry disability index (ODI) and the Bath Ankylosing Spondylitis Activity and Function Index (BASDAI and BASFI) so as to seek correlations between radiological parameters and symptoms. Except for pelvic incidence (PI), significant difference was found in all radiological spinopelvic parameters between the preoperative and follow-up values. Furthermore, there was significant improvement in the clinical assessment parameters ODI, BASDAI and BASFI, which all correlated significantly with the postoperative pelvic tilt (PT). The results of this study show that posterior VCD is an effective option to manage sagittal imbalance in AS. In the current series, patients improving LL and PT were found to achieve good clinical outcomes. Overall, our findings show that it is important to quantify sagittal spinopelvic parameters and promote sagittal balance in the surgery for AS.

**Keywords** : ankylosing spondylitis ; sagittal balance ; vertebral column decancellation ; spinopelvic parameters.

### INTRODUCTION

Ankylosing spondylitis (AS) is a chronic inflammatory disease that primarily invades the spinal cord and sacroiliac joints and produces pain, stiffness and a progressive thoracolumbar kyphotic deformity (10). With the progression of spinal deformity, patients develop gait disturbance, difficulty in looking in the forward direction and disorders of

- Bin Lin, MD, PhD.
- Wen-Bin Zhang.
- Tao-yi Cai, MD.
- Cheng-Wu Lu, MD.
- Qin Zhou, MD.
- Zhuanzhi Huang, BS.
- Hui Yu, BS.

*Department of Orthopaedics, 175th Hospital of PLA, Orthopaedics Center of PLA, Southeast Hospital of Xiamen University, Zhangzhou, Fujian Province, People's Republic of China.*

Correspondence : Bin Lin, Department of Orthopaedics, 269 Zhanghua Road, Zhangzhou 363000, Fujian Province, People's Republic of China. E-mail : linbin813@163.com

© 2015, Acta Orthopædica Belgica.

digestive functions ascribed to the compression of abdominal organs (16).

The concept of sagittal balance has become an important item among spinal surgeons for evaluation and management of spinal disorders since 1985 (15). More recently, the importance of individual pelvic anatomy and assessment of pelvic parameters on sagittal balance are additionally emphasized. These pelvic parameters are correlated to the severity of spinal pathology and the clinical outcomes in AS patients after spinal surgery. Thereby, the treatment of AS has gradually focused upon the sagittal plane deformities of the patients. However, the correlation between the magnitude of regional kyphotic curves and patient-reported clinical outcomes remains undetermined (9).

A corrective osteotomy of fixed kyphosis is complicated surgery. It is thought to be very effective in patients with a long segment kyphosis who lose the compensation of sagittal imbalance. Vertebral column decancellation (VCD) is a new spinal osteotomy technique including multilevel vertebral decancellation, removal of residual disc, osteoclasts of the concave cortex, and compression of the convex cortex accompanied by posterior instrumentation with pedicle screws, reported initially by Wang Y (24).

Accordingly, the present study intends to explore the correlations of spinopelvic parameters with the clinical outcomes of AS patients after VCD surgery.

## MATERIALS AND METHODS

### Patients

A total of 42 AS patients (36 males and 6 females) were enrolled consecutively at the orthopedic clinic from April 2005 to June 2012 in our hospital. The mean age at surgery was 37.5 years (range, 21-54 years) and the mean duration of symptoms was 19.5 years (range, 3-36 years). All patients underwent a posterior one-stage VCD osteotomy of the thoracolumbar spine in our department. The medical records and radiographs of each patient were reviewed in detail. The enrolled patients were followed up for an average period of 4.7 years (range, 2-7 years) after surgery.

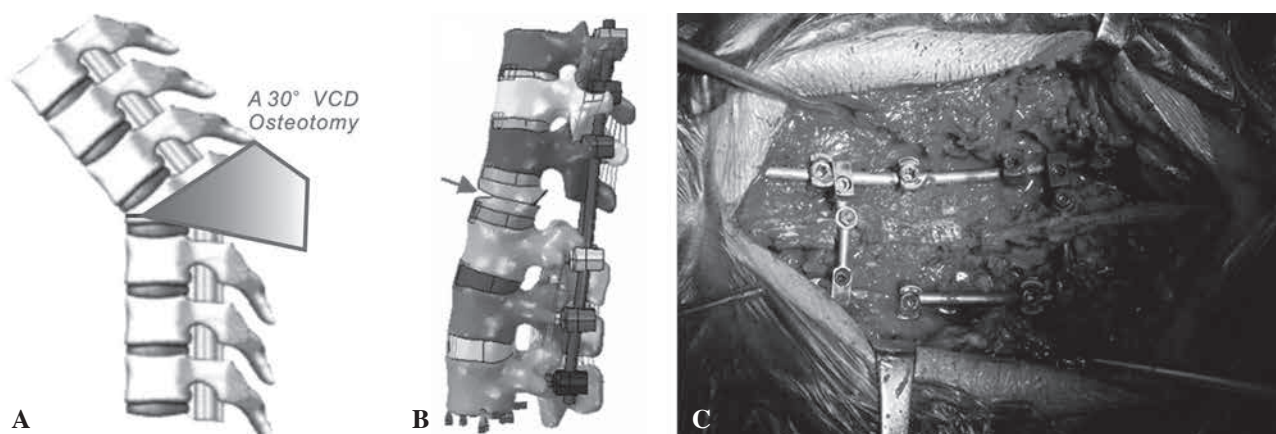
The diagnosis was confirmed based on the Modified New York Criteria for AS (22). Radiological assessment

revealed ossification of the spinal and interspinous ligaments (bamboo spine), as well as sclerosis of the sacroiliac joint and the capsule of the facet joints. Also loss of lumbar lordosis was evident. All patients had positive HLA-B27 and demonstrated an inability to look straight forward and see the horizon. They were also unable to lie down flat in bed with their heads touching the pillow because of gradually progressing extreme kyphotic deformity. These patients also presented obstacles in their routine activities owing to the compression of abdominal viscera and subsequent indigestion. Severe restriction of walking, driving, maintaining personal relationship in daily life due to disabled eye contact and kyphotic deformity, were considered the indications for surgical intervention.

The Bath Ankylosing Spondylitis Function Index (BASFI) (2) containing 10 items was completed before and 1 year after surgery to assess the physical functions and the constraint level of patients' daily lives (score range 0-10, 10 being the best score). The Bath Ankylosing Spondylitis Disease Activity Index (BASDAI) (8) composed of 6 items related to major symptoms was used to evaluate the status of the disease (score range 0-10, 10 being the worst score). The Oswestry disability index (ODI) (7) (range, 0-100%, 100% being the worst score) was evaluated pre- and post-operation and explained by the same surgeon.

### Surgical procedure

The patient was placed prone on a radiolucent table and the thoracolumbar junction was approached posteriorly. Somatosensory evoked potentials were used along the surgery. A standard skin incision was made in the midline, and subperiosteal dissection was performed to expose the bony structures of the posterior elements. All pedicle screws were inserted via a free hand pedicle screw placement technique (11). The VCD begun with the probe of the pedicle of the deformed vertebral body to be removed. Care was taken to preserve the exiting nerve root running along the medial and inferior surfaces of the pedicle. C-arm fluoroscopy confirmed the appropriate plane for the osteotomy. Then, a high-speed drill was used to enlarge the pedicle hole both cephalad and caudad until the corresponding walls were penetrated. An angular forceps or curette was used to remove the residual upper and lower cartilaginous endplates of the resected vertebra and intervertebral discs; then, a Kerrison rongeur or drill was used to thin the anterior and lateral walls of the vertebral body, which collapsed under pressure laterally to expose the posterior walls further.



**Fig. 1.** — Schematic representation of VCD osteotomy (A). The blue line segment ranging from 0.7 to 1 cm shows the tip of the osteotomy and the red zone shows the removed posterior elements along with the residual disc (B). Postoperative lateral view shows that the correction is achieved by elongating and opening (arrow) the anterior column and shortening the posterior column (C). Closure of the osteotomy site was achieved with direct bone-to-bone contact.

The posterior wall was resected with an angular forceps. After the vertebral bodies were decancellated, the posterior elements, including the spinous processes, laminae, facet joints, and transverse processes were removed (Fig. 1A). Osteoclasis of the anterior cortex of the vertebral body was achieved by gentle manual extension of the upper body and the lumbar spine to close the posterior wedge in combination with compressive forces on the adjacent pedicle screws, creating an anterior monosegmental intervertebral opening wedge or osteoclasis of the anterior cortex with elongation of the anterior column (Fig. 1B). In this way, closure of the osteotomy site was achieved with direct bone-to-bone contact (Fig. 1C).

### Radiographic measurement

All patients had pre and postoperative standing radiographs of the spine. A minor subgroup had an MRI scan performed, mostly because of suspicion of a narrowing of the spinal canal. The pre and postoperative radiographs were reviewed and the parameters reflecting pelvic morphology and fullspine curve in the sagittal plane were measured.

### Spinal parameters

As shown in Fig. 2A, the spinal parameters included T5-T12 thoracic kyphosis (TK), L1-S1 lumbar lordosis (LL), and sagittal vertical axis (SVA). Their definitions are listed as follow :

**TK** : the angle between the upper endplate of T5 and the lower endplate of T12 ;

**LL** : the angle between the superior endplate of T12 and S1 ;

**SVA** : the horizontal distance between the perpendicular line through C7 and the posterior corner of the sacrum.

### Pelvic parameters

As shown in Fig. 2B, the pelvic parameters included pelvic incidence (PI), pelvic tilt (PT), and sacral slope (SS).

The definitions are listed as follow :

**PI** : the angle between the perpendicular bisector of the S1 endplate and the line connecting the midpoint of the S1 upper endplate and the center of the femoral heads ;

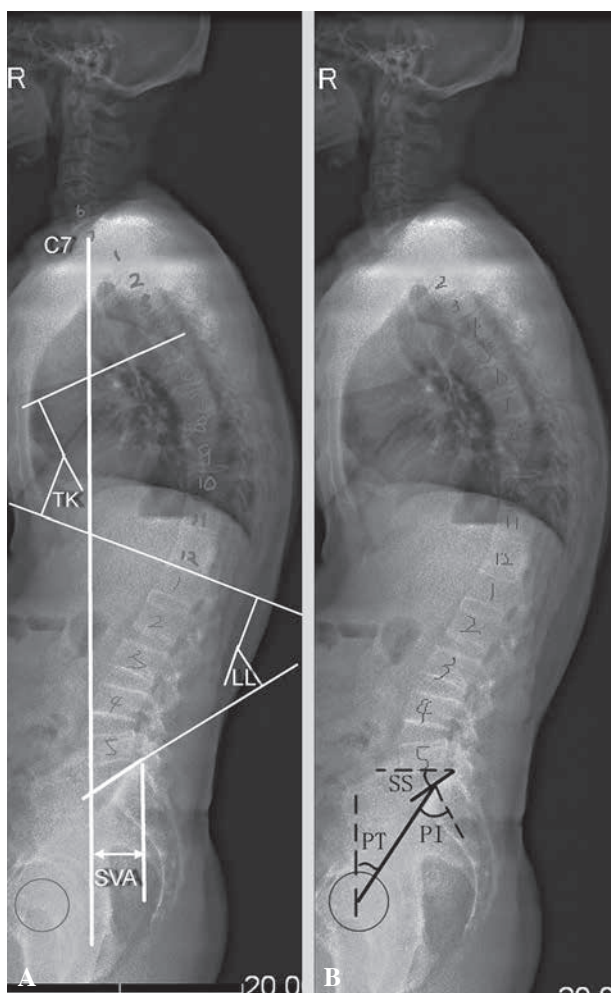
**PT** : the angle between the line connecting the midpoint of the S1 upper endplate and the center of the femoral heads and the perpendicular line ;

**SS** : the angle between the tangent of the S1 endplate and the horizontal line.

All measurements were performed by the same surgeon. Data were obtained as the average values of three measurements excluding those in blurred radiographs.

### Statistical analysis

Statistical analysis was conducted with SPSS 17.0 software for Windows (SPSS, Chicago, IL). To determine the powerful variables for the prediction of sagittal imbalance, logistic regression analysis was adopted.



**Fig. 2.** — Schematic diagram of parameters measured on the plain radiographs. (A) TK indicates the angle between the upper endplate of T5 and the lower endplate of T12 ; LL indicates the angle between the superior endplate of T12 and S1 ; SVA indicates the horizontal distance between the perpendicular line through C7 and the posterior corner of the sacrum. (B) PI indicates the angle between the perpendicular bisector of the S1 endplate and the line connecting the midpoint of the S1 upper endplate and the center of the femoral heads ; PT indicates the angle between the line connecting the midpoint of the S1 upper endplate and the center of the femoral heads and the perpendicular line ; SS indicates the angle between the tangent of the S1 endplate and the horizontal line.

Initially, univariate logistic regression was used to test the associations between variables estimated. After that, forward stepwise multiple logistic regression was used to develop a prediction model. The pre- and post-operative results were compared using the t-test and the correlation

analyses were performed using Pearson correlation to determine the relationship between variables. Data were expressed by mean  $\pm$  SD. A  $P < 0.05$  was regarded as statistically significant. Surgimap Spine software (Nemaris, Inc., New York, NY, USA) was used for computer simulations.

## RESULTS

A total of 36 men and 6 women who underwent a single-level lumbar VCD were included in this study (Fig. 3), and their average age was 37.5 (range 22-54 years). The mean duration of follow-up was 4.7 years (range 2-7 years). The most common sites of VCD were L2 ( $n = 23$ ), L1 ( $n = 12$ ) and L3 ( $n = 7$ ). The mean focal resection angle at the osteotomy site was  $36.8^\circ$  (SD =  $6.4^\circ$  ; range =  $39-50^\circ$ ).

### Radiological results

The radiological outcomes are shown in Table I. Except for PI, all radiological parameters (TK, LL, PT, SS, SVA), were significantly improved at the last follow-up visit compared to preoperative measurements ( $P < 0.05$ ).

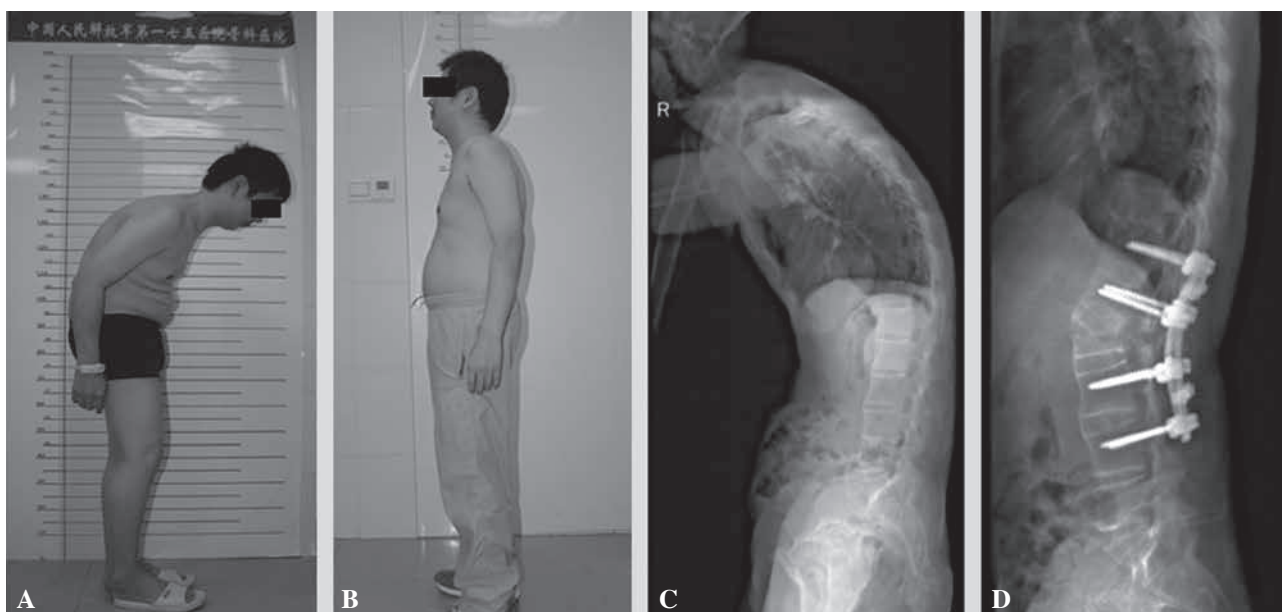
### Clinical assessments

The BASDAI score was improved significantly from an average of 5.3 points (range, 4.1-6.6) before surgery to 2.3 points (range, 0.4-6.1) at the last follow-up visit ( $p < 0.01$ ). The BASFI also significantly improved from 2.0 points (range, 1.0-4.0) before surgery compared to 5.7 points (range 3.0-8.5) after surgery ( $p < 0.01$ ). The average physical component summary score on the ODI was 65.8 points (range, 47.5-83.7) before operation and 39.6 points (range, 17.5-56.0) after operation, showing a significant improvement ( $p < 0.01$ ) (Table II).

### Correlations between the radiological and clinical evaluations

There were no significant correlation between the difference of lumbar lordosis angle before and after surgery and the BASFI score ( $p > 0.05$ ) ; the latter correlated significantly, however, with TK





**Fig. 3.** — (A) Preoperative lateral view of a 37-year-old patient with severe kyphotic deformity for 9 years. (B) Post-operative lateral view after single level VCD at L2. (C) Pre-operative standing lateral radiograph demonstrating the kyphotic deformity in the thoracolumbar and lumbar spine. (D) Post-operative standing lateral radiograph showing the correction of kyphotic deformity.

Table I. — Radiological assessments

	Pre-operation	Post-operation at last follow-up visit	<i>p</i> Value
Thoracic kyphosis (°)	49.6 ± 11.7	43.5 ± 9.2	< 0.01
Lumbar lordosis (°)	-1.8 ± 8.9	-36.9 ± 8.5	< 0.01
Pelvic incidence (°)	47.4 ± 9.3	46.3 ± 8.5	> 0.05
Pelvic tilt (°)	36.5 ± 7.6	24.8 ± 8.9	< 0.01
Sacral slope (°)	10.9 ± 9.4	21.5 ± 8.7	< 0.01
Sagittal vertical axis, mm	110.8 ± 30.7	39.7 ± 34.3	< 0.01

( $P < 0.05$ ). The correlation between SVA correction and BASFI score was significant ( $r = 0.510$ ,  $p < 0.05$ ). Significant correlations between the degree of the improvement in the BASDAI score, the corrected angle of the thoracic kyphosis, and the SVA were not found ( $p > 0.05$ , respectively). Nonetheless, the degree of lumbar lordosis correction was significantly correlated to the BASDAI score ( $r = 0.463$ ,  $p < 0.05$ ).

The change in ODI score was significantly correlated with the thoracic kyphosis angle, the degree of lumbar lordosis angle increase, the degree of SVA correction, sacral slope and pelvic tilting,

( $p < 0.05$ ,  $< 0.05$ , and  $< 0.01$ ,  $p < 0.01$ ,  $< 0.05$ , respectively). There was, however, no significant correlation with pelvic incidence ( $p > 0.05$ ) (Table III).

## DISCUSSION

Thoracolumbar kyphotic deformity in AS is a disabling condition affecting more than 30% of patients. Sagittal realignment of AS with thoracolumbar kyphosis is a complex undertaking that poses significant challenge to spine surgeons. Patients find it difficult to sit, stand and or lie down comfortably. Their horizontal visual field is compromised and

Table II. — Clinical assessments

	Pre-operation	Post-operation at last follow-up visit	<i>p</i> Value
BASDAI score	5.3 ± 0.9	2.3 ± 0.7	< 0.01.
BASFI score	2.0 ± 0.8	5.7 ± 0.6	< 0.01
ODI score	65.8 ± 4.8	39.6 ± 5.4	< 0.01

due to an overall loss of sagittal balance their efficiency in gait is severely compromised. Previously, cervicothoracic osteotomies for ankylosing spondylitis were performed with halo-cast fixation (21). Since the reporting of an osteotomy in the lumbar area by Smith-Petersen *et al* (10) many scholars have reported lumbar osteotomy results (18,3,25). However, traditional osteotomies have been fraught with the risk of neurological and catastrophic vascular complications (4,25). More recently, segmental instrumentation and neuromonitoring have made spinal osteotomy surgery safer and more effective (13).

Until now, most spine surgeons commonly use the single pedicle subtraction osteotomy (PSO) to treat thoracolumbar kyphosis and flat back syn-

drome with good result. However, failure to achieve proper sagittal balance after PSO results in residual kyphosis, which makes the center of gravity still remain far anteriorly to the spine. As a result, the implants are placed under high tension and there is a significant increased risk of implant failure, delayed union, and loss of correction (1). In the case of failed realignment, a difficult revision surgery is often needed (23).

The use of VCD for correction of sharp angular spinal deformities was initially reported by Wang Y in 2004 (24). He described 45 patients who underwent VCD with an average of 2.2 vertebrae decancellated for severe sharp angular spinal deformities. A reported correction of approximately 64% in the

Table III. — Multiple linear regression analysis showing the correlation between the measured parameters and clinical scores

		Correlation coefficient (r)	<i>p</i> Value
Thoracic kyphosis	BASDAI	0.235	> 0.05
	BASFI	0.536	< 0.05
	ODI	0.137	< 0.05
Lumbar lordosis	BASDAI	0.463	< 0.05
	BASFI	0.037	> 0.05
	ODI	0.130	< 0.05
Sagittal vertical axis	BASDAI	0.100	> 0.05
	BASFI	0.510	< 0.05
	ODI	0.225	< 0.01
Pelvic incidence	BASDAI	0.825	> 0.05
	BASFI	0.191	> 0.05
	ODI	-0.207	> 0.05
Pelvic tilt	BASDAI	0.582	< 0.01
	BASFI	0.477	< 0.05
	ODI	0.212	< 0.05
Sacral slope	BASDAI	-0.082	> 0.05
	BASFI	0.510	< 0.05
	ODI	0.725	< 0.01

Note : BASDAI, Bath Ankylosing Spondylitis Disease Activity Index ; BASFI, Bath Ankylosing Spondylitis Function Index ; ODI, Oswestry disability index.

coronal and sagittal planes was attained. Since 2005, we applied this technique to correct thoracolumbar kyphotic deformity in AS with good clinical result.

Nowadays, most of the reports dealing with osteotomies for the treatment of kyphotic deformity caused by AS dealt with corrective methodological approaches emphasizing the reduction of postsurgical complications. However, the relevance of spinopelvic measurements in AS remains unclear. On the other hand, the relationship between spinopelvic radiographic parameters and clinical symptoms in AS are of evident clinical importance.

Debarge *et al* (5) have emphasised the importance of the pelvic incidence in balancing severe kyphosis and determining the size of pedicle subtraction osteotomy required to correct sagittal balance. In a recent case-control study, Schwab *et al* (20) found that patients with adult spine deformity with failed realignments after PSO had greater preoperative spinopelvic deformities than those with successful realignments. Lafage *et al* (14) found that pelvic tilt was associated with health-related quality of life in the setting of adult deformity which is consistent with our findings. In fact, in the present study, pelvic tilt was found to be the only significant predictor for the determination of sagittal balance in AS patients at the multiple logistic regression analysis. In our study, PT is significantly correlated to BASDAI, BASFI and ODI. In addition, we find that ODI scores were significantly correlated to sagittal vertical axis, lumbar lordosis, thoracic kyphosis, pelvic tilt and sacral slope. Those were the parameters closely related to the pelvic orientation and played a critical role in maintenance of spinal stabilization, balance and physiological functions.

According to the results of the study of Schwab *et al* (20), besides large preoperative SVA and PI, a large preoperative PT is also a risk factor for postoperative sagittal imbalance after PSO, which is not fully consistent with our results. However, the real radiographical risk factors independently predicting the postoperative sagittal imbalance should be initially analyzed through correlation analysis and the predictive ability should be investigated through the subsequent stepwise multiple regression analysis.

Park *et al* (17) analyzed 24 patients with AS with fixed kyphotic deformity in whom sagittal imbalance was treated with PSO. In their study, they concluded the SVA changes were closely linked to BASFI and psychological status, especially anxiety and depression. However, they observed that thoracic kyphosis was not corrected after the osteotomy had been performed. In our study TK decreases from  $49.6^\circ \pm 11.7^\circ$  before to  $43.5^\circ \pm 9.2^\circ$  after surgery. Furthermore, TK is significantly correlated with BASFI and ODI concerning the quality of life.

Comparing the correlation between TK, LL, SVA, PT, PI, SS and the clinical symptoms, our findings demonstrate that the PT had the greatest correlation with clinical symptoms in patients. The improved lumbar lordosis is significantly correlated with BASDAI and ODI. Sagittal imbalance, decreased lumbar lordosis and increased thoracic kyphosis increases disability and pain severity, which should be taken into account by surgeons when treating AS. In addition, the pelvic parameters especially PT should be considered in the treatment plan of patients with AS.

Limitations of this study is the short follow-up time and the relatively small patient sample. All subjects, however, of this study were patients with AS associated with a fused spine caused by ossification around the vertebral body. So, we can assume that no significant loss of correction and changes in clinical scores would occur after more than a year. Second, there were only 42 subjects in this study. Although sample size was small, this study is worthwhile because analyses about interrelation between the corrective surgery and the changes of clinical outcomes in patients with AS are uncommon. In future studies, more definitive results could be obtained with a larger sample size.

## CONCLUSION

Our study indicates that posterior VCD is an effective therapeutic approach for sagittal imbalance in AS patients. The patients with improved parameters of LL and PT are found to have good clinical outcomes. It is important to quantify the sagittal

spinopelvic parameters and improve the sagittal balance in the surgery for AS patients.

## REFERENCES

1. **Arun R, Dabke HV, Mehdian H.** Comparison of three types of lumbar osteotomy for ankylosing spondylitis : a case series and evolution of a safe technique for instrumented reduction. *Eur Spine J* 2011 ; 20 : 2252-2260.
2. **Calin A, Garrett S, Whitelock H et al.** A new approach to defining functional ability in ankylosing spondylitis : the development of the Bath Ankylosing Spondylitis Functional Index. *J Rheumatol* 1994 ; 21 : 2281-2285.
3. **Chen IH, Chien JT, Yu TC.** Transpedicular wedge osteotomy for correction of thoracolumbar kyphosis in ankylosing spondylitis : experience with 78 patients. *Spine* 2001 ; 26 : E354-360.
4. **Camargo FP, Cordeiro EN, Napoli MM.** Corrective osteotomy of the spine in ankylosing spondylitis. Experience with 66 cases. *Clin Orthop* 1986 ; 208 : 157-167.
5. **Debarge R, Demey G, Roussouly P.** Sagittal balance analysis after pedicle subtraction osteotomy in ankylosing spondylitis. *Eur Spine J* 2011 ; 20 (suppl 5) : 619-625.
6. **Debarge R, Demey G, Roussouly P.** Radiological analysis of ankylosing spondylitis patients with severe kyphosis before and after pedicle subtraction osteotomy. *Eur Spine J* 2010 ; 19 : 65-70.
7. **Fairbank JC, Pynsent PB.** The Oswestry Disability Index. *Spine (Phila Pa 1976)* 2000 ; 25 (22) : 2940-2952 ; discussion 2952.
8. **Garrett S, Jenkinson T, Kennedy LG et al.** A new approach to defining disease status in ankylosing spondylitis : the Bath Ankylosing Spondylitis Disease Activity Index. *J Rheumatol* 1994 ; 21 : 2286-2291.
9. **Johnson RD, Valore A, Villaminar A et al.** Sagittal balance and pelvic parameters – a paradigm shift in spinal surgery. *J Clin Neurosci* 2013 ; 20 (2) : 191-196.
10. **Kim TJ, Kim TH.** Clinical spectrum of ankylosing spondylitis in Korea. *Joint Bone Spine* 2010 ; 77 (3) : 235-240.
11. **Kim YJ, Lenke LG, Bridwell KH et al.** Free hand pedicle screw placement in the thoracic spine : is it safe ? *Spine* 2004 ; 29 (3) : 333-342.
12. **Kim KT, Lee SH, Suk KS et al.** Spinal pseudarthrosis in advanced ankylosing spondylitis with sagittal plane deformity : clinical characteristics and outcome analysis. *Spine* 2007 ; 32 : 1641-1647.
13. **Lieberman JA, Lyon R, Feiner J, Hu SS, Berven SH.** The efficacy of motor evoked potentials in fixed sagittal imbalance deformity correction surgery. *Spine (Phila Pa 1976)* 2008 ; 33 (13) : E414-E424.
14. **Lafage V, Schwab F, Patel A et al.** Pelvic tilt and truncal inclination : two key radiographic parameters in the setting of adults with spinal deformity. *Spine* 2009 ; 34 : E599-E606.
15. **Mangione P, S n gas J.** Sagittal balance of the spine in French. *Rev Chir Orthop Reparatrice Appar Mot* 1997 ; 83 (1) : 22-32.
16. **Park YS, Kim HS, Baek SW.** Spinal osteotomy in ankylosing spondylitis : radiological, clinical, and psychological results. *Spine J* 2013. pii : S1529-9430 (13)01718-X.
17. **Park YS, Kim HS, Baek SW.** Spinal osteotomy in ankylosing spondylitis : radiological, clinical, and psychological results. *Spine J* 2014 Sep 1 ; 14 (9) : 1921-1927.
18. **Rose PS, Bridwell KH, Lenke LG et al.** Role of pelvic incidence, thoracic kyphosis, and patient factors on sagittal plane correction following pedicle subtraction osteotomy. *Spine* 2009 ; 34 : 785-791.
19. **Smith-Petersen MN, Larson CB, Aufranc OE.** Osteotomy of the spine for correction of flexion deformity in rheumatoid arthritis. *Clin Orthop Relat Res* 1969 ; 66 : 6-9.
20. **Schwab FJ, Patel A, Shaffrey CI et al.** Sagittal realignment failures following pedicle subtraction osteotomy surgery : are we doing enough ? *J Neurosurg Spine* 2012 ; 16 : 539-546.
21. **Urist MR.** Osteotomy of the cervical spine : report of a case of ankylosing rheumatoid spondylitis. *J Bone Joint Surg Am* 1958 ; 40-A (4) : 833-843.
22. **van der Linden S, Valkenburg HA, Cats A.** Evaluation of diagnostic criteria for ankylosing spondylitis. A proposal for modification of the New York criteria. *Arthritis Rheum* 1984 ; 27 (4) : 361-368.
23. **van Royen BJ, De Gast A.** Lumbar osteotomy for correction of thoracolumbar kyphotic deformity in ankylosing spondylitis. A structured review of three methods of treatment. *Ann Rheum Dis* 1999 ; 58 : 399-406.
24. **Wang Y, Lenke LG.** Vertebral column decancellation for the management of sharp angular spinal deformity. *Eur Spine J* 2011 ; 20 (10) : 1703-1710.
25. **Weatherley C, Jaffray D, Terry A.** Vascular complications associated with osteotomy in ankylosing spondylitis : a report of two cases. *Spine* 1988 ; 13 : 43-46.