

## CASE REPORT

# CALCIFYING APONEUROTIC FIBROMA : A REPORT OF THREE CASES

N. K. SFEROPOULOS, R. KOTAKIDOU<sup>1</sup>

Three cases of calcifying aponeurotic fibroma in an 8-year-old boy, a 43-year-old woman and a 48-year-old man are presented. The lesions involved the substance of the palmaris longus tendon, the lateral aspect of the foot at the base of the fifth metatarsal and the fifth digit of the foot, respectively. The clinical and radiologic findings, including ultrasound and computed tomography, are described. Histologic features included chondroid tissue and calcification within areas of proliferative plump fibroblasts in the younger patient, while in the two adults the lesions were more sharply defined showing increased calcification of dense connective tissue with less pronounced cellularity and no evidence of chondroid differentiation.

**Keywords :** calcifying aponeurotic fibroma.

**Mots-clés :** fibrome aponevrotique calcifiant.

### INTRODUCTION

Calcifying aponeurotic fibroma (CAF) is an uncommon but well-characterized benign fibrous tumor. It usually presents as a slowly growing mass attached to tendon or aponeurosis commonly in the extremities of children and young adults. Rapidity of growth seems to slow down, while tumor calcification appears to increase with age. The lesion has a strong propensity for local invasion, and the recurrence rate is approximately 50%. However, complete excision is advisable when this can be accomplished without functional compromise. Otherwise, a more conservative surgical approach is advised (1, 4, 5).

Three cases are presented illustrating the clinical, radiologic and histologic features of this disease process.

### CASE REPORTS

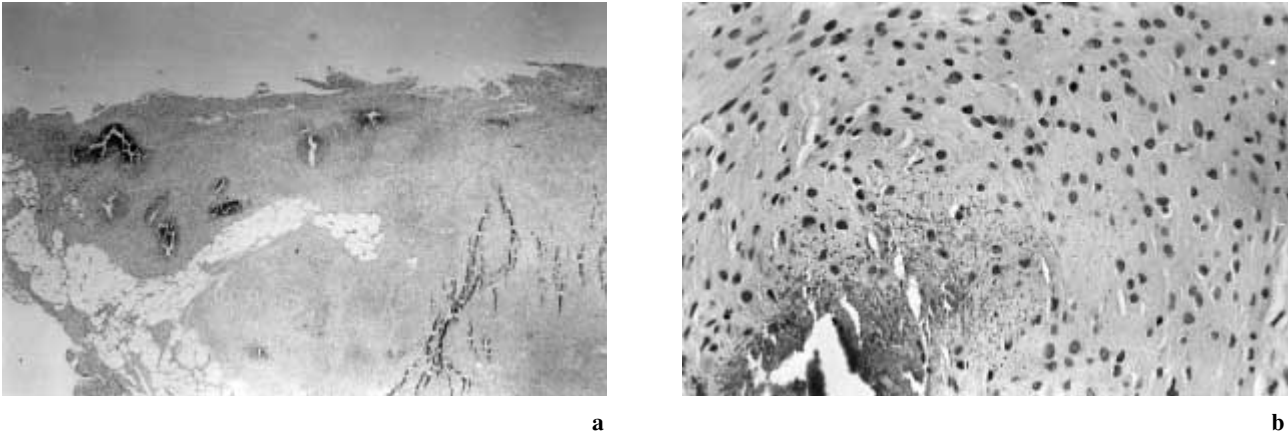
#### Case 1

An 8-year-old boy was admitted for evaluation of a firm, mobile mass that had developed on the volar aspect of his left wrist 18 months previously. The lesion had grown recently and caused mild pain and tenderness more pronounced with wrist extension. There was no history of trauma and no local sign of infection. Routine blood tests and plain radiographs were normal. Ultrasound revealed a subcutaneous solid mass.

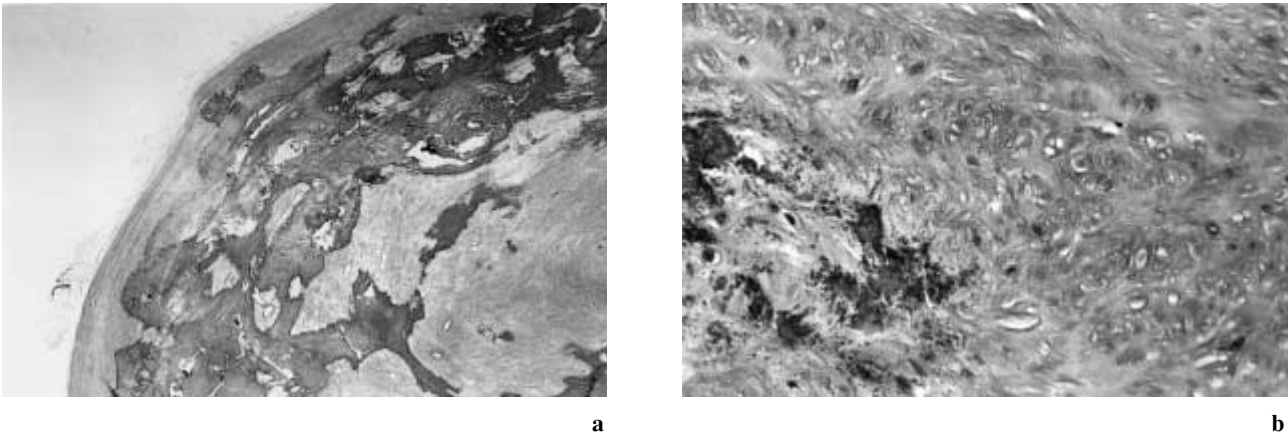
Under general anesthesia a transverse incision was made across the volar aspect of the wrist between flexor creases. The tumor was located within the substance of the palmaris longus, so the tendon was excised to macroscopically healthy borders. Histologic examination indicated a lobulated and poorly margined tumor measuring  $11 \times 6 \times 5$  mm. There was diffuse fibroblastic growth with a linear arrangement of the rounded fibroblasts and areas of spotty calcification surrounded by chondrocytes. Fat infiltration as well as remnants of tendon fibers were also found (fig. 1). There was no sign of nuclear atypia and mitotic activity. Two years later no local recurrence was detected.

Departments of Orthopedic Surgery and <sup>1</sup> Pathology, "G. Gennimatas" Hospital, Thessaloniki, Greece.

Correspondence and reprints : N. K. Sferopoulos, P. Papageorgiou 3, 546 35, Thessaloniki, Greece.



**Fig. 1.** — Case 1. The lesion was not well circumscribed. It included fat infiltration and remnants of tendon fibers (a). Plump fibroblasts and focal calcification were also evident (b).



**Fig. 2.** — Case 2. The lesion showed very well-delineated margins and extensive calcification (a). Myofibroblast-like cells were noted around calcified areas (b).

## Case 2

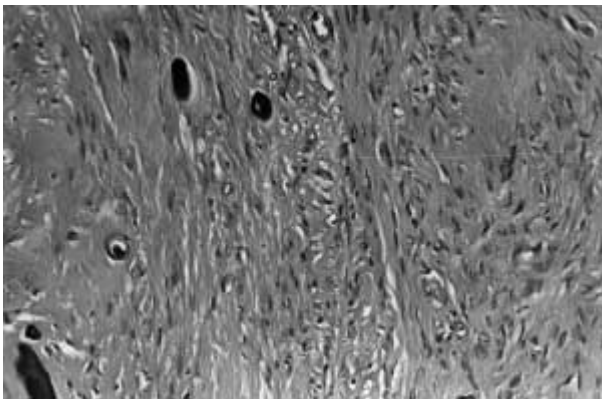
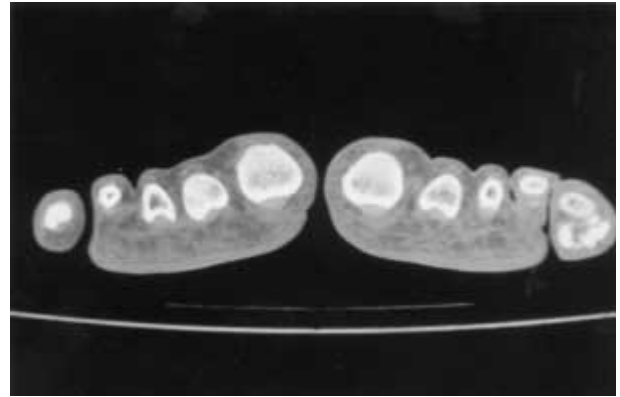
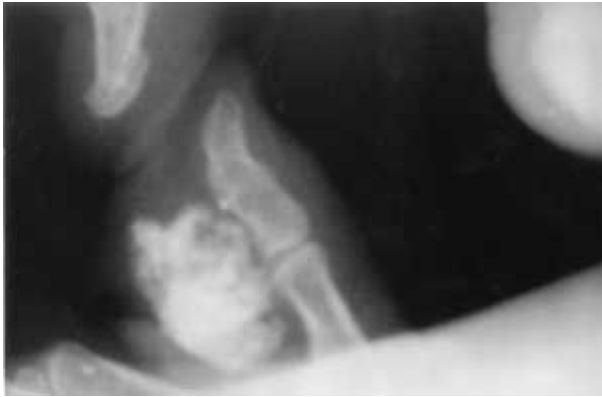A 43-year-old woman was referred for a 2-cm, nontender tumor in the lateral aspect of the foot at the base of the fifth metatarsal. Since first noted, about 15 years previously, it had grown slowly and caused some discomfort with shoes. There was no history of trauma. Routine blood tests were normal. Radiographs showed a calcified lesion close to the underlying bone. Ultrasound evaluation indicated a subcutaneous fibrous mass with diffuse hyperechoic areas representing calcification.

It was removed under local anesthesia. The lesion was a well-defined mass adjacent to the

peroneal tendon. The histologic picture was characterized by a heavily collagenized component exhibiting extensive calcification. The cellularity was low with foci of myofibroblast-like cells. There was no sign of chondroid differentiation (fig. 2). Nuclear atypia, mitotic activity and local tissue destruction were not encountered. Three years later there was no recurrence.

## Case 3

A 48-year-old man came for evaluation of a 2-cm mass of the fifth digit of the right foot. It had appeared about 12 years previously, had grown



a	b
c	

**Fig. 3.** — Case 3. Extensive calcification of the lesion with an apparent cleavage plane from the underlying bone was noted on radiographs (a) and CT-scan (b). Histology revealed a heavily collagenized component containing focal calcification resembling psammoma bodies (c).

slowly, and caused some pain and tenderness recently. Radiographs of the lesion showed a calcified lesion close to the proximal interphalangeal joint but with no bony destruction (fig. 3a). A computed tomography indicated a heavily calcified mass on the plantar and lateral aspect of the fifth toe entirely separated from bone (fig. 3b).

The lesion was removed under local anesthesia. It was a firm, well-circumscribed mass adjacent to the flexor tendons. Microscopically, the mass consisted of dense fibrous stroma with extensive foci of calcification. There was no evidence of cartilaginous metaplasia (fig. 3c). After 2 1/2 years the patient had no symptoms.

### DISCUSSION

Calcifying aponeurotic fibroma (CAF) is usually found superficially in subcutaneous tissue or in deeper musculofascial and paraskelatal tissue, while an intratendinous lesion has only been reported once in an adult (7). The appearance of

this fibroblastic tumor within the substance of the palmaris longus tendon in our younger patient may well indicate that even in children a tendon can be involved apart from fat, fascia or aponeurosis.

The most constant clinical findings include a slow-growing, nontender, firm, mobile mass less than 3 cm in diameter in the distal portion of the extremities in children and adolescents (4). However, there is only a single report of a CAF involving a digit of the foot (9).

Radiographic features are also nonpathognomonic. No calcification or only smudge-like radiopacities may appear initially. However, lesions that have been present for years may exhibit large calcified areas (1). Ultrasound examination excludes the more likely diagnosis of a ganglion indicating a solid mass mainly fibrous with foci of calcification. A computed tomography also reveals a calcified rather than ossified lesion with a visible cleavage plane from bone, which may lead to the diagnosis of panniculitis ossificans, extra-skeletal or parosteal chondroma (1, 4, 5).

Definite diagnosis is always based on histologic findings and sometimes on immunohistochemical tests and ultrastructural studies (5, 6).

A typical microscopic picture appeared in our younger patient. It was manifested as a lobulated mass with irregular borders demonstrating plump fibroblasts, foci of calcification, and patches of chondroid differentiation. Therefore, a clear distinction from infantile or juvenile forms of fibromatosis, fibrous hamartoma of infancy and monophasic fibrous-type of synovial sarcoma could be easily made (4).

In our adult patients histologic findings were almost identical. In both cases extensive degenerative changes were encountered i.e. fibrosis, calcification.

Differential diagnosis from parosteal osteochondroma and extraskeletal chondroma was based on absolute lack of cartilage formation. On the other hand, panniculitis ossificans (fibro-osseous pseudotumor) exhibits a distinct mineralization pattern with a fibroblastic proliferation showing varying degrees of atypia, while parosteal (nodular) fasciitis can be readily distinguished by the presence of plump fibroblasts within a myxoid background (3,5).

Differential diagnosis from a calcified soft tissue leiomyoma is more complicated. In deep soft tissue leiomyomas regressive changes are quite common, and calcium may also be laid down in distinct spherules reminiscent of psammoma bodies. However, the main histologic characteristics of leiomyoma i.e. cells with elongated, oblong, fusiform, blunt-ended nuclei as well as proliferation of smooth muscle fibers (2) were not found in our patients. On the other hand, the appearance of cells closely resembling myofibroblasts surrounding the calcified areas is compatible with CAF (6, 8). The diagnosis of CAF was also supported by recent studies where older lesions appeared well-demarcated and less cellular, with increased collagen deposition between the fibroblasts and with a more prominent degree of calcification suggesting maturation of the process. Finally, chondroid foci, although typically present, are not absolute prerequisites for the diagnosis of CAF (1, 4, 5).

## REFERENCES

1. Bogumill G. P., Fleegler E. J. Tumors of the Hand and Upper Limb, Churchill Livingstone, Edinburgh, 1993, pp. 239-240.
2. Bulmer J. H. Smooth muscle tumours of the limbs. J. Bone Joint Surg., 1967, 49-B, 52-58.
3. Dupree W. B., Enzinger F. M. Fibro-osseous pseudotumor of the digits. Cancer, 1986, 58, 2103-2109.
4. Enzinger F. M., Weiss S. W. Soft tissue tumors, Mosby, St Louis, 1995, pp. 256-261.
5. Fetsch J. F., Miettinen M. Calcifying aponeurotic fibroma : A clinicopathologic study of 22 cases arising in uncommon sites. Hum. Pathol., 1998, 29, 1504-1510.
6. Iwasaki H., Kikuchi M., Eimoto T., Enjoji M., Yoh S., Sakurai H. Juvenile aponeurotic fibroma : An ultrastructural study. Ultrastruct. Pathol., 1983, 4, 75-83.
7. Moskovich R., Posner M. A. Intratendinous aponeurotic fibroma. J. Hand Surg. 1988, 13-A, 563-566.
8. Navas-Palacios J. J. The fibromatoses. An ultrastructural study of 31 cases. Pathol. Res. Pract., 1983, 176, 158-175.
9. Yee D. Y., Mott R. C., Nixon B. P. Calcifying aponeurotic fibroma. J. Foot. Surg., 1991, 30, 279-283.

## SAMENVATTING

*N. K. SFEROPOULOS, R. KOTAKIDOU. Calcifierend aponeurotisch fibroma (C.A.F.) : drie gevallen.*

Drie gevallen van een calcifierend fibroom van de aponeurosis worden beschreven ; het ging om een jongetje van 8 jaar, een 43-jarige vrouw en een 48-jarige man ; de localisatie was respectievelijk : de pees van de palmaris longus, de laterale voet ter hoogte van metatarsaal V basis en de V<sup>o</sup> teen.

Klinische en radiografische (waaronder Echo en CT) karakteristieken worden beschreven. Histologisch vindt men chondroid weefsel en verkalking, middenin gebieden van proliferatie van plompe fibroblasten bij het jongetje, bij de twee volwassenen daarentegen, waren de letsels scherper begrensd en minder celrijk, was er meer calcificatie van het bindweefsel, en was er geen chondroïde differentiatie.

## RÉSUMÉ

*N. K. SFEROPOULOS, R. KOTAKIDOU. Fibrome aponeurotique calcifiant : présentation de 3 cas.*

Les auteurs ont observé trois cas de fibrome aponeurotique calcifiant chez un garçon de 8 ans, une femme de

43 ans et un homme de 48 ans. Les lésions étaient localisées au niveau du tendon du palmaris longus dans un cas, à la base du 5<sup>ème</sup> métatarsien dans le second et au niveau du petit orteil dans le 3<sup>ème</sup>. Les auteurs présentent les aspects cliniques et radiologiques, en particulier échographique et tomodensitométrique. Sur le plan histologique, ils ont observé chez le patient le plus jeune du

tissu chondroïde et des calcifications dans des zones de prolifération ostéoblastique ; chez les deux autres patients, les lésions étaient plus clairement définies et montraient un tissu conjonctif dense fortement calcifié, moins cellulaire, sans signe de différenciation chondroïde.