



Risk factors for additional surgery after closed reduction of hip developmental dislocation

Simon VANDERGUGTEN, Sidi Yaya TRAORE, Pierre-Louis DOCQUIER

Cliniques universitaires Saint-Luc, Service de Chirurgie orthopédique et Traumatologique, Brussels, Belgium

Purpose : to evaluate the risk factors for additional surgery after closed reduction of hip developmental dislocation

Methods : closed reduction for developmental hip dislocation was performed on 72 patients, with a total of 82 hips (10 bilateral). Were included only patients with irreducible hip dislocation who were treated by overhead traction followed by closed reduction under general anaesthesia and spica casting. The mean age at the time of closed reduction was 10 months, with 82% of dislocation diagnosed after the age of 6 months. In 28 hips (34.1%), no additional surgical procedure was necessary, while 54 hips (65.9%) needed an additional surgery, consisting in Salter osteotomy in 40 hips (48.8%) or open hip reduction in 14 (17.1%).

Results : risk factors for the need of additional surgery were: older age at the time of reduction, male sex, high grade of hip dislocation (Tönnis grade 3 and 4, versus grade 1 and 2), and quality of hip reduction. All the patients older than 17 months at the time of closed reduction needed additional surgery. Bilateral hip dislocation had poorer Severin grading than unilateral dislocation. Poorer Kalamchi scoring was associated with older age and with the presence of the cephalic nucleus at the time of reduction.

Conclusion : this study confirmed delayed diagnosis of hip dislocation leads to a more extensive treatment with poorer issue.

Keywords : developmental hip dislocation, open reduction, innominate osteotomy, overhead traction.

INTRODUCTION

Developmental dislocation of the hip (DDH) is the most common developmental abnormality affecting the hip with a variable incidence around 188 per 1000 newborns in Canadian Indians, 0.1 per 1000 in Hong Kong and 0 in African native (9,17). Despite various protocols to improve early detection of DDH, diagnosis is unfortunately often delayed in newborns, and sometimes to walking age (24). Any delay leads to a more extensive treatment and uncertain prognosis of the hip (20,32), especially because of abnormal development of the

-
- Simon Vandergugten, M.D.
 - Sidi Yaya Traore, M.D.
 - Pierre-Louis Docquier, M.D., Ph.D.

Cliniques universitaires Saint-Luc, Service de Chirurgie orthopédique et Traumatologique, Avenue Hippocrate, 10, B-1200 Brussels, Belgium.

CARS (computer assisted robotic surgery), Institut de Recherche Expérimentale et Clinique (IREC), Université Catholique de Louvain, Tour Pasteur +4, Avenue Mounier, 53, B-1200 Brussels, Belgium.

Correspondence : Pierre-Louis Docquier, Cliniques universitaires Saint-Luc, Service de Chirurgie orthopédique et Traumatologique, Avenue Hippocrate, 10, B-1200 Brussels, Belgium

E-mail: pierre-louis.docquier@uclouvain.be

© 2016, Acta Orthopaedica Belgica.

No benefits or funds were received in support of this study. The authors report no conflict of interests.

Acta Orthopaedica Belgica, Vol. 82 - 4 - 2016

femoral head and insufficient coverage related to the acetabulum (4-5,24). Conversely, early reduction of femoral head with a good and concentric hip position will allow a normal hip development, resulting in a stable, functional and painless hip from adolescence to adult age (8,13,18). The Salter innominate osteotomy is widely used for patients older than 18 months (2) but there is no consensus about ideal treatment.

Very long-term results after progressive orthopaedic reduction and innominate osteotomy (16) versus after open reduction and innominate osteotomy (27) show better survival rates after closed reduction.

In patients treated with closed reduction of the dislocated hip, some need further surgical procedures to correct residual dysplasia or for redislocation, while others do not. This is a retrospective study of a large series of patients with DDH treated by closed reduction aimed to find factors that can predict the future requirement for pelvic osteotomy or other surgeries (as capsulorrhaphy).

MATERIALS AND METHODS

Patients' series and treatment protocol

Agreement from the local ethical committee was obtained. We carried out a retrospective study of patients having needed hip closed reduction

between 1979 and 2012 in a single university hospital. Were included only patients with irreducible hip dislocation who were treated by overhead traction followed by closed reduction under general anaesthesia and spica casting. Were excluded patients with reducible hips treated with Pavlik harness as well as the patients directly operated by open reduction without attempt of closed reduction. Patients were also excluded if the medical records and radiographs were inadequate, if the duration of follow-up was less than 24 months after closed reduction or if the dislocation was not idiopathic (neurovascular disease, syndromic dislocation, etc...). The four-stage treatment protocol consisted in : a first period of around 7 days overhead traction, a second stage of closed reduction under general anaesthesia with a hip arthrogram and immobilisation with hip spica cast for an average time of 3 months, which is changed after 6 weeks at the third stage with a control hip arthrogram under general anaesthesia, the 4th stage consisted in determining the need of surgery based on radiological evolution.

Radiological evaluation

Pre-reduction grading of the hip dislocation was estimated using the grading system of Tönnis (28). According to this classification, the capital femoral ossification center is medial to Perkin's line in

Table I. — Hip dislocation grading according to Tönnis

Tönnis grade (position of the capital femoral ossification center)	Number of hips (%)	Number of finally operated hip (%) (p=0.046)
Grade 1 (medial to Perkin's line)	1 (1.2%)	0 (0%)
Grade 2 (lateral to Perkin's line)	41 (50%)	23 (50.1%)
Grade 3 (at the level of acetabular rim)	33 (40.2%)	24 (72.7%)
Grade 4 (superior to acetabular rim)	7 (8.5%)	7 (100%)

Table II. — Quality of arthrographic reduction according to Tönnis

Tönnis grade (position of femoral head)	Number of hips (%)	Number of finally operated hip (%) (NS)
Grade 1 (fully reduced)	49 (59.8%)	30 (61.2%)
Grade 2 (below the labrum but slightly lateralised)	26 (31.7%)	17 (65.4%)
Grade 3 (outside the acetabulum)	7 (8.5%)	7 (100%)

Table III. — Result of Severin classification

	Radiographic Appearance	Center-Edge Angle (CEA)	Number of hips (%)
Class I	Normal	Ia: >19° (6 to 13 years old); >25° (>14 years old)	21 (25.6%)
		Ib: >15 to 19° (6 to 13 years old); 20 to 25° (>14 years old)	6 (7.3%)
Class II	Moderate deformity of femoral head, femoral neck, or acetabulum	Ila: >19° (6 to 13 years old); >25° (>14 years old)	40 (48.8%)
		Ilb: >15 to 19° (6 to 13 years old); 20 to 25° (>14 years old)	6 (7.3%)
Class III	Dysplasia without subluxation	<15° (6 to 13 years old); <20° (>14 years old)	7 (8.5%)
Class IV	IVa : Moderate subluxation	=0°	2 (2.4%)
	IVb: Severe subluxation	<0°	0
Class V	Femoral head articulates with pseudo acetabulum in superior part of original acetabulum		0
Class VI	Redislocation		0

Table IV. — Result of Kalamchi and MacEwen classification for avascular necrosis (AVN)

Kalamchi and MacEwen	Number of hips (%)	Number of finally operated hip (%) (NS)
Grade 1 (ossification delay)	56 (68.3%)	39 (69.6%)
Grade 2 (lateral epiphysiodesis => valgus)	6 (7.3%)	4 (66.7%)
Grade 3 (medial epiphysiodesis => varus)	3 (3.7%)	1 (33.3%)
Grade 4 (complete epiphysiodesis => short neck and great trochanter ascension)	17 (20.7%)	10 (58.8%)

grade 1, lateral to the line in grade 2, at the level of acetabular rim in grade 3 and superior to acetabular rim in grade 4 (Table I).

The quality of arthrographic reduction of the hips was assessed using the grading system of Tönness (28): the femoral head is fully reduced in grade 1, the femoral head is below the labrum but slightly lateralized in grade 2 and the femoral head is not below the labrum and outside the acetabulum in grade 3 (Table II).

The postoperative outcome was graded on the basis of the most recent follow-up radiograph. Patient bone maturity was assessed by Risser test. To assess residual dysplasia, we used Severin classification for hip development (23): the average center-edge angle (CEA) was measured and considered as “normal” if it was more than 25° (Table III). The presence and degree of osteonecrosis was determined using Kalamchi and MacEwen classification for avascular necrosis (AVN) (6):

there is a simple ossification delay in grade 1, a lateral epiphysiodesis leading to valgus hip in grade 2, a medial epiphysiodesis leading to varus hip in grade 3 and a complete epiphysiodesis leading to a short femoral neck and a great trochanter ascension in grade 4 (Table IV).

Clinical evaluation

The clinical hip function at latest follow-up was classified according to the criteria described by McKay (1). In grade 1, there is a stable, painless hip, without limp, a negative Trendelenburg sign, and a full range of movement. In grade 2, there is stable, painless hip, with slight limp, a negative Trendelenburg sign, and a slight decrease in range of movement. In grade 3, there is stable, painless hip, limp, positive Trendelenburg sign, and limitation of movement. In grade 4, there is unstable or painful hip, or both; positive Trendelenburg sign (Table V).

Statistics

Statistical analyses were conducted using SPSS® software (SPSS ® version 20.0, SPSS Inc., Chicago, IL, USA). A logistic regression with Cox model was performed. The different variables that were tested in the model were: gender, hip side, unilateral or bilateral, age at the time of reduction, pre-reduction traction or not, traction's time, presence of the femoral head ossification nucleus, pre-reduction grading of hip dislocation (Tönnis), and the spica cast's time. We grouped Tönnis 1 and 2 as low risk group and Tönnis 3 and 4 as high risk group.

Univariate analysis of variables was made to search the predictive factors for surgery. Only variables with a p value ≤ 0.2 were included in the multivariate model and were calculated using 95% confidence interval (CI). We also made Chi-square to test the factors having an impact on the functional results of the hip and the Kalamchi score. A p value less or equal to 0.05 was considered statistically significant.

RESULTS

There were 65 girls and 7 boys (72 patients) and a total of 82 dislocated (10 bilateral). The mean age at the time of closed reduction was 10 months (range, 1 to 26 months), with 82% of dislocation diagnosed after the age of 6 months (extremes from 0.9 to 25 months). In 40% of patients, a previous attempt of closed reduction with Pavlik harness had been unsuccessful. In 62 patients (86%), a preoperative overhead traction was applied for a mean time of 10 days (range, 0 to 42 days). A core cephalic ossification center was present in 39 hips (48%) at the time of reduction. There were 36 left, 26 right and 10 bilateral hip dislocations.

The mean follow-up was 7 years (range, 24 months to 31 years). The average age at latest follow-up was 8 years (range, 3 to 33 years). In 28 hips, no surgical procedure was necessary (34.1%) (Fig. 1), while 54 hips (65.9%) needed surgical procedure (Fig. 2), consisting in Salter osteotomy in 40 hips (48.8%) and open reduction in 14 (17.1%). For 4 hips, a second additional surgery was necessary, consisting in Salter osteotomy in

1 hip, shelf acetabuloplasty in 2 hips and femoral varus osteotomy in 1 hip. In the non-operated group the mean age at the time of reduction was 5.4 months (range, 0.9 to 17 months), while it was 12.7 months (range, 2 to 26) in the operated group ($p < 0.0001$, Mann-Whitney test). Result of univariate Cox regression for predictive factors of surgical procedure (Salter or open reduction) is summarized in Table 6. Only variables with a p value ≤ 0.2 were included in the multivariate model (Table VII).

Radiological results

– Reduction evaluation: Pre-reduction grading of the hip dislocation according to Tönnis is summarized in Table 1. Quality of arthrographic reduction of the hips according to Tönnis is summarized in Table 2. There were 52 patients rated Risser 0 (72.2%), 2 patients Risser 2 (2.8%), 1 patient Risser 3 (1.4%), 3 patients Risser 4 (4.2%) and 14 patients Risser 5 (19.4%). There was no Risser 1.

– Residual dysplasia evaluation: At latest follow-up the mean center-edge angle (CEA) was 27° (8 to 47°). Result of Severin classification is summarized in Table 3, there was no relationship between final CEA and age at the time of closed reduction (p value = 0.611). Influence of the different factors on the Severin classification was tested and only bilaterally had poorer Severin grading than unilaterality ($p = 0.016$).

– Avascular necrosis evaluation: Result of Kalamchi and MacEwen classification in Table 4. Three factors influence Kalamchi score: older age was associated with poorer scoring ($p = 0.003$), traction prevents from AVN ($p = 0.030$), and the presence of the cephalic nucleus had poorer scoring ($p = 0.036$).

Functional results

Result of McKay's classification is in Table 5. All patients who were at skeletal maturity were McKay 1 (15 hips) or 2 (2 hips). Three factors negatively influence McKay scoring: bilateralism ($p = 0.015$), high Tönnis before reduction ($p = 0.025$)

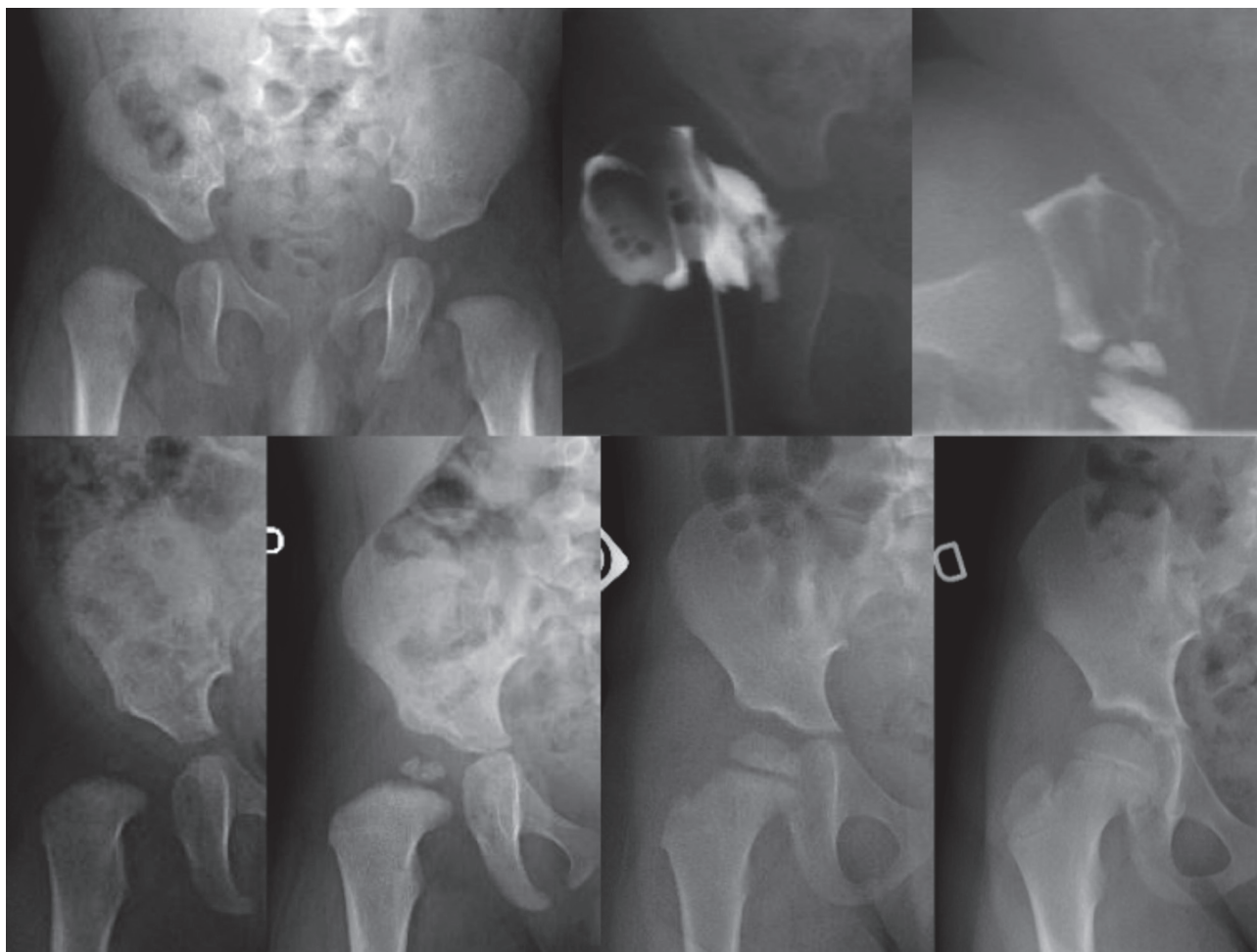


Fig. 1. — Example of a closed reduction without need of additional surgery. 2A-B. 4-month-old girl with right Tonnis-grade 2 hip dislocation. After 8-day-overhead traction, the hip was closely reduced. 1C. Reduction was scored grade 1. 1D: radiograph at the age of 11 months. 1E: radiograph at the age of 17 months. 1F: radiograph at the age of 3 years. 1G: radiograph at the age of 7 years and 6 months.

and number of traction days ($p=0.047$). Patients with poorer Severin scoring and poorer Kalamchi scoring also had poorer McKay scoring ($p<0.001$).

DISCUSSION

Influence of the age

It is admitted that the final functional result after reduction of DDH depends on the age at the time of reduction (11), with better results when the treatment was started before walking age (16). In our series, all the patients older than 17 months at the

time of closed reduction needed additional surgery in the follow-up. Age at the time of reduction was found to be a statistically significant factor for future surgery (open reduction or Salter osteotomy) according to Malvitz *et al.* (15) and Bolland *et al.* (3). The older the child at the time of reduction; the more the risk of additional surgery: the risk to have additional surgery was 1.1 times the age in months. There was no relationship between age at the time of the reduction and the coverage of the acetabulum (CEA) at latest follow-up in agreement with Terjesen *et al.* (26). Conversely, Malvitz and Weinstein had better CEA results in

younger patients (15). The age appeared as a factor influencing the occurrence of AVN ($p=0.003$). For Weiner *et al.*, age less than one year old substantially reduces the incidence of AVN and prognosis is worse for the patient more than one year old (30). Xu M *et al.* (33) found also that the age at the time of reduction was an important factor to predict the severity of AVN. Age did not appear to have significant influence on the Severin grade ($p=0.06$). In general, the earlier the reduction of the hip the better its radiographic appearance, and hence the better its function (10,15,31).

Influence of gender

The gender of patients seemed to be a factor to lead to surgery in our study. The risk for the need of surgery was multiplied par 4.138 for the boys by comparison with the girls. Incidence of DDH is higher in girls, and that can be attributed to potentiation by endogenous estrogens produced by the female infant and the transiently increased ligamentous laxity in the perinatal period caused by high levels of circulating maternal hormones. The relaxin family has also been implicated (14). We

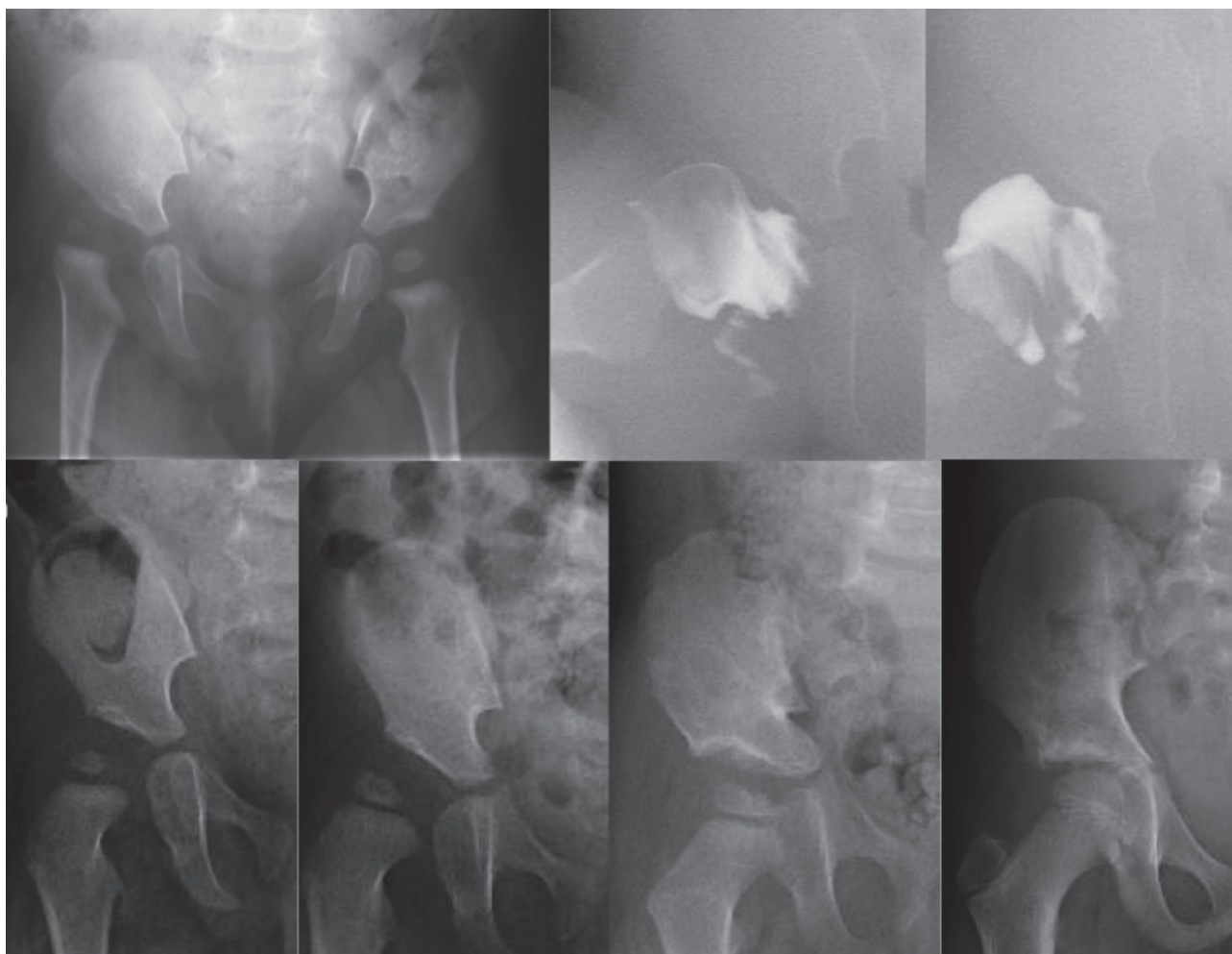


Fig. 2. — Example of a closed reduction with further need of additional surgery. 1A-B. 7-month-old girl with right Tonnis-grade2 hip dislocation. After 8-day-overhead traction, a closed reduction was attempted. 1C. Reduction was scored grade 1. 1D: radiograph at the age of 12 months. 1E: radiograph at the age of 19 months. A Salter innominate osteotomy was performed at the age of 21 months. 1F: radiograph at the age of 2 years and 6 months. 1G: radiograph at the age of 6 years and 6 months.

Table V. — Result of McKay's functional classification

Mc Kay grade	Number of hips (%)	Number of finally operated hip (%) (NS)
Grade 1 (painless, full ROM)	61 (74.4%)	39 (63.9%)
Grade 2 (slight limp, slight diminution of ROM)	16 (19.5%)	13 (81.2%)
Grade 3 (limp, trendelburg sign, ROM limitation)	5 (6.1%)	2 (40%)
Grade 4 (unstable or painful)	0%	0%

Table VI. — Univariate Cox regression

Variables	Hazard Ratio	CI to 95%	p value	Chi-2
Sex	2.940	1.397-6.188	0.005	0.086
Age at the time of reduction	1.087	1.045-1.130	0.000	0.046
Traction	1.492	0.674-3.302	0.324	0.170
Number of traction's day	1.075	1.036-1.115	0.000	0.099
Presence of femoral head nucleus	1.972	1.136-3.425	0.016	0.003
Tönnis before reduction (high/low risk)	2.338	1.344-4.066	0.003	0.001
Tönnis after reduction	2.027	1.290-3.185	0.002	0.129
Plaster's time	0.988	0.674-1.475	0.988	0.288
Bilateral	1.114	0.603-2.059	0.730	0.653
Side treated	0.960	0.664-1.387	0.826	0.724

Table VII. — Multivariate regression

Variables	Hazard Ratio	CI to 95%	p value
Sex	4.138	1.826-9.379	0.001
Age at the time of reduction	1.088	1.010-1.172	0.027
Number of traction's days	1.050	1.007-1.095	0.022
Presence of cephalic nucleus	0.816	0.292-2.285	0.699
Tönnis before reduction (high/low risk)	1.363	0.735-2.528	0.325
Tönnis after reduction	2.834	1.685-4.766	0.000

have no explanation for the higher need for surgery in boys.

Influence of overhead traction

Preoperative traction was not found to be beneficial to avoid future surgery in univariate regression (p-value=0.130). In our study, there was statistically significant relationship between avascular necrosis classified according to Kalamchi-McEwen, preoperative traction (p=0.03) and the presence of the femoral head nucleus (p=0.036).

In the literature, overhead traction seems to reduce the risk of avascular necrosis by reducing stress on the cephalic nucleus (7). The overhead traction can reduce the rate of severe growth disturbances (25). For Weiner *et al.*, traction of twenty-one days or more substantially reduces the incidence of AVN (30).

Influence of the time of spica cast

The time of spica cast did not appear to influence the need of future surgery (p=0.99).

Influence of grade of dislocation

The Tönnis grade of dislocation appeared to be significantly determining for the need for surgery. High grade dislocation (Tönnis grade 3 and 4) had higher risk for surgery compared to Tönnis grade 1 and 2 in the univariate model (p -value = 0,003) and Chi-square test (p -value = 0,001). Grade of dislocation did not influence the occurrence of avascular necrosis, according to Xu M *et al.* (33), but influenced the clinical outcome with poorer clinical outcome in higher grades (3 and 4) (p -value = 0,025).

Influence of the presence of the femoral head nucleus

The presence of the femoral head nucleus was associated with more surgeries (according to univariate regression and Chi-square test), which is probably correlated with age. In a retrospective series, Luhmann *et al.* concluded that delaying the reduction of dislocated hip until the appearance of the ossification nucleus more than doubles the need for future surgery to make the hip as anatomically normal as possible (12). In our series, the risk of avascular necrosis was higher in the presence of the ossifying nucleus, according to Segat *et al.* (22). Roposch *et al.* (19) in a meta-analysis concluded that the presence of the femoral head ossific nucleus did not have significant effect on the development of AVN of any grade, but did have a protective effect on the more severe forms of the condition. Xu M *et al.* (33) did not find a relationship between severity of AVN and the presence of femoral head nucleus.

In our series the presence of the nucleus did not influence the clinical outcome.

Influence of Tönnis arthrographic reduction quality

Reduction quality was found to be a predictive factor of future surgery ($p=0.002$). This makes sense because earlier reduction is necessary for good development of acetabulum (10) and if the reduction is not adequate, development of acetabulum will not occur adequately. When the

grade of the quality of reduction increases, the risk is 2.8 times superior. This emphasizes once more that obtaining a concentric and stable reduction are probably the most important factors in determining the outcome of a dislocated hip. All patients with Tönnis grade 3 needed a surgery in the following weeks (100%) as the femoral head was not below the labrum and was outside the acetabulum. For some patients, the surgery was delayed until the patient was 10-month-old.

Influence of bilateralism

In our study, we found poorer Severin score in case of bilateralism of DDH ($p = 0.016$). Ryan *et al.* (21) reported that patients with bilateral DDH and an older age tended to have a poor radiographic outcome but Wang *et al.* found that children of walking age with bilateral and unilateral dysplasia treated with one-stage surgery had similar outcomes according to the Severin classification (29).

Influence on clinical outcome

Number of traction's day, bilateralism, Tönnis before reduction, Severin grade and Kalamchi-McEwen score had statistically significant relationship with McKay functional scoring. Malvitz *et al.* reported a function deterioration with the time, even in the absence of disturbance of growth in the proximal end of the femur (15).

The average CEA of patients at skeletal maturity was 33° (23 to 45). For the others patients, the average CEA were normal in average (25°) but could evolve because 73% of patients did not achieve skeletal maturity. The CEA does not seem to be an important factor for the prediction of the clinical outcome. This was observed by Morin *et al.* (16). The same authors recommend progressive orthopaedic reduction rather than open reduction to avoid growth disturbance of the femoral head, which will lead many years later to premature osteoarthritis.

The limits of this study were: most of the patients did not reach skeletal maturity at the time of last follow-up, the use of several traction duration protocols. For some patients, the duration

of follow-up is not sufficient to judge the AVN or if a surgery will be needed to correct the residual dysplasia.

CONCLUSION

This study confirmed that late DDH diagnosis leads to a more extensive treatment. The quality of reduction is an important factor that may lead to a future surgery. Tönnis grade 3 and 4 had higher risk for surgery compared to Tönnis grade 1 and 2. All patients older than 17 months needed surgery to reduce the hip joint. The clinical outcome depends on the traction, the traction's day number, McKay scoring, and Severin scoring.

REFERENCES

1. **Barrett W P, Staheli L T, Chew D E.** The effectiveness of the Salter innominate osteotomy in the treatment of congenital dislocation of the hip. *J Bone Joint Surg Am* 1986 ; 68 (1) : 79-87.
2. **Berkeley M E, Dickson J H, Cain T E, Donovan M M.** Surgical therapy for congenital dislocation of the hip in patients who are twelve to thirty-six months old. *J Bone Joint Surg Am* 1984 ; 66 (3) : 412-20.
3. **Bolland B J, Wahed A, Al-Hallao S, Culliford D J, Clarke N M.** Late reduction in congenital dislocation of the hip and the need for secondary surgery: radiologic predictors and confounding variables. *J Pediatr Orthop* 2010 ; 30 (7) : 676-82.
4. **Browne R S.** The management of late diagnosed congenital dislocation and subluxation of the hip-with special reference to femoral shortening. *J Bone Joint Surg Br* 1979 ; 61 (1) : 7-12.
5. **Gabuzda G M, Renshaw T S.** Reduction of congenital dislocation of the hip. *J Bone Joint Surg Am* 1992 ; 74 (4) : 624-31.
6. **Kalamchi A, MacEwen G D.** Avascular necrosis following treatment of congenital dislocation of the hip. *J Bone Joint Surg Am* 1980 ; 62 (6) : 876-88.
7. **Kaneko H, Kitoh H, Mishima K, Matsushita M, Ishiguro N.** Long-term outcome of gradual reduction using overhead traction for developmental dysplasia of the hip over 6 months of age. *J Pediatr Orthop* 2013 ; 33 (6) : 628-34.
8. **Kershaw C J, Ware H E, Pattinson R, Fixsen J A.** Revision of failed open reduction of congenital dislocation of the hip. *J Bone Joint Surg Br* 1993 ; 75 (5) : 744-9.
9. **Kokavec M, Bialik V.** Developmental dysplasia of the hip. Prevention and real incidence. *Bratisl Lek Listy* 2007 ; 108 (6) : 251-4.
10. **Lindstrom J R, Ponseti I V, Wenger D R.** Acetabular development after reduction in congenital dislocation of the hip. *J Bone Joint Surg Am* 1979 ; 61 (1) : 112-8.
11. **Lisle R, Boekelaar M, Stannage K, Whitewood C.** Delayed diagnosis of developmental dislocation of the hip: the Western Australian experience. *ANZ J Surg* 2012 ; 82 (9) : 612-5.
12. **Luhmann S J, Bassett G S, Gordon J E, Schootman M, Schoenecker P L.** Reduction of a dislocation of the hip due to developmental dysplasia. Implications for the need for future surgery. *J Bone Joint Surg Am* 2003 ; 85-A (2) : 239-43.
13. **Luhmann S J, Schoenecker P L, Anderson A M, Bassett G S.** The prognostic importance of the ossific nucleus in the treatment of congenital dysplasia of the hip. *J Bone Joint Surg Am* 1998 ; 80 (12) : 1719-27.
14. **MacLennan A H, MacLennan S C.** Symptom-giving pelvic girdle relaxation of pregnancy, postnatal pelvic joint syndrome and developmental dysplasia of the hip. The Norwegian Association for Women with Pelvic Girdle Relaxation (Landforeningen for Kvinner Med Bekkenlosningsplager). *Acta Obstet Gynecol Scand* 1997 ; 76 (8) : 760-4.
15. **Malvitz T A, Weinstein S L.** Closed reduction for congenital dysplasia of the hip. Functional and radiographic results after an average of thirty years. *J Bone Joint Surg Am* 1994 ; 76 (12) : 1777-92.
16. **Morin C, Bisogno J, Kulkarni S, Morel G.** Treatment of late-presenting developmental dislocation of the hip by progressive orthopaedic reduction and innominate osteotomy. Our results with more than 30 years of follow up. *J Child Orthop* 2011 ; 5 (4) : 251-60.
17. **Ortolani M.** Congenital hip dysplasia in the light of early and very early diagnosis. *Clin Orthop Relat Res* 1976 ; (119) : 6-10.
18. **Pemberton P A.** Pericapsular Osteotomy of the Ilium for Treatment of Congenital Subluxation and Dislocation of the Hip. *J Bone Joint Surg Am* 1965 ; 47 : 65-86.
19. **Roposch A, Stohr K K, Dobson M.** The effect of the femoral head ossific nucleus in the treatment of developmental dysplasia of the hip. A meta-analysis. *J Bone Joint Surg Am* 2009 ; 91 (4) : 911-8.
20. **Rosendahl K, Markestad T, Lie R T.** Ultrasound screening for developmental dysplasia of the hip in the neonate: the effect on treatment rate and prevalence of late cases. *Pediatrics* 1994 ; 94 (1) : 47-52.
21. **Ryan M G, Johnson L O, Quanbeck D S, Minkowitz B.** One-stage treatment of congenital dislocation of the hip in children three to ten years old. Functional and radiographic results. *J Bone Joint Surg Am* 1998 ; 80 (3) : 336-44.
22. **Segal L S, Boal D K, Borthwick L, Clark M W, Localio A R, Schwenker E P.** Avascular necrosis after treatment of DDH: the protective influence of the ossific nucleus. *J Pediatr Orthop* 1999 ; 19 (2) : 177-84.
23. **Severin E.** Contribution to the knowledge of congenital dislocation of the hip joint: late results of closed reduction

- and arthrographic studies of recent cases. *Acta Chir Scand* 1941 ; 84 : 1-142.
24. **Shih C H, Shih H N.** One-stage combined operation of congenital dislocation of the hips in older children. *J Pediatr Orthop* 1988 ; 8 (5) : 535-9.
 25. **Sibinski M, Murnaghan C, Synder M.** The value of preliminary overhead traction in the closed management of DDH. *Int Orthop* 2006 ; 30 (4) : 268-71.
 26. **Terjesen T, Horn J, Gunderson R B.** Fifty-year follow-up of late-detected hip dislocation: clinical and radiographic outcomes for seventy-one patients treated with traction to obtain gradual closed reduction. *J Bone Joint Surg Am* 2014 ; 96 (4) : e28.
 27. **Thomas S R, Wedge J H, Salter R B.** Outcome at forty-five years after open reduction and innominate osteotomy for late-presenting developmental dislocation of the hip. *J Bone Joint Surg Am* 2007 ; 89 (11) : 2341-50.
 28. **Tönnis D.** Congenital dysplasia and dislocation of the hip in children and adults. Springer Berlin Heidelberg, Berlin 1987.
 29. **Wang T M, Wu K W, Shih S F, Huang S C, Kuo K N.** Outcomes of open reduction for developmental dysplasia of the hip: does bilateral dysplasia have a poorer outcome? *J Bone Joint Surg Am* 2013 ; 95 (12) : 1081-6.
 30. **Weiner D S, Hoyt W A, Jr., O'Dell H W.** Congenital dislocation of the hip. The relationship of premanipulation traction and age to avascular necrosis of the femoral head. *J Bone Joint Surg Am* 1977 ; 59 (3) : 306-11.
 31. **Weinstein S L, Ponseti I V.** Congenital dislocation of the hip. *J Bone Joint Surg Am* 1979 ; 61 (1) : 119-24.
 32. **Wirth T, Stratmann L, Hinrichs F.** Evolution of late presenting developmental dysplasia of the hip and associated surgical procedures after 14 years of neonatal ultrasound screening. *J Bone Joint Surg Br* 2004 ; 86 (4) : 585-9.
 33. **Xu M, Gao S, Sun J, Yang Y, Song Y, Han R, et al.** Predictive values for the severity of avascular necrosis from the initial evaluation in closed reduction of developmental dysplasia of the hip. *J Pediatr Orthop B* 2013 ; 22 (3) : 179-83.