



## Patellar instability - An update

Lars BLØND

*From the Zealand University Hospital, Køge, Department of Orthopedics, Arthroscopic Section, Koege, Denmark  
and Aleris-Hamlet Parken Hospital, Copenhagen, Denmark*

**This review is a current concept on the topic of patellofemoral instability purposing to highlight, reflect and in cooperate both recent important findings regarding the patellofemoral joint. In the past decade numerous studies have significantly contributed to our understanding of both the epidemiology, symptomatology and underlying pathomorphology of patella instability. The topic of patella instability is very complex and several biomechanical important factor have been elucidated and consequently treatment strategies are changing. Both non-surgical as well as surgical algorithms are evolving, but still there is a lot of controversies and generally there is lack of consensus. Many different surgical options exist primarily based upon repair what have been torn, or by correcting the underlining pathomorphology. Reconstruction of the medial patellofemoral ligament is the most common surgical procedure, nevertheless in cases with more severe underlining pathomorphologic factors such as trochlear dysplasia, patella alta and increased femoral anteversion, subsequent procedures correcting those abnormalities should be corrected.**

**Keywords :** Patellar instability, Trochlear Dysplasia, Patellofemoral, Trochleoplasty, Medial patellofemoral ligament reconstruction

### INTRODUCTION

This is a current concept, non systematic review, on the topic of patellofemoral (PF) instability purposing to highlight, reflect and in cooperate

*No benefits or funds were received in support of this study  
Contributions: Lars Blønd has done manuscript writing  
and references search. The authors report no conflict of  
interests.*

both recent and old important findings regarding the patellofemoral joint, a field that is evolving very fast, and where there is a huge lack of consensus. The evidence in this medical field is to a large degree based on the combination of anatomy, biomechanics, pathomorphology, epidemiology, cohort studies and case controlled studies, however a number of randomized studies do exist. A computerised literature search was performed on PubMed, ScienceDirect, ISI Web of Knowledge, Google Scholar and Cochrane Central Register using the keywords patella instability, patella dislocation and patellofemoral, and this was giving more than 12.000 publications and here among 1.400 are from the past decade. Nevertheless recent years studies have clearly demonstrated that the cohort of patellofemoral instability patients is inhomogeneous, and consequently most previous randomised studies have compared heterogeneous groups, making the interpretation of those results difficult. This review is not based on Prisma criteria, as this would foreclose some studies that helps to provide a snapshot of where we stand today and the limitation is therefore selection bias and

#### ■ Lars Blønd, MD

*Zealand University Hospital, Køge, Department of  
Orthopedics, Arthroscopic Section, Koege, Denmark*

*Correspondence : Lars Blønd, Zealand University Hospital  
of Køge, Department of Orthopedics, Arthroscopic Section,  
Lykkebaekvej 1, DK-4600 Koege, Denmark*

*E-mail : lars-blond@dadlnet.dk*

*© 2017, Acta Orthopædica Belgica.*

selective reporting within studies. The eligibility criteria is based on a subjective condensation of studies related to new pathomorphologic and biomechanical understanding of the patellofemoral joint. Hopefully this provides a better understanding of this very complex topic and inspires to further studies. The past decades numerous studies have significantly contributed to our understanding of both the symptomatology and pathomorphology of this disorder. Consequently, treatment strategies are luckily changing, because this is a field where patients have experienced non-optimal, repeated surgical procedures and also neglect to do anything. Generally patellofemoral instabilities can be regarded as a continuum, ranging from only anterior knee pain without any symptoms of instability, through subluxations with giving-way sensations, then episodic dislocations, then more severe instability where the patella habitually dislocates with every flexion, and right up to rare cases where the patella is permanently dislocated and never relocates into the trochlear groove. A true patella dislocation is when the patient can report that the kneecap either visibly “popped” out of joint or that it required reduction.

#### *Presence*

The incidence of patella dislocations varies between 2.3 and 77 per 100,000 person-years. The highest incidence is in the age group 15-19 years and among the athletically active - about half of the cases occurs during athletic activity (5,57,75,120,157,185). A family history is present in 9-35% of patients (5,96,162). In about one third of the cases the disorder is bilateral (1). Routine Magnetic Resonance Imaging MRI emergency room scans of swollen knees of patients who had suffered a twisting injury, demonstrated signs that 16% had had patellar dislocation, which indicates that the disorder is under-reported (58). An unknown number of patients with patella redislocations fail for various reasons to see a physician.

#### *Mechanism Of Trauma*

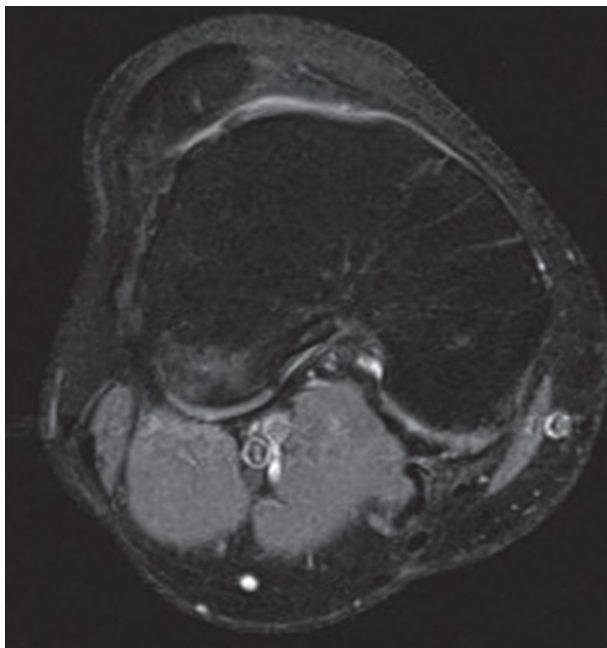
The movement pattern of the patellar dislocation corresponds to the pattern we know from the ante-

rior cruciate ligament injury - a slightly flexed knee combined with slight internal rotation and valgus forces, typically with the foot fixed at the surface (121). In some patients the dislocation event is triggered simply by ordinary everyday activities, such as walking on uneven or slippery surfaces, but most frequently it happens during extraordinarily rapid and unexpected changes of direction during such as in sports (162). In about 7% the dislocation is caused by a direct blunt trauma to the patella (5).

#### *Biomechanics & Risk Factors*

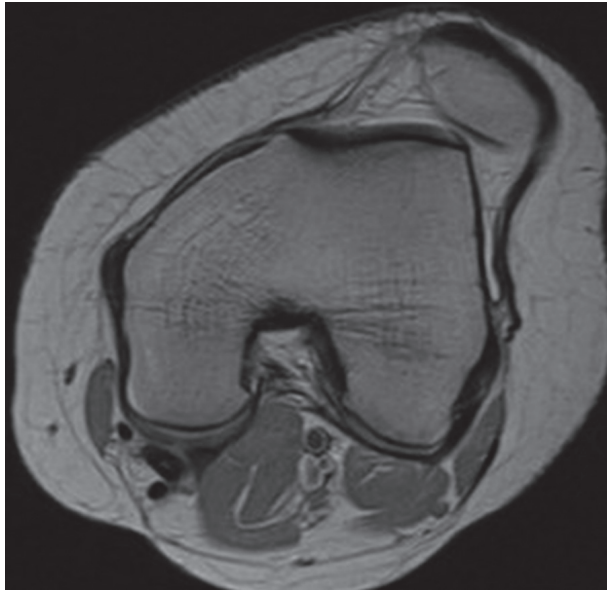The patellofemoral joint is biomechanically one of the most complex of the body's articulations, with osseous, ligamentous and dynamic factors all influencing patellar stability. The cause of PF instability is not fully understood. It appears to be multifactorial, a consequence of abnormalities in both passive and active patellar stabilisers. Recent studies have focused on some of these factors and confirmed that trochlear dysplasia, patella alta, tibia tubercle-trochlear groove distance (TT-TG) and tibial tubercle rotational angle (TTRA) (108) are the ones of most importance (12,31,40,86,91,92,107,118,126,168). Factors such as increased femoral anteversion (42,45,187), increased tibial internal rotation, tibial tubercle-posterior cruciate ligament distance (TT-PCL) and valgus may also be of importance (3,147). Frequently a combination of these predisposing biomechanical factors are present, making it a complex decision to decide which of any abnormalities should be addressed to achieve functional correction. Lewallen et al. (91,92) found a 5-year recurrence of 70 % in patients younger than 25 years having both trochlear dysplasia and patella alta, where it as only 27% in patients without these abnormalities. Looking at age as a factor, the studies showed that the risk of recurrence was decreased by 8% for each additional year of age. Jaquith and Parikh (78) used multivariate analysis and by combining trochlear dysplasia, a history of contralateral dislocation, open physis and severe patella alta, a 88.2 % risk of redislocation was observed. Trochlear dysplasia means a shallow, flat or even a convex groove in the trochlea, resulting in a lack of osseous stability to the patella, probably linked to some hereditary

factors (5,29,37,39,104,109). Today trochlear dysplasia is regarded as the single most important factor for patella instability and the prevalence of trochlear dysplasia is found to be between 35,7% and 96% in patients with patella instability compared to 3-4% among asymptomatics (30,40,86,91,168). Steensen et al. in a retrospective review (168) found trochlear dysplasia was present among 68.3 % of patients having recurrent patella instability and this was seen among 5.8 % in the a control group with no history of patellar dislocation. In a similar study by Jaquith and Parikh (78) among children and adolescents with first time patellar dislocation found a 55.8 % recurrence rate among those having trochlear dysplasia, compared with a 23.5 % recurrence rate among those without trochlear dysplasia. The trochlear dysplasia is mainly seen in the proximal part of trochlea and several authors have classified the abnormal configuration. See figure 1. The first classification by Dejour et al. is based on X-rays. The earlier classification identified three groups, and this was later refined to include four groups (39,173). The Dejour classification has been widely used. However Nelitz et al. (113) and



**Fig. 1.** — Example of a patient troubled by recurrent patella instability and MRI demonstrate severe trochlear dysplasia with a concave trochlear and a lateralized patella.

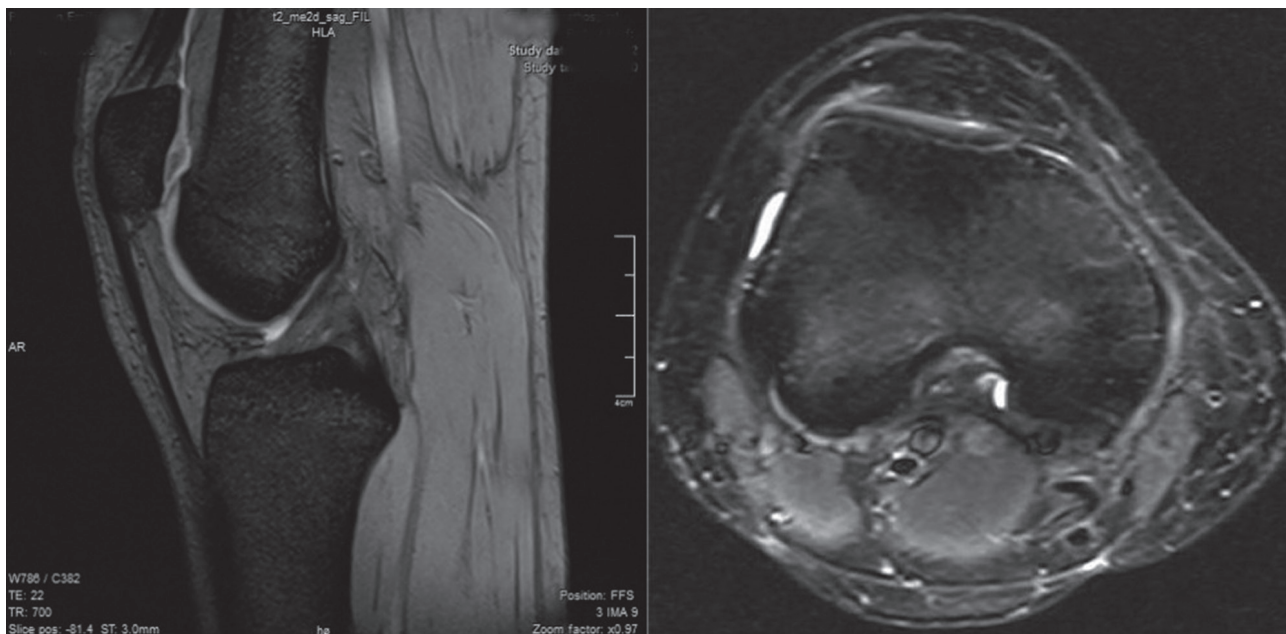
Lippacher et al. (93) found poor relation between objective parameters of trochlear dysplasia and the four grade classification system, but by simplifying the classification to just distinguish between low (Dejour grade A) or high (Dejour grade B,C or D) degrees of trochlear dysplasia, the intraobserver and interobserver agreement were found to be good to excellent. Howell et al. (74) used a 4 group MRI classification with either no dysplasia, a shallow but concave trochlea, a flat trochlea or a convex trochlea. Steensen et al. (168) further simplified this to include only three groups, since he considered that patients with only a slightly shallow groove did not have dysplasia. One of the objective to have a classification system has been the importance of the trochlear bump, presented in Dejour type B and D. Some have advocated to do only trochleplasties in type B or D trochlear dysplasia. In a follow-up study after trochleoplasty by Fucentese et al. (61) found dysplasia types B and D benefited more from surgery than types A and C, while others have not been able to verify this finding. Biedert and Bachmann (16) have found specific characteristics for trochlear dysplasia and based on the type of pathologic configuration they classified the type of dysplasia as either decreased depth in the center of the trochlea and was found in 83 % in their study group or decreased height of the lateral facet found in 17 %. Still there is no consensus of which classification is most specific and reproducible. See figure 2. Patella alta is the second most important biomechanical factor, and since the patella is high-riding it is proximal to the trochlear groove. See figure 3. During knee flexion there is a delay before bony engagement of the patella in the trochlea is achieved, and during this delay lateral forces acting on the patella can make it dislocate. Steensen et al. (168) found using the Insall-Salvati ratio that patella alta was seen among 60.0 % of patients having recurrent patella instability and this was seen among 20.8 % in a control group without dislocations. Lewallen et al. (92) correspondingly found a 47% risk of recurrence after first time patellar dislocation having patella alta. An important message is that trochlear dysplasia as well as patella alta have been associated with development of patellofemoral arthritis (77,79,106,170,171,175).



**Fig. 2.** — Comparable to figure 1, this is an example of a patient troubled by recurrent patella instability and MRI demonstrate trochlear dysplasia. This case demonstrates the difficulties classifying the dysplasia, and to judge when either the trochlea is concave, flat or convex. The bone contour is clearly concave, most of the cartilage part of the trochlea is flat, however the articulation more laterally with the patella is convex.

### *Anatomy & Pathomorphology*

The patella, being a sesamoid bone, is embedded in the patellar tendon (ligament). Its main purpose is to magnify the leverage that the tendon can exert on the femur by increasing the angle at which it acts. When the patella dislocates, the medial ligamentous structures - of which the medial patellofemoral ligament (MPFL) has been identified as the most important, since it accounts for 60 % of the medial restraining forces - are damaged (41,56,80,134). In an anatomical study, Mochizuki et al. (105) demonstrated, contrary to previous assumptions that the MPFL structures only insert on the medial proximal part of the patella, that the ligament has a much more fan like structure. The main fibers often insert into the distal portion of the quadriceps tendon, more specifically on the part belonging to the vastus intermedius. This was later been confirmed by others (62,136). This finding consequently inspired a new surgical technique for reconstruction of the medial restraining structure, now referred to as the medial quadriceps tendon-femoral ligament reconstruction (MQTFL) (62).



**Fig. 3.** — This is both a sagittal view and axial view of the same right knee, demonstrating combined Patella Alta and trochlear dysplasia. The patient was troubled by recurrent patella instability and were successfully treated by arthroscopic deepening trochleoplasty and MPFL reconstruction, alternatively a tibial tubercle distalisation could be considered.

In this technique the most proximal part of the fan shaped medial patellofemoral ligament is reinforced. Sometimes when the patella dislocates and relocates, the shear forces between the patella and the lateral part of the trochlear can cause visible osteochondral damage, and this has been reported in 39 % to 96 % of patients (51,72,120,124,167). In patients with recurrent patellar dislocations, cartilage changes are more pronounced compared to patient with first time patella dislocations (123). The importance of hypermobility for patellar instability is not yet clear and in a study by Smith et al. (162) no increased instability symptoms among the hypermobile were observed. In patients having trochlear dysplasia, a typical finding is increased mobility during the glide test - where the patella is moved from side to side - and this can mistakenly be interpreted as hypermobility. For a long time the importance of femoral internal torsion to anterior knee pain and patellofemoral instability has been underestimated, but the causative relation is getting both more accepted and focused (14,43,116,131,186). Diederichs et al. (45) found a 1.56-fold higher mean femoral anteversion in patients with a history of patellofemoral instability compared with controls. Increased femoral anteversion results in internal rotation of femur distally. The result is increased lateral vector forces acting on the patella relative to the trochlear groove, leading to either patella instability, anterior knee pain or increased wear of the cartilage in the PF joint. Increased femoral anteversion results in internal rotation of the femur distally. The result is increased lateral vector forces acting on the patella relative to the trochlear groove, leading to either patella instability, anterior knee pain or increased wear of the cartilage in the PF joint. The increased anteversion of the femur is sometimes combined with external rotation of the tibia, termed miserable malalignment syndrome (23,131). It is important to notice that Staheli (166) found that anteversion is gradually reduced from childhood to adult. The importance of patellar morphology and patella tilt is debatable and the differences between the normal population and patients having patellar instability, could be a consequence of different morphology of the trochlear configuration. In the normal population, a Wiberg type A patella is

present in 16.1% of subjects, a type B in 80% and a type C in 12.9% (148). In a case series of patients with objective patellar instability, type A patella was present in 15.7% of cases, type B in 60.7% and type C in 23.6% of cases and also patellar shape type C was found more frequent in knees with trochlear dysplasia (130). Fucentese et al. (60) investigated patellar morphology in trochlear dysplasia, and the key morphologic change of the patella was a decreased medial facet length. Correspondingly Panni et al. (130) found significantly more Wiberg type C patella in patients with underlying trochlear dysplasia. Patellar tilt is influenced by different factors depending whether it is measured in static or dynamic conditions. When the quadriceps is relaxed, the tilt results from the bony surfaces morphology. Nove-Josserand et al. (125) demonstrated that the more severe the trochlear dysplasia, the greater the patellar tilt.

#### *History & Physical Examination*

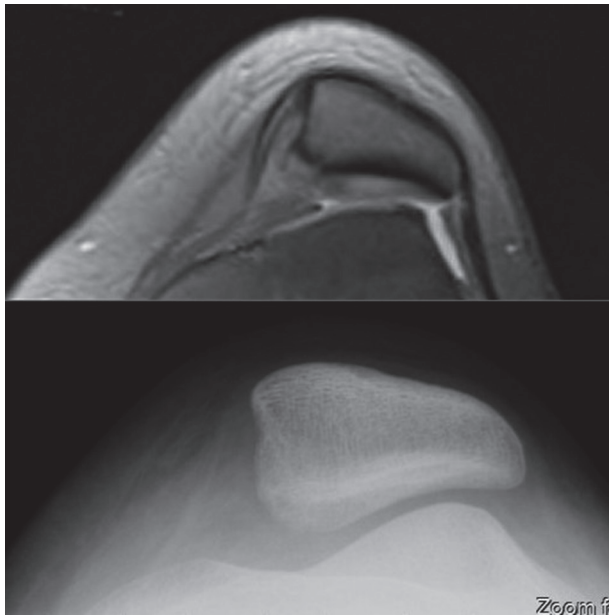
Some patients clearly describe that the 'kneecap jumps out its socket', while others simply feel that the knee fails without being able to relate it to any looseness of the patella. When a dislocation occurs, some patients need help to reduce the patella either locally or at an emergency department. In other cases patients manages to bump the patella while extending the knee, and thereby the patella goes back in place, with a spontaneous repositioning eventually occurring with a 'clunk'. First-time patellar dislocation is followed by acute pain, swelling of the knee and effusion, but in more chronic cases this is not necessarily the case. A typical finding is tenderness of medial structures and regularly there is also tenderness lateral to the patella. Even in the absence of recurrent instability, patients who sustain a patellar dislocation, or even subluxations, may develop a number of significant problems, including persistent knee pain, functional limitation, decreased athletic performance, and typically they avoid torsional activities (162). The direction of the patellofemoral instability is almost always lateral, although rare cases of medial dislocation have been reported to occur secondary to iatrogenic causes (143). Assessment of the knee in the chronic patellar

dislocator is typically performed in a quieter phase. Examination should include standing, walking, sitting with the knee bent, and lying down. A large number of tests exist (90,161,181). In a clinical trial of ten patellar-unstable knees assessed by five members of the International Patellofemoral Study Group, poor inter-observer reliability was found for the majority of the physical tests, with only the assessments of patellofemoral crepitus, foot arch position and the J-sign achieving fair to moderate agreement (159). The most commonly used test is the patella apprehension test, where the patella is gently passively lateralised by placing the thumb on the medial patella facet with the knee resting in extension. The test is considered positive if the patient resists the action by contracting the quadriceps, and/or recognises the feeling that the patella is going out. The test is repeated in different degrees of flexion, and notice is paid to the angle at which the patella is stabilised by the trochlea (159). In some severe cases of instability, the examiner is not able to keep the patella contained in the trochlear groove while the patient actively contracts the quadriceps. This indicates that some major lateral vector forces are affecting the tracking. In these severe cases it is mandatory for the surgery to be based on the anatomical abnormalities, accepting that an isolated MPFL reconstruction will not provide long lasting stability unless the bony abnormalities are simultaneously corrected. Q-angle has previously been used frequently in the evaluation of the patella, but lately inconsistency has been highlighted regarding the correlation between the Q-angle and the TT-TG distance (36,43,95,150). Patella alta might be noticed by inspection. If the patient sits and bends the knee to 90 degrees, a so called camel-sign may be observed, since the Hoffa fat pad and the patella are both protruding. With the patient in a prone position, the greater trochanter is palpated in its most lateral position, which reflects a horizontal femoral neck axis. With the knee bent to 90 degrees, the angle between the longitudinal axis of the leg and a vertical line represents femoral torsion (140). Several scoring systems are regularly used in articles to interpret the results after patellar stabilising procedures (107). The most popular is the Kujala score (85) developed in a mixed group of patients with patellofemoral problems. Lately

two new patient-related scoring systems specific to patellar instability have been published, and offer us instruments to build greater scientific soundness for comparison of different treatments. The Norwich score is a self-administered 19-item questionnaire to assess perceived patellar instability (163). The Banff Patella Instability Instrument is a 31-item questionnaire developed and validated using the COSMIN guidelines (68). Those questionnaire can also advantageously be used by the surgeon to evaluate the level of discomfort the patient experience.

### *Imaging*

Traditionally X-rays have been used for assessing the patella, and many measurements have been based on X-rays. However, today Computer Tomography (CT) scans and MRI scans have supplanted many of these, and new measurements are taking over. X-rays, however, can still be useful. This applies to the assessment of acute patellar dislocation, where anteroposterior, lateral and axial views still are recommended for detecting osteochondral fractures and for trochlear dysplasia screening. The Merchant view - also called the tangential view, axial view, skyline view or sunrise view - has been very popular for evaluation of the patellofemoral joint. However, since the recording is done in 30-45 degrees of flexion the more distal part of the trochlear groove is visualized, and it is therefore not a sufficient screening tool for trochlear dysplasia, since subtle patellar tracking abnormalities are localized to the first 0-30 degrees of knee flexion (142). See figure 4. The tangential view together with the lateral view can be used for evaluation of patellar configuration and patella tilt (48). The lateral view is an effective screening tool for trochlear dysplasia (63). Ultrasound scans can also be advantageously used to detect trochlear dysplasia (119,178). See figure 5. The presence or exclusion of trochlear dysplasia is important for its prognostic value (91,92). MRI gives the most reliable evaluation of the patellofemoral joint and today, operative planning for patella instability should not be based on clinical examination only, but should include the pathoanatomic findings from MRI and/or CT scans. In the more subacute

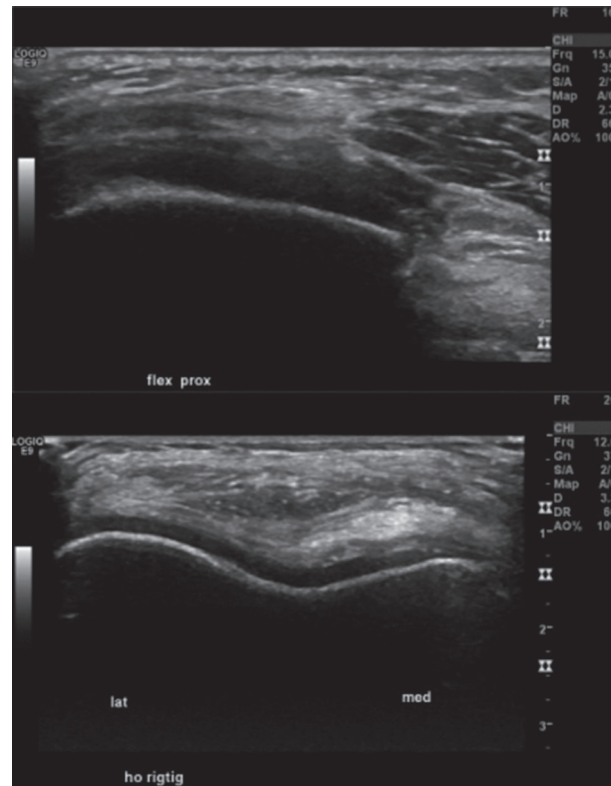


**Fig. 4.** — This illustrate X-ray skyline view and MRI of the same knee. The x-ray seems to demonstrate no trochlear dysplasia, contrary to the MRI finding trochlear dysplasia.

setting, the typical MRI findings following a patella dislocation include bone oedema in the anterolateral part of the lateral condyle and at the medial patella site, and also eventual tears of the medial stabilisers can be localized (31,44,52,65,141).

Radiology in relation to patellar instability has developed considerably over the past decade. In a study by Charles et al. (31) a large number of well known radiologic parameters were found to be significantly different between those with recurrent patellar instability and normal knees. Among many described radiological parameters the following have been found to be of increasing importance:

Galland et al. (63) called it the gradient of the lateral slope, the one that Carrillon et al. (28) later defined as the lateral trochlear inclination angle which is the angle formed between the plane of the lateral trochlear facet subchondral bone and a tangential line through the posterior femoral condyles, and considered an angle of less than 11 degrees as indicative for trochlear dysplasia. The angle indirectly express how much stability the lateral trochlea facet provides to the patella and has been suggested as the single most important biomechanical index associated with trochlear

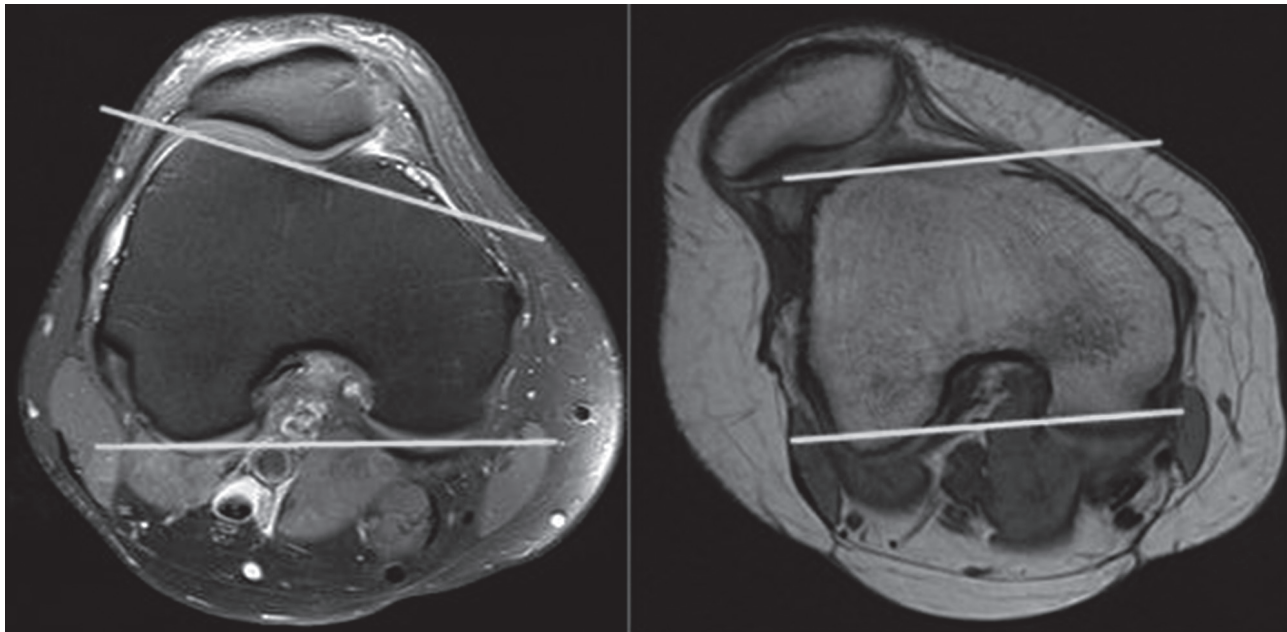


**Fig. 5.** — Example of a patient troubled by recurrent patella instability and having trochlear dysplasia. Ultrasound examination before and after arthroscopic deepening trochleoplasty. See figure 9.

dysplasia (49), since it is very closely related to the osseous stability. See figure 6.

Trochlea asymmetry is a relative new measurement that has helped to explain the pathology behind trochlear dysplasia and explain how TT-TG distance is influenced. The asymmetry is the ratio of medial trochlear facet width to lateral trochlear facet width and measured in the axial plane. A ratio of less than 0.4 is considered abnormal and indicates trochlear dysplasia (135).

Anterior posterior measurements as a method to depict between heightened trochlear floor or decreased inclination of the lateral facet of the trochlea is another important way to describe trochlear dysplasia (16). The trochlear depth can also be measured on true lateral x-rays as described by Malghem and Maldague (99) and by MRI as described by Pfirrmann et al. (135). A depth less than 3 mm is considered to be trochlear dysplasia.



**Fig. 6.** — MRI demonstrating both a knee without patella instability at left, with a normal lateral trochlear inclination angle at approximately 18 degrees, and at right a knee with patella instability and a low trochlear inclination angle at approximately -1 degree.

Biedert et al. (16) presented the central height and defined it as the lowest point of the trochlea compared to the width of the femoral condyle and expressed as a percentage of the width. They also defined the medial condyle height as the height of the medial condyle compared to the width of the femoral condyle and expressed as a percentage of the width. This depicted and differentiated two types of trochlear dysplasia: Increased height in the center, and decreased inclination of the lateral facet of the trochlea.

The sulcus angle was originally defined by Brattstrom on X-rays. This is the angle formed by the intersection of the medial and lateral trochlear facets in the transverse plane (22), and since then it has been widely used as a measurement for the geometry of the trochlea. The sulcus angle decreases from proximal to distal (59,101) and also the angle diverges between cartilage or bone (152), and through the literature various measurement methods have been used on CT scans and MRI scans, but no consensus exists. These aspects makes comparison between different studies difficult.

Patella alta can be evaluated via X-rays, MRI and CT scans, and several methods exist. The

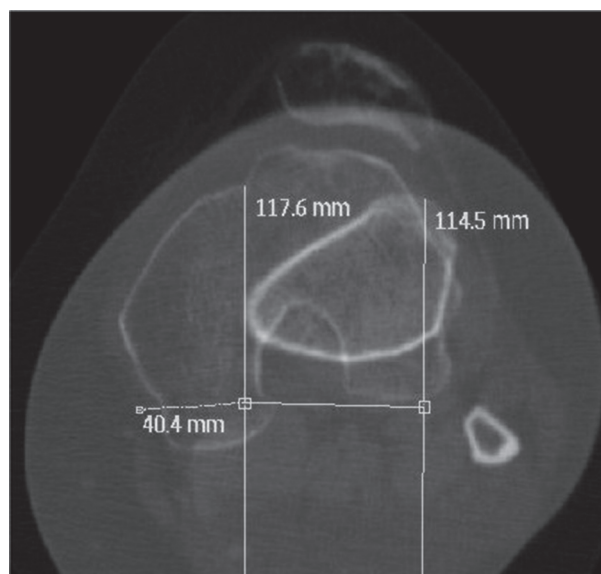
most widely used are the Insall-Salvati ratio (76) or the Caton-Dechamps index (30), and if those are more than 1.2 this characterises patella alta. The patellotrochlea index described by Biedert and Albrecht (15), is strongly recommended to determine the presence of alta, as it is the only measure that is representative of the true pathoanatomical problem, describing the position of the articular surface of the patella in relation to the trochlear cartilage. If the overlap is less than 12.5% having the knee in 0 degrees of flexion, this is considered as patella alta., and when the knee is flexed the overlap increases the TT-TG distance is for many surgeons a popular measurement, and have been used to guide tibial turbercle osteotomy, especially if the distance is higher than a threshold of 20 mm. The TT-TG is assessed on axial views using either CT scans (141) or MRI scans with superimposed cuts between the most anterior point of the tibial tuberosity and through the proximal trochlea. It is defined by Dejour et al. (40) as the first cut with cartilage, identified by a slight condensation of the lateral facet and by the shape of the notch, which is rounded and looks like a Roman arch. It is called the “reference cut.” In most recent studies. TT-TG



distance is measured on axial MRI-sequences using cartilaginous landmarks at the most proximal appearance of the trochlear groove (6,7,44,46,49,179) or where the groove is the deepest (26,144). Tscholl et al. (179) found that the further distal the femoral reference point chosen on the trochlear groove, the smaller the TT-TG becomes, since the trochlear groove is not perpendicular to mechanical leg axis. For the tuberosity tibia measurement the slice that depict a complete attachment of the patellar tendon slightly cranial to the tuberositas tibiae is normally used (49,144). Therefore to compare different findings of the TT-TG, it is important to notice what measurement method has been used in the study design. An abnormal TT-TG distance can be caused by a lateralization of the tibial tubercle, a medialised trochlear groove and an excessive tibial external rotation. Tensho et al. (176) found in a group of patients with patella dislocation that increased TT-TG distance was significantly correlated to knee rotation angle and tibia tubercle lateralisation. It is important to remember that when the trochlear groove is medialized as seen in trochlear dysplasia (trochlear asymmetry), the TT-TG distance is subsequently increased. Nevertheless no studies has tried to divide the group of patients having increased TT-TG distance into either trochlear dysplasia or tibial rotational defects. Steensen et al. (168) found among 41.7 % of patients having recurrent patella instability a TT-TG distance above 20 mm and in the control group of patients without patella instability only 3.3 % had a TT-TG distance above 20 mm. They did not analyze if those patients having increased TT-TG had this as a result of trochlear asymmetry. Some other factors have to be taken into account evaluating the TT-TG distance, and for example Hingelbaum et al. (70) have found it important to correct for knee size. Others have documented that the TT-TG distance decreases with light flexion, based on the screw-home mechanism of the knee (46,172) and imaging at 0° of extension is only achieved with specific knee coils that are larger than standard knee coils (179). Measurement tools, such as the Tibial Tubercle Rotation Angle (TTRA) as defined by Muneta et al. (108) or the Tibia Tubercle to posterior tubercle distance

TT-PCL as defined by Seitlinger et al, (147) more specifically define the degree of external placement of the tibial tubercle (3,67). See figure 7.

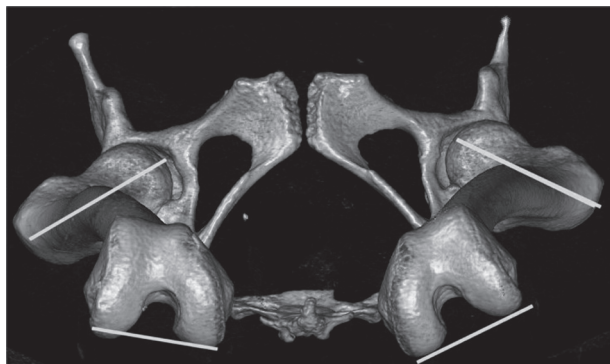
In cases with clinical suspicion of rotational deformities, the angle of femoral anteversion should be evaluated on either CT or MRI. This is the angle between the condylar axis and the axis of the femoral neck. Although several methods exist, the method using a line parallel to the posterior femoral condyles is regarded as the standard method (42,45,50,131). As the standard deviation from the normal value (24°) is 17°, the CT scan alone cannot be used to decide about performing a torsional femoral osteotomy. See figure 8. Knee torsion is measured by superimposition of a line along the posterior cortex of the proximal tibia section on the



**Fig. 7** — This CT scan demonstrate a right knee with a pathologic TT-TG distance measuring 40.4 mm. The question is to what degree the increased TT-TG distance is caused by either the trochlear asymmetry in relation to trochlear dysplasia, or by external rotation of the tibial turbecele.

posterior condylar axes on the distal femur section, while tibia rotation is the the angle between the proximal and distal tibia (45,131).

Patella tilt refers to the abnormal position of the patella in relation to the trochlear groove and is the result of a complex interplay of factors,



**Fig. 8.** — This is a 3D reconstruction of both femurs having left site recurrent patella instability. The CT scan demonstrate rotational abnormality in the left femur, with increased angle between the axis of the femoral neck and the distal femur (defined as a line parallel to the most posterior part of the medial and lateral femur condyles).

including trochlear and patellar shape, medial restraint insufficiency and lateral retinaculum tightness. The most important factor seems to be trochlear dysplasia, where the articulation often only includes the lateral patella facet. Patellar tilt is measured with or without quadriceps contraction on axial CT or MRI scans, and it is the angle formed by the transverse axis of the patella and a tangent to the posterior femoral condyles. Values of above 20 degrees are considered abnormal (141).

The patella instability severity score is a rating system that evaluates risk factors such as age, bilateral problems and radiologic findings and thereby gives an initial risk assessment for recurrent patellar dislocation (8).

#### *Non-Operative Treatment*

First time patellar dislocators do not usually require surgical intervention, unless there is a significant osteochondral lesion. However, as mentioned previously, Lewallen et al. (92) and Jaquith and Parikh (78) found that the risk of redislocations in patients with open epiphyses having trochlear dysplasia was approximately 70%, and this high risk challenges the general agreement that first time dislocators should always be treated conservatively (92) or if early surgical intervention should be considered. A stabilizing

brace for 2-6 weeks, and full weight bearing, may promote healing of the medial ligamentous structures, but evidence for bracing is lacking (97). Once the acute inflammation has subsided, physical therapy can be helpful to reduce swelling, improve range of motion and muscle strength, stabilise patellofemoral tracking, regain proprioception of the knee, and normalise the gait pattern. However the evidence is lacking that physiotherapy prevents recurrence (158,160). The reported rate of redislocation after first time patellar dislocation varies from 14% to 44% (24,34,66,122,153). However some patients without redislocations continue to have symptoms of instability (91,97). For those patients troubled by recurrent patellar instability, a rehabilitation program consisting of some months of physiotherapy, guided exercises for the quadriceps and gluteus muscles, core stability, balance training, and eventually including stabilising tape and neuromuscular electrical stimulation, should be tried. Patellar stabilising braces are frequently used as an adjunct to rehabilitation, and an unknown number of patients describe as positive either a mechanical or a psychological effect, though some may still experience dislocation wearing a brace (2). Becher et al. (10) demonstrated improvements of several radiographic parameters by using a dynamic realignment patella brace in patient troubled by patellofemoral instability.

#### *Operative Treatment*

In a meta-analysis focusing on various non-operative treatments versus various operative treatments in first time patellar dislocators, a significantly reduced rate of recurrence was found, but for those operated upon a significantly increased risk of osteoarthritis was observed (164). Two randomised studies have found significant superiority of reconstruction of the MPFL in terms of less recurrence and better Kujala score compared to conservative treatment (17,25). None of those studies comparing non-operative versus operative treatment have tried to take account for predisposing factors. In a recent review from Song et al. (165) comparing surgical methods they have

by excluding those with predisposing factors wisely avoided confounding factors.

#### *Medial Implication/Reefing/Duplication/Augmentation*

The surgery consists of tightening, plication or augmentation of the ligamentous structures medial to the patella. Lee et al. (89) demonstrated good long time results after combined medial plication and lateral release with a redislocation rate at 10 % after having excluded those with predisposing factors. Three randomized trials have found no superiority of this surgical technique compared to conservative treatment (122,129,155). In a comprehensive systematic review by Song et al. (165) patients with predisposing factors were excluded, and medial implication equalised reconstruction of the MPFL, in respect to rate of redislocation and Kujala score gain.

#### *Reinsertion Of The Medial Patellofemoral Ligament*

A randomised study comparing reinsertion of the MPFL ligament at its femoral insertion site found no superiority of this surgical technique for reducing the rate of recurrence compared to conservative treatment (32) and a retrospective study has confirmed the high recurrence rate (4).

#### *Lateral Release/Lengthening*

In this procedure the lateral retinaculum is released, or better lengthened, as demonstrated in a double-blind randomised study comparing the two open techniques (128). The lateral lengthening, the idea of which is to reduce the lateral forces acting on the patella, is a recognised procedure for lateral patellar hyperpressure syndrome (114). A biomechanical study has demonstrated a significant reduction of patella stability following the lateral release. The procedure has no role as an isolated method for the stabilisation of the patella, but can be used as an adjunct procedure to other stabilising procedures in selected cases (33,88).

#### *Medialisation Of The Tibial Tubercle*

In this procedure the tibial tubercle is moved medially, and thereby the lateral vector forces on the

patella are reduced, and the tibial tubercle rotational angle (TTRA) is normalized and the tibia tubercle - trochlear groove (TT-TG) distance is reduced. The operation comes in several varieties, with the most common including the Elmslie-Trillat, Fulkerson, Roux-Goldthwait and Hauser procedures.

The success rate in terms of instability and functional outcome is well documented, but for the long term outcome there seems to be declining results in the second decade with pain and osteoarthritis in more than 50% of the cases and a number of patients continues to have instability symptoms (27,110,111,154,183). Payne et al. (133) found, in a systematic review of 19 studies of tibial tubercle osteotomy, a complication rate of 4.6%. The most devastating complication was nonunion of the osteotomy site, and this was seen more frequently in procedures where the tibial tubercle was completely detached. The tibial tubercle osteotomies had previously been used without specific notice of any anatomical findings, and this could theoretically explain unsatisfactory long-term results. Using a more pathoanatomic approach with a rigorous selection of patients having a TT-TG distance above 15 mm, good results have been demonstrated by Tecklenburg et al. in a 38 month follow-up and by Koëter et al. in a 24 month follow-up (84,174). In cases with a TT-TG distance above 20 mm, medialisation of the tibial tubercle should be considered, although if the abnormality is caused by a trochlear asymmetry as part of trochlear dysplasia, then a deepening trochleoplasty should be considered. It is difficult to balance a tennis ball on a football (citation Simon Donell).

#### *Distalisation Of The Patella*

In cases where patella alta is the main pathomorphology for the instability, a distalisation of the tibial tubercle or the ligamentum patellae [patellar tendon] can correct the biomechanical abnormality by bringing the patella earlier into the trochlear groove, and thereby normalising the osseous stability. In a systematic review of distalisation procedures in patients having recurrent patellar instability and patella alta, satisfactory outcomes following distalisation was found (98).

Benoit et al. (11) found excellent results in a 13.5 year follow-up of eight young patients with a mean age of 10.3 years. Others have confirmed these satisfactory results in medium-term follow-up (100,102,137). Mayer et al. (102) included patellar tendon tenodesis in order to reduce the increased mobility in the coronal plane, caused by the long patellar tendon length. Caution against over-correcting when performing a distalisation should be emphasised, since this can result in a patella baja that eventually leads to pain. Fabricant et al found that reconstruction of the medial patellofemoral ligament itself significantly reduced the patella height, meaning that in mild cases of patella alta no additionally distalisation of the tibial tubercle may be needed (54). Moreover if the distalisation is combined with reconstruction of the medial patellofemoral ligament, the risk of overcorrection may be increased compared to distalisation only.

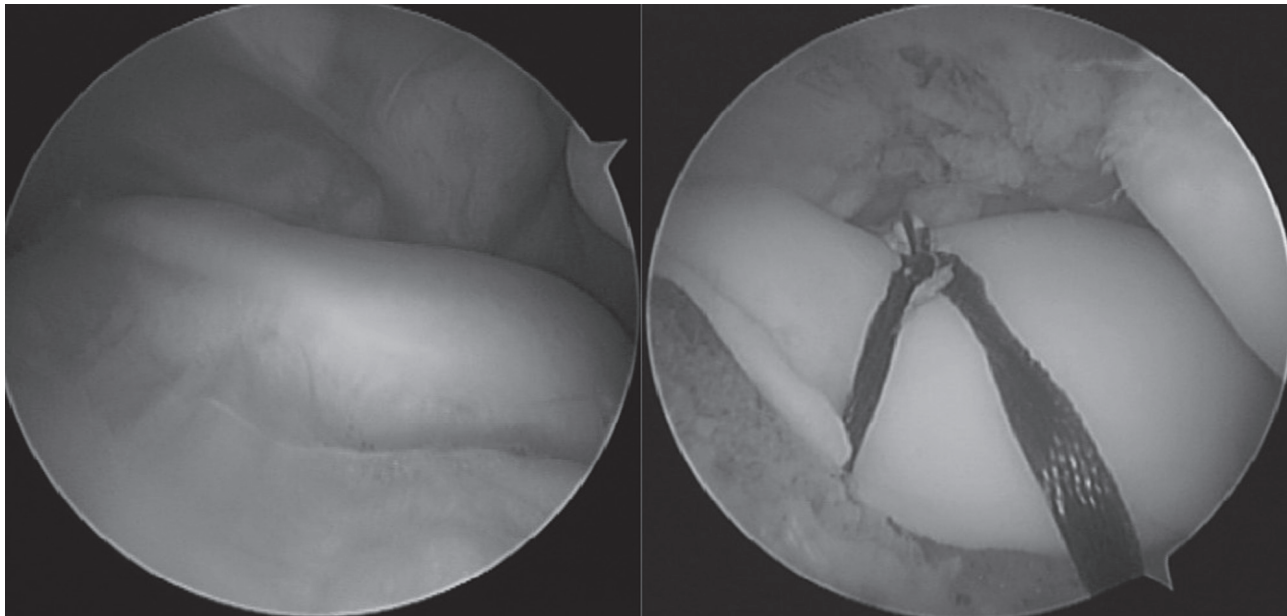
#### *Reconstruction Of The Medial Ligamentous Structures*

The purpose of these reconstruction procedures is to reinforce the medial ligaments - the MPFL (medial patello-femoral ligament), the MQTFL (medial quadriceps tendon-femoral ligament) or the MPTL (medial patellotibial ligament) - and thereby provide ligamentous stability to the patella. Today, MPFL reconstructions are perhaps the most common stabilising procedure for the unstable patella but, as explained below, it is not a panacea for all patellar instabilities. Single- and double-bundle techniques and several types of graft material have been used - autologous gracilis-tendon, semitendinosus-tendon, quadriceps-tendon or adductor-tendon, and, as an alternative, also allograft or synthetic material (145,156,169,188) and no techniques is considered to represent the golden standard. Short- and long-term results after MPFL reconstruction are satisfactory in terms of both stability and functionality (53,74,94). Shah et al. found in a review a complication rate of 26.1 % after the procedure, with stiffness as the most common complication, followed by re-dislocation, anterior knee pain and patellar fracture (132,149). Enderlein et al. (53) found, in a group of 240

patients undergoing MPFL reconstruction, that 30% were having pain at the medial epicondyle, and 43% were still experiencing subluxations or re-dislocation. In patients with more pronounced trochlear dysplasia, less satisfactory results have been observed. Wagner et al. (184) observed no significant outcome improvement after MPFL reconstruction among those with severe trochlear dysplasia. Similarly, Hopper et al. (73) observed a 100% re-dislocation rate in his subgroup of patients with recurrent patellar dislocation. Kita et al. (81) observed that severe trochlear dysplasia was the most important predictor of residual patellofemoral instability after isolated MPFL reconstruction. Interestingly, Howell et al reported excellent results in a case series of 219 knees having MPFL reconstructions, perhaps based on the fact that patients with severe trochlear dysplasia and patella alta were excluded since they had different surgery. In patients with open growth plates the drilling of the femur bone tunnels can potentially damage the physis and studies have demonstrated that going distally from the physis is reasonably safe (64,80,87,112,151). As an alternative to a bone fixation a soft tissue fixation can be used.

#### *Trochleoplasty*

Patellofemoral instabilities arising from trochlea dysplasia are increasingly treated with a surgical technique aimed at restoring normal anatomy (69). Today, when talking about trochleoplasty techniques, it is mostly the deepening trochleoplasty that is referred to, while elevating trochleoplasty is considered more or less obsolete, since the pressure in the patellofemoral joint increases, followed by pain and secondary arthritis. Several techniques have been described and currently the most common techniques are the ones from Dejour and Bereiter. However, the arthroscopic trochleoplasty, a less invasive variant from the Bereiter technique, is getting increasingly more widespread (18-21,39,103,117,127). See Figure 9. In general, all of these techniques unload the compressive forces in the patellofemoral joint, and re-establish osseous stability to the patella. With the trochleoplasty procedure the new groove can be



**Fig. 9.** — This example demonstrate a left knee before and after arthroscopic deepening trochleoplasty. Same knee examined by ultrasound in figure 5.

lateralised 5-10 mm, wherein the TT-TG distance is reduced proportionally (24,126,146). Recent studies have supplemented the trochleoplasty with reconstruction of the MPFL, since this adds stability from extension to the first degrees of flexion until the patella has engaged the trochlea (9,19,114,115,117,126). Today nearly 20 case series of trochleoplasty have demonstrated good short to midterms results with high knee scores and rates of redislocation close to zero (9,19,38,47,82, 83,115,117,127,138,139,146,177,180,182). One concern has been lack of healing of the trochlea cartilage, but yet no reports on this. Next concerns has been raised for long term consequences of trochleoplasty for development of arthritis, and a study from Rouanet et al. (139) with a mean follow-up at 15 years found that 53% of patients experienced occasional pain and 20 cases out of 34 cases had > Iwano 2 radiographic osteoarthritis. What has to be taken in to account is that trochlear dysplasia it selves predispose to arthritis (171,175) and furthermore 17 patients in that study had additional tibial tubercle osteotomies, a procedure that is also recognized to be associated with arthritis (27,55,110). So to what degree these to opposite factors contribute to the development of arthritis

should be further elucidated by prospective studies. Degenerative cartilage changes in the trochlea, have been considered as a contraindication for the trochleoplasty procedure. However Neumann et al. (117) found significantly improvement in knee scores after combined trochleoplasty and MPFL surgery and the results for the subgroup containing 17 patients having preoperatively degenerative changes in the trochlea, where equivalent to the group of patients without degenerative changes. In rare trochleoplasty cases, due to a flatt patella a subsequent patella closing wedge osteotomy may be needed in order to achieve congruency (83).

#### *Rotational Osteotomies*

For a long time, the importance of femoral internal torsion to anterior knee pain and patellofemoral instability has been underestimated, but the causative relation is getting more accepted. Increased femoral anteversion leads to an internally rotated gait unless compensated by external torsion of the tibia, which rotates the leg outward to maintain a normal foot progression angle. In the knee, increased femoral internal torsion results in abnormal patellofemoral loads. In a few case series and surgical techniques

papers excellent results have been reported by performing derotational distal external femoral osteotomies eventually in combination with internal tibia osteotomy or reconstruction of the medial patellofemoral ligaments (13,23,35,42,71,116,131).

### CONCLUSION

In the past decade, many studies focusing on anatomy, biomechanics, pathomorphology, symptoms, and imaging techniques have contributed to the understanding of patellar instability. The conservative treatment approach for first time patellar dislocators has been challenged by two randomised studies favoring MPFL reconstruction. Screening first time patellar dislocation patients for trochlear dysplasia, patella alta and increased TT-TG distance can help predict the risk of re-dislocation and help to separate out those who should be treated conservatively from those who should have surgery. Experiencing patellar subluxations or recurrent patella dislocation often results in significant reduced quality of life, and operative intervention should be considered if physiotherapy-guided knee stabilising training has failed. Algorithms for surgical intervention should respect the pathomorphology revealed by MRI, and normalisation of biomechanical abnormalities must be considered. Both new radiologic parameters to interpret biomechanical factors for patellar instability, as well as new patient-related outcome measures to evaluate different surgical procedures, are important in optimising future surgical strategies. Trochlear dysplasia has been recognized as having major importance, and trochleoplasty procedures have become increasingly popular, but more longer duration follow-up studies are needed. Today the most widespread solution for recurrent patellar instability is reconstruction of the medial ligamentous stabilisers, and excellent results can be achieved, but medial patellofemoral ligament reconstruction are not a panacea for every patella instability and severe bony abnormalities must be look for and concomitantly corrected. Future studies must strive for higher levels of evidence, with randomised studies respecting the inhomogeneity of the patellofemoral instability. The goal is that all patients from the start to have the optimal long lasting treatment that ensures both a high level of

activity with no pain, meaning that those who needs surgery only should be operated once.

*Acknowledgement:*

*The author wants to thank Dr Sheila Strover for proof reading the paper.*

### REFERENCES

1. **Andersen PT.** Thesis: Luxatio Patellae (Danish) English summary. 1955
2. **Andrish J.** The management of recurrent patellar dislocation. *Orthop Clin North Am* 2008 ; 39 : 313-327, vi.
3. **Anley CM, Morris G V., Saithna A et al.** Defining the Role of the Tibial Tubercle-Trochlear Groove and Tibial Tubercle-Posterior Cruciate Ligament Distances in the Work-up of Patients With Patellofemoral Disorders. *Am J Sports Med* 2015 ; 43 : 1348-1353.
4. **Arendt E a, Moeller A, Agel J.** Clinical outcomes of medial patellofemoral ligament repair in recurrent (chronic) lateral patella dislocations. *Knee Surg Sports Traumatol Arthrosc* 2011 ; 19 : 1909-1914.
5. **Atkin DM, Fithian DC, Marangi KS et al.** Characteristics of patients with primary acute lateral patellar dislocation and their recovery within the first 6 months of injury. *Am J Sports Med* 2000 ; 28 : 472-479.
6. **Balcarek P, Jung K, Ammon J et al.** Anatomy of lateral patellar instability: trochlear dysplasia and tibial tubercle-trochlear groove distance is more pronounced in women who dislocate the patella. *Am J Sports Med* 2010 ; 38 : 2320-2327.
7. **Balcarek P, Jung K, Frosch K-H et al.** Value of the tibial tuberosity-trochlear groove distance in patellar instability in the young athlete. *Am J Sports Med* 2011 ; 39 : 1756-1761.
8. **Balcarek P, Oberthür S, Hopfensitz S et al.** Which patellae are likely to redislocate? *Knee Surg Sports Traumatol Arthrosc* 2013 ;
9. **Banke IJ, Kohn LM, Meidinger G et al.** Combined trochleoplasty and MPFL reconstruction for treatment of chronic patellofemoral instability: a prospective minimum 2-year follow-up study. *Knee Surg Sports Traumatol Arthrosc* 2014 ; 22 : 2591-2598.
10. **Becher C, Schumacher T, Fleischer B et al.** The effects of a dynamic patellar realignment brace on disease determinants for patellofemoral instability in the upright weight-bearing condition. *J Orthop Surg Res* 2015 ; 10 : 126.
11. **Benoit B, Laflamme GY, Laflamme GH et al.** Long-term outcome of surgically-treated habitual patellar dislocation in children with coexistent patella alta. Minimum follow-up of 11 years. *J Bone Joint Surg Br* 2007 ; 89 : 1172-1177.

12. **Bereiter H, Gautier E.** Die Trochleoplastik als Chirurgische Therapie der Rezidierenden Patellaluxation bei Trochleadysplasie. *Arthroscopie* 1994 ; 7 : 281-286.
13. **Biedert R, Sigg A, Gal I et al.** 3D representation of the surface topography of normal and dysplastic trochlea using MRI. *Knee* 2011 ; 18 : 340-346.
14. **Biedert RM.** Osteotomies. *Orthopade* 2008 ; 37 : 872-883.
15. **Biedert RM, Albrecht S.** The patellotrochlear index: a new index for assessing patellar height. *Knee Surg Sports Traumatol Arthrosc* 2006 ; 14 : 707-712.
16. **Biedert RM, Bachmann M.** Anterior-posterior trochlear measurements of normal and dysplastic trochlea by axial magnetic resonance imaging. *Knee Surg Sports Traumatol Arthrosc* 2009 ; 17 : 1225-1230.
17. **Bitar AC, Demange MK, D'Elia CO et al.** Traumatic patellar dislocation: nonoperative treatment compared with MPFL reconstruction using patellar tendon. *Am J Sports Med* 2012 ; 40 : 114-122.
18. **Blønd L.** Arthroscopic Deepening Trochleoplasty: The Technique. *Oper Tech Sports Med* 2015 ; 23 : 136-142.
19. **Blønd L, Haugegaard M.** Combined arthroscopic deepening trochleoplasty and reconstruction of the medial patellofemoral ligament for patients with recurrent patella dislocation and trochlear dysplasia. *Knee Surg Sports Traumatol Arthrosc* 2014 ; 22 : 2484-2490.
20. **Blønd L, Schöttle PB.** The arthroscopic deepening trochleoplasty. *Knee Surg Sports Traumatol Arthrosc* 2010 ; 18 : 480-485.
21. **Blønd L, Schöttle PB.** Arthroscopic Deepening Trochleoplasty. In: Zaffagnini S, Dejour D, Arendt E, eds. *Patellofemoral Pain, Instability, and Arthritis*. 2010; 233-237
22. **Brattström H.** Shape of the Intercondylar Groove Normally and in Recurrent Dislocation of Patella: A Clinical and X-Ray Anatomical Investigation. *Acta Orthopaedica* 1964 ; 35 : 1-148.
23. **Bruce WD, Stevens PM.** Surgical correction of miserable malalignment syndrome. *J Pediatr Orthop* 2004 ; 24 : 392-396.
24. **Buchner M, Baudendistel B, Sabo D et al.** Acute traumatic primary patellar dislocation: long-term results comparing conservative and surgical treatment. *Clin J Sport Med* 2005 ; 15 : 62-66.
25. **Camanho GL, Viegas A de C, Bitar AC et al.** Conservative versus surgical treatment for repair of the medial patellofemoral ligament in acute dislocations of the patella. *Arthroscopy* 2009 ; 25 : 620-625.
26. **Camp CL, Stuart MJ, Krych AJ et al.** CT and MRI Measurements of Tibial Tubercle-Trochlear Groove Distances Are Not Equivalent in Patients With Patellar Instability. *Am J Sports Med* 2013 ; 41 : 1835-1840.
27. **Carney JR, Mologne TS, Muldoon M et al.** Long-term evaluation of the Roux-Elmslie-Trillat procedure for patellar instability: a 26-year follow-up. *Am J Sports Med* 2005 ; 33 : 1220-1223.
28. **Carrillon Y, Abidi H, Dejour D et al.** Patellar instability: assessment on MR images by measuring the lateral trochlear inclination-initial experience. *Radiology* 2000 ; 216 : 582-585.
29. **Carter C, Sweetnam R.** Familial Joint Laxity and Recurrent Dislocation of the Patella. *J Bone Joint Surg Br* 1958 ; 40B : 664-667.
30. **Caton J, Deschamps G, Chambat P et al.** [Patella infera. Apropos of 128 cases]. *Rev Chir Orthop Reparatrice Appar Mot* 1982 ; 68 : 317-325.
31. **Charles MD, Haloman S, Chen L et al.** Magnetic Resonance Imaging-Based Topographical Differences Between Control and Recurrent Patellofemoral Instability Patients. *Am J Sports Med* 2013 ; 41 : 374-384.
32. **Christiansen SE, Jakobsen BW, Lund B et al.** Isolated repair of the medial patellofemoral ligament in primary dislocation of the patella: a prospective randomized study. *Arthroscopy* 2008 ; 24 : 881-887.
33. **Christoforakis J, Bull a MJ, Strachan RK et al.** Effects of lateral retinacular release on the lateral stability of the patella. *Knee Surg Sports Traumatol Arthrosc* 2006 ; 14 : 273-277.
34. **Coffield RH, Bryan RS.** Acute dislocation of the patella: results of conservative treatment. *J trauma* 1977 ; 17 : 526-531.
35. **Cooke TD, Price N, Fisher B et al.** The inwardly pointing knee. An unrecognized problem of external rotational malalignment. *Clin Orthop Relat Res* 1990 ; : 56-60.
36. **Cooney a D, Kazi Z, Caplan N et al.** The relationship between quadriceps angle and tibial tuberosity-trochlear groove distance in patients with patellar instability. *Knee Surg Sports Traumatol Arthrosc* 2012 ;
37. **Crosby EB, Insall J.** Recurrent dislocation of the patella. Relation of treatment to osteoarthritis. *J Bone Joint Surg Am* 1976 ; 58 : 9-13.
38. **Dejour D, Byn P, Ntagiopoulos PG.** The Lyon's sulcus-deepening trochleoplasty in previous unsuccessful patellofemoral surgery. *Int Orthop* 2013 ; 37 : 433-439.
39. **Dejour H, Walch G, Neyret P et al.** Dysplasia of the femoral trochlea. *Rev Chir Orthop Reparatrice Appar Mot* 1990 ; 76 : 45-54.
40. **Dejour H, Walch G, Nove-Josserand L et al.** Factors of patellar instability: an anatomic radiographic study. *Knee Surg Sports Traumatol Arthrosc* 1994 ; 2 : 19-26.
41. **Desio SM, Burks RT, Bachus KN.** Soft tissue restraints to lateral patellar translation in the human knee. *Am J Sports Med* 1998 ; 26 : 59-65.
42. **Dickschas J, Harrer J, Reuter B, Schwitulla J SW.** Osteotomies of the Femur. *J Orthop Res* 2014 ; : 1193-1199.
43. **Dickschas J, Harrer J, Bayer T et al.** Correlation of the tibial tuberosity-trochlear groove distance with the Q-angle. *Knee Surg Sports Traumatol Arthrosc* 2014 ;
44. **Diederichs G, Issever AS, Scheffler S.** MR Imaging of Patellar Instability : Injury Patterns and Assessment of Risk. *Radiographics* 2010 ; 30 : 961-981.
45. **Diederichs G, Kohlitz T, Kornaropoulos E et al.** Magnetic Resonance Imaging Analysis of Rotational Alignment

- in Patients With Patellar Dislocations. *Am J Sports Med* 2013 ; 41 : 51-57.
46. **Dietrich TJ, Betz M, Pfirrmann CW a et al.** End-stage extension of the knee and its influence on tibial tuberosity-trochlear groove distance (TTTG) in asymptomatic volunteers. *Knee Surg Sports Traumatol Arthrosc* 2014 ; 22 : 214-218.
  47. **Donell ST, Joseph G, Hing CB et al.** Modified Dejour trochleoplasty for severe dysplasia: operative technique and early clinical results. *Knee* 2006 ; 13 : 266-273.
  48. **Donell ST, Shepherd K, Ali K et al.** The inferomedial patellar protuberance and medial patellar ossicle in patellar instability. *Knee Surg Sports Traumatol Arthrosc* 2015 ;
  49. **Dornacher D, Reichel H, Lippacher S.** Measurement of tibial tuberosity-trochlear groove distance: evaluation of inter- and intraobserver correlation dependent on the severity of trochlear dysplasia. *Knee Surg Sports Traumatol Arthrosc* 2014 ; 22 : 2382-2387.
  50. **Eckhoff DG, Montgomery WK, Kilcoyne RF et al.** Femoral morphometry and anterior knee pain. *Clin Orthop Relat Res* 1994 ; : 64-68.
  51. **Elias D a, White LM.** Imaging of patellofemoral disorders. *Clinical radiology* 2004 ; 59 : 543-557.
  52. **Elias D a, White LM, Fithian DC.** Acute lateral patellar dislocation at MR imaging: injury patterns of medial patellar soft-tissue restraints and osteochondral injuries of the inferomedial patella. *Radiology* 2002 ; 225 : 736-743.
  53. **Enderlein D, Nielsen T, Christiansen SE et al.** Clinical outcome after reconstruction of the medial patellofemoral ligament in patients with recurrent patella instability. *Knee Surg Sports Traumatol Arthrosc* 2014 ; 22 : 2458-2464.
  54. **Fabricant PD, Ladenhauf HN, Salvati EA et al.** Medial patellofemoral ligament (MPFL) reconstruction improves radiographic measures of patella alta in children. *Knee* 2014 ; 21 : 1180-1184.
  55. **Farr S, Huyer D, Sadoghi P et al.** Prevalence of osteoarthritis and clinical results after the Elmslie-Trillat procedure: A retrospective long-term follow-up. *Int Orthop* 2014 ; 38 : 61-66.
  56. **Felus J, Kowalczyk B.** Age-related differences in medial patellofemoral ligament injury patterns in traumatic patellar dislocation: case series of 50 surgically treated children and adolescents. *Am J Sports Med* 2012 ; 40 : 2357-2364.
  57. **Fithian DC, Paxton EW, Stone M Lou et al.** Epidemiology and natural history of acute patellar dislocation. *Am J Sports Med* 2004 ; 32 : 1114-1121.
  58. **Frobell RB, Lohmander LS, Roos HP.** Acute rotational trauma to the knee: poor agreement between clinical assessment and magnetic resonance imaging findings. *Scand J Med Sci Sports* 2007 ; 17 : 109-114.
  59. **Fucntese SF, Schottle PB, Pfirrmann CW et al.** CT changes after trochleoplasty for symptomatic trochlear dysplasia. *Knee Surg Sports Traumatol Arthrosc* 2007 ; 15 : 168-174.
  60. **Fucntese SF, von Roll A, Koch PP et al.** The patella morphology in trochlear dysplasia--a comparative MRI study. *Knee* 2006 ; 13 : 145-150.
  61. **Fucntese SF, Zingg PO, Schmitt J et al.** Classification of trochlear dysplasia as predictor of clinical outcome after trochleoplasty. *Knee Surg Sports Traumatol Arthrosc* 2011 ; 19 : 1655-1661.
  62. **Fulkerson JP, Edgar C.** Medial Quadriceps Tendon-Femoral Ligament: Surgical Anatomy and Reconstruction Technique to Prevent Patella Instability. *Arthrosc Tech* 2013 ; 2 : e125-e128.
  63. **Galland O, Walch G, Dejour H et al.** An anatomical and radiological study of the femoropatellar articulation. *Surg Radiol Anat* 1990 ; 12 : 119-125.
  64. **Greenrod W, Cox J, Astori I et al.** A Magnetic Resonance Imaging Study of the Significance of the Distal Femoral Pysis During Medial Patellofemoral Ligament Reconstruction. *Orthop J Sports Med* 2013 ; 1 : 1-4.
  65. **Guerrero P, Li X, Patel K et al.** Medial patellofemoral ligament injury patterns and associated pathology in lateral patella dislocation: an MRI study. *Sports Med Arthrosc Rehabil Ther Technol* 2009 ; 1 : 17.
  66. **Hawkins RJ, Bell RH, Anisette G.** Acute patellar dislocations. The natural history. *Am J Sports Med* 1986 ; 14 : 117-120.
  67. **Heidenreich MJ, Camp CL, Dahm DL et al.** The contribution of the tibial tubercle to patellar instability: analysis of tibial tubercle-trochlear groove (TT-TG) and tibial tubercle-posterior cruciate ligament (TT-PCL) distances. *Knee Surg Sports Traumatol Arthrosc* 2015 ; : 4-8.
  68. **Hiemstra L a, Kerslake S, Lafave MR et al.** Initial validity and reliability of the banff patella instability instrument. *Am J Sports Med* 2013 ; 41 : 1629-1635.
  69. **Hinckel BB, Arendt E a., Ntgiopoulos PG et al.** Trochleoplasty: Historical Overview and Dejour Technique. *Oper Tech Sports Med* 2015 ; 23 : 114-122.
  70. **Hingelbaum S, Best R, Huth J et al.** The TT-TG Index: a new knee size adjusted measure method to determine the TT-TG distance. *Knee Surg Sports Traumatol Arthrosc* 2014 ; 22 : 2388-2395.
  71. **Hinterwimmer S, Minzlaff P, Saier T et al.** Biplanar supracondylar femoral derotation osteotomy for patellofemoral malalignment: the anterior closed-wedge technique. *Knee Surg Sports Traumatol Arthrosc* 2014 ; 22 : 2518-2521.
  72. **Hjelle K, Solheim E, Strand T et al.** Articular cartilage defects in 1,000 knee arthroscopies. *Arthroscopy* 2002 ; 18 : 730-734.
  73. **Hopper GP, Leach WJ, Rooney BP et al.** Does Degree of Trochlear Dysplasia and Position of Femoral Tunnel Influence Outcome After Medial Patellofemoral Ligament Reconstruction? *Am J Sports Med* 2014 ; : 1-7.
  74. **Howells NR, Eldridge JD.** Medial patellofemoral ligament reconstruction for patellar instability in patients with hypermobility: A case control study. *J Bone Joint Surg Br* 2012 ; 94 : 1655-1659.
  75. **Hsiao M, Owens BD, Burks R et al.** Incidence of acute traumatic patellar dislocation among active-duty United



- States military service members. *Am J Sports Med* 2010 ; 38 : 1997-2004.
76. **Insall J, Salvati E.** Patella position in the normal knee joint. *Radiology.* 1971 ; 101 : 101-104.
  77. **Iriuchishima T, Ryu K, Murakami T et al.** The correlation between femoral sulcus morphology and osteoarthritic changes in the patello-femoral joint. *Knee Surg Sports Traumatol Arthrosc* 2015 ;
  78. **Jaquith BP, Parikh SN.** Predictors of Recurrent Patellar Instability in Children and Adolescents After First-time Dislocation. *J Pediatr Orthop* 2015 ;
  79. **Kalichman L, Zhang Y, Niu J et al.** The association between patellar alignment and patellofemoral joint osteoarthritis features--an MRI study. *Rheumatology (Oxford)* 2007 ; 46 : 1303-1308.
  80. **Kepler CK, Bogner E a, Hammoud S et al.** Zone of injury of the medial patellofemoral ligament after acute patellar dislocation in children and adolescents. *Am J Sports Med* 2011 ; 39 : 1444-1449.
  81. **Kita K, Tanaka Y, Toritsuka Y et al.** Factors Affecting the Outcome of Double-Bundle Medial Patellofemoral Ligament Reconstruction for Recurrent Patellar Dislocations Evaluated by Multivariate Analysis. *Am J Sports Med* 2015 ;
  82. **von Knoch F, Böhm T, Bürgi ML et al.** Trochleoplasty for recurrent patellar dislocation in association with trochlear dysplasia. A 4- to 14-year follow-up study. *J Bone Joint Surg Br* 2006 ; 88 : 1331-1335.
  83. **Koch PP, Fuchs B, Meyer DC et al.** Closing wedge patellar osteotomy in combination with trochleoplasty. *Acta Orthop.Belg.* 2011 ; 77 : 116-121.
  84. **Koëter S, Diks MJF, Anderson PG et al.** A modified tibial tubercle osteotomy for patellar maltracking: results at two years. *J Bone Joint Surg Br* 2007 ; 89 : 180-185.
  85. **Kujala UM, Jaakkola LH, Koskinen SK et al.** Scoring of patellofemoral disorders. *Arthroscopy.* 1993 ; 9 : 159-163.
  86. **Köhlitz T, Scheffler S, Jung T et al.** Prevalence and patterns of anatomical risk factors in patients after patellar dislocation: a case control study using MRI. *Eur radiol* 2013 ; 23 : 1067-1074.
  87. **Ladd PE, Laor T, Emery KH et al.** Medial collateral ligament of the knee on magnetic resonance imaging: does the site of the femoral origin change at different patient ages in children and young adults? *J Ped Orthop* 2010 ; 30 : 224-230.
  88. **Lattermann C, Toth J, Bach Jr. BR et al.** The role of lateral retinacular release in the treatment of patellar instability. *Sports Med Arthrosc.* 2007 ; 15 : 57-60.
  89. **Lee J-J, Lee S-J, Won Y-G et al.** Lateral release and medial plication for recurrent patella dislocation. *Knee Surg Sports Traumatol Arthrosc* 2012 ; 20 : 2438-2444.
  90. **Lester JD, Watson JN, Hutchinson MR.** Physical examination of the patellofemoral joint. *Clin J Sport Med* 2014 ; 33 : 403-412.
  91. **Lewallen L, McIntosh A, Dahm D.** First-time patellofemoral dislocation: risk factors for recurrent instability. *The journal of knee surgery* 2015 ; 1 : 1-7.
  92. **Lewallen LW, McIntosh AL, Dahm DL.** Predictors of recurrent instability after acute patellofemoral dislocation in pediatric and adolescent patients. *Am J Sports Med* 2013 ; 41 : 575-581.
  93. **Lippacher S, Dejour D, Elsharkawi M et al.** Observer Agreement on the Dejour Trochlear Dysplasia Classification: A Comparison of True Lateral Radiographs and Axial Magnetic Resonance Images. *Am J Sports Med* 2012 ; 40 : 837-843.
  94. **Mackay ND, Smith N a., Parsons N et al.** Medial Patellofemoral Ligament Reconstruction for Patellar Dislocation: A Systematic Review. *Orthop J Sports Med* 2014 ; 2 : 1-7.
  95. **Madani A, Sadr AP, Yeganeh A et al.** The correlation between Q-angle ( clinical ) and TTTG distance ( axial computed tomography ) in Firuzgar Hospital , 2008. *Med J Islam Rep Iran* 2010 ; 23 : 189-199.
  96. **Maenpaa H, Huhtala H, Lehto MU.** Recurrence after patellar dislocation. Redislocation in 37/75 patients followed for 6-24 years. *Acta Orthop Scand.* 1997 ; 68 : 424-426.
  97. **Maenpaa H, Lehto MU.** Patellar dislocation. The long-term results of nonoperative management in 100 patients. *Am J Sports Med* 1997 ; 25 : 213-217.
  98. **Magnussen RA, De Simone V, Lustig S et al.** Treatment of patella alta in patients with episodic patellar dislocation: a systematic review. *Knee Surg Sports Traumatol Arthrosc* 2014 ; 22 : 2545-2550.
  99. **Malgheem J, Maldague B.** Depth insufficiency of the proximal trochlear groove on lateral radiographs of the knee: relation to patellar dislocation. *Radiology* 1989 ; 170 : 507-510.
  100. **Marteau E, Burdin P, Brillhault J-MM.** Gracilis tendon transfer associated with distal alignment for patella alta with recurrent dislocations: an original surgical technique. *Orthop Traumatol Surg Res* 2011 ; 97 : S5-S11.
  101. **Martinez S, Korobkin M, Fondren FB et al.** Computed tomography of the normal patellofemoral joint. *Investigative radiology* 1983 ; 18 : 249-253.
  102. **Mayer C, Magnussen R a, Servien E et al.** Patellar tendon tenodesis in association with tibial tubercle distalization for the treatment of episodic patellar dislocation with patella alta. *Am J Sports Med* 2012 ; 40 : 346-351.
  103. **Metcalfe AJ, Clark D a., Kemp M et al.** The Bristol Experience of the Bereiter Trochleoplasty: Indications and Technique. *Oper Tech Sports Med* 2015 ; 23 : 123-128.
  104. **Miller GF.** Familial recurrent dislocation of patella with autosomal dominant mode of inheritance. *J Bone Joint Surg Br* 1978 ; 60-B : 203-204.
  105. **Mochizuki T, Nimura A, Tateishi T et al.** Anatomic study of the attachment of the medial patellofemoral ligament and its characteristic relationships to the vastus intermedius. *Knee Surg Sports Traumatol Arthrosc* 2013 ; 21 : 305-310.

106. **Mofidy A, Veravalli K, Jinnah RH et al.** Association and impact of patellofemoral dysplasia on patellofemoral arthropathy and arthroplasty. *Knee* 2014 ; 21 : 509-513.
107. **Monk AP, Doll HA, Gibbons CL et al.** The pathoanatomy of patellofemoral subluxation. *J Bone Joint Surg Br* 2011 ; 93 : 1341-1347.
108. **Muneta T, Yamamoto H, Ishibashi T et al.** Computerized tomographic analysis of tibial tubercle position in the painful female patellofemoral joint. *Am J Sports Med* 1994 ; 22 : 67-71.
109. **Mäenpää H, Lehto MU.** Surgery in acute patellar dislocation--evaluation of the effect of injury mechanism and family occurrence on the outcome of treatment. *Br J Sports Med* 1995 ; 29 : 239-241.
110. **Nakagawa K, Wada Y, Minamide M et al.** Deterioration of long-term clinical results after the Elmslie-Trillat procedure for dislocation of the patella. *J Bone Joint Surg Br* 2002 ; 84 : 861-864.
111. **Naveed M a, Ackroyd CE, Porteous a J.** Long-term (ten- to 15-year) outcome of arthroscopically assisted Elmslie-Trillat tibial tubercle osteotomy. *J Bone Joint Surg Br* 2013 ; 95-B : 478-485.
112. **Nelitz M, Dornacher D, Dreyhaupt J et al.** The relation of the distal femoral physis and the medial patellofemoral ligament. *Knee Surg Sports Traumatol Arthrosc* 2011 ; 19 : 2067-2071.
113. **Nelitz M, Lippacher S, Reichel H et al.** Evaluation of trochlear dysplasia using MRI: correlation between the classification system of Dejour and objective parameters of trochlear dysplasia. *Knee Surg Sports Traumatol Arthrosc* 2014 ; 22 : 120-127.
114. **Nelitz M, Williams SRM.** Kombinierte Trochleoplastik und Rekonstruktion des medialen patellofemorale Ligaments zur Behandlung der patellofemorale Instabilität. *Operative Orthopädie und Traumatologie* 2015.
115. **Nelitz M, Dreyhaupt J, Lippacher S.** Combined trochleoplasty and medial patellofemoral ligament reconstruction for recurrent patellar dislocations in severe trochlear dysplasia: a minimum 2-year follow-up study. *Am J Sports Med* 2013 ; 41 : 1005-1012.
116. **Nelitz M, Dreyhaupt J, Williams SRM et al.** Combined supracondylar femoral derotation osteotomy and patellofemoral ligament reconstruction for recurrent patellar dislocation and severe femoral anteversion syndrome: surgical technique and clinical outcome. *Int Orthop* 2015 ;
117. **Neumann M V, Stalder M, Schuster a J.** Reconstructive surgery for patellofemoral joint incongruency. *Knee Surg Sports Traumatol Arthrosc* 2014 ;
118. **Neyret P, Robinson AHN, Le Coultre B et al.** Patellar tendon length--the factor in patellar instability? *Knee* 2002 ; 9 : 3-6.
119. **Nietosvaara Y, Aalto K.** The cartilaginous femoral sulcus in children with patellar dislocation: an ultrasonographic study. *J Pediatr Orthop* 1997 ; 17 : 50-53.
120. **Nietosvaara Y, Aalto K, Kallio PE.** Acute patellar dislocation in children: incidence and associated osteochondral fractures. *J Ped Orthop* 1994 ; 14 : 513-515.
121. **Nikku R, Nietosvaara Y, Aalto K et al.** The mechanism of primary patellar dislocation: trauma history of 126 patients. *Acta orthop* 2009 ; 80 : 432-434.
122. **Nikku R, Nietosvaara Y, Aalto K et al.** Operative treatment of primary patellar dislocation does not improve medium-term outcome: A 7-year follow-up report and risk analysis of 127 randomized patients. *Acta orthopaedica* 2005 ; 76 : 699-704.
123. **Nomura E, Inoue M.** Second-look arthroscopy of cartilage changes of the patellofemoral joint, especially the patella, following acute and recurrent patellar dislocation. *Osteoarthritis Cartilage* 2005 ; 13 : 1029-1036.
124. **Nomura E.** Cartilage Lesions of the Patella in Recurrent Patellar Dislocation. *Am J Sports Med* 2004 ; 32 : 498-502.
125. **Nove-Josserand L, Dejour D.** [Quadriceps dysplasia and patellar tilt in objective patellar instability]. *Rev Chir Orthop Reparatrice Appar Mot* 1995 ; 81 : 497-504.
126. **Ntagiopoulos PG, Byn P, Dejour D.** Midterm results of comprehensive surgical reconstruction including sulcus-deepening trochleoplasty in recurrent patellar dislocations with high-grade trochlear dysplasia. *Am J Sports Med* 2013 ; 41 : 998-1004.
127. **Ntagiopoulos PG, Dejour D.** Current concepts on trochleoplasty procedures for the surgical treatment of trochlear dysplasia. *Knee Surg Sports Traumatol Arthrosc* 2014 ; 22 : 2531-2539.
128. **Pagenstert G, Wolf N, Bachmann M et al.** Open lateral patellar retinacular lengthening versus open retinacular release in lateral patellar hypercompression syndrome: A prospective double-blinded comparative study on complications and outcome. *Arthroscopy* 2012 ; 28 : 788-797.
129. **Palmu S, Kallio PE, Donell ST et al.** Acute patellar dislocation in children and adolescents: a randomized clinical trial. *J Bone Joint Surg Am* 2008 ; 90 : 463-470.
130. **Panni AS, Cerciello S, Maffulli N et al.** Patellar shape can be a predisposing factor in patellar instability. *Knee Surg Sports Traumatol Arthrosc* 2011 ; 19 : 663-670.
131. **Parikh S, Noyes FR.** Patellofemoral Disorders: Role of Computed Tomography and Magnetic Resonance Imaging in Defining Abnormal Rotational Lower Limb Alignment. *Sports health* 2011 ; 3 : 158-169.
132. **Parikh SN, Nathan ST, Wall EJ et al.** Complications of medial patellofemoral ligament reconstruction in young patients. *Am J Sports Med* 2013 ; 41 : 1030-1038.
133. **Payne J, Rimmke N, Schmitt LC et al.** The Incidence of Complications of Tibial Tubercle Osteotomy: A Systematic Review. *Arthroscopy* 2015 ;
134. **Petri M, von Falck C, Broese M et al.** Influence of rupture patterns of the medial patellofemoral ligament (MPFL) on the outcome after operative treatment of traumatic patellar

- dislocation. *Knee Surg Sports Traumatol Arthrosc* 2013 ; 21 : 683-689.
135. **Pfirschmann CW, Zanetti M, Romero J et al.** Femoral trochlear dysplasia: MR findings. *Radiology* 2000 ; 216 : 858-864.
  136. **Placella G, Tei MM, Sebastiani E et al.** Shape and size of the medial patellofemoral ligament for the best surgical reconstruction: a human cadaveric study. *Knee Surg Sports Traumatol Arthrosc* 2014 ; 22 : 2327-2333.
  137. **Pritsch T, Haim A, Arbel R et al.** Tailored tibial tubercle transfer for patellofemoral malalignment: analysis of clinical outcomes. *Knee Surg Sports Traumatol Arthrosc* 2007 ; 15 : 994-1002.
  138. **Reddy KR, Reddy NS.** Trochleoplasty and medial patellofemoral ligament reconstruction for recurrent patellar dislocation. *Indian J Orthop* 2012 ; 46 : 242-245.
  139. **Rouanet T, Gougeon F, Fayard JM et al.** Sulcus deepening trochleoplasty for patellofemoral instability: A series of 34 cases after 15 years postoperative follow-up. *Orthop Traumatol Surg Res* 2015 ; 101 : 443-447.
  140. **Ruwe PA, Gage JR, Ozonoff MB et al.** Clinical determination of femoral anteversion. A comparison with established techniques. *J Bone Joint Surg Am* 1992 ; 74 : 820-830.
  141. **Saggin PRF, Saggin JI, Dejour D.** Imaging in Patellofemoral Instability. *Sports Med Arthrosc Rev* 2012 ; 20 : 145-151.
  142. **Salzmann GM, Weber TS, Spang JT et al.** Comparison of native axial radiographs with axial MR imaging for determination of the trochlear morphology in patients with trochlear dysplasia. *Arch Orthop Trauma Surg* 2010 ; 130 : 335-340.
  143. **Sanchis-Alfonso V, Merchant AC.** Iatrogenic Medial Patellar Instability: An Avoidable Injury. *Arthroscopy* 2015 ; 31 : 1628-1632.
  144. **Schoettle PB, Zanetti M, Seifert B et al.** The tibial tuberosity-trochlear groove distance; a comparative study between CT and MRI scanning. *Knee* 2006 ; 13 : 26-31.
  145. **Schöttle PB, Fucentese SF, Romero J.** Clinical and radiological outcome of medial patellofemoral ligament reconstruction with a semitendinosus autograft for patella instability. *Knee Surg Sports Traumatol Arthrosc* 2005 ; 13 : 516-521.
  146. **Schöttle PB, Fucentese SF, Pfirschmann C et al.** Trochleoplasty for patellar instability due to trochlear dysplasia: A minimum 2-year clinical and radiological follow-up of 19 knees. *Acta orthop* 2005 ; 76 : 693-698.
  147. **Seitlinger G, Scheurecker G, Hogler R et al.** Tibial Tubercle-Posterior Cruciate Ligament Distance: A New Measurement to Define the Position of the Tibial Tubercle in Patients With Patellar Dislocation. *Am J Sports Med* 2012 ; 1-7.
  148. **Servien E, Ait Si Selmi T, Neyret P.** [Study of the patellar apex in objective patellar dislocation]. *Rev Chir Orthop Reparatrice Appar Mot* 2003 ; 89 : 605-612.
  149. **Shah JN, Howard JS, Flanigan DC et al.** A systematic review of complications and failures associated with medial patellofemoral ligament reconstruction for recurrent patellar dislocation. *Am J Sports Med* 2012 ; 40 : 1916-1923.
  150. **Shakespeare D, Fick D.** Patellar instability-can the TT-TG distance be measured clinically? *Knee.* 2005 ; 12 : 201-204.
  151. **Shea KG, Polousky JD, Jacobs JC et al.** The Relationship of the Femoral Physis and the Medial Patellofemoral Ligament in Children : A Cadaveric Study. *J Ped Orthop* 2014 ; 34 : 808-813.
  152. **Shih YF, Bull AM, Amis AA.** The cartilaginous and osseous geometry of the femoral trochlear groove. *Knee Surg Sports Traumatol Arthrosc* 2004 ; 12 : 300-306.
  153. **Sillanpää PJ, Mattila VM, Mäenpää H et al.** Treatment with and without initial stabilizing surgery for primary traumatic patellar dislocation. A prospective randomized study. *J Bone Joint Surg Am* 2009 ; 91 : 263-273.
  154. **Sillanpää PJ, Mattila VM, Visuri T et al.** Patellofemoral osteoarthritis in patients with operative treatment for patellar dislocation: a magnetic resonance-based analysis. *Knee Surg Sports Traumatol Arthrosc* 2011 ; 19 : 230-235.
  155. **Sillanpää PJ, Mäenpää HM, Mattila VM et al.** Arthroscopic surgery for primary traumatic patellar dislocation: a prospective, nonrandomized study comparing patients treated with and without acute arthroscopic stabilization with a median 7-year follow-up. *Am J Sports Med* 2008 ; 36 : 2301-2309.
  156. **Sillanpää PJ, Mäenpää HM, Mattila VM et al.** A mini-invasive adductor magnus tendon transfer technique for medial patellofemoral ligament reconstruction: a technical note. *Knee Surg Sports Traumatol Arthrosc* 2009 ; 17 : 508-512.
  157. **Sillanpää P, Mattila VM, Iivonen T et al.** Incidence and risk factors of acute traumatic primary patellar dislocation. *Med Sci Sports Exerc* 2008 ; 40 : 606-611.
  158. **Smith TO, Chester R, Cross J et al.** Rehabilitation following first-time patellar dislocation: A randomised controlled trial of purported vastus medialis obliquus muscle versus general quadriceps strengthening exercises. *Knee* 2015 ; 22 : 313-320.
  159. **Smith TO, Clark A, Neda S et al.** The intra- and inter-observer reliability of the physical examination methods used to assess patients with patellofemoral joint instability. *Knee* 2012 ; 19 : 404-410.
  160. **Smith TO, Davies L, Chester R et al.** Clinical outcomes of rehabilitation for patients following lateral patellar dislocation: a systematic review. *Physiotherapy* 2010 ; 96 : 269-281.
  161. **Smith TO, Davies L, O'Driscoll M-L et al.** An evaluation of the clinical tests and outcome measures used to assess patellar instability. *Knee* 2008 ; 15 : 255-262.
  162. **Smith TO, Donell ST, Chester R et al.** What activities do patients with patellar instability perceive makes their patella unstable? *Knee* 2011 ; 18 : 333-339.
  163. **Smith TO, Donell ST, Clark A et al.** The development, validation and internal consistency of the Norwich Patellar

- Instability (NPI) score. *Knee Surg Sports Traumatol Arthrosc* 2014 ; 22 : 324-335.
- 164. Smith TO, Song F, Donell ST et al.** Operative versus non-operative management of patellar dislocation. A meta-analysis. *Knee Surg Sports Traumatol Arthrosc* 2011 ; 19 : 988-998.
- 165. Song J-G, Kang S-B, Oh S-H et al.** Medial Soft-Tissue Realignment Versus Medial Patellofemoral Ligament Reconstruction for Recurrent Patellar Dislocation: Systematic Review. *Arthroscopy* 2015 ; : 1-10.
- 166. Staheli LT.** Torsion--treatment indications. *Clin Orthop Relat Res* 1989 ; : 61-66.
- 167. Stanitski CL, Paletta GA.** Articular cartilage injury with acute patellar dislocation in adolescents. Arthroscopic and radiographic correlation. *Am J Sports Med* 1998 ; 26 : 52-55.
- 168. Steensen RN, Bentley JC, Trinh TQ et al.** The Prevalence and Combined Prevalences of Anatomic Factors Associated With Recurrent Patellar Dislocation: A Magnetic Resonance Imaging Study. *Am J Sports Med* 2015 ; 43 : 921-927.
- 169. Steensen RN, Dopyrak RM, Maurus PB.** A simple technique for reconstruction of the medial patellofemoral ligament using a quadriceps tendon graft. *Arthroscopy* 2005 ; 21 : 365-370.
- 170. Stefanik JJ, Zhu Y, Zumwalt AC, Gross KD, Clancy M, Lynch JA, Frey Law LA, Lewis CE, Roemer FW, Powers CM, Guermazi A FD.** Association between patella alta and the prevalence and worsening of structural features of patellofemoral joint osteoarthritis: the multicenter osteoarthritis study. *Arthritis Care Res* 2012 ; 29 : 997-1003.
- 171. Stefanik JJ, Roemer FW, Zumwalt AC et al.** Association between measures of trochlear morphology and structural features of patellofemoral joint osteoarthritis on MRI: the MOST study. *J Orthop Res* 2012 ; 30 : 1-8.
- 172. Tanaka MJ, Elias JJ, Williams A a. et al.** Correlation Between Changes in Tibial Tuberosity-Trochlear Groove Distance and Patellar Position During Active Knee Extension on Dynamic Kinematic Computed Tomographic Imaging. *Arthroscopy* 2015 ; 31 : 1748-1755.
- 173. Tecklenburg K, Dejour D, Hoser C et al.** Bony and cartilaginous anatomy of the patellofemoral joint. *Knee Surg Sports Traumatol Arthrosc* 2006 ; 14 : 235-240.
- 174. Tecklenburg K, Feller J a, Whitehead TS et al.** Outcome of surgery for recurrent patellar dislocation based on the distance of the tibial tuberosity to the trochlear groove. *J Bone Joint Surg Br* 2010 ; 92 : 1376-1380.
- 175. Teichtahl AJ, Hanna F, Wluka AE et al.** A flatter proximal trochlear groove is associated with patella cartilage loss. *Med Sci Sports Exerc* 2012 ; 44 : 496-500.
- 176. Tensho K, Akaoka Y, Shimodaira H et al.** What Components Comprise the Measurement of the Tibial Tuberosity-Trochlear Groove Distance. *J Bone Joint Surg Am* 2015 ; 97 : 1441-1448.
- 177. Thaunat M, Bessiere C, Pujol N et al.** Recession wedge trochleoplasty as an additional procedure in the surgical treatment of patellar instability with major trochlear dysplasia: early results. *Orthop Traumatol Surg Res* 2011 ; 97 : 833-845.
- 178. Toms AP, Cahir J, Swift L et al.** Imaging the femoral sulcus with ultrasound, CT, and MRI: Reliability and generalizability in patients with patellar instability. *Skeletal Radiology* 2009 ; 38 : 329-338.
- 179. Tscholl PM, Antoniadis A, Dietrich TJ et al.** The tibial-tubercle trochlear groove distance in patients with trochlear dysplasia: the influence of the proximally flat trochlea. *Knee Surg Sports Traumatol Arthrosc* 2014 ;
- 180. Utting MR, Mulford JS, Eldridge JDJ.** A prospective evaluation of trochleoplasty for the treatment of patellofemoral dislocation and instability. *J Bone Joint Surg Br* 2008 ; 90 : 180-185.
- 181. Vallotton J, Echeverri S.** Clinical Examination of the Patellofemoral Patient. In: Patellofemoral Pain, Instability, and Arthritis. 2010; 41-49
- 182. Verdonk R, Jansegers E, Stuyts B.** Trochleoplasty in dysplastic knee trochlea. *Knee Surg Sports Traumatol Arthrosc* 2005 ; 13 : 529-533.
- 183. Vivod G, Verdonk P, Drobnj M.** Long-term clinical and radiographic outcome of patello-femoral realignment procedures: a minimum of 15-year follow-up. *Knee Surg Sports Traumatol Arthrosc* 2014 ; 22 : 2747-2755.
- 184. Wagner D, Pflazer F, Hingelbaum S et al.** The influence of risk factors on clinical outcomes following anatomical medial patellofemoral ligament (MPFL) reconstruction using the gracilis tendon. *Knee Surg Sports Traumatol Arthrosc* 2013 ; 21 : 318-324.
- 185. Waterman BR, Belmont PJ, Owens BD.** Patellar dislocation in the United States: role of sex, age, race, and athletic participation. *J Knee Surg* 2012 ; 25 : 51-57.
- 186. Wright SJ, Boymans T a. EJ, Grimm B et al.** Strong correlation between the morphology of the proximal femur and the geometry of the distal femoral trochlea. *Knee Surg Sports Traumatol Arthrosc* 2014 ; 22 : 2900-2910.
- 187. Zaffagnini S, Giordano G, Bruni D et al.** Pathophysiology of Lateral Patellar Dislocation. In: Zaffagnini S, Dejour D, Arendt E, eds. Patellofemoral Pain, Instability, and Arthritis. Springer-Verlag, Berlin Heidelberg; 2010; 17-27
- 188. Zaffagnini S, Marcheggiani Muccioli GM, Grassi A et al.** Minimally invasive medial patellofemoral ligament reconstruction with fascia lata allograft: surgical technique. *Knee Surg Sports Traumatol Arthrosc* 2014 ;