



Latarjet reconstruction in patients with anterior shoulder instability and significant Hill-Sachs lesion

Abd Elrahman ELGANAINY, Mohammed Abou EL-NOUR

From the Orthopedic Surgery department, Faculty of Medicine, Mansoura University, Egypt

Management of glenohumeral instability with large Hill-Sachs lesions remains controversial either to address or just grafting the glenoid rim defects. This study was done to investigate if open Latarjet is sufficient to prevent recurrent instability in patients with significant Hill-Sachs defects without addressing these lesions. In the period between October 2009 and November 2014 twenty three patients with shoulder instability and significant bone loss were treated by open Latarjet. All patients were followed up for a period ranged from 17 to 58 months (median \pm SD : 30 ± 13.9). The mean preoperative Rowe score was significantly increased from 45.4 to 91.5 (p value $<0,001$). At the final follow up there was 17 patients with excellent result, 5 patients with good result and 2 patients with fair result. In conclusion, Latarjet provides a reliable and effective stabilization for anteroinferior glenohumeral instability with significant bone loss and engaging Hill-Sachs lesion.

Keywords : Shoulder, Latarjet reconstruction, anterior instability, bony defect, Hill-Sachs lesion.

INTRODUCTION

Over the last decade, attention has been focused on the concept of shoulder instability caused by osseous deficiency localized to humeral head or glenoid (9). Although many literatures exist on the well-established relationship between glenoid bony defects and shoulder instability (15), there is a relative paucity of literature on humeral head defects (3). Itoi *et al.* (19) reported that the incidence

of Hill-Sachs lesions in anterior shoulder instability was 38-88% and is associated with 100% recurrent dislocation. Burkhart and De Beer (6) showed a recurrence rate of 67% after arthroscopic Bankart repair in patients with significant bone defects, this was in contrast to 4% recurrence rates in those without significant bone loss. The diagnosis and optimal treatment of glenohumeral instability associated with bony deficiency represent complex and evolving challenges to clinicians. There is considerable debate in management of instability with significant bone loss whether to address the humeral side e.g. anterior plication, several bone grafting techniques allograft mosaicoplasty or just address glenoid side by Latarjet or iliac bone graft (16).

The intent with these humeral head procedures is to fill the defect and restore native anatomy by effectively increasing the articular arc of the humerus as it rotates on the glenoid, thereby preventing engagement and instability.

Application of a coracoid graft increased depth and width of the deficient glenoid and creates a

■ Abd Elrahman Elganainy,
■ Mohammed Abou El-nour
*Orthopedic Surgery department, Faculty of Medicine,
Mansoura University, Egypt.*

Corresponding author : Abd Elrahman Elganainy, M.D.,
Mansoura Faculty of Medicine, Box 50, 35516, Al-Mansoura,
Egypt.

E-mail : ganainy1968@yahoo.com

© 2017, Acta Orthopædica Belgica.

*No benefits or funds were received in support of this study.
The authors report no conflict of interests.*

than 20%, seven patients with large Hill-Sachs lesion about 40%, and 16 patients with Hill-Sachs lesion between 20-40% of humeral head. MRI for detection of concomitant rotator cuff tears or any associated lesions e.g. slap lesions.

Although various methods of quantification for both the glenoid and the humeral heads have been described to be useful in pre-operative planning, there has been no universal acceptance of any of these methods (8). Dynamic arthroscopy remains the gold standard for evaluation of bone loss (10).

Operative Procedure

An Examination under Anesthesia to delineate the severity and direction of instability

Each patient in this study underwent diagnostic arthroscopy for detection of the amount of bone loss and if there was any associated pathology (e.g., SLAP lesions) that would need to be addressed arthroscopically before open surgery. Diagnostic arthroscopy was performed with the patient in the lateral decubitus position, we measured the diameter of the widest part of the inferior glenoid with calibrated probe, then we measured the distance from the glenoid bare spot to the anterior and posterior glenoid margins, we could determine the percentage of the inferior glenoid diameter bone loss. Engaging Hill-Sachs lesions were identified through dynamic arthroscopic examination by bringing the arm into 90° abduction and 90° external rotation. If the Hill-Sachs lesion engaged the anterior glenoid rim in this position, we considered it to represent a significant bone deficiency.

The patient is placed in a peach chair position. The operated arm is allowed free for intraoperative adduction and external rotation, small towel is placed under the scapula to stabilize and flatten the scapula.

A limited deltopectoral approach. The skin incision is made vertically 4 to 5 cm long from the coracoid tip toward the axillary fold. Branching vessels from the cephalic vein are ligated, a self-retaining retractor is placed between the deltoid and the pectoralis major, a human retractor is placed over the coracoid process.

The coracoacromial ligament (CAL) is incised 1cm lateral to the coracoids, the pectoralis minor

tendon is released from its coracoid attachment by electrocautery but not far the tip of the coracoid because the blood supply of the graft enters just medial to the conjoint tendon insertion. Expose the site of osteotomy (the knee of the coracoid at the junction of its horizontal and vertical components), by curved osteotome the osteotomy is made from medial to lateral harvesting a graft of 2.5-3cm. make the osteotomy in a perpendicular fashion to avoid extension into the glenoid, the undersurface is decorticated and two drill holes are made in the coracoid 1cm apart

The subscapularis is exposed and splitted at the junction of its superior two thirds and inferior third. the underlying capsule is exposed and opened in a vertical manner in the level of the joint line, an intra-articular retractor is placed to retract the humeral head, superior exposure is improved by placing a 4mm Steinman pin into the superior scapular neck as high as possible. The anterior labrum and periosteum are excised. A curette is used to decorticate the anteroinferior surface of the glenoid to create a flat surface of bleeding cancellous bone. The inferior hole of the glenoid is drilled at a position of 4-5 o'clock in the right shoulder (7-8 o'clock in the left shoulder) It is important to avoid placing the graft too inferiorly which can result in recurrent dislocation over the top of the graft. The hole must be placed about 7 mm medial to the glenoid margin to avoid lateral coracoid overhanging from glenoid, the drill is directed parallel to the glenoid articular surface and passes through the posterior glenoid cortex.

The coracoid graft is fixed with a 35mm long 4mm partially threaded cancellous screw for better compression (Fig. 2). The screw is fully inserted into the inferior hole of the coracoid graft and then derived into the already drilled hole in the glenoid and tightened ensuring that the coracoid comes to lie parallel to the articular margin with no overhanging. A depth gauge is used to determine the appropriate length of the second screw. Both screws are tightened using a 2-finger technique; avoid overtightening to prevent fracture of the coracoid graft. The capsule is repaired to the CAL stump with the arm in full external rotation to prevent postoperative stiffness. We never repair the split in the subscapularis muscle.

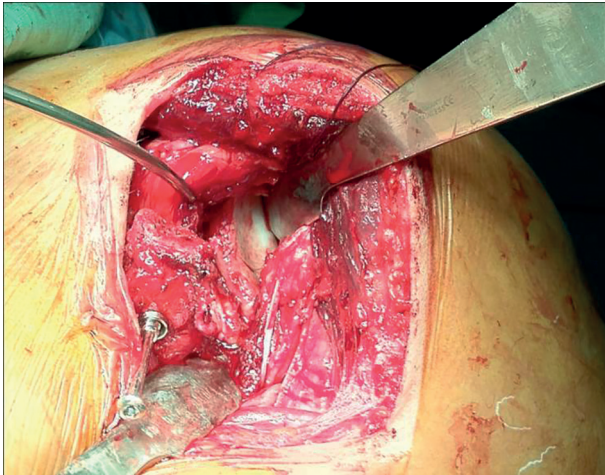


Fig. 2. — Graft fixation

We used a simple sling for 2 weeks to encourage rest and reduce risk of postoperative hematoma. Rehabilitation with self-mobilization in elevation and external rotation is allowed from day 3. Activities of daily living are allowed after 2 weeks. Plain radiographs are obtained immediate postoperative (Fig. 3) then after 3 months to assess healing of the graft, if healing is satisfactory return to sports are allowed gradually (Fig. 4).

Statistical analysis of the data was conducted using SPSS® version 11 (Chicago, IL, USA). Data are expressed as mean value \pm SD for quantitative data. Non-parametric (Mannwhitney,kruskalwallis) and Chisquare tests were used for comparison between preoperative and postoperative parameters with regard to Rowe score. P value of <0.05 was considered to be significant.

RESULTS

All patients were followed up for a period ranged from 17 to 58 months (median \pm SD : 30 ± 13.9). The mean Rowe score was significantly increased from 45.4 ± 4.6 (ranged from 37 to 51) to 91.5 ± 6.7 (ranged from 72-97), P value <0.001 . At the final follow up, we had 17 patients with excellent results, 5 patients with good results, and 2 patients with fair results.

Preoperative mean active forward elevation was $169^\circ\pm 6.8^\circ$ (range, 160 to 180°) which increased postoperatively to $172^\circ\pm 5.9^\circ$ (range, 160 to 180°).

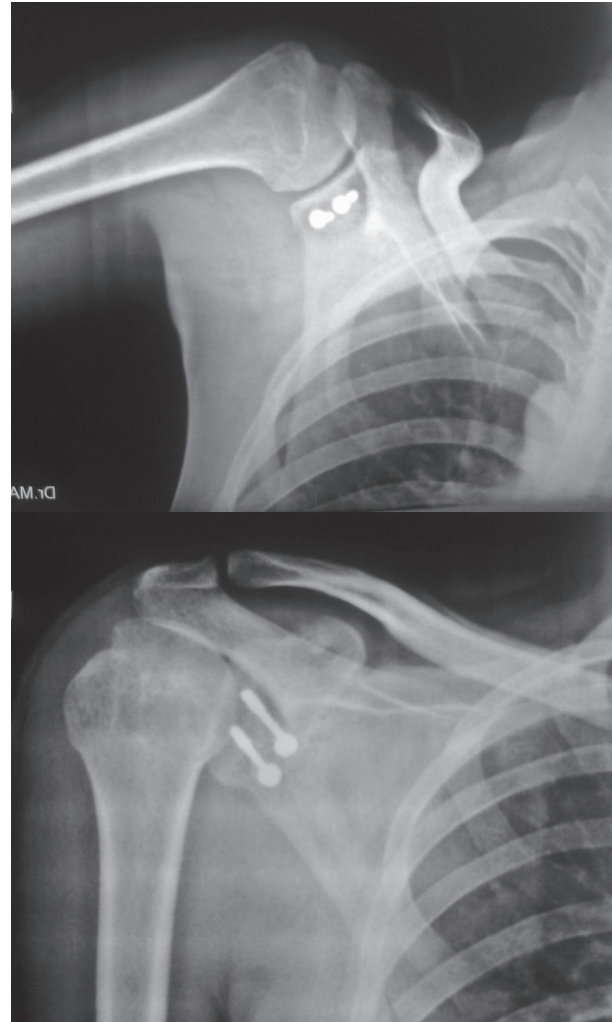

Fig. 3. — Postoperative x ray

Preoperative external rotation with the arm at the side was $71.3^\circ\pm 8.5^\circ$ (range, 50° to 80°), decreased postoperatively to $63.9^\circ\pm 6.9^\circ$ (range, 48° to 75°).

Of the 23 patients, there were 7 athletes who returned to their previous sports after four to six months postoperatively.

At the final follow up, we did not report any case with dislocation or subluxation and there was no evidence of scapular dyskinesia or malposition in any patient. There were no major postoperative complications apart from one patient who got superficial infection resolved by medical treatment without any surgical interference and one case was diagnosed radiologically with fibrous union of the graft without any evident clinical symptoms.

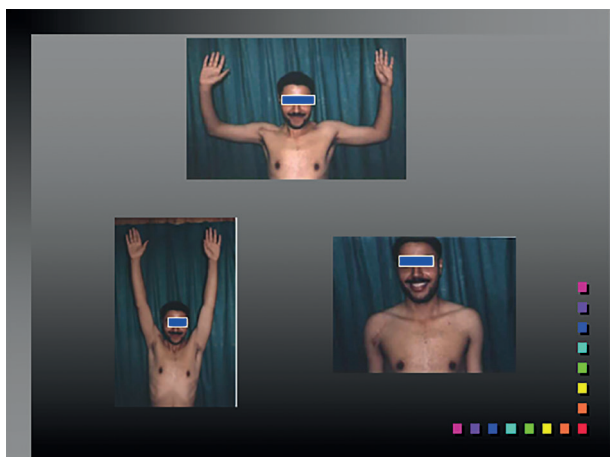


Fig. 4 — Postoperative follow up

As regard the position of the graft, there were 2 patients with lateral placement of the graft with mild overhanging. No signs of glenohumeral arthrosis were detected in the last follow up X ray.

DISCUSSION

Bony defects of glenoid or humeral head can result in recurrent dislocation because they modify the congruency of glenohumeral joint surfaces and the function of static glenohumeral stabilizers (13). Failure to address these bony defects in treatment of shoulder instability can result in poor outcome.

The incidence of hill-sachs lesion in young traumatic first dislocation has been varied from 47% to 100% (4). This incidence may be as high as 100% in patients with recurrent anterior instability (12). In cases of increased glenoid bone loss; a less humeral-sided bone involvement is needed for significant instability to occur.

Yamamoto and his colleagues (28) described the glenoid contact area which shifts from inferomedial to superolateral portion of the posterior aspect of the humeral head as the glenoid track. These investigators reported that a Hill-Sachs lesion is at higher risk of engagement if it extends medially over the medial margin of the glenoid track. So, increased glenoid bone loss decreases the size of this glenoid track, making engagement and recurrent instability more common. The importance of addressing glenoid defects in the setting of humeral

lesions was demonstrated by Kurokawa *et al.* (21) who used a Latarjet procedure to increase the width of the glenoid without treatment of the concurrent Hill-Sachs lesions. They showed that after the Hill-Sachs lesions were placed inside the glenoid track, they became nonengaging and changed from an off-track lesion to an on-track lesion. Many different surgical techniques to address humeral bone loss have been reported; anterior plication and rotational osteotomy, several bone grafting techniques, allograft mosaicoplasty and arthroplasty (11,14, 20). Regardless of the method chosen, the goal is to prevent further engagement of the Hill-Sachs lesion with the glenoid. Although all our cases had significant Hill-Sachs lesions, we used Latarjet procedure and we did not address any of the Hill-Sachs lesions even engaging defects without any recorded cases of dislocation or even subluxation. As described by Patte and Debeyre (25), Latarjet provides stabilization of these unstable shoulders by three mechanisms; 1st the coracoid graft extends the glenoid arc so the shoulder cannot externally rotate enough to engage the defect over the front of the graft (bony effect), 2nd the tethering effect of the conjoined tendon provides a sling effect across the anterior joint capsule increasing stability in the 90°-90° position (belt or sling effect), 3rd repairing of the joint capsule with augmentation via the stump of coracoacromial ligament (bumper effect). So Hill-Sachs lesion changed from an off-track lesion to an on-track lesion and no need to do more surgical steps for these lesions to avoid many complications; as postoperative shoulder stiffness, iliac bone graft site morbidity, and potential risk of disease transmission in allografts and to save surgical time.

In this study all the patients had significant Hill-Sachs lesion, 10 patients had significant glenoid defect and 7 patients had engaging Hill-Sachs lesion. The mean preoperative Rowe score was significantly increased from (45.4) to (91.5) with p value $<0,001$. There was no dislocation or subluxation and this was similar to the results of Neyton *et al.* (23) who recorded mean Rowe score 91.9. Shoulder movement and rotation were not affected with good range of motion postoperatively. In disagreement with other authors (2,7,18), we had not found a significant loss of external rotation in our patients

after the Latarjet procedure. The key differences in our technique were ; use of a subscapularis-splitting approach, repair of the capsule to the coracoacromial ligament stump with the arm in maximal external rotation, and immediate postoperative range of motion rehabilitation, including external rotation.

A recent systematic review concluded that the recurrence rate of arthroscopic Bankart repair was 12.7%, and that the rate was similar in arthroscopic and open Bankart (1). In our study we had 6 patients with previous Bankart repair, by studying their radiological series, all of them had Hill-Sachs defects and 4 patients had engaging lesions, after Latarjet they had good results without further instability. This confirms the hypothesis that Bankart repair in face of significant bone loss, an off-axis load will be resisted only by soft tissue rather than bone which leads to high rates of failure (18, 27).

Higher failure rates have been reported in contact athletes with recurrent instability following arthroscopic soft tissue procedures (5). An open bony procedure seems to give better results with a pain-free, mobile, and strong shoulder in this group. There were seven contact athletes patients either football or overhead throwing who revealed excellent results and returned to their preinjury level after about six months postoperatively.

Despite these excellent clinical and functional results, some concern about the adverse effects of Latarjet procedure especially glenohumeral arthrosis after many years. Allain et al (2) found correlation between arthrosis and associated cuff lesions, lateral overhanging of the coracoid and intra articular screws after 14.3 years follow up.

We recommend some tips and tricks to achieve better results in this procedure : (1) Avoid injury of musculocutaneous nerve by gentle dissection of the undersurface of the coracoid. (2) Take sutures in the cut part of the coracoacromial ligament to facilitate its repair with the capsule and inferior glenohumeral ligament in adduction and maximal external rotation and so no need for using anchors (3) Adequate decortication of the coracoid process and roughening of the glenoid avoid non-union of the graft. (4) Appropriate positioning of the graft flush with the anterior border of the glenoid and

avoid too medial or too lateral placement of the graft (5) The length of the screws must not exceed 40 mm to avoid injury of the suprascapular nerve.

Recent systemic reviews raised concerns about short term complications of Latarjet including ; instability, nerve palsies, hardware complications, intraoperative fractures and infections. In our experience the complications with Latarjet procedure are rare with a meticulous surgical technique. We had only one patient with mild superficial infection improved by medical treatment only.

The present study demonstrates reliable success and high clinical outcomes with only 2 patients with positive apprehension. Clinically, they had large number of dislocations and they had associated weakness of the rotator cuff muscles. By studying their radiology both of them had bipolar bony defect (engaging Hill-Sachs lesion), and lateral placement of the graft with mild overhanging. Our study had some limitations, Small number of cases and short follow up period and we did not study the incidence of post-traumatic osteoarthritis because the follow-up time was too short.

CONCLUSION

Latarjet is a very good and economic option for anterior glenohumeral instability especially in patients with 3 times more dislocation, initial severe trauma with axially load the humeral head, further instability with minor trauma and with daily life activates and radiologic evidence of Hill-Sachs lesion.

REFERENCES

1. **Abouali JAK, Hatzatoni K, Holtby R, Veillette C, Theodoropoulos J.** Revision arthroscopic Bankart repair. *Arthroscopy* 2013 ; 29 :1572-8.
2. **Allain J, Goutallier D, Glorion C.** Long-term results of the Latarjet procedure for the treatment of anterior instability of the shoulder. *J Bone Joint Surg Am* 1998 ; 80 :841-52.
3. **Armitage MS, Faber KJ, Drosdowech DS, Litchfield RB, Athwal GS.** Humeral head bone defects : Remplissage, allograft, and arthroplasty. *Orthop Clin North Am* 2010 ; 41 :417-425.

4. **Baker CL.** Intraarticular pathology in acute, first-time anterior shoulder dislocation : An arthroscopic study. *Arthroscopy* 1996 ; 10 : 478-479.
5. **Bonneviale N, Mansat P, Bellumore Y, et al.** Surgical treatment of anterior shoulder instability in rugby players : clinical and radiographic results with minimum five-year follow-up. *Rev Chir Orthop Reparatrice Appar Mot* 2008 ; 94 :635-42 [in French].
6. **Burkhart SS, De Beer JF.** Traumatic glenohumeral bone defects and their relationship to failure of arthroscopic Bankart repairs : Significance of the inverted-pear glenoid and the humeral engaging Hill-Sachs lesion. *Arthroscopy* 2000 ; 16 :677-694.
7. **Burkhart SS, De Beer JF, Barth JR, Criswell T, Roberts C, Richards DP.** Results of modified Latarjet reconstruction in patients with anteroinferior instability and significant bone loss. *Arthroscopy* 2007 ; 23 :1033-1041.
8. **Burkhart SS, Debeer JF, Tehrany AM, et al.** Quantifying glenoid bone loss arthroscopically in shoulder instability. *Arthroscopy* 2002 ; 18 : 488-491.
9. **Bushnel BD, Creighton RA, Herring MM.** Bony Instability of the Shoulder. *Arthroscopy* 2008 ; 24 :1061-1073.
10. **Cho SH, Cho NS, Rhee YG.** preoperative analysis of the Hill- Sachs lesion in anterior shoulder instability : How to predict engagement of the lesion. *Am J Sports Med* 2011 ; 39 : 2389-2395.
11. **Connolly J.** Humeral head defects associated with shoulder dislocations-Their diagnostic and surgical significance. *AAOS Instr Course Lect* 1972 ; 21 :42-54.
12. **Flatow EL, Warner JI.** Instability of the shoulder : Complex problems and failed repairs. Part I: relevant biomechanics, multidirectional instability, and severe glenoid loss. *Instr Course Lect* 1998 ; 47 : 97-112.
13. **Franceschi F, Longo UG, Ruzzini L, Rizzello G, Maffulli N, Denaro V.** Arthroscopic salvage of failed arthroscopic Bankart repair : a prospective study with a minimum follow-up of 4 years. *Am J Sports Med* 2008 ; 36 :1330-1336.
14. **Gerber C, Lambert SM.** Allograft reconstruction of segmental defects of the humeral head for the treatment of chronic locked posterior dislocation of the shoulder. *J Bone Joint Surg Am* 1996 ; 78 :376-382.
15. **Ghodadra N, Gupta A, Romeo AA, et al.** Normalization of glenohumeral articular contact pressures after Latarjet or iliac crest bone-grafting. *J Bone Joint Surg Am* 2010 ; 92 :1478-1489.
16. **Griffin JW, Brockmeier SF.** Shoulder with Concomitant Bone Loss In Athlete. *Orthop Clin N Am* 2015 ; 46 :89-103.
17. **Hall RH, Isaac F, Booth CR.** Dislocations of the shoulder with special reference to accompanying small fractures. *J Bone Joint Surg Am* 1959 ; 41 :489-95.
18. **Hovelius L, Sandström B, Sundgren K, et al.** One hundred eighteen Bristow-Latarjet repairs for recurrent anterior dislocation of the shoulder prospectively followed for fifteen years : study I- clinical results. *J Shoulder Elbow Surg* 2004 ; 13 :509-16.
19. **Itoi E, Yamamoto N, Omori Y. Glenoid track.** In : **Di Giacomo G, Costantini A, De Vita A, de Gaspreis N,** eds. *Shoulder Instability : Alternative Surgical Technique* 2011 ; New York, USA :Springer.
20. **Krackhardt T, Schewe B, Albrecht D, et al.** Arthroscopic fixation of the subscapularis tendon in the reverse Hill-Sachs lesion for Traumatic unidirectional posterior dislocation of the shoulder. *Arthroscopy* 2006 ; 22 :227e1-227e6.
21. **Kurokawa D, Yamamoto N, Nagamoto H, Omori Y, Tanaka M, Sano H, Itoi E.** The prevalence of a large Hill-Sachs lesion that needs to be treated. *J Shoulder Elbow Surg* 2013 ; 1.
22. **Miniaci A, Gish M.** Management of anterior glenohumeral instability associated with large Hill-Sachs defects. *Techniques in Shoulder & Elbow Surgery* 2004 ; 5 :170-175.
23. **Neyton L, Young A, Dawidziak B, et al.** Surgical treatment of anterior instability in rugby union players : clinical and radiographic results of the Latarjet-Patte procedure with minimum 5-year follow-up. *J Shoulder Elbow Surg* 2012 ; 21 : 1721-1727.
24. **Ochoa E and Burkhart SS.** Bone Defects in Anterior Instability of the Shoulder : Diagnosis and Management. *Oper tech Orthop* 2008 ; 18 : 68-78.
25. **Patte D, Debeyre J.** Luxations récidivantes de l'épaule. *Encycl Med Chir Paris. Tech Chir Orthop* 1980 ; 44265 :4.4.-025.
26. **Rokous JR, Feagin JA, Abbott HG.** Modified axillary roentgenogram a useful adjunct in the diagnosis of recurrent instability of the shoulder. *Clin Orthop Relat Res* 1972 ; 82 : 84-86.
27. **Walch G, Boileau P.** Latarjet-Bristow procedure for recurrent anterior instability. *Tech Shoulder Elbow Surg* 2000 ; 1 :256- 261.
28. **Yamamoto N, Itoi E, Abe H, et al.** Contact between the glenoid and the humeral head in abduction, external rotation, and horizontal extension : a new concept of glenoid track. *J Shoulder Elbow Surg* 2007 ; 16 : 649-56..