



The role of the carpometacarpal ligaments of the thumb in stability and the development of osteoarthritis lesions : an anatomical study

Claudia LAMAS GÓMEZ, Amer MUSTAFA GONDOLBEU, Rosa MORRO MARTÍ, Ignacio PROUBASTA RENART,
Manuel LLUSÀ PÉREZ

*from the Hand Unit and Upper Extremity. Department of Orthopaedic Surgery,
Hospital de la Santa Creu i Sant Pau, Universitat Autònoma de Barcelona*

This study aims to assess ligament lesions and subluxations of the carpometacarpal (CMC) joint of the thumbs and the role that these ligament ruptures play in the pathophysiology of osteoarthritis (OA). Twenty-five fresh-frozen cadaver hands were dissected. There were 14 female and 11 male with mean age 65 years (51-92 years old). The origin, insertion, and fibre orientation of the ligaments were identified based on Berger's anatomical descriptions. Length, thickness and width of the main ligaments were measured. The ligament ruptures and the metacarpal translation associated with these ruptures were measured (mm). Cartilage thickness in the trapezium and metacarpal of specimens was assessed. We investigated the relationship between the ligament ruptures and the area of chondromalacia and OA. In the specimens that showed an isolated or combined rupture in DRL we found a significant increase in the dorsal translation of metacarpal with a mean of 1.7 mm. Statistical analysis of data demonstrates a significant difference ($P = 0.006$). There was a relationship between the presence of a tear in the DRL and OA in the radial quadrants ($P = 0.032$). These observations suggest a translation of metacarpal on trapezium in the production of arthritic lesions and support a hypothesis that pathologic joint instability could be a cause of CMC osteoarthritis. This study suggests that repairing the DRL during ligament reconstruction of the CMC joint should be considered.

Keywords : Trapeziometacarpal joint ; Dorsoradial ligament ; Beak ligament ; Anatomical study ; Carpometacarpal osteoarthritis.

INTRODUCTION

The basal joint of the thumb is supported by a tough capsule, with strong ligaments on the volar, dorsal, and lateral aspects. As many as 16 ligaments around the joint have been described by Bettinger et al. (2). Four ligaments and the joint capsule are the main

- Claudia Lamas Gómez^{1,2},
- Amer Mustafa Gondolbeu²,
- Rosa Morro Martí²,
- Ignacio Proubasta Renart¹,
- Manuel Llusà Pérez²

¹Hand Unit and Upper Extremity. Department of Orthopaedic Surgery, Hospital de la Santa Creu i Sant Pau, Universitat Autònoma de Barcelona

²Department of Human Anatomy. Faculty of Medicine, Universitat de Barcelona, Spain.

Correspondence : Claudia Lamas Gómez, Hand Unit and Upper Extremity. Department of Orthopaedic Surgery. Hospital de la Santa Creu i Sant Pau. Universitat Autònoma de Barcelona C/ Sant Antoni M. Claret, 167, 08025 Barcelona. Spain.

E-mail: clamasg@santpau.cat

© 2017, Acta Orthopædica Belgica.

*No benefits or funds were received in support of this study.
The authors report no conflict of interests.*

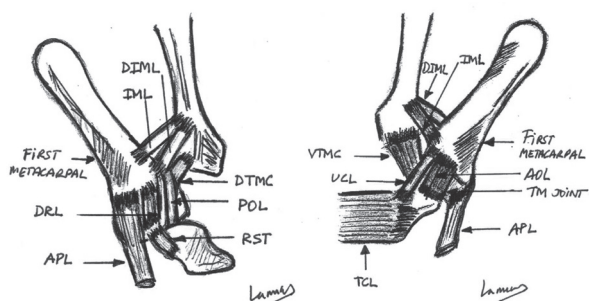


Fig. 1. — Scheme showing the ligaments of the trapezium and trapeziometacarpal (TM) joint: A) dorsal aspect and B) Volar aspect. DRL = Dorsoradial ligament, AOL = Anterior oblique ligament, POL = Posterior oblique ligament, UCL = Ulnar collateral ligament, IML = Intermetacarpal ligament, DIML = Dorsal intermetacarpal ligament, TCL = Transverse carpal ligament, and RST = radio-scaphotrapezial ligament.

stability of the TM joint is debatable. Eaton and Littler (8) believed that the AOL is the key stabilizing structure and give little credit to the dorsal ligaments in joint stability. Pellegrini (17) showed that the degeneration of the AOL increases shear forces across the joint, leading to OA and subluxation of the joint. Others authors found the DRL, POL and IML to be the key stabilizers of the joint (5,12). Strauch et al. (19) studied the importance of the TM joint ligaments in providing stability to the joint. Serial sectioning of the ligaments was performed on 38 cadaver thumbs. The primary restraint to dorsal dislocation was found to be the DRL with significant contributions from the other 3 ligaments. In these studies the four main ligaments contributed

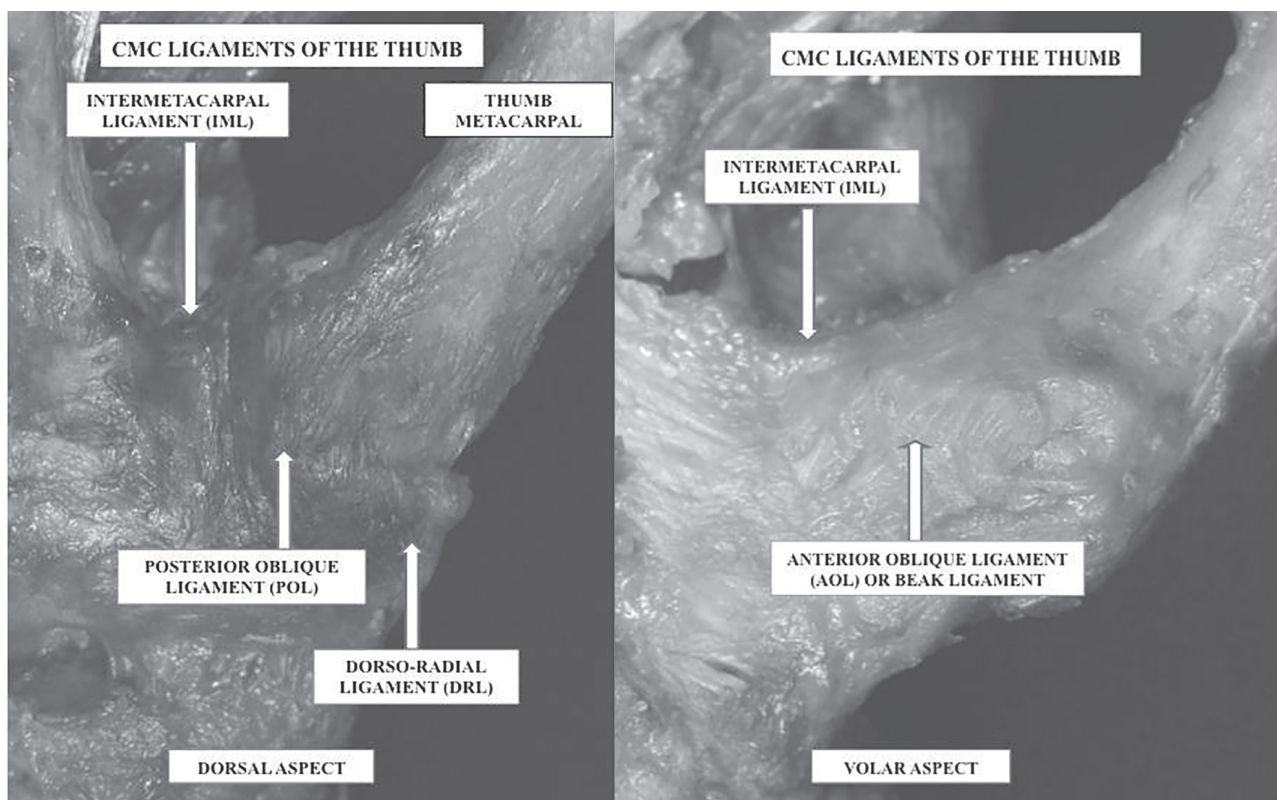


Fig. 2. — Photographs showing the main stabilizers ligaments of the TM joint: A) dorsal aspect and B) volar aspect.

stabilizers of the trapeziometacarpal (TM) joint. These ligaments are the dorsoradial (DRL), anterior oblique (AOL), posterior oblique ligaments (POL), and intermetacarpal (IML) (2,4,19) (Figs. 1 and 2). The importance of each of these ligaments in the

to TM joint stability (12,16). Ligamentous laxity and repeated longitudinal stress could produce attrition of the dorsoradial facet of the trapezium (7). A greater understanding of the pathogenesis of CMC joint OA may be clinically useful. Determining the

articular cartilage wear pattern of the thumb CMC joint is important in elucidating the etiology of OA (10). The purpose of the study was : (1) to describe the anatomy and dimension of the thumb CMC joint ligaments ; (2) to assess the ligament lesions and the degree of subluxation of the CMC joint of the thumbs ; (3) to measure cartilage thickness in the trapezium and metacarpal and pattern of chondromalacia and OA ; (4) to measure location and contact area in TM joint in opposition, palmar abduction and radial abduction. We investigated the role that these ligament ruptures play in the pathophysiology of the OA.

MATERIALS AND METHODS

Twenty-five fresh-frozen cadaver hands were dissected of all soft tissue to expose the joint capsule and ligaments of the TM joint. There were 14 female and 11 male with mean age 67 years (51-94 years old). Exposure of the CMC joint was achieved through a combined dorsal and volar approach. The dissection was performed under x4.5 loupe magnification. The origin, insertion, and fibre orientation of the ligaments were identified based on Berger's anatomical descriptions (1). Length and width of the ligaments were measured in a position of in situ maximal passive tension as described by Bettinger et al. (2) with a digital caliper (CDC-P30PMX, Mitutoyo, Kawasaki, Japan ; 0.01 mm). All ligament dimensions were obtained using a precision caliper accurate to 0.05 mm and were made after removing individual bone-ligament-bone

complexes from the hand. Lengths were measured between the intra-articular attachments (from within the joint). Width and thickness measurements were made while suspending the bone-ligament-bone complexes in air. The prevalence of each ligament, as well as the location of their bony insertions and fiber orientations were documented. We showed the main ligaments and also the ligament ruptures in IML, AOL or beak ligament, POL and DRL. We described the location of the ligament tears and whether these ruptures were partial or total. The stability of the joint was evaluated with the first metacarpal in neutral, flexed, and extended positions. Dorsoradial displacement and translation of the metacarpal shaft in relation to the trapezium was measured in millimeters (mm). The joints were dissected to expose the articular surface of both the trapezium and metacarpal without damaging to the cartilage. Each joint was staged visually for OA by using an anatomic grading method previously reported by Xu et al. (21). Cartilage thickness in the trapezium and metacarpal of specimens was measured. Cartilage thickness was evaluated as the distance from the articular surface to the corresponding subchondral bone surface. We described the degree of degenerative changes using the staging protocol to describe visual degeneration by Koff et al. (10) (Table 1). In addition to the assessment of surface coverage of fibrillation, pitting, clefts, and osteophyte formation, a hand-held depth probe for estimating the depth of cartilage lesions, under x4.5 loupe magnification was used to help assign OA stage. Each joint was then assigned an overall stage according to the highest level of degeneration

Table I. — Staging Protocol to Describe Visual Degeneration of OA Articular Cartilage

Visual Stage	Cartilage State	Description
I	Normal	Smooth, shiny, intact surface
II	Early degeneration	Matted, dull surface
IIa	Localized fibrillation and/or pitting	< 25% of total surface < 25% of depth
IIb	Moderate fibrillation and/or pitting	< 50% of total surface < 25% of depth
IIc	Pervasive fibrillation and/ or localized	< 50% of total surface < 25% of depth
III	Progressive degeneration: pitting, with or without fibrillation, Fissures, clefts, blisters, deep fissures, clefts to bone	> 25% of depth
IV	End-stage degeneration: Bone eburnation, osteophytes	

observed at any site on the trapezium or metacarpal. The OA was analysed by four anatomic quadrants (dorsal-radial, dorsal-ulnar, volar-radial, volar-ulnar). We investigated the relationship between the ligament ruptures and the area of chondromalacia and OA.

The contact area of the TM joint was studied by Momose's method (15). Similar to these authors, we calculated in opposition, palmar abduction, and radial abduction the total joint area, the contact area between trapezium and metacarpal and the ratio. Measurements of the total joint area and contact area were made in cm² and the ratio of the contact area to the contact joint area was calculated. Orientation of the TM joint was determined with reference to the plane of the thumbnail, which defined the dorsal position. The articular surfaces of the trapezium and metacarpal were divided into four segments : dorsal-radial, dorsal-ulnar, volar-radial, volar-ulnar. The total joint area of the trapezium (A) and metacarpal (B) and the noncontact area of the trapezium (a) were calculated. The contact area of the trapezium was calculated subtracting the noncontact area of the trapezium from the total area of the trapezium (A-a). The contact area of the trapezium was equal to that of the metacarpal ; the contact area of the metacarpal was therefore A-a. Because the size of each joint was different, the ratio of the contact area to the total joint area in the trapezium was $(A-a/A) \times 100\%$. The ratio of the contact area to the total joint area in the metacarpal was $(A-a/B) \times 100\%$.

The information from anatomic dissections was organized by means of the SPSS 18 computer software system and this software was also used for the statistical analysis. We correlated the ligaments disruptions with metacarpal translation and the arthritic changes. The total joint area of the trapezium (A) and metacarpal (B) and the noncontact area of the trapezium (a) were calculated in mm² and the ratio in %. Categorical variables were analysed in a univariate model by means of X² contingency table analysis. Statistical analysis of data was performed with the Chi-square test and the level of significance was $P < 0.05$. Comparison between means of the surface of the trapezium and metacarpal was made with the Student's t-test.

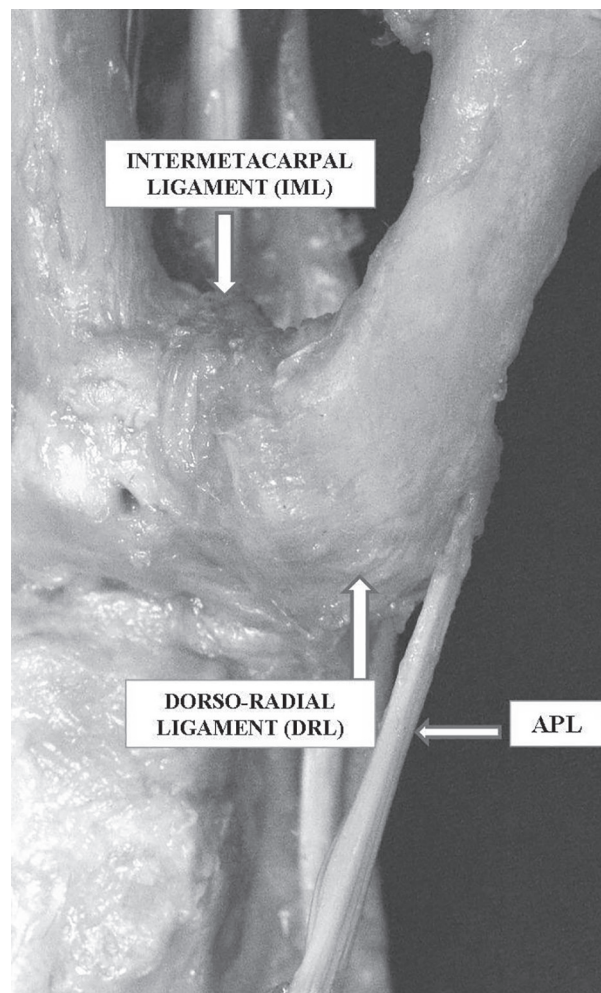


Fig. 3. — Stability of the TM joint of the thumb associated with the dorso-radial ligament complex.

RESULTS

Anatomical description and dimension of the ligaments.

Seven principal ligaments of the thumb CMC joint were identified using Berger's principles (1) : three dorsal deltoid-shaped ligaments (dorsal radial, dorsal central, posterior oblique), two volar ligaments (anterior oblique and ulnar collateral) and two ulnar ligaments (dorsal trapeziometacarpal and intermetacarpal). The DRL is covered on its dorsoradial side by the Abductor Pollicis Longus (APL), which attaches distally on the lateral side on the first metacarpal and is located radially to

the POL, which is immediately adjacent to the DRL. The APL had a distal insertion divided into superficial part and deep part. The superficial part is inserted with one or more tendons into the radial side of the base of the first metacarpal bone, and the deep part is variably inserted into trapezium, the joint capsule and its ligaments, and into the belly of Abductor Pollicis Brevis or Opponens Pollicis. An accessory APL tendon was present in more than 90% of the specimens. The DRL originates from the dorsoradial tubercle on the trapezium and inserts the dorsal edge of the base of first metacarpal (Fig. 3). The average length of the DRL obtained during dissection was 12.8 mm (SD = 0.6). The average thickness of the DRL was 1.3 mm (SD = 0.3) and the average width was 6 mm (SD = 0.5). The AOL is located just beneath the thenar muscles and is intimately linked to them. The AOL originates from the volar tubercle of the trapezium and inserts across the volar ulnar tubercle (palmar beak) of the first metacarpal. The average length of the AOL obtained during dissection was 12.6 mm (SD = 1.5). The average thickness of the AOL was 0.7 mm (SD = 0.4) and the average width was 5.2 mm (SD = 0.3) (Fig. 4 and 5) (Table 2).

Ligament ruptures

Ligament lesions were found in all 25 specimens. Isolated rupture of the dorsoradial ligament (DRL) was found in 10 (40%), isolated rupture of the anterior oblique ligament (AOL) was found in 7 (28%), isolated rupture of the intermetacarpal ligament (IML) was found in 2 (8%). Combined rupture of

the DRL and IML in 4 (16%), combined rupture of the AOL and IML in 2 (8%) joints. The mean metacarpal displacement due to isolated rupture of the ligaments was DRL 1.6 mm, AOL 1.1 mm, POL 0.2 mm and IML 0.4 mm. The mean metacarpal displacement due to combined rupture of the DRL and IML was 1.7 mm ; and combined rupture of the AOL and IML was 1.3 mm. We have correlated the isolated or combined ligament ruptures with the metacarpal displacement. There was a relationship between the presence of a DRL rupture and the presence of metacarpal displacement. Statistical analysis of the anatomical data demonstrates a significant difference ($P = 0.006$) (Table 3).

Chondromalacia and osteoarthritis

We found 2 cases OA stage I, 7 cases OA stage II (1 IIa, 3 IIb and 3 IIc), 9 OA stage III and 7 OA stage IV (Fig. 6). We have correlated the isolated rupture of the DRL, AOL, IML and combined ruptures (DRL and IML ; AOL and IML) with the arthritic changes in the four anatomical quadrants (dorsal-radial, dorsal-ulnar, volar-radial, volar-ulnar). Statistical analysis with X²-test found these results $P = 0.032$, $P = 0.649$, $P = 0.617$, $P = 0.041$, $P = 0.635$, respectively. There was a relationship between the presence of a tear in the DRL and the presence of OA in the radial quadrants ($P = 0.032$). We showed that cartilage degradation is initiated in the radial quadrants of the metacarpal and progresses to the volar quadrants of the articular surface (Fig. 7).

Contact locations and area

In opposition, the contact area of the trapezium was located in the radial, volar and ulnar segments of the joints. The contact area of the metacarpal was in the dorsal, radial, and volar segments. In palmar abduction, the contact area of both the trapezium and metacarpal was in the radial segments. In radial abduction, the contact area of both the trapezium and metacarpal was in the dorsal segments. We calculated the surface of the trapezium and the first metacarpal. The average trapezium surface was 281.3 mm² (SD = 63.9). The average metacarpal surface was 252.7 mm² (SD = 43.1). Both surfaces are similar and the results are not statistically

Table II. — Ligament dimensions *

Ligament	Length (mm)	Width (mm)	Thickness (mm)
DRL	12.8 ± 0.6	6 ± 0.5	1.3 ± 0.3
AOL	12.6 ± 1.5	5.2 ± 0.3	0.7 ± 0.4
POL	11.6 ± 1.3	4.1 ± 0.1	1.4 ± 0.3
UCL	9.8 ± 0.9	4.7 ± 0.2	1.1 ± 0.4
IML	11.2 ± 0.6	2.6 ± 0.4	0.8 ± 0.1

* The values are given as the mean and standard deviation. DRL= Dorsoradial ligament, AOL= Anterior oblique ligament, POL= Posterior oblique ligament, UCL= Ulnar collateral ligament, and IML= Intermetacarpal ligament.

Table III. — Ligament ruptures and metacarpal displacement *

Ligament	rupture (cases)	Mean metacarpal displacement (mm)	X 2 test (P< 0.05)
DRL	10	1.6	0.01
AOL	7	1.1	0.449
POL	0	0.2	0.821
IML	2	0.4	0.617
Combined DRL + IML	4	1.7	0.006
Combined AOL + IML	2	1.3	0.325

* DRL= Dorsoradial ligament, AOL= Anterior oblique ligament, POL= Posterior oblique ligament, and IML= Intermetacarpal ligament.

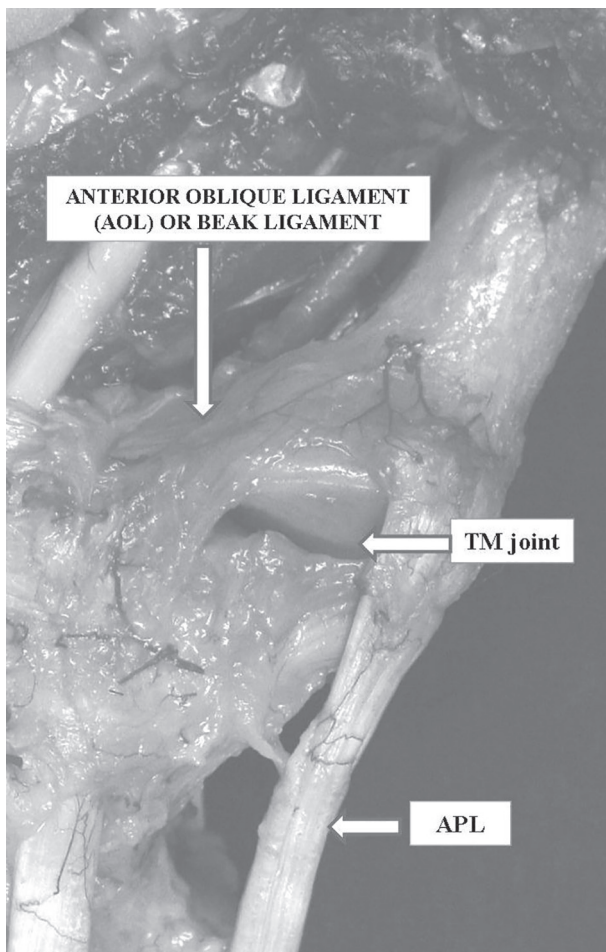


Fig. 4. — Anatomical structure and insertion of the anterior oblique ligament (AOL) in the CMC joint of the thumb.

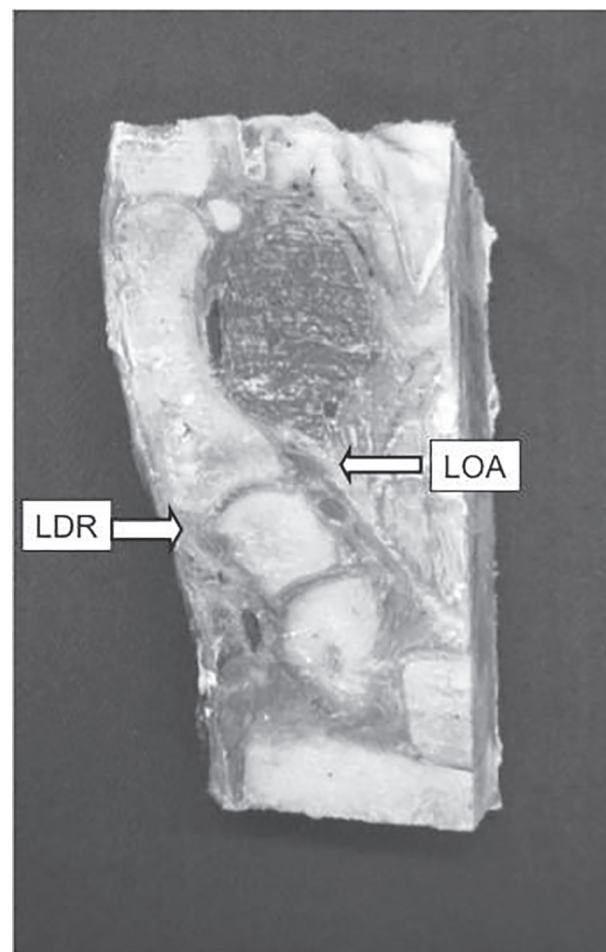


Fig. 5. — Sagittal section of the thumb. Anterior oblique ligament (AOL) and dorso-radial ligament (DRL).

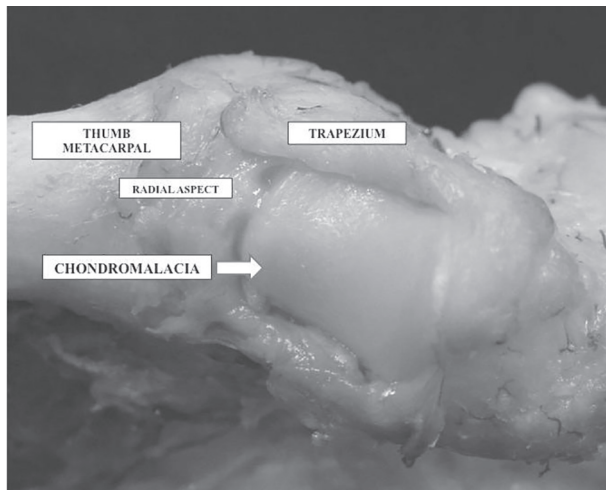


Fig. 6. — Chondromalacia in the articular surface of the trapezium. Concavoconvexity of trapezium analogous to a saddle.

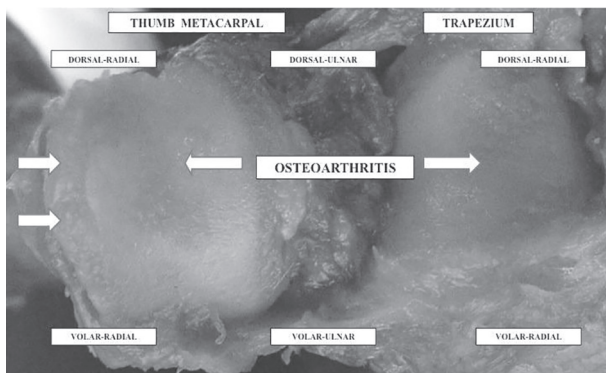


Fig. 7. — Cartilage degradation is initiated in the radial quadrants of the metacarpal and trapezium and progresses to the volar quadrants of the articular surface.

significant (Student's t-test 0.643). The contact area was the largest in opposition. Measurements of the total joint area and contact area were taken and the ratio of the contact area to the total area was calculated. On average, 54.8% of the trapezium was in contact with 55.3 % of the metacarpal in opposition, while 30.2 % of the trapezium was in contact with 26.4 % of the metacarpal in palmar abduction and 23.5 % of the trapezium was in contact with 21.7 % of the metacarpal in radial abduction. The ratio of the contact area to the total joint area was largest in opposition for the trapezium and the metacarpal ($p < 0.01$).

DISCUSSION

Osteoarthritis at the base of the thumb most frequently presents in association with involvement of other joints in one or two common patterns of disease. Primary idiopathic OA affects the distal interphalangeal joint most frequently (85%) with TM involvement in 65% of the cases (17). Eaton and Littler (7,8) have suggested that the dorsoradial facet of the TM joint was the first site to be involved with degenerative disease. Seeing this region of the joint during surgical reconstruction demonstrated chondromalacic articular cartilage. The hypothesis for the cause of TM osteoarthritis could include attritional changes in the ligaments preferentially DRL and AOL. The dorsopalmar translation of the metacarpal on the trapezium during normal activities and the degenerative changes could increase with different factors (4). One factor is the laxity of the CMC joint capsule. This laxity could be due to trauma, age or systemic synovial inflammation and also to partial or total ligament ruptures (8). The other factor is compressive loading in joint surface during movements. Eaton and Littler (8) hypothesized that the peripheral area adjacent to the APL insertion experienced direct compressive loading and joint surface impingement in the functional position of palmar abduction and extension. Joint surface contact pressure patterns in a cadaver model simulating lateral pinch have confirmed the primary loading areas to be in the same palmar regions of the joint as the eburnated surfaces in diseased joints (18). Biochemical analysis of the hyaline cartilage from arthritic TM joints showed preferential loss of glycosaminoglycan from the extracellular matrix with sparing of collagen in the palmar regions. These findings are consistent with other studies and suggest a selective biochemical degradation of the cartilage matrix (13).

However, the role of the main ligaments in CMC joint it is still under discussion. Some authors (3,4,19), supported by previous biomechanical studies, identified the DRL as the ligament that stabilizes the CMC joint and prevents joint subluxation. Anatomically, the DRL is one of the thickest and broadest ligaments in the CMC joint and its function is to prevent dorsoradial subluxation of the

metacarpal (20). For others (17) the AOL is the key to CMC stability in power pinch or grasp and if it is cut or torn the joint loses all stability. The IML and POL play a secondary role in CMC joint stability and in preventing radial translation. D'Agostino et al. (5) have measured the ligament length and thickness with MRI and anatomical dissection. Comparison of the MRI dimensions of the DRL and the AOL indicated that the DRL was significantly shorter, thicker, and narrower than the AOL. Similar to other authors (9,11) our results suggest that the AOL and DRL play an important role in stabilizing the CMC joint. However, our results showed that the DRL is significantly shorter and thicker than the AOL, which is thin and ill-defined. Our dissections found a thin AOL with less importance in CMC stability than the DRL. Our results also indicate that the DRL has a higher stiffness than AOL, making it a more likely candidate to provide joint stability. Our findings suggest that the DRL is a strong structure and its rupture allows metacarpal translation. Statistical analysis of the anatomical data demonstrates a significant difference ($P = 0.006$). In the study published by Ladd et al. (11) that included thirty cadaver hands, in all specimens the AOL was extremely thin and capsular. With an average thickness of < 0.8 mm this structure was hard to delineate even with $\times 4.5$ loupe magnification and macroscopically appeared to be little more than a reinforced joint capsule. In the study of Mobargha et al. (14) the dense collagen structure and rich innervation of the DRL in patients with OA suggest that the DRL has an important proprioceptive and stabilizing role. In our specimens the complete isolated lesion of the DRL or combined with the IML rupture resulted in the greatest dorsoradial subluxation of the metacarpal ($P = 0.006$). There was a significant relationship between the presence of a tear in the DRL and OA in the radial quadrants ($P = 0.032$). Dumont et al. (6) propose assessing ligament lesions and subluxations of the CMC joints of the thumbs and OA using advanced magnetic Resonance imaging (MRI). MRIs of CMC frequently show combined ligament ruptures. The dorsal subluxation of metacarpal correlates with OA severity based on X-rays and can be quantified by MRI (6). We measured the contact area with the

thumb at maximum angle of opposition, palmar abduction and radial abduction to investigate the contact area in the position of pinch and grasp. Our results showed that the ratio of the contact area to the total joint area was largest in opposition for the trapezium and the metacarpal ($p < 0.01$).

Limitations of the study

There are some limitations in the study. This is an experimental study and the mean age of our specimens was relatively high (65 years). The age of the specimens may have had an impact on ligament integrity and osteoarthritis.

Clinical relevance

Stability of the CMC joint of the thumb relies on muscles, tendons, and ligaments crossing the joint. Laxity of the ligaments has been proposed as a mechanism for the development of OA of the TM joint. Understanding ligament function and its relevance is primordial in optimizing surgical interventions. We need to know the ligament functions to reconstruct the ligament or ligaments that give the joint stability. Our study suggests that translation of the metacarpal on trapezium was associated to DRL ruptures. These lesions produce joint instability and also cartilage degeneration. Our results support the hypothesis of pathologic joint instability as the cause of TM osteoarthritis. This study suggests that repairing the DRL during ligament reconstruction of the CMC joint of the thumb should be considered.

Acknowledgments

The authors thank the donors of the cadavers in the Department of Anatomy, Faculty of Medicine, for their indispensable contribution to this study.

REFERENCES

1. **Berger RA.** The anatomy of the ligaments of the wrist and distal radioulnar joints. *Clin Orth Rel Res* 2001 ; 383 : 32-40.
2. **Bettinger PC, Linscheid RL, Berger RA, Cooney WP, An KN.** An anatomic study of the stabilizing ligaments of the trapezium and trapeziometacarpal joint. *J Hand Surg* 1999 ; 24-A : 786-798.

3. **Bettinger PC, Smutz P, Linscheid RL, Cooney WP, An KN.** Material properties of the trapezial and trapeziometacarpal ligaments. *J Hand Surg* 2000 ; 25-A : 1085-1095.
4. **Colman M, Mass DP, Draganich LF.** Effects of the deep anterior oblique and dorsoradial ligaments on trapeziometacarpal joint stability. *J Hand Surg* 2007 ; 32-A : 310-317.
5. **D'Agostino P, Kerkhof FD, Shahabpour M, Moermans JP, Stockmans F, Vereecke E.** Comparison of the anatomical dimensions and mechanical properties of the dorsoradial and anterior oblique ligaments of the trapeziometacarpal joint. *J Hand Surg* 2014 ; 39-A : 1098-1106.
6. **Dumont C, Lerzer S, Vafa MA, Tezval M, Dechent P, Stürmer KM, Lotz J.** Osteoarthritis of the carpometacarpal joint of the thumb : a new MR imaging technique for standardized detection of relevant ligament lesions. *Skeletal Radiol* 2014 ; 43 : 1411-1420.
7. **Eaton RG, Littler JW.** A study of the basal joint of the thumb. Treatment of its disabilities by fusion. *J Bone Joint Surg Am* 1969 ; 51 : 661-668.
8. **Eaton RG, Littler JW.** Ligament reconstruction for the painful thumb carpometacarpal joint. *J Bone Joint Surg* 1973 ; 55-A : 1655-1666.
9. **Edmunds JO.** Current concepts of the anatomy of the thumb trapeziometacarpal joint. *J Hand Surg* 2011 ; 36-A : 170-182.
10. **Koff MF, Ugwonalu OF, Strauch RJ, Rosenwasser MP, Ateshian GA, Mow VC.** Sequential wear patterns of articular cartilage of the thumb carpometacarpal joint in osteoarthritis. *J Hand Surg* 2003 ; 28-A : 597-604.
11. **Ladd AL, Lee J, Hagert E.** Macroscopic and microscopic analysis of the thumb carpometacarpal ligaments. *J Bone Joint Surg* 2012, 94-A : 1468-1477.
12. **Lin JD, Karl JW, Strauch RJ.** Trapeziometacarpal joint stability : the importance of the dorsal ligaments. *Clin Orth Rel Res* 2014 ; 472 : 1138-1145.
13. **Mankin H, Dorfman H, Lippiello L.** Biomechanical and metabolic abnormalities in articular cartilage from osteoarthritic human hips. II. Correlation of morphology with biomechanical and metabolic data. *J Bone Joint Surg* 1971 ; 53-A : 523-537.
14. **Mobargha N, Ludwing C, Ladd AL, Hagert E.** Ultrastructure and innervation of thumb carpometacarpal ligaments in surgical patients with osteoarthritis. *Clin Orth Rel Res* 2014 ; 472 : 1146-1154.
15. **Momose T, Nakatsuchi Y, Saitoh S.** Contact area of the trapeziometacarpal joint. *J Hand Surg* 1999 ; 24-A : 491-495.
16. **Ozer K.** A new surgical technique for the ligament reconstruction of the trapeziometacarpal joint. *Tech Hand Upper Extremity Surg* 2006 ; 10 : 181-186.
17. **Pellegrini VD.** Osteoarthritis of the trapeziometacarpal joint : The pathophysiology of articular cartilage degeneration. I. Anatomy and pathology of the aging joint. *J Hand Surg* 1991 ; 16-A : 967-974.
18. **Pellegrini VD.** Osteoarthritis at the base of the thumb. *Orthopaedic Clinics of North Am* 1992 ; 23 : 83-102.
19. **Strauch RJ, Behrman MJ, Rosenwasser MP.** Acute dislocation of the carpo-metacarpal joint of the thumb : an anatomic and cadaver study. *J Hand Surg* 1994 ; 19-A : 93-98.
20. **Tan J, Xu J, Guo Xie R, Dong Deng A, Bo Tang J.** In vivo length and changes of ligaments stabilizing the thumb carpometacarpal joint. *J Hand Surg* 2011 ; 36-A : 420-427.
21. **Xu L, Strauch RJ, Ateshian GA, Pawluk RJ, Mow VC, Rosenwasser MP.** Topography of the osteoarthritic thumb carpometacarpal joint and its variations with regard to gender, age, site and osteoarthritic stage. *J Hand Surg* 1998 ; 23-A : 454-464.